

Cloudy central corneal dystrophy of François

Five cases in the same family

I. M. STRACHAN

Department of Ophthalmology, Royal Hospital, West Street, Sheffield

François (1956a) reported eight cases of a corneal dystrophy which had not previously been described. The lesion, visible only with the slit lamp, affected a disc in the central third of the corneal stroma, and consisted of small cloudy grey areas with indefinite structure and indistinct margins. These areas were larger and more numerous in the posterior part of the stroma and became smaller and less frequent in the anterior part. In some cases the anterior layers of the stroma were unaffected but in others the grey patches reached Bowman's membrane. The corneal endothelium and epithelium were unaffected. The ages of his patients ranged from 35 to 76 years. It was not considered that the dystrophy affected the visual acuity, as in those patients with an acuity of less than 6/6 there were other ocular lesions to account for the visual impairment. In sibship of five two members were affected, but the other six cases described had no affected relatives. The condition was said to be non-progressive and the mode of inheritance was obscure (François, 1956b; 1961). A further case was described by François and Neeter (1957) in a family with central speckled corneal dystrophy.

Collier (1964) described a woman of 72 years with central speckled dystrophy in both eyes and cloudy central dystrophy in one. The daughter of this patient also suffered from central speckled corneal dystrophy. Collier (1965) described another case in one of two sisters who both suffered from pseudoxanthoma elasticum. The 17-year-old son of this patient had some fine opacities in the posterior third of the corneal stroma in one eye. Collier (1966) described a further case in a 77-year-old man whose son was found to have a predescemetic dystrophy.

Material

(1) **A 77-year-old woman** (Fig. 1, I, 2) complained of failing vision due to senile cataract, and was noted to have cloudy central corneal dystrophy which was so marked as to be visible to the naked eye (Fig. 2).

The appearance described by François (1956a) was confirmed by slit-lamp examination. All the available members of her family were examined (Fig. 1), and this brought to light four more cases: two daughters (II, 7 and II, 10), a granddaughter (III, 12), and a niece (II, 4).

(2) **A woman aged 53** (Case II, 7) had corneal lesions similar to her mother's, which were also visible to the naked eye.

(3) **A woman aged 33** (Case II, 10) had less marked corneal involvement confined to the posterior layers of the stroma and visible only by the slit lamp.

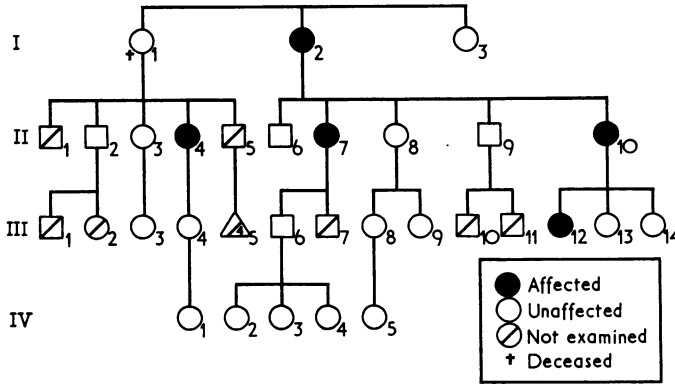


FIG. 1 Family tree

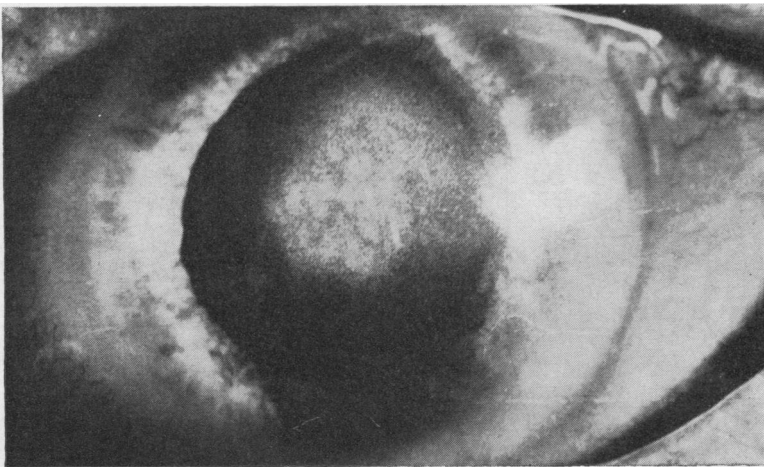


FIG. 2 Appearance of cloudy corneal dystrophy in Case I, 2

(4) **An 8-year-old girl** (Case III, 12) showed posterior stromal lesions visible by the slit lamp.

(5) **A 47-year-old woman** (Case II, 4) also had lesions like those of Cases 3 and 4. This case was discovered when members of a collateral branch of the family were examined.

All these five cases had equal involvement of both corneae. Four had visual acuity of 6/5 in each eye and removal of the cataract from the right eye of Case 1 improved her visual acuity to 6/5 also.

Discussion

The mode of inheritance of cloudy central corneal dystrophy in the cases previously reported has been uncertain. Only two pairs of related cases of cloudy central dystrophy have been described previously (François, 1956a; Collier, 1965). François's cases were two sibs and Collier's a doubtfully affected son of an affected mother. The family described here showed inheritance of the trait in three successive generations and therefore appears to show a dominant mode of transmission.

Summary

Five cases of the cloudy central corneal dystrophy of François in the same family are described; in this family it appears to have been transmitted as a dominant trait.

I wish to acknowledge the secretarial help given by Mrs. M. E. Goodliffe and to thank Mr. F. M. Dunca who took the photograph.

References

- COLLIER, M. (1964) *Bull. Soc. Ophtal. Fr.*, p. 608
——— (1965) *Ibid.*, p. 301
——— (1966) *Ibid.*, p. 575
FRANÇOIS, J. (1956a) *Bull. Soc. belge Ophtal.*, No. 111, p. 391
——— (1956b) *J. Génét. hum.*, **5**, 189
——— (1961) "Heredity in Ophthalmology", p. 312. Mosby, St. Louis
——— and NEETENS, A. (1957) *Bull. Soc. belge Ophtal.*, No. 114, p. 641