

Primary calcareous degeneration of the cornea

HARI MOHAN, D. K. GUPTA, AND D. K. SEN

Department of Ophthalmology, Irwin Hospital, New Delhi, 1, India

Primary calcareous degeneration of the cornea is a very rare condition. Axenfeld (1917) reported a bilateral case in a boy aged 8 years; a massive deposition of calcium phosphate occurred in the superficial and central strata of the parenchyma, slightly affecting Bowman's membrane and leaving the epithelium intact (Duke-Elder, 1965). Michail (1935) reported a similar case which followed a slight injury but the changes were quite disproportionate to the original damage.

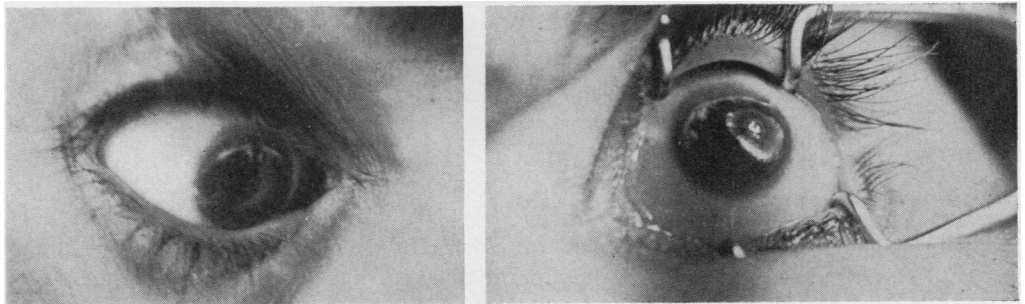
In these three eyes the lesion started round the periphery and extended towards the centre, but Tita (1940) reported a case in which the deposits were localized.

Two cases of primary calcareous degeneration of the cornea, one unilateral and the other bilateral, are presented below.

Case reports

(1) **A man aged 30 years** attended the ophthalmic out-patient department on June 1, 1967, complaining of failing vision for the past few months.

Examination General and systemic examination revealed nothing abnormal. Both eyes presented an almost symmetrical and identical picture. A dense chalky-white linear-shaped opacity (about 1 mm. wide) with irregular margins ran along the limbus from 10 to 2 o'clock (Figs 1 and 2). There was a clear area of 2-3 mm. between the opacity and the limbus. From this linear opacity numerous small processes of similar nature extended vertically in an irregular manner towards the centre of the cornea but fell short of the pupillary area. The patient reported that this opacity had been present since childhood and was not increasing. There was no history of soreness or trauma, and no one in his family had suffered from a similar condition.



FIGS 1 and 2 *Right and left eyes in Case 1*

Slit-lamp examination The eye was quiet, with no evidence of inflammation. The calcareous deposits were granular in nature and were seen mostly in the superficial stromal region. In places Bowman's membrane was also involved. Over the site of opacity, the epithelium was raised from the surface but no calcareous deposit could be seen on the epithelium (Fig. 3).

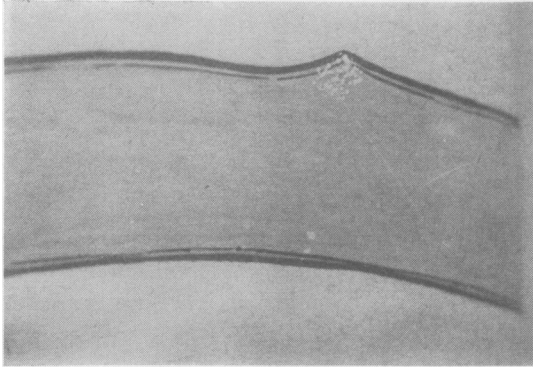


FIG. 3 *Slit-lamp appearance in Case 1*

The anterior chamber, pupil, iris, lens, ocular tension, and fundus were normal.

The visual acuity was 6/18 (Snellen), improving to 6/6 with -1D sph. in both eyes.

Laboratory investigations Serum calcium and phosphate and urinary calcium and phosphate levels were within normal limits. There was no evidence of osteoporosis or sarcoidosis.

(2) **A man aged 22 years** complained of failing vision in October, 1967.

Examination A linear-shaped opacity extended from 8 to 11 o'clock 2-3 mm. from the limbus of the right eye only.

Slit-lamp examination The superficial layers of the stroma were involved as in Case 1, but the opacity was not so dense (Fig. 4) and was unioocular.

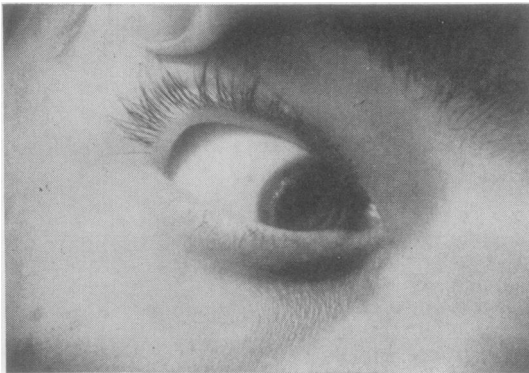


FIG. 4 *Right eye in Case 2*

Comment

Calcareous degeneration of the cornea in which calcium carbonate and phosphate are deposited as granules in the superficial layers of the cornea, may be of secondary or primary origin. Secondary calcareous degenerations are more common and may occur in old scars, leucomata, atheromatous ulcers, or cases of band-shaped keratopathy or hyper-

calcaemia, *e.g.* sarcoidosis or osteoporosis (Duke-Elder, 1965). Primary calcareous degeneration with no evidence of hypercalcaemia is comparatively rare, and its aetiology is not known. Nor is it clear why in some cases the degeneration progresses and interferes with visual acuity.

Summary

Two rare cases of primary calcareous degeneration of the cornea (one unilateral, and the other bilateral and symmetrical) are presented. In both cases the deposits were localized and the condition stationary.

References

- AXENFELD, T. (1917) *Klin. Mbl. Augenheilk.*, **58**, 58 (Cited by Duke-Elder, p. 891)
DUKE-ELDER, S. (1965) "System of Ophthalmology", vol. 8 (part 2), pp. 890-892. Kimpton, London
MICHAEL, D. (1935) *Arch. Ophthal. (Paris)*, **52**, 247 (Cited by Duke-Elder, p. 891)
TITA, C. (1940) *Boll. Oculist.*, **19**, 19 (Cited by Duke-Elder, p. 892)