

Maculopathy in pellagra

S. P. MATHUR

Department of Ophthalmology, R.N.T. Medical College, and General Hospital, Udaipur, Rajasthan, India

Pellagra is very common in the rural area of Udaipur, where maize is the staple diet. The condition is due to a deficiency of nicotinic acid in food, and is frequently part of a general malnutrition syndrome. Pellagra manifests as dermatitis, diarrhoea, and dementia; the typical dermatitis (Fig. 1) appears in the cooler months, and affects the exposed parts of the body when villagers bask in the sun. There may be brownish pigmentation of the skin of the eyelids, the lid margin, and the exposed part of the conjunctiva, limbus, corneal epithelium, and cortical and sub-cortical areas of the lens (Fig. 2).

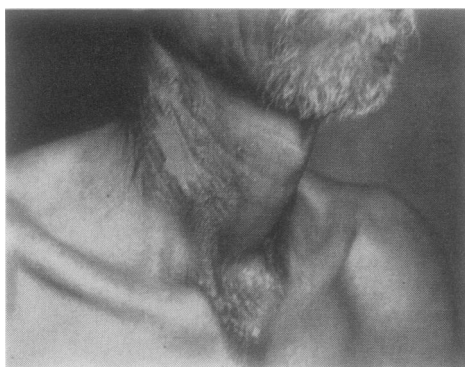

FIG. 1 *Necklace type of dermatitis involving exposed parts of the skin*

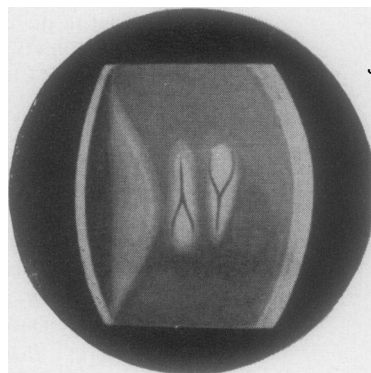


FIG. 2 *Brown pigment in the posterior cortical area of the lens, and yellowish brown towards the nucleus*

The present study includes a careful examination of the fundus in 61 cases of pellagra and to the best of our knowledge, these observations have not been described in the literature. A preliminary survey of the subject was reported at the conference of the All India Ophthalmological Society in 1966.

Material

Cases of pellagra with severe manifestations requiring hospitalization were taken from the medical wards of the General Hospital, Udaipur.

Method

The eyes were examined in detail with the slit lamp and ophthalmoscope. The visual acuity and colour vision were recorded as far as the illiteracy and mental defects of the patients permitted.

Treatment consisted in a diet rich in protein, milk, and vegetables, with massive doses of nicotinic acid and other vitamin B complex factors.

Most of the patients showed a marked improvement within a month and were discharged with instructions to continue the treatment at home.

Observations

The fundus showed the following changes (Fig 3):

- (1) Hyperpigmentation all over the retina (32·8 per cent.).
- (2) Loss of yellow reflex at the macula (47·5 per cent.).
- (3) Vascularization and hyperaemia of the macular area (55·7 per cent.).
- (4) Hyperpigmentation at the macular area similar to that caused by burns (32·8 per cent.).

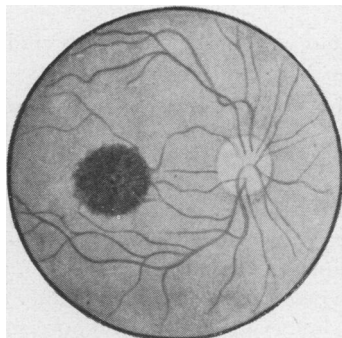


FIG. 3 *Diagram of the fundus showing burn at the macula; there was loss of yellow reflex, hyperaemia, vascularization, and hyperpigmentation*

There was reduced visual acuity and colour vision in 64 per cent.

All these changes were more marked in older patients in whom the disease was more severe and of longer duration.

After treatment there was only partial improvement in visual acuity in 67 per cent. (26 out of 39), and no improvement in the appearance of the macula.

Discussion

The various manifestations of pellagra are caused by sensitivity of the ectodermal structures produced by a deficiency of nicotinic acid. Exposure to sunlight causes dermatitis and hyperpigmentation of the skin and similar changes occur in the eyes and adnexa. In affected subjects normal sunlight causes retinal hyperpigmentation, and at the macula, where the intensity of light is greater, the appearance is similar to a burn, with loss of foveal reflex, vascularization, and hyperaemia; this is accompanied by a loss of visual acuity.

After treatment, two of the three general manifestations (dermatitis and diarrhoea) were greatly improved, as was the pigmentation of the lids, conjunctiva, and cornea. But the extent and density of pigmentation in the lens and the retinal damage did not improve nor did the patients regain their normal mental level. There was a slight improvement in visual acuity in 26 out of 39 patients in whom the disease was of shorter duration. It is therefore important to treat pellagra in the very early stages before permanent damage to the brain or macula has taken place. Better still is the prevention of pellagra by improving the availability of necessary food.

Summary

The eyes of patients with chronic and severe pellagra were examined in detail. The most important findings were changes in the retina and macula similar to burns. Treatment improved the general condition of the patients but not their mental and visual impairment.

I am grateful to the Principal of the R.N.T. Medical College, Udaipur, for permission to publish this paper, and to the Professor and Head of the Department of Medicine for allowing me to examine his patients.