

Cataracts of dysplasia epiphysialis punctata

HUGH RYAN

St. Vincent's Hospital, Melbourne, Australia

This rare disease of cartilage in infants has been recorded under various names since it was first described by Langhans (1893). Amongst these are chondrodystrophia calcificans congenita, chondrodystrophia punctata, stippled epiphyses, foetal epiphyseal calcinosis, chondrodystrophia calcarea, chondroangiopathia calcarea seu punctata, and chondrodystrophia hypoplastica calcinosa.

Conradi (1914) described the radiological appearance of the condition. He thought it was an atypical form of achondroplasia, and it was not until much later that Fairbank (1927) distinguished the two conditions.

In 43 cases described by Yakovac (1954), 25 per cent. had bilateral cataracts; these were present in Conradi's original case. Optic atrophy has also been described in this condition.

The disease, as the name suggests, has a striking radiographic appearance, the irregular calcification of the cartilage of the epiphyses giving a characteristic stippled appearance. This stippling may be generalized throughout the cartilage or limited to an area around the centre of ossification. It has been reported to disappear later in childhood (Paul, 1954).

In association with this abnormality there are usually other defects. The infants are frequently dwarfs of the short limb type. There may be contractures of the limbs, talipes, kyphoscoliosis, "saddle-shaped" nose, enlargement of the skull, and mental deficiency, and the skin may be thickened. In general the infant is weak and usually fails to thrive, so that death from intercurrent infection in the first 12 months of life is almost the rule.

Case report

A baby boy 11 weeks old was referred for investigation because of loss of weight and a history of not sucking well. He weighed 7 lb. (3.4 kg.) and was 19½ in. (50 cm.) in length. The head appeared large in proportion to the body length with marked parietal and occipital eminences. The head was 14 in. (35.5 cm.) in circumference and in general the baby appeared stunted. Examination of the eyes showed bilateral mature cataracts.

There were marked contractures of the limbs and limitation of movement of the shoulders, elbows, hips, and knees. The legs were kept in marked adduction. There was a rash on the skin of the chin, cheeks, and neck. The liver was enlarged. The facies were abnormal, rather suggesting a mongoloid condition. Mentally the baby was apathetic and a generalized weakness was obvious. X-ray examination of the skeleton showed stippling of the epiphyses of the long bones, and the femoral and humeral shafts were short and thick.

Pathology The baby died soon afterwards and an eye was obtained for histological examination. It measured 16 × 17 mm. Microscopic examination showed the cornea to be normal except that Descemet's membrane was rather thinner than usual. The iris was normal but the ciliary processes were very poorly developed.

The main pathology was seen in the lens (Figure). The trouble lay mainly in the equatorial and subcapsular regions. The equatorial lens epithelium was abnormal in that it consisted of large swollen cells proliferating but not forming any true lens fibres. The more superficial of these cells showed large vacuoles filled with clear fluid displacing the nuclei towards the centre of the lens. The anterior polar region gave a picture of normal subcapsular epithelial cells, but the abnormal lens fibres arising from the equator extended in a haphazard fashion deep in this epithelium right up to the anterior pole. These abnormal fibres also extended for a considerable distance in the posterior portion of the lens.

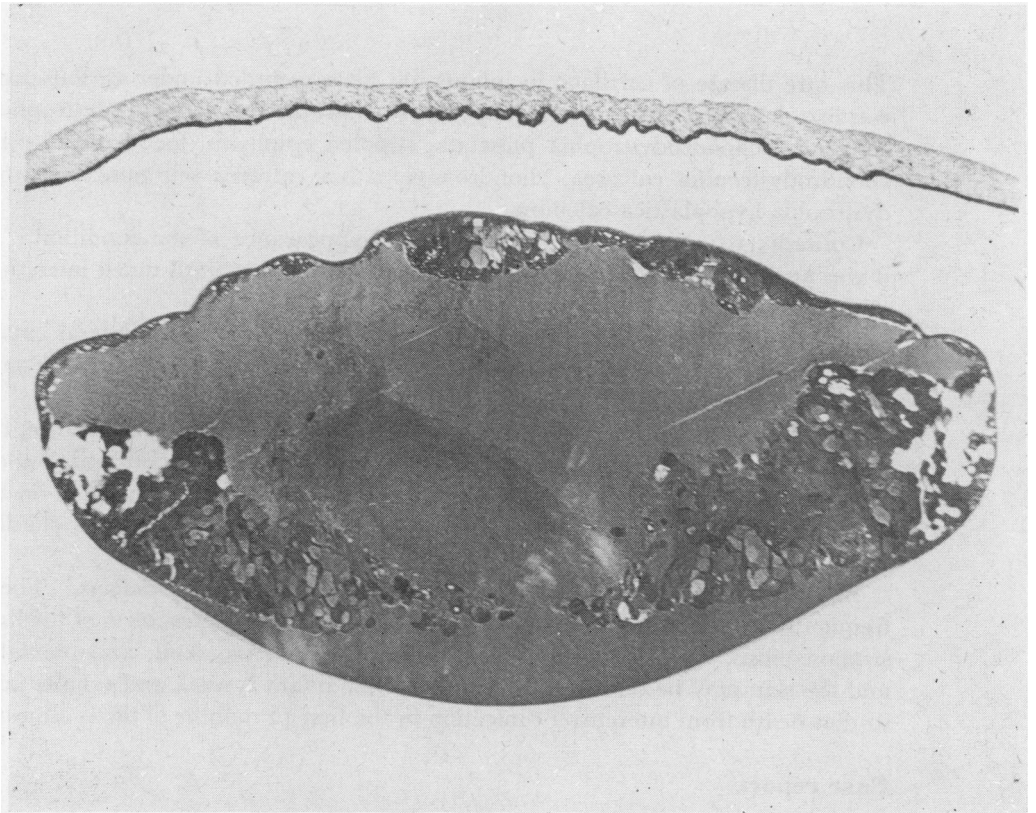


FIGURE Site of cataract and vacuolated abnormal lens fibres

The centre of the lens became more normal as it was followed inwards, except for one area where an unidentifiable abnormal material was deposited between the fibres. No crystals were to be seen in the lens substance. The lens capsule was well developed and normal. The retina showed some oedema of the nerve fibre layer and a small subretinal haemorrhage. The optic nerve was normal. The extraocular muscles were infiltrated by small round cells and some endothelioid cells.

Discussion

Histological examination of the lens showed that the condition was a primary malformation of the secondary lens fibres and not a degeneration of the originally normal lens fibres. From the position of the abnormalities in the lens in relation to other lens structures, it appeared that the noxious agent began to act in about the fifth or sixth month of foetal life, and that it had continued to act after birth until death supervened.

In considering the nature of the noxious agent there are several points to be discussed. The vacuolation and swelling of the cells and fibres of the lens epithelium suggest that the agent acts on the metabolism of the cell. The disease begins in about the fifth month of intrauterine life, at which time a changeover in the mechanism of the nutrition of the lens is occurring. Up to this time the nutrition of the lens is effected by the tunica vasculosa lentis but later, after this has atrophied, the lens is dependent on the aqueous humour for its metabolic needs. It would appear that the former mode of nutrition is adequate for the growing lens, but that trouble begins when the lens fibres are required to obtain their nourishment from the aqueous.

Lenticular metabolism when mediated by the aqueous humour is effected by a complex system of enzymes. The energy requirements of the lens are served mainly by carbohydrate metabolism, in particular glucose metabolism, by a very complicated series of reactions, each apparently with its own enzyme to act as a catalyst. It has been shown experimentally that young animals are more susceptible than adults to nutritional cataract formation. It appears likely that the cataracts in dysplasia epiphysialis punctata are produced by an enzyme deficiency which may be congenital. The poor development of the ciliary processes in the case described above may support this latter theory.

Any hypothesis advanced to explain the formation of these cataracts must also explain the other lesions of the syndrome which are largely lesions of cartilage.

Hyaline cartilage has a high mucopolysaccharide content (chondroitin sulphate) and it is without a blood supply; like the lens it has to obtain its nutritional requirements from the surrounding body fluids. Its metabolic processes are therefore somewhat similar to those of the lens and it is probable that in dysplasia epiphysialis punctata both the formation of abnormal lens fibres causing cataracts and the abnormality of the epiphyseal cartilage are due to a common nutritional disorder such as an enzyme deficiency.

Summary

A case is reported of dysplasia epiphysialis punctata with cataract formation. The histological structure of the cataract is described and a possible aetiology of the condition is discussed.

The author wishes to thank Prof. Ida Mann and Mrs. Antoinette Pirie for their generous help with this paper, and also Dr. K. Campbell for the clinical notes and specimen.

References

- CONRADI, E. (1914) *Jb. Kinderheilk.*, **80**, 86
FAIRBANK, H. A. T. (1927) *Brit. J. Surg.*, **15**, 120
LANGHANS, T. (1893) *Quoted by* Haynes, E. R., and Wangner, W. F. (1951) *Radiology*, **57**, 547
PAUL, L. W. (1954) *Amer. J. Roentgenol.*, **71**, 941
YAKOVAC, W. C. (1954) *Arch. Path.*, **57**, 62