

Extruded collagen ophthalmic sutures

A clinical survey

A. SMITH

Sunderland Eye Infirmary

During the last decade ophthalmic surgeons have shown increasing interest in absorbable sutures, though a large body of opinion still favours silk and synthetic fibres. Hitherto, prejudice against catgut centred in the uncertainty of tissue reaction, wound healing, and absorption, and physical defects such as brittleness and unsuitable needles.

The change of outlook follows improved manufacturing processes resulting in stronger and finer catgut and needles more suitable for ophthalmic work. A substitute for catgut, Plain and Chromic Extruded Collagen*, has been made from the flexor tendons of cattle. These are digested and dispersed in an acid medium and homogenized. The collagen dispersion is then extruded to form a tape and multiple tapes are converted into round uniform strands of specified thickness and length and the needles are swaged on. The sutures are sealed in aluminium foil packets and sterilized by electron beam irradiation.

My 5 years' personal experience with catgut in cataract extractions has given convincing proof of the value of absorbable sutures in ophthalmic surgery. This paper reviews 151 cataract extractions and 155 squint operations in which, with the co-operation of the manufacturers, Extruded Collagen only was used in order to assess from a clinical point of view its physical and biological properties.

(1) In the first series only Plain Collagen was used, the sutures being 4/0 Plain double-armed Collagen with G3 cutting micro-point needle and 6/0 Plain double-armed Collagen with G6 cutting micro-point needle. The 4/0 Collagen was used only for sclero-muscular attachments in squint operations, and the 6/0 for corneo-scleral and conjunctival suturing. In the last ten cases of squint in this series 6/0 Collagen was used also for sclero-muscular suturing.

(2) In the second series only Chromic Collagen was used, namely, 6/0 Chromic double-armed Collagen with a G6 cutting micro-point needle in all cases throughout the series.

Surgical technique

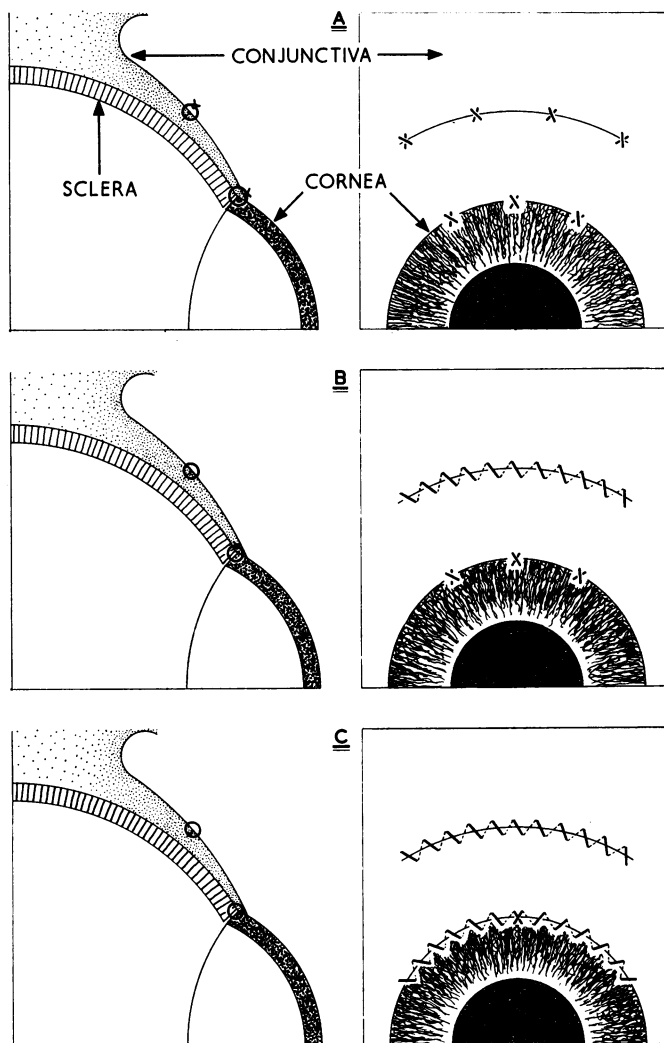
(1) LENS EXTRACTION

Local anaesthesia was given in all cases. Cataract knife section incorporating a broad conjunctival flap was followed by peripheral iridectomy. Three pre-placed corneo-scleral sutures were inserted and the lens was removed with capsule forceps, erisophake, or cryoprobe. Zonulysin was not used. The wound was closed in three ways with 6/0 Collagen:

(a) Three interrupted corneo-scleral sutures were tied on the conjunctival surface, with the knots and cut ends exposed (Diagram A). This method was discontinued after the first six cases in the first series.

(b) The corneo-scleral sutures were placed subconjunctivally and the ends cut short. This was done in 44 cases of the first series and in all those in the second series (Diagram B).

(c) A double-armed corneo-scleral suture was inserted at 12 o'clock and tied beneath the conjunctiva, and the nasal and temporal extremities were used for continuous corneo-scleral suturing along their respective sections (Diagram C). This was done in twelve cases of the first series.



The conjunctiva was closed with a running suture in all cases after the first five, in which interrupted sutures were used.

(2) SQUINT OPERATIONS

General anaesthesia was given in all cases. In *recession* operations a Collagen Suture was placed at the upper and at the lower musculo-tendon extremity and a cinch suture tied with a single knot before section and suturing at the new insertion. In *resection* operations the suture was similarly placed in the upper and lower borders of the muscle at the appropriate distance from the insertion before section, and re-suturing was done at the original insertion. The running conjunctival suture was tied at each end, so completing the procedure, sealing off the operation area.

Physical properties

SUTURE MATERIALS

Both Plain and Chromic Collagen had satisfactory pliability and tensile strength only when moist. Unless the Collagen was thoroughly soaked it quickly became wiry and brittle as the moisture evaporated through use. Chromic Collagen retained moisture longer and in consequence its pliability and strength lasted longer. Therefore, long loops and loose ends of the pre-placed sutures were moistened frequently along their length throughout operation.

Smooth passage through the sclera and cornea was facilitated by the fact that the Collagen did not fray as catgut often does, and also by the uniformity of its gauge. Unlike catgut, the material did not stretch and the knots held firmly, allowing the free ends to be cut very short. This reduced the bulk of the suture beneath the conjunctiva, especially with the 4/0 suture. The 6/0 suture knots were very small and unobtrusive.

The Chromic Collagen seemed more pliable and the exposed cut ends caused less mechanical irritation than those of Plain Collagen. The main reason for using running conjunctival sutures and subconjunctival corneo-scleral sutures was to reduce this discomfort.

The 6/0 suture was at first thought to be too fine for squint surgery, but it proved to be very suitable for sclero-muscular sutures, provided it was kept well moistened throughout the operation and not exposed to sudden uneven tension when tying knots.

NEEDLES

The G6 needle with the cutting micro-point was ideally suited for corneo-scleral work—its sharp point with cutting edge and its suitable size and curvature allowed smooth passage of the needle with minimum trauma. Care had to be taken, however, to avoid tilting the needle while passing through sclera, as this might have caused the encroaching edge to cut through. I found the slightly larger G3 needle with the 4/0 suture very satisfactory. Numerous types of needle holder were tried, but the problem of the swivelling of the needle was never satisfactorily resolved.

Biological properties

CATARACT EXTRACTION. SERIES I

This comprised sixty intracapsular cataract extractions in which 6/0 Plain Collagen only was used.

Tissue reaction

(1) *Conjunctival suture*

(a) The interrupted sutures were surrounded by a small localized patch of oedema lasting 2 to 5 days and associated with conjunctival congestion which took 3 to 4 days longer to subside. This effect was accentuated by irritation from the projecting cut ends of the sutures, which caused pain and lacrimation during the first 24 to 36 hours. For this reason the use of interrupted conjunctival sutures was discontinued.

(b) A running conjunctival suture was used in all subsequent cases. Slight oedema and congestion appeared at the overlaps, especially when it was drawn tight, by the 2nd day, but this rapidly subsided. There was no discomfort.

(2) *Corneo-scleral suture*

(a) The exposed interrupted suture tied on the conjunctival surface caused discomfort and increased injection of the eyeball and lids from mechanical irritation of the knots during the first 2 days. Therefore, after the first six cases, all sutures were placed subconjunctivally.

(b) The subconjunctival sutures caused only slight reaction with no oedema, except in two cases in which erosion occurred.

(c) The continuous corneo-scleral subconjunctival suture produced slight local oedema and congestion which subsided in 7 to 10 days. Vascular proliferation and congestion in and around the corneo-scleral section was never excessive; it reached its maximum intensity by the 5th day and in many cases faded rapidly by the 8th to 9th day.

Wound healing

This was firm and was not delayed except in three cases in which the sutures were slack allowing slight gaping between them. The continuous corneo-scleral suture was followed by speedy and firm union especially if tied at each extremity to prevent slackening. In this series no iris prolapse occurred.

Period of absorption

The running *conjunctival suture* absorbed evenly within 7 to 12 days; the interrupted single sutures took longer, up to 21 days in some cases, especially if the ends were long.

The exposed interrupted *corneo-scleral sutures* absorbed slowly in 4 to 6 weeks, but when they were placed subconjunctivally absorption was speeded up to a period of 2 to 3 weeks depending on the size of the knot and the length of the cut ends. Erosion occurred in two cases, increasing the absorption time by 7 to 10 days.

Complications

There were no complications that could be directly attributable to the Collagen. There were three cases of residual hyphaema following haemorrhage into the anterior chamber during the operation but no postoperative hyphaemata. Striate keratitis along the edge of the corneal section occurred in two cases.

CATARACT EXTRACTION. SERIES 2

This comprised 91 cataract extractions in which 6/0 Chromic Collagen only was used.

Tissue reaction

Chromic Collagen differed slightly from Plain Collagen, chiefly in the remarkably low degree of reaction and the more rapid absorption of the conjunctival sutures.

Initial reaction was minimal at 48 hours, when the first dressing was done. There was no oedema around the sutures; this was in marked contrast to the Plain Collagen.

Later superficial and deep conjunctival congestion increased until the 5th day and then rapidly subsided. The subconjunctival corneo-scleral knots projected slightly beneath the conjunctiva, but deep local reaction around them was slight. By the 9th to the 12th day the eyes were quiet; in many cases the eyes were white by the 6th day.

Erosion of the corneo-scleral knots occurred in four patients which delayed absorption by 1 to 2 weeks. This was not accompanied by increased local inflammation or by a weakened corneo-scleral scar.

Wound healing

Close apposition of the corneo-scleral wound edge was occasionally defective midway between the three corneo-scleral sutures, especially if they were slack, and in three cases iris prolapse occurred at this site. Safe and firm union was obtained by a corneo-scleral bite of two-thirds depth at right angles to the sclera; oblique suturing caused distortion and defective union. An increased number of sutures would eliminate this defect and, in view of the low incidence of reaction, additional sutures are unlikely to increase discomfort. Throughout postoperative convalescence the patients complained of no discomfort other than slight soreness during the first 24 hours.

Period of absorption

This was much the same as with Plain Collagen though slightly shorter, namely 6 to 9 days for the conjunctival suture and slightly longer for the corneo-scleral subconjunctival sutures, namely 3 to 5 weeks depending on the size of the knots and cut ends.

Postoperative complications

There were three cases of striate keratitis and two of postoperative hyphaema. This may have been indirectly associated with the Collagen but is as likely to occur with other suture materials.

Postoperative visual results

These are not influenced directly by the choice of suture material, other factors being of greater significance, but firm accurate apposition of the corneo-scleral wound edges by subconjunctival sutures reduces the incidence of postoperative astigmatism. From a random selection of 55 cases in this series, the astigmatism is listed as follows:

+ 0.5 to + 1.5	15 cases
+ 2.0	16 cases
+ 2.5	12 cases
+ 3.0 to + 3.5	9 cases
+ 4.0	3 cases

SQUINT OPERATIONS. SERIES I

In this consecutive series of 100 cases, Plain Collagen only was used. 6/0 sutures with the G6 cutting micro-point needle were used for the conjunctiva and also for the sclero-muscular suturing in the last ten cases. 4/0 sutures were used for sclero-muscular suturing in the first ninety cases.

Reaction

This was slight, but oedema around the conjunctival sutures was evident at the first dressing. This subsided within 2 days and the accompanying conjunctival congestion subsided within a week. In six cases, however, severe and deep-seated oedema and congestion occurred over the site of one buried sclero-muscular suture. This was accompanied by pain on moving the eye and, in three patients, by pyrexia which responded rapidly to local steroids and systemic antibiotics. In two patients the deep localized reaction recurred at the same site after an interval of 6 to 8 weeks. Despite this reaction no granulomata were observed. In the ten cases in which 6/0 Collagen was used, the reaction was negligible.

SQUINT OPERATIONS. SERIES 2

In this series of 55 cases, 6/0 Chromic Collagen with the G6 needle was used for sclero-muscular as well as conjunctival suturing.

Reaction

No oedema was seen around the conjunctival sutures, and conjunctival congestion, though noticeable in the first 4 days, rapidly subsided, the eye becoming quiet by the 6th to 7th day. This reaction was severe in only two cases in which it was associated with deep sclero-muscular inflammation. This responded rapidly to local steroids and systemic antibiotics. The late appearance of a granuloma occurred in three cases. All patients were allowed home on the 1st or 2nd day after the operation.

Absorption

As in the first series, the conjunctival sutures absorbed in 7 to 9 days. It was not possible to assess the period of absorption of the sclero-muscular sutures. The absence of discomfort from the 2nd day in most cases suggests a negligible reaction at the suture site. Subsequent favourable orthoptic measurements confirmed my opinion that these 6/0 Collagen sutures hold the new insertion effectively and are very suitable for squint surgery.

Comments

Previous experience with catgut encouraged this survey, which demonstrated the suitability of absorbable collagen sutures in ophthalmic surgery. Absorbable sutures eliminate the unnecessary discomfort and risk of ocular trauma entailed in the removal of non-absorbable sutures and cause less reaction.

The advantages of the G6 needle in both corneo-scleral and sclero-muscular suturing was demonstrated in all cases—adequate fixation by a suitable needle holder is desirable.

The 6/0 Chromic Collagen has proved to be a satisfactory material in both corneo-scleral and sclero-muscular suturing, provided it is kept moist throughout the operation. Under these conditions it is very pliable and has greater tensile strength than ordinary catgut, and the knots hold firmly however short the cut ends may be.

The period of absorption is not too rapid; adequate union takes place during the post-operative period.

Absence of reaction ensured greater comfort and the patients were fit for discharge much earlier than hitherto—many of our cataract patients are now discharged on the 6th day, some even on the 5th. This applies also to squint patients who are discharged on the 1st or 2nd day after operation.

The use of multiple subconjunctival corneo-scleral sutures in cataract patients reduces postoperative astigmatism and has a favourable influence on postoperative visual acuity.