

Infection of the eye by tapeworm *Coenurus*

P. H. WILLIAMS AND A. C. TEMPLETON

From Kuluwa Hospital, Arua and Makerere University, Kampala, Uganda

The adult tapeworm of the *Multiceps* variety is quite a common parasite of the bowel of canine animals. In temperate climates it may be found in the domestic dog and the most common intermediate hosts are the sheep ('gid') and the rabbit. In Africa the natural cycle of the worm is not fully known, but it seems likely that the adult is found in such animals as the jackal and the intermediate host may be the porcupine or swamp rat (Nelson, Pester, and Rickman, 1965) or smaller rodents (Fain, 1956). Man has been infected by the *Coenurus* stage of this tapeworm in fifty cases (Templeton, 1968), in eight of which the eye was affected (Boase, 1956; Epstein, Procter, and Heinz, 1959; Raper and Dockeray, 1956; Templeton, 1968; Vanderick, Fain, Langi, and van Balen, 1964; and Wainwright, 1957). We here report five new cases of ocular disease caused by this parasite and review experience of this unusual problem.

Case reports

Brief details of our cases and those previously recorded are shown in the Table. The vitreous, the orbit, and the subconjunctival tissue have been involved, but localization in the eye is not certain.

Table *Details of thirteen recorded cases of Coenurus infection of the eye and orbit*

<i>Case</i>	<i>Age (yrs)</i>	<i>Sex</i>	<i>Site</i>	<i>History</i>	<i>Tribe</i>	<i>Country</i>
Present series 1	14	F	Anterior chamber	Few days	Lugbara	Uganda
2	1	M	Subconjunctival	6 mths	Kiga	Uganda
3	1	F	Subconjunctival	?	Toro	Uganda
4	Adult	M	Vitreous	3 yrs	Nkole	Uganda
5	35	M	Vitreous	Long time	Kiga	Uganda
Templeton (1968) (Case 14)	35	F	Vitreous	?	Lugbara	Uganda
(Case 12)	2	M	Subconjunctival	1 yr	Nyoro	Uganda
Boase (1956) (Case 2)	1	F	Subconjunctival	3 wks	Ruanda	Ruanda
(Case 1)	21	M	Vitreous	1 wk	Nkole	Uganda
Wainwright (1957)	51	M	Vitreous	3 mths	?	S. Africa
Epstein and others (1959)	3½	F	Vitreous	?	White	S. Africa
Raper and Dockeray (1956) (Case 3)	12	M	Rectus lateralis muscle	?	?	Kenya
Vanderick and others (1964)	6	F	Subconjunctival	?	Hutu	Ruanda

the anterior chamber appears to be unique to our Case 1 and for this reason further details are given below recorded.

An adolescent African girl of the Lugbara tribe presented with a history of pain in the eye for a few days.

Examination

There was injection of the globe for which antibiotic was instilled. The cornea, anterior chamber, pupil, and media were noted to be normal. She returned 9 days later with a pronounced ciliary flush and hypopyon. Despite the addition of atropine, her condition worsened and the lower half of the cornea became generally infiltrated. On the 17th day after she was first seen, a round foreign body was observed in the anterior chamber behind the infiltration and keratic precipitates. After a further 3 days its size had increased and careful observation with the corneal microscope showed peristalsis in the cyst-like body (Fig. 1).

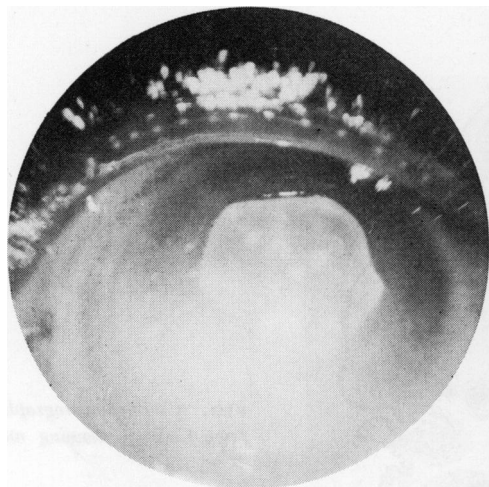


FIG. 1 Anterior chamber, showing *Coenurus* in situ (Case 1)

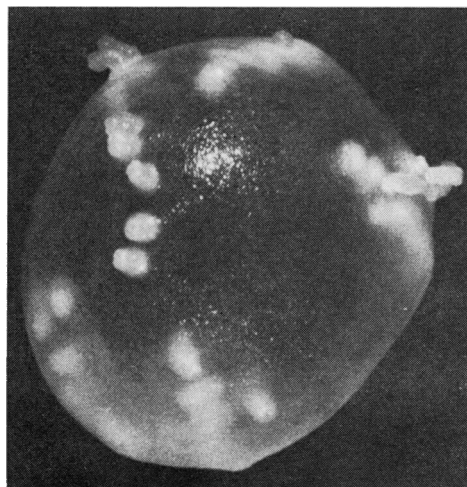


FIG. 2 *Coenurus* cyst from Case 2, showing scolices projecting from surface. $\times 12$ (Courtesy of Prof. Paul C. Beaver)

Treatment and Result

The cyst was removed intact by surgery. The eye healed slowly, and a year later showed vitreous bands extending to the corneal incision and cholesterol crystals in the posterior chamber.

The cyst measured 4 mm. in diameter and bore sixty developing scolices which appeared to be arranged in eight rows of three to ten scolices each row. They radiated from a pole of the *Coenurus* and were restricted to one hemisphere (Fig. 2, overleaf.) None of the scolices were developed sufficiently to bear suckers.

Discussion

Infection of man by *Coenurus* in temperate regions of the world usually results in central nervous system involvement in adult patients. Thus, of the eighteen cases reported from locations outside tropical countries, thirteen were located in the brain or spinal cord and usually affected adults. In tropical Africa 26 out of 32 recorded cases have presented with a subcutaneous *Coenurus*. Most of the patients with subcutaneous disease are children and the commonest site of involvement is the trunk. These striking differences argue that

the mode of infection and possibly the species of parasite is different in the two areas. Unfortunately little information is available on this subject in spite of various feeding experiments. Attempts have been made to classify the species on the basis of the arrangement of the scolices in the *Coenurus* but these are very unsatisfactory. Thus Brumpt (1936) delineated the species *M. serialis* largely on the basis of the linear arrangement of scolices in the *Coenurus*.

All five cases in which the cyst was located in the subconjunctival region occurred in children. All lived in the mountains which form the eastern wall of the Western Rift Valley at the border between Congo and Uganda. As such they show striking similarities to the Ugandan patients with subcutaneous disease who are often of a similar age and reside in the same part of the country. It is possible in view of the age of the patients that such cases result from inoculation of the larva directly into the conjunctiva or skin during early toddler life when the trunk and eyes are frequently close to the ground which may be contaminated. Removal of the cyst (Fig. 3) is seldom difficult and results in a complete cure.

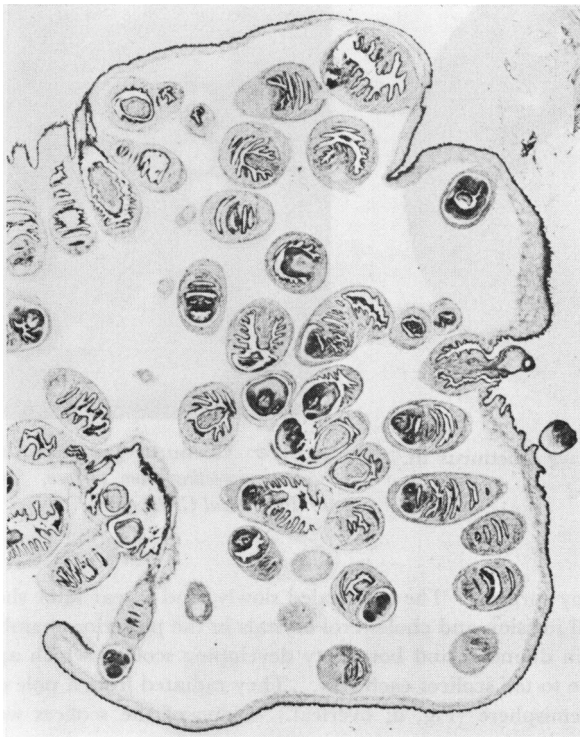

FIG. 3 Photomicrograph of *Coenurus* from Case 3, showing numerous scolices. $\times 35$

In all but one case (the only white patient recorded, a girl aged $3\frac{1}{2}$ years: Epstein and others, 1959), involvement of the interior of the eye occurred in older patients and as such more closely resembled the cases of central nervous system involvement seen in temperate climates. A more likely route of infection in such cases appears to be the mouth, with spread to involve the eye or central nervous system perhaps *via* the blood stream. In the early stages of infection the cyst provokes little or no reaction and if it is removed at this stage useful vision may be preserved. However, as the cyst matures, it excites an inflammatory reaction and the eye becomes painful, glaucomatous, and finally blind.

In the late stages of infection all that remain are the teeth and suckers of the scolices surrounded by inflammatory tissue in which calcium and even bone may be found. Infection of the eye by this parasite is almost certainly more common in Uganda than the paucity of reports would indicate. In the late stages of infection identification is impossible and many patients do not present at hospital until panophthalmitis is too far advanced to be certain of the mode of onset.

The exact identification of *Coenuri* is difficult and in fact the taxonomic position of the whole *Multiceps* family is under some dispute. Some favour generic status for this group whereas others regard it as a species within the genus *Taenia*. Whichever classification is eventually adopted, all the cases seen in Uganda conform to a type and most closely resemble the species named *brauni* (Setti). Fain (1956) and Nelson and others (1965) favoured this identification for the *Coenuri* which were found in animals in Ruanda and Kenya respectively. Cases involving the central nervous system have usually been diagnosed as *M. multiceps* and are frequently multilocular, whereas ocular cases are usually unioocular (except Boase, 1956, Case 1). *Coenurus cerebralis* is usually assumed to have been due to accidental involvement in the natural dog-to-sheep life cycle. In tropical Africa no case of involvement of the central nervous system has been recorded in humans and no well-documented infection in sheep has been found (Nelson and others, 1965). It thus seems that the cerebral and subcutaneous forms of infection are due to differences in the species and life cycle of the parasite. Ocular cases have been seen in both temperate and tropical Africa and it would be of great interest to compare the morphology of cases involving the vitreous in Uganda and South Africa to see if there are morphological differences in the *Coenuri* in the two areas.

Summary

Five new cases of ocular involvement by *Coenuri* of the *Multiceps* species are recorded. Subconjunctival infection is seen in young children and may be a result of direct inoculation with infected material. Involvement of the globe occurs in older people and is possibly due to spread from the bloodstream. In the early stages the *Coenurus* appears not to cause irritation and may be removed without gross damage to the eye. Later in its development reaction with fibrosis and blindness is the general rule.

Our thanks are due to Dr. Dale E. Wykoff of the Walter Reed Army Institute of Research, and Prof. Paul C. Beaver of Tulane University, who kindly confirmed our diagnoses in some of these cases and supplied two of the photographs.

References

- BOASE, A. J. (1956) *Brit. J. Ophthalm.*, **40**, 183
 BRUMPT, E. (1936) "Précis de parasitologie", 5th ed., vol. 1, p. 738. Masson, Paris
 EPSTEIN, E., PROCTOR, N. S. F., and HEINZ, H. J. (1959) *S. Afr. med. J.*, **33**, 602
 FAIN, A. (1956) *Ann. Soc. belge Méd. trop.*, **36**, 673
 NELSON, G. S., PESTER, F. R. N., and RICKMAN, R. (1965) *Trans. roy. Soc. trop. Med. Hyg.*, **59**, 507
 RAPER, A. B., and DOCKERAY, G. C. (1956) *Ann. trop. Med. Parasit.*, **50**, 121
 TEMPLETON, A. C. (1958) *Trans. roy. Soc. trop. Med. Hyg.*, **62**, 251
 VANDERICK, F., FAIN, A., LANGI, S., and VAN BALEN, (1964) *Ann. Soc. belge Méd. trop.*, **44**, 1077
 WAINWRIGHT, J. (1957) *J. Path. Bact.*, **73**, 347