

Diabetic retinopathy in the dog

K. C. BARNETT

From the Animal Health Trust Small Animals Centre, Lanwades Park, Kennett, Newmarket, Suffolk

SUMMARY The literature on diabetic retinopathy in the dog is reviewed. A case report, including the ophthalmoscopic appearance of typical diabetic retinopathy, in an 8½-year-old standard poodle known to be diabetic for over 7 years, is given. The relationship between the duration of diabetes and the retinopathy is discussed.

The first report of diabetic retinopathy in a dog was documented by Patz and Maumenee in 1962.¹ The subject was a 12-year-old male cocker spaniel with spontaneous diabetes mellitus of 2½ years' duration. Histological examination of flat sections revealed microaneurysms and exudates typical of those observed in human diabetic retinopathy, together with a generalised loss of mural cells and mural cell ghosts. This dog also had a nephropathy (diffuse glomerulosclerosis) and cortical cataracts.

This report was followed 2 years later by a case of retinopathy in a dog with diabetes induced by growth hormone.² The subject was a male fox terrier with metasomatotrophin-induced diabetes of 10 years' duration. The report relates only to specimens following fixation, there being a few small retinal haemorrhages at the posterior pole and in the mid periphery of both fundi. Microaneurysms were also found in digested flat preparations. There were no ophthalmoscopic pathological changes after 8 years of diabetes, but the development of cataract in the last 2 years prevented clinical examination of the fundus at the end.

Further experimental cases were recorded by Bloodworth and Molitor³ and Engerman and Bloodworth,⁴ who induced diabetes by bovine growth hormone and alloxan. Three dogs, diabetic for over 4 years, had a retinopathy in which the retinal lesions were milder than in man; microaneurysms were mostly thin-walled and haemorrhages and exudates small.

Sibay and Hausler⁵ described changes in the eye in 2 spontaneously diabetic and related dogs. The first, an 11-year-old terrier type male, treated for diabetes for over 2 years, showed several areas of dilatation of the retinal arterioles but no capillary micro-

aneurysms. A son of this dog, a 12-year-old castrated male part terrier, diabetic for 5 years, showed many aneurysms in the retinal vascular tree. Gepts and Toussaint⁶ in the same year also described minor vascular changes in spontaneous diabetes in the dog, revealed by trypsin digestion and flat-mounted specimens.

More recently Rubin⁷ has stated that the extent and seriousness of the ocular disease in dogs is extremely mild in comparison with its counterpart in man and that fundus changes are exceedingly difficult to demonstrate *in vivo*. A fundus photograph of a 12-year-old dachshund with two small and isolated aneurysms was published.

This report is believed to be the first to describe the ophthalmoscopic appearance of typical diabetic retinopathy in a dog and in addition would seem to be a much more severe case than any of those previously described.

Case history

The patient was a male white standard poodle, Roger, aged 8½ years. Diabetes mellitus had been diagnosed at 14 months of age, and the dog had been on daily insulin therapy since that time. No visual defect had been noticed by the owner. Diabetic retinopathy was discovered on routine ophthalmoscopic examination; previous eye examinations over several years had revealed no abnormality.

The retinopathy was bilateral, and the most severe changes were at the posterior pole, as was to be expected. Microaneurysms and larger haemorrhages were visible ophthalmoscopically, as were irregular variations in calibre of the veins and a venous loop (Figs. 1 and 2). Present also was an area of retinal degeneration, with increased tapetal

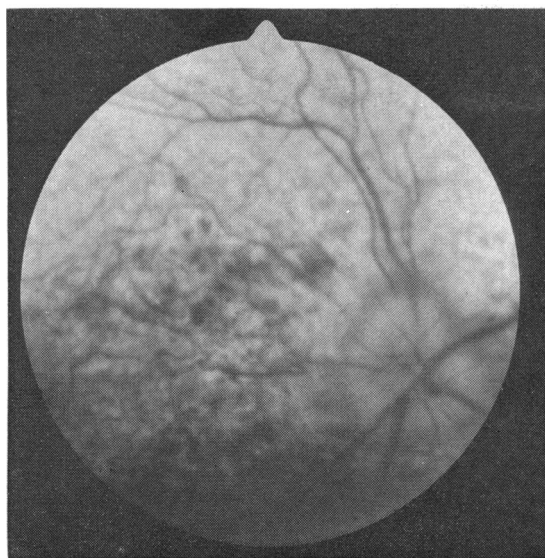


Fig. 1 Fundus of right eye.

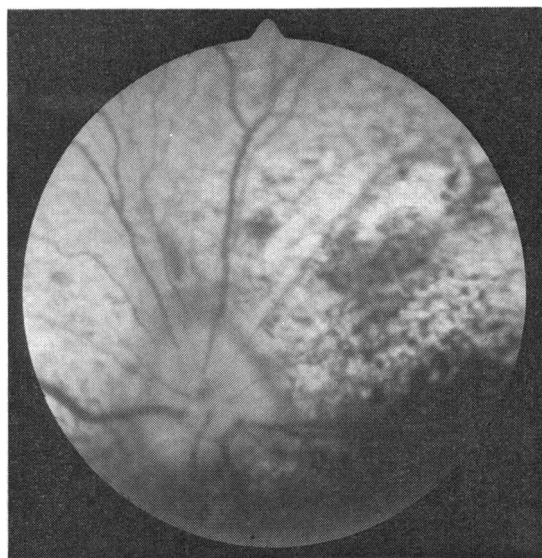


Fig. 2 Fundus of the left eye.

reflectivity, in the area centralis region. No exudates were visible. Twelve months later retinal haemorrhages were larger and more numerous, and there was evidence of vitreal degeneration. Vision remained unimpaired.

Discussion

Diabetes mellitus is a common disease in the dog, with an incidence estimated to be between 1:200 and 1:500.⁸ The highest age incidence is between 5 and 12 years, and it is commoner in bitches than male dogs. Survival times are poor, with a maximum life span quoted at 27 months after diagnosis⁸ and 4 years,⁹ and in a recent survey in Kent,¹⁰ although the longest survival was 7 years, the mean was only 1½ years. Diabetic cataract is very common, is said to be as high as 40%⁹ and 68%⁸ and is sometimes the presenting sign, being more obvious to the owner than increased thirst or loss of condition. Very little mention of retinal changes is to be found in the veterinary literature. Ettinger¹¹ states that haemorrhages and exudates have not been observed clinically, and Peiffer *et al.*¹² as recently as 1977 considered that the canine eye is spared the blindness associated with retinal neovascular and proliferative changes that occur in man.

In 1962 Bloodworth¹³ remarked that one of the major deterrents to understanding diabetic retinopathy was the failure of naturally diabetic animals to develop a diabetic retinopathy. There followed a few histological reports¹⁻⁶ showing that the classical

lesion of microaneurysm did occur in the dog in both natural and induced diabetes.

The case reported here again lends support to the relationship between the duration of diabetes and the incidence and severity of the retinopathy. It does not support the notion of a lessened susceptibility of the canine retinal capillaries to develop degenerative changes, which has been suggested.⁶

Although diabetes is common in the dog, it is usually a disease of age, and some owners are reluctant to give daily injections to their pets. Therefore very few animals are on insulin therapy for long periods, a fact which could explain the paucity of descriptions of diabetic retinopathy in this species. In the present case the diligent care of a remarkable owner controlled the disease, and probably the development of cataract also, but did not prevent the occurrence of a typical diabetic retinopathy.

References

- 1 Patz A, Maumenee AE. Studies on diabetic retinopathy 1. Retinopathy in a dog with spontaneous diabetes mellitus. *Am J Ophthalmol* 1962; **54**: 532-41.
- 2 Hausler HR, Sibay TM, Campbell J. Retinopathy in a dog following diabetes induced by growth hormone. *Diabetes* 1964; **13**: 122-6.
- 3 Bloodworth JMB, Molitor DL. Ultrastructural aspects of human and canine diabetic retinopathy. *Invest Ophthalmol Visual Sci* 1965; **4**: 1037-48.
- 4 Engerman RL, Bloodworth JMB. Experimental diabetic retinopathy in dogs. *Arch Ophthalmol* 1965; **73**: 205-10.
- 5 Sibay TM, Hausler HR. Eye findings in two sponta-

- neously diabetic related dogs. *Am J Ophthalmol* 1967; **63**: 289–94.
- 6 Gepts W, Toussaint D. Spontaneous diabetes in dogs and cats. *Diabetologia* 1967; **3**: 249–65.
 - 7 Rubin LF. *Atlas of Veterinary Ophthalmoscopy*. Philadelphia: Lea and Febiger, 1974: 138–40.
 - 8 Wilkinson JS. Spontaneous diabetes mellitus. *Vet Rec* 1960; **72**: 548–55.
 - 9 Lauder I. Canine diabetes mellitus. *The Veterinary Annual*. Bristol: Wright, 1972 152–60.
 - 10 Foster SJ. Diabetes mellitus—a study of the disease in the dog and cat in Kent. *J Small Animal Pract* 1975; **16**: 295–315.
 - 11 Ettinger SJ. *Textbook of Veterinary Internal Medicine*. Philadelphia: Saunders, 1975; **1**: 516.
 - 12 Peiffer RL, Gelatt KN, Gwin RM. Diabetic cataracts in the dog. *Canine Pract* 1977; **4**: 18–22.
 - 13 Bloodworth JMB. Diabetic retinopathy. *Diabetes* 1962; **11**: 1–22.