

Graves' ophthalmopathy: III. Effect of transantral orbital decompression on optic neuropathy

E SVERKER HALLIN,¹ STEVEN E FELDON,² AND JEFFREY LUTTRELL²

From the ¹Department of Ophthalmology, University of Göteborg, Sweden; and the ²Departments of Ophthalmology and Neurological Surgery, University of Southern California School of Medicine, Los Angeles, California, USA

SUMMARY Twenty-five patients (48 eyes) underwent transantral, surgical decompression of their orbits for treatment of Graves' ophthalmopathy with optic neuropathy. Visual acuity improved in 77%, remained unchanged in 17%, and worsened in 6%. Colour vision improved in 76%, remained unchanged in 20%, and worsened in 4%. Visual fields improved in 67%, remained unchanged in 12%, and worsened in 22%. In general the worse the vision preoperatively the greater the relative improvement postoperatively. Clinical and radiological findings failed to correlate with visual outcome of surgical intervention. The study shows surgery to be highly effective in restoring optic nerve function for patients with severe Graves' ophthalmopathy.

The optimal treatment of optic neuropathy associated with Graves' ophthalmopathy is controversial. Systemic corticosteroids,¹⁻⁴ high energy irradiation,⁵⁻⁸ and surgical decompression⁹⁻¹³ of the orbit have all been advocated. Although most authors have reported beneficial effects on visual acuity from surgical decompression, its effects on other aspects of visual function have not been emphasised. The purpose of this report is to quantitate the effect of transantral orbital decompression on the visual acuity, colour vision, and visual fields of 25 patients with Graves' dysthyroid optic neuropathy who failed to respond to high dose systemic corticosteroids.

Patients and methods

PATIENTS

Twenty-five patients who underwent surgical decompression of their orbits for treatment of optic neuropathy secondary to Graves' ophthalmopathy were evaluated in a retrospective manner. Of these, 21 patients underwent a single bilateral procedure, two underwent a single unilateral procedure, and two underwent a second bilateral procedure. Nineteen patients were women and six were men; the average age was 58.8 years, range 27 to 83 years. All the patients were examined preoperatively for visual

acuity by Snellen types, colour vision (AO pseudo-isochromatic plates), and visual fields (15 patients by Octopus automated perimeter). In addition all the patients had CT scans, all but four of which were evaluated quantitatively to determine the extent of extraocular muscle enlargement.¹⁴ Visual function tests were repeated at least once after surgery. Table 1 summarises the presenting features of each patient. The data were analysed by standard statistical techniques of correlation and linear regression. Visual fields were analysed by Octopus Program Delta. The average follow-up time was 18.5 months, ranging from a low of one to a high of 49 months.

SURGERY

Transantral orbital decompression was performed according to the technique described by Walsh and Ogura¹¹ and lateral orbital decompression by the technique described by Kroll and Casten.¹⁰ All patients received at least two weeks of high dose (80-100 mg/day) methylprednisolone (prednisone) prior to surgery; this was gradually tapered for one to three weeks after surgery. Transient or permanent infraorbital anaesthesia was present in the majority of patients. Diplopia, not present preoperatively, was apparent after surgery in 7 of 12 patients. No instances of orbital cellulitis, leak of cerebrospinal fluid, orbital haemorrhage, or catastrophic visual loss were encountered.

Correspondence to Steven Feldon, MD, Estelle Doheny Eye Foundation, 1355 San Pablo Street, Los Angeles, CA 90033, USA.

Table 1 Presenting features of 25 patients

Patient	Age	Sex	Eye	VA	CV	Field loss	APD	ON	Propt.	TA	Exp.	%Lim.	Strab.	% Muscle volume
1	66	F	R	20/800	0/15	20-1	+	1	22	20	-	59	25XT	15-6
			L	20/40	4/15	16-9	-	0	20	24	-	45		16-8
2	82	F	R	20/300	0/15	NA	+	4	22	24	+	63	Ortho	21-0
			L	*	*	*	*	*	*	*	*	*	*	*
3	39	F	R	20/50	8/15	NA	+	2	27	27	+	NA	10RHT	20-5
			L	20/30	4/15	NA	-	0	26	24	-	NA		18-2
4	53	F	R	20/40	11/15	21-6	-	0	22	28	-	41	10X(T)	12-6
			L	20/60	11/15	20-6	-	0	22	31	-	43		13-8
5	31	F	R	20/25	14/15	NA	-	0	25	23	+	71	Ortho	23-4
			L	20/25	12/15	NA	-	0	26	26	+	40		24-7
6	62	M	R	20/400	0/15	22-3	+	2	21	20	+	25	Ortho	23-0
			L	20/40	9/15	16-5	-	2	21	20	+	60		19-5
7	59	M	R	20/15	15/15	NA	-	2	25	21	-	100	Ortho	12-1
			L	20/25	15/15	9-5	+	4	23	30	-	55		18-1
8	56	M	R	20/40	13/15	0-4	+	3	29	16	-	57	14RHT	16-0
			L	20/30	15/15	0-0	-	3	27	17	-	64	8XT	14-2
9	61	F	R	20/80	9/15	12-5	+	0	26	20	-	66	NA	NA
			L	20/60	12/15	NA	-	0	26	12	-	66	35LHT	NA
10	42	F	R	20/40	11/15	4-9	-	0	26	30	-	86	Ortho	19-0
			L	20/30	11/15	7-3	+	0	27	32	-	69		19-0
11	63	F	R	20/20	10/15	9-7	-	4	22	19	-	93	Ortho	17-0
			L	20/70	10/15	18-9	+	0	22	19	-	93		18-6
12	63	F	R	20/30	8/15	NA	-	2	26	15	-	45	11E(T)	17-4
			L	20/30	7/15	NA	+	2	27	16	-	45		16-4
13	83	F	R	20/200	10/15	NA	-	0	19	20	+	22	Diplopia	NA
			L	20/70	8/15	NA	-	0	19	18	+	29	NA	NA
14	59	M	R	20/80	11/15	NA	-	0	9	24	-	35	Diplopia	11-9
			L	20/40	11/15	NA	-	1	7	25	-	41		14-0
15	51	F	R	20/20	12/15	0-0	-	3	25	20	-	43	sm.XT	NA
			L	20/30	10/15	0-0	-	3	23	18	-	53	NA	NA
16	75	F	R	20/200	0/15	NA	+	4	21	20	+	50	35ET	NA
			L	20/60	0/15	NA	-	0	19	20	+	43	NA	NA
17	78	F	R	20/200	NA	19-9	-	3	28	19	+	38	Ortho	21-6
			L	20/400	NA	14-6	-	4	27	22	+	40		21-5
18	29	F	R	20/200	11/15	16-8	+	3	22	26	+	31	Ortho	13-2
			L	20/20	15/15	5-2	-	2	22	26	+	31		11-5
19	49	F	R	20/25	11/15	2-5	-	2	23	14	-	19	Ortho	14-5
			L	30/15	12/15	4-4	-	2	23	15	-	19		12-4
20	72	F	R	20/60	10/15	2-1	-	3	24	17	NA	33	Ortho	19-0
			L	20/60	10/15	2-3	+	0	26	17	NA	35		20-6
21	27	M	R	20/30	14/15	1-5	-	0	31	25	+	60	RHT	17-8
			L	20/50	13/15	3-0	-	0	30	20	+	60	10ET	15-2
22	74	F	R	10/100	2/15	NA	-	2	18	60	+	43	Diplopia	26-0
			L	20/200	2/15	NA	+	4	14	14	+	43		26-9
23	67	F	R	20/100	8/15	5-3	+	0	23	14	+	30	RHT	13-8
			L	*	*	*	*	*	*	*	*	*	*	*
24	74	M	R	20/30	10/15	NA	-	2	24	18	-	70	4RHT	14-5
			L	20/20	10/15	NA	-	2	27	20	-	48		12-7
25	54	F	R	20/25	10/15	NA	-	2	26	15	+	15	4RHT	10-7
			L	20/25	13/15	NA	-	2	25	15	-	38		9-0

VA=visual acuity. CV=colour vision. Field loss=mean decibel whole field loss. APD=afferent pupillary defect. ON=optic nerve status (0=no neuropathy, 1=hyperaemia, 2=swollen, 3=partial atrophy, 4=atrophy). Propt.=proptosis. TA=tension applanation. Exp.=exposure. %Lim=total percentage muscle limitation. Strab.=Strabismus present.

XT=exotropia. Ortho=orthotropia. RHT=right hypertropia. LHT=left hypertropia. E(T)=intermittent esotropia. ET=esotropia. NA=not available. *=Surgery not performed on that eye.

Results

DIFFERENCES IN VISUAL FUNCTION FOLLOWING SURGERY

Of the 48 eyes that had surgery 37 (77%) had

improvement in visual acuity postoperatively, eight (17%) showed no improvement (five of which had a preoperative visual acuity of 20/20 or better), and three (6%) worsened. Of the 25 eyes tested for colour vision pre- and postoperatively the colour vision

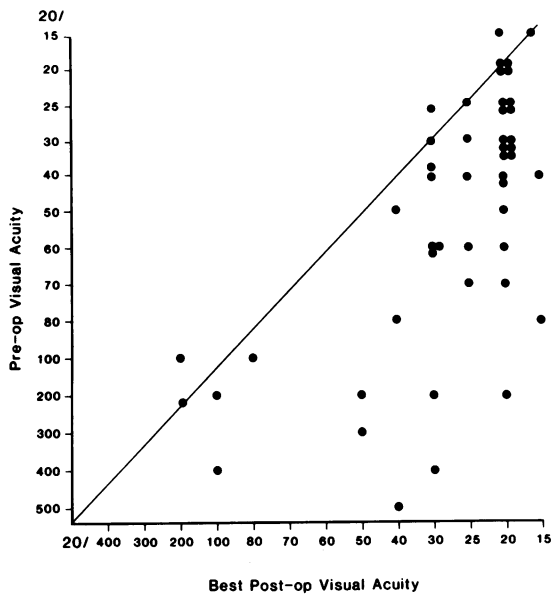


Fig. 1 Scatterplot comparing pre- and postoperative Snellen visual acuity results ($t = -7.02$, $p < 0.001$). For this and all succeeding scatterplots the solid line represents 'no change'; points above the line denote a decrease, while points below denote an improvement.

improved in 19 (76%), remained unchanged in five (20%) (two of which had a preoperative colour vision of 15/15), and deteriorated in one (4%). Of the eyes evaluated by Octopus automated perimetry there was quantitative improvement in 18 (67%), no change in three (12%) (all of which showed no preoperative loss), and an increased loss in six (22%).

A quantitative analysis of visual parameters was

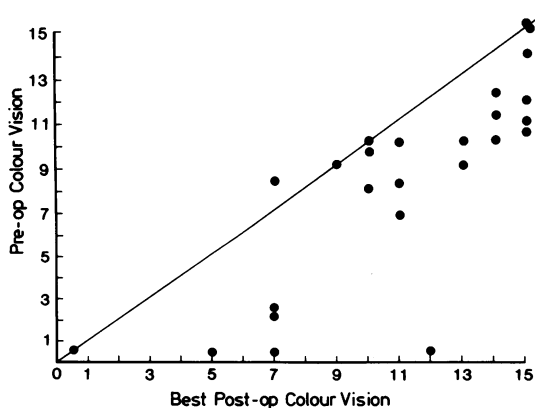


Fig. 2 Scatterplot comparing pre- and postoperative pseudoisochromatic colour vision results ($t = -5.33$, $p < 0.001$).

performed to determine the amount of change between the preoperative and postoperative assessment. Fig. 1 compares the pre- and postoperative visual acuity by Snellen types for each patient. Fig. 2 compares the pre- and postoperative results of pseudoisochromatic testing of colour vision. In general, patients with higher degrees of visual loss preoperatively had greater improvement after surgery. This tendency was statistically significant, with correlations between preoperative visual acuity and postoperative change being -0.54 ($p < 0.001$), between preoperative colour vision and postoperative change being -0.74 ($p < 0.001$), between preoperative central 10° visual fields and postoperative change being -0.72 ($p < 0.001$), and between preoperative whole visual fields and postoperative change being -0.60 ($p < 0.001$).

ASSOCIATION OF NON-VISUAL AND VISUAL PARAMETERS WITH POSTOPERATIVE VISUAL IMPROVEMENT

Proptosis, limitation of extraocular motility, and extraocular muscle size on CT scan were evaluated as possible predictors of visual outcome following orbital decompression. However, correlations were nearly zero in each instance.

QUANTITATIVE ASSESSMENT OF VISUAL FIELDS

The type of visual field loss encountered preoperatively was studied by means of analysis by quadrants, whole 30° fields, and central 10° fields. The frequency of encountering visual loss of various degrees in these portions of the field are shown in Fig. 3. The frequency of improvement in visual fields postoperatively for each portion of the field is shown in Fig. 4. A significant correlation was found for postoperative improvement with preoperative severity for the whole field, the lower temporal, the lower nasal, and the central 10° of field. These correlations are summarised in Table 2.

Discussion

Quantitative analysis of several parameters of visual function in patients undergoing orbital decompression for Graves' ophthalmopathy with optic neuropathy suggests that surgery is highly effective in restoring all manifestations of optic nerve function—acuity, visual fields, and colour vision. This improvement is especially remarkable in this series of patients because the criterion for surgical decompression was either failure to improve on or drug intolerance to corticosteroids. Morbidity of the procedure was acceptable, with the major complications being diplopia and infraorbital numbness, as has also been reported by others.^{11 15}

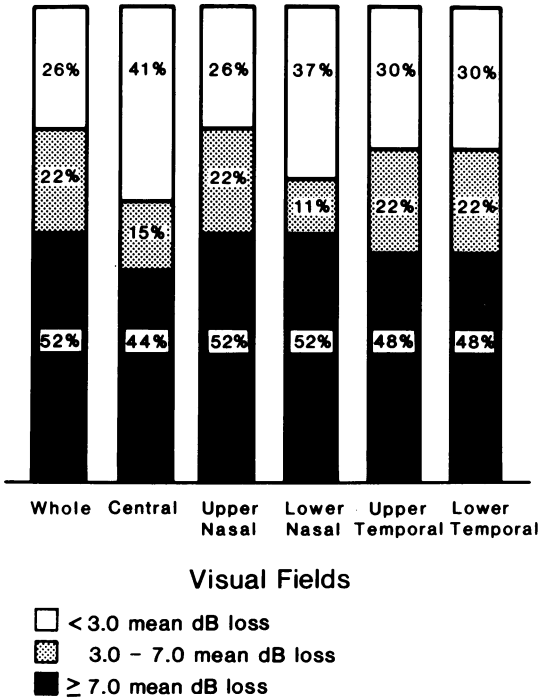


Fig. 3 Bar diagram demonstrating the frequency of preoperative visual field loss: 27 eyes.

Other than the finding first noted by Ogura *et al.*,¹⁶ that patients with more severe visual dysfunction are more likely to show postoperative improvement, no other parameter of disease, such as preoperative proptosis, motility limitation, or even extraocular muscle enlargement by CT scan seems to aid in predicting which patients are likely to benefit substantially from surgery.

Similar studies to compare quantitatively the results of orbital decompression with other types of treatment for optic neuropathy in Graves' ophthalmopathy are needed. These additional studies should improve the treatment of this vision-threatening disease.

Table 2 Correlations between preoperative visual field mean decibel loss and postoperative improvement

Visual field	r	p
Central	-0.72	<0.001
Lower temporal	-0.66	<0.001
Lower nasal	-0.63	<0.001
Whole	-0.60	<0.001
Upper temporal	-0.44	<0.05
Upper nasal	-0.37	NS

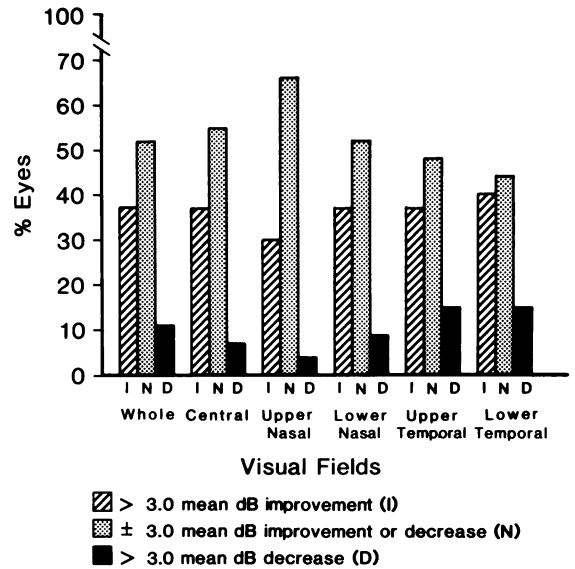


Fig. 4 Bar diagram demonstrating the frequency of postoperative visual field improvement. I=improvement, N=no change, D=decrease.

This study was supported in part by Handlande Herman Svenssons Fund, De Blindas Vanner, and by grant No. EY03908 awarded by the National Institutes of Health (USA).

References

- Brain R, Aterman K, Cope CL. Cortisone in exophthalmos. Report on a therapeutic trial of cortisone and corticotrophin (ACTH) in exophthalmos and exophthalmic ophthalmoplegia by a panel appointed by the Medical Research Council. *Lancet* 1955; **i**: 6-9.
- Brown J, Coburn JW, Wigod RA, Hiss JM Jr, Dowling JT. Adrenal steroid therapy of severe infiltrative ophthalmopathy of Graves' disease. *Am J Med* 1963; **34**: 786-95.
- Day RM, Carroll FD. Corticosteroids in the treatment of optic nerve involvement associated with thyroid dysfunction. *Arch Ophthalmol* 1968; **79**: 279-82.
- Mulherin JL Jr, Temple TE Jr, Cundey DW. Glucocorticoid treatment of progressive infiltrative ophthalmopathy. *South Med J* 1972; **65**: 77-80.
- Donaldson SS, Bagshaw MA, Kriss JP. Supervoltage orbital radiotherapy for Graves' ophthalmopathy. *J Clin Endocrinol Metab* 1973; **37**: 276-85.
- Ravin JG, Sisson JC, Knapp WT. Orbital radiation for the ocular changes of Graves' disease. *Am J Ophthalmol* 1975; **79**: 285-8.
- Covington EE, Lobes L, Sudarsanam A. Radiation therapy for exophthalmos: report of seven cases. *Radiology* 1977; **122**: 797-9.
- Hurbli T, Char DH, Harris J, Weaver K, Greenspan F, Sheline G. Radiation therapy for thyroid eye diseases. *Am J Ophthalmol* 1985; **99**: 633-7.
- Long JC, Ellis GD. Temporal decompression of the orbit for thyroid exophthalmos. *Am J Ophthalmol* 1966; **62**: 1089-98.
- Kroll AJ, Casten VG. Dysthyroid exophthalmos: palliation by lateral orbital decompression. *Arch Ophthalmol* 1966; **76**: 205-10.
- Walsh TE, Ogura JH. Transantral orbital decompression for malignant exophthalmos. *Laryngoscope* 1957; **67**: 544-68.

- 12 Leone CR Jr, Bajandas FJ. Inferior orbital decompression for thyroid ophthalmopathy. *Arch Ophthalmol* 1980; **98**: 890-2.
- 13 McCord CD Jr. Orbital decompression for Graves' disease: exposure through lateral canthal and inferior fornix incision. *Ophthalmology* 1981; **88**: 533-41.
- 14 Feldon SE, Lee CP, Muramatsu SK, Weiner JM. Quantitative computed tomography of Graves' ophthalmopathy: extraocular muscle and orbital fat in development of optic neuropathy. *Arch Ophthalmol* 1985; **103**: 213-5.
- 15 Shorr N, Neuhaus RW, Baylis HI. Ocular motility problems after orbital decompression for dysthyroid ophthalmopathy. *Ophthalmology* 1982; **89**: 323-8.
- 16 Ogura J, Wessler S, Avioli LV. Surgical approach to the ophthalmopathy of Graves' disease. *JAMA* 1971; **216**: 1627-31.

Accepted for publication 2 July 1987.