

Yellow forelock – a new neuro-ophthalmological sign

R I Kellen, B Schrank, R M Burde

Abstract

We examined a middle-aged man with a prominent yellow forelock who complained of loss of vision in both eyes. He smoked his pipe avidly and drank a little Bourbon whisky daily. The nicotine content of the forelock (21.7 ng/mg) was 10 times that of the hair on his occiput (2.23 ng/mg). A yellow forelock when associated with isolated painless visual loss suggests tobacco amblyopia.

For the diagnosis of tobacco-alcohol amblyopia Traquair required a history of smoking tobacco, visual loss in both eyes, centrocaecal scotomas with sloping edges containing one or more nuclei, and no changes in the peripheral field.¹

We report the case of a late middle-aged man who smoked a pipe heavily most of his life, had visual loss in both eyes, and had a yellow forelock. We believe he represents a case of tobacco-alcohol amblyopia occurring in the United States of America.

Case report

A 63-year-old white man, a retired auditing clerk, complained of progressive painless loss of vision in both eyes for two months before we saw him. He had no other neurological complaints, and he denied weight loss. Past ocular history and family history were unremarkable. He smoked a pipe, consuming about 10 oz (280 g) of pipe tobacco per week for more than 15 years. Although he drank 1-2 'shots' (25-50 ml) of Bourbon whisky per day, he denied exposure to home-brewed alcohol, drugs, or industrial toxins. He lived alone and denied any food faddism. He was thin, looking older than his years; his gray hair had a prominent yellow forelock (Fig 1). He weighed 46.8 kg and was

167.6 cm tall (72% of ideal body weight). His best-corrected visual acuity was 'finger counting' as 4 feet (1.2 m) in both eyes. He identified only the control plate of the Ishihara pseudoisochromatic test. Both pupils reacted sluggishly to light (from 5 mm to 4 mm) without a relative afferent pupillary defect. The near reflex produced a final miosis of 2.5 mm in both eyes. Kinetic visual fields showed bilateral caecocentral scotomas (Fig 2). Both optic discs were pale temporally, and in the papillomacular bundle the nerve fibre layer was thin. The rest of the findings on ophthalmic examination were unremarkable.

We found mild bilateral sensorineural hearing loss, but his deep tendon reflexes were normal, toe responses were flexor, and there were no signs of cerebellar dysfunction. His mental status was normal.

Laboratory studies included a normal haematocrit (41.7%) with a mean corpuscular volume of 113.5 fl (normal range 80-97.6). The smear showed <5% hypersegmented polymorphonuclear white blood cells. The vitamin B-12 level was 129 pmol/l (normal >140 pmol/l). Parietal cell antibodies were positive, with a low titre of 1:40. There were no intrinsic factor antibodies, and serum and red cell folate levels were normal. Blood urea nitrogen (BUN) was 2.1 mmol/l (3.7-7.0), albumin 42 g/l (35-48), and uric acid 210 µmol/l (240-540). Serum iron was 17.2 µmol/l (11-30), and the total iron binding capacity was 37 µmol/l (45-72). Transketolase assay and the lead level were normal. We could not assess the results of the Schilling test because the patient did not collect complete urine samples. He refused any determination of gastric pH. We could not find evidence of syphilis (VDRL, TPHA, and FTA-Abs tests were negative). He refused lumbar puncture or neuroimaging.

The nicotine content of his yellow forelock was 21.7 ng/mg but that of the hair from the back of his head was 2.23 ng/mg.

We diagnosed optic neuropathy due to tobacco abuse and treated him with 1000 µg/week of parenteral hydroxycobalamin and gave him oral multivitamins, including 100 mg of thiamine and 1 mg of folate daily. Over the next three months his vision did not improve. He still smoked his pipe but said that he had 'cut it down'.

We concede that given the available data (no cerebrospinal fluid examination or neuroimaging) we cannot prove unequivocally that this man had tobacco amblyopia. Nevertheless the clinical picture is suggestive and conforms to other descriptions.¹⁻⁵ We describe a physical sign not recorded before which indicates an addiction to tobacco: the yellow forelock. It reminds us of the white forelock seen in Waardenburg's syndrome.⁶

Washington University
School of Medicine, St
Louis, Missouri, USA,
Department of
Ophthalmology
R I Kellen
R M Burde

Department of Neurology
B Schrank
R M Burde

Department of
Neurological Surgery
R M Burde

Correspondence to:
Ronald M Burde, MD,
Department of
Ophthalmology, Albert
Einstein College of
Medicine/Montefiore
Medical Center, 111 East
210th Street, Bronx, NY
10467, USA.

Accepted for publication
9 January 1990

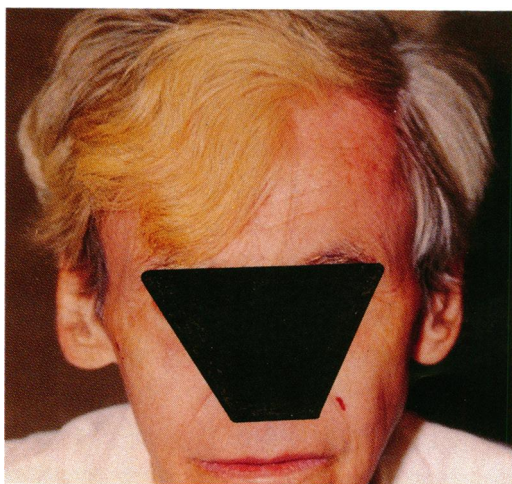


Figure 1: The patient is a 63-year-old white man with gray hair and a prominent yellow forelock.

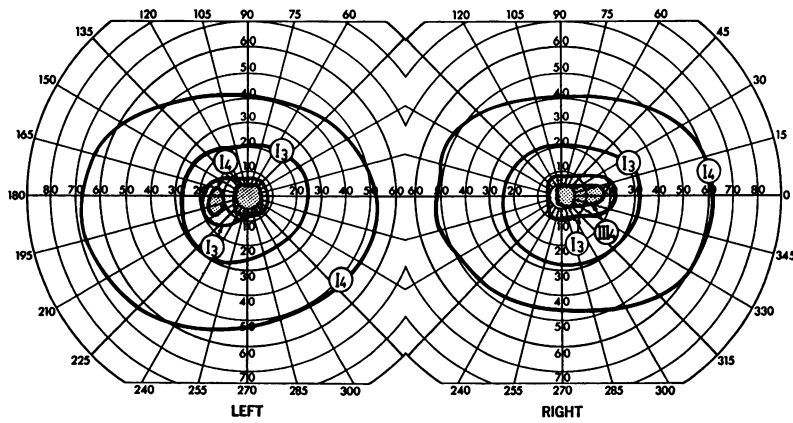


Figure 2: Kinetic visual fields showing bilateral caecocentral scotomas.

This work was supported in part by an unrestricted grant from Research to Prevent Blindness, Inc., New York, New York (Department of Ophthalmology).

- 1 Traquair HM. Toxic amblyopia, including retrobulbar neuritis. *Trans Ophthalmol Soc UK* 1930; 50: 351-95.
- 2 Wokes F. Tobacco amblyopia. *Lancet* 1958; ii: 526-7.
- 3 Foulds WS, Chisholm IA, Bronte-Stewart J, Reid HCR. The investigation and therapy of the toxic amblyopias. *Trans Ophthalmol Soc UK* 1970; 90: 739-63.
- 4 Potts AM. Tobacco amblyopia. *Surv Ophthalmol* 1973; 17: 313-39.
- 5 Foulds WS, Pettigrew AR. Tobacco-alcohol amblyopia. In: Brockhurst RJ, Boruchoff SA, Hutchinson BT, Lessell S eds. *Controversies in ophthalmology*. Philadelphia; Saunders, 1977: 851-65.
- 6 Waardenburg RJ. A new syndrome combining developmental anomalies of the eyelids, eyebrows and nose root with pigmentary defects of the iris and head hair and with congenital deafness. *Am J Hum Genet* 1951; 3: 195-253.