

# Correlation of peripheral displacement thresholds and optic disc parameters in ocular hypertension

Simon Ruben, Fred Fitzke

## Abstract

Both peripheral displacement thresholds and measurement of optic disc parameters have been advocated in the early diagnosis of glaucoma at the stage before scotomata are detected on conventional visual field assessment. The peripheral movement displacement thresholds were measured in 50 eyes of 50 patients with ocular hypertension and a significant correlation was found with neuroretinal rim areas measured using a computerised image system. There was also a significant correlation with optic disc diameter but no correlation with cup-disc ratio. The results support the proposition that measurement of peripheral movement displacement thresholds may be a useful tool in the detection of early glaucomatous optic nerve damage.

(*Br J Ophthalmol* 1994; 78: 291-294)

The use of newer psychophysical tests of visual function as tools for detecting early glaucomatous visual loss are currently receiving increasing interest. These tests include measurements of peripheral and central colour contrast sensitivity,<sup>1,2</sup> colour vision,<sup>3</sup> and flicker sensitivity.<sup>4</sup> In a previous publication,<sup>5</sup> peripheral movement displacement thresholds (MDT) were shown to discriminate between glaucomatous and normal eyes, and it was suggested that decreased sensitivity of motion detection may predict early ganglion cell damage in patients with ocular hypertension but with normal automated fields. This may relate to the early selective loss of large ganglion cells which has been shown to occur in glaucoma.<sup>6</sup> MDT may therefore become a sensitive and selective measure for detecting early glaucomatous visual loss, since it is well known that significant

ganglion cell numbers are lost before conventional field tests become abnormal.<sup>7,8</sup>

Another area which has gained considerable interest in recent years is optic disc morphology in relation to glaucoma and ocular hypertension. As with the newer psychophysical techniques, it has been shown that changes in certain optic disc parameters, in particular neuroretinal rim area, may precede visual field defects.<sup>9-12</sup> More recently, the measurement of optic disc morphology is becoming a more realistic method of longitudinal follow up, with the introduction of the scanning laser ophthalmoscope which gives fast and accurate analysis of optic nerve morphology without the need for mydriasis.<sup>13</sup>

If MDT results are related to ganglion cell function we might expect there to be a relation between the anatomical appearance of the optic nerve and its physiological function. In this study we used conventional optic disc photography together with computerised analysis of two dimensional disc morphology in a cohort of patients with ocular hypertension in order to assess the relation between optic disc parameters and what is believed to be a functional test of ganglion cell activity, the MDT.

## Materials and methods

Fifty patients with ocular hypertension having a mean age 61 years were studied. The results from only one eye of each patient were used for subsequent analysis. All patients had intraocular pressure (IOP) greater than 23 mm Hg with a mean of 26.9 (SD 1.8) (Fig 1). Intraocular pressures were measured by Goldmann applanation tonometry and the average of the three most recent clinic visits recorded. No patient was receiving pressure lowering treatment.

All patients, by definition, had normal Humphrey automated fields on at least two occasions judged by the criteria of having no point with more than 5 dB reduction compared with age-matched normals (excluding the outer ring of the 24-2 program).

Peripheral movement displacement thresholds at a single locus were measured by the method described previously.<sup>5</sup> The test uses a 2 minute by 2 degree computer generated line. The background and stimulus luminance were 7 cd/m<sup>2</sup> and 27 cd/m<sup>2</sup> respectively. The background subtended 8 × 10 degrees and was viewed at 1.24 metres. Measurements were made at a single location at 15 degrees in the temporal field, on the 330 degree meridian, just above the blind spot. Frequency of seeing curves were constructed by presenting the moving target (frequency 2.5 Hz) 10 times at 0-18 minutes of arc displacements (in random order). The data were analysed by probit analysis to give a 50% value of

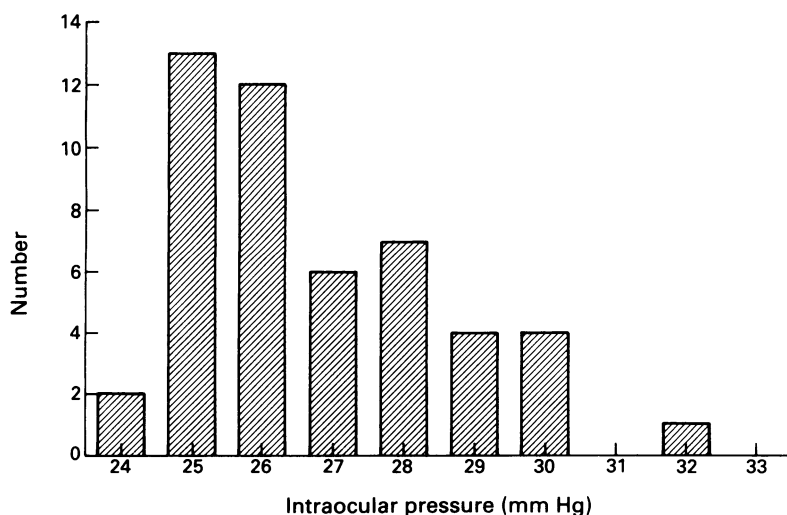
Glaucoma Unit,  
Moorfields Eye Hospital,  
City Road, London EC1  
S Ruben

Institute of  
Ophthalmology, Bath  
Street, London EC1  
F Fitzke

Correspondence to:  
Mr S Ruben.

Accepted for publication  
23 September 1993

Figure 1 Frequency distribution of intraocular pressures.



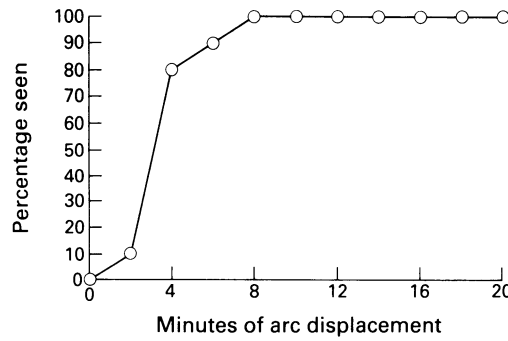


Figure 2 Typical curve for peripheral movement displacement thresholds.

movement displacement threshold. Figure 2 shows a typical curve for an ocular hypertensive patient.

Previous results have given values for normal, ocular hypertensive, and glaucomatous eyes (Table 1).

Optic disc photographs were taken after mydriasis with the Canon CF-60U retinal camera. Two slightly eccentric views were taken so as to allow pseudostereoscopic viewing of the discs. Keratometric measurements and refractive error (spherical equivalent) were recorded. The photographs were then analysed using a computerised image analysis system (Thot Informatique, Pr Bechetoille, Angers, France) which estimates dimensions and areas using calculations based on Littmann's formula and corrected for the Canon retinal camera. This system has been shown to give reproducible results in a previous study.<sup>14</sup> The optic disc was outlined manually with reference to stereo photographs using the inner boundary of the peripapillary scleral ring.<sup>15</sup> The outline of the disc cup was drawn in a similar fashion based on the contour of the rim and not on pallor. The disc measurements were made without knowledge of the MDT results. Values for vertical disc diameter, vertical, horizontal, and surface area cup-disc ratios, and surface areas of disc, cup, and neuroretinal rim were recorded.

**Results**

**MOVEMENT DISPLACEMENT THRESHOLDS**

The mean displacement threshold for all 50 eyes was 5.54 minutes of arc with a standard deviation

Figure 3 Frequency distribution of movement displacement threshold (MDT) values.

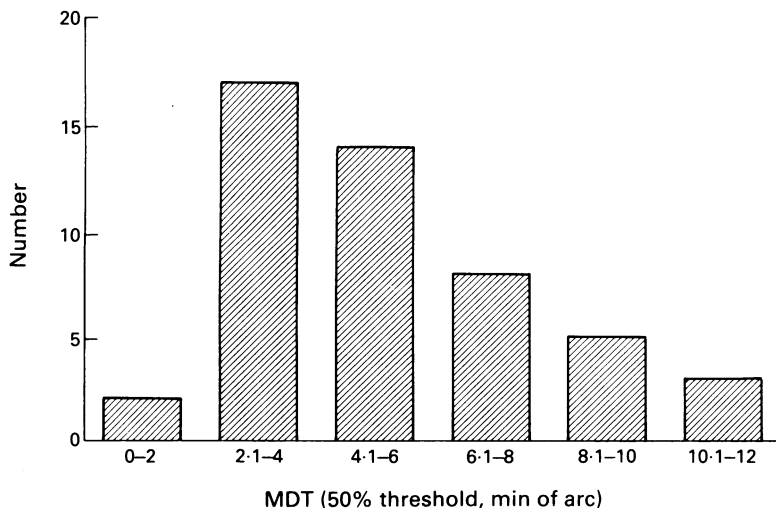


Table 1 Movement displacement threshold (MDT) values for normal, ocular hypertension, and glaucoma<sup>5</sup>

MDT (min arc)	Mean	Standard deviation
Normals	3.23	1.9
Ocular hypertension	5.49	3.14
Glaucoma	9.73	4.93

Table 2 Results of disc measurements, movement displacement thresholds (MDT), and intraocular pressures (IOP) for all patients

	Mean (n=50)	Standard deviation
Disc area (mm <sup>2</sup> )	2.19	0.68
Cup area (mm <sup>2</sup> )	0.51	0.39
Neuroretinal rim area (mm <sup>2</sup> )	1.68	0.42
Vertical diameter (mm)	1.8	0.29
Cup-disc ratio		
Vertical	0.43	0.11
Horizontal	0.46	0.12
Surface area	0.21	0.1
MDT (50% threshold, min arc)	5.54	2.68
IOP (mm Hg)	26.76	1.84
Age (years)	61	14

of 2.68. The results are summarised in Figure 3. The values for this newly recruited group of ocular hypertensives are in close agreement with previously reported values of MDT for ocular hypertensive patients (Table 1).

**OPTIC DISC MEASUREMENTS**

Results of optic disc measurements are summarised in Table 2. The mean disc area was 2.19 (SD 0.68) mm<sup>2</sup> with a diameter of 1.8 mm and vertical cup-disc ratio of 0.43 (0.11). Mean neuroretinal rim area was 1.68 (0.42) mm<sup>2</sup>.

The relation between MDT and the following parameters was studied: intraocular pressure, vertical disc diameter, vertical cup-disc ratio, neuroretinal rim area. In addition the relation between neuroretinal rim area and vertical disc diameter was plotted. Scattergrams for all these parameters are shown in Figures 4 and 5. The results were examined for statistical significance using Pearson's correlation coefficient. Although the distribution of MDT results appears skewed (Fig 3), they do not vary significantly from the normal distribution as calculated by the Kolmogorov-Smirnov test for normality (p>0.05).

There was no significant correlation between MDT and IOP, or cup-disc ratio. However, there was a significant correlation between MDT results and neuroretinal rim areas (Fig 5);  $r = -0.43$ ,  $r^2 = 0.19$ ,  $p = 0.0017$ , equation of line:  $Y = -0.063 X + 2$ . There was also a significant correlation between MDT and disc diameter (Fig 4A), although the relation was not as strong as with neuroretinal rim area:  $r = -0.35$ ,  $r^2 = 0.12$ ,  $p = 0.011$ , equation of line:  $Y = -0.039 X + 2.02$ . As expected the correlation between diameter and neuroretinal rim area was highly significant (Fig 4D);  $r = 0.85$ ,  $p < 0.000001$ . The association between neuroretinal rim area and MDT was also significant when analysed using non-parametric methods; Spearman rank correlation coefficient =  $-0.37$ ,  $p = 0.009$ .

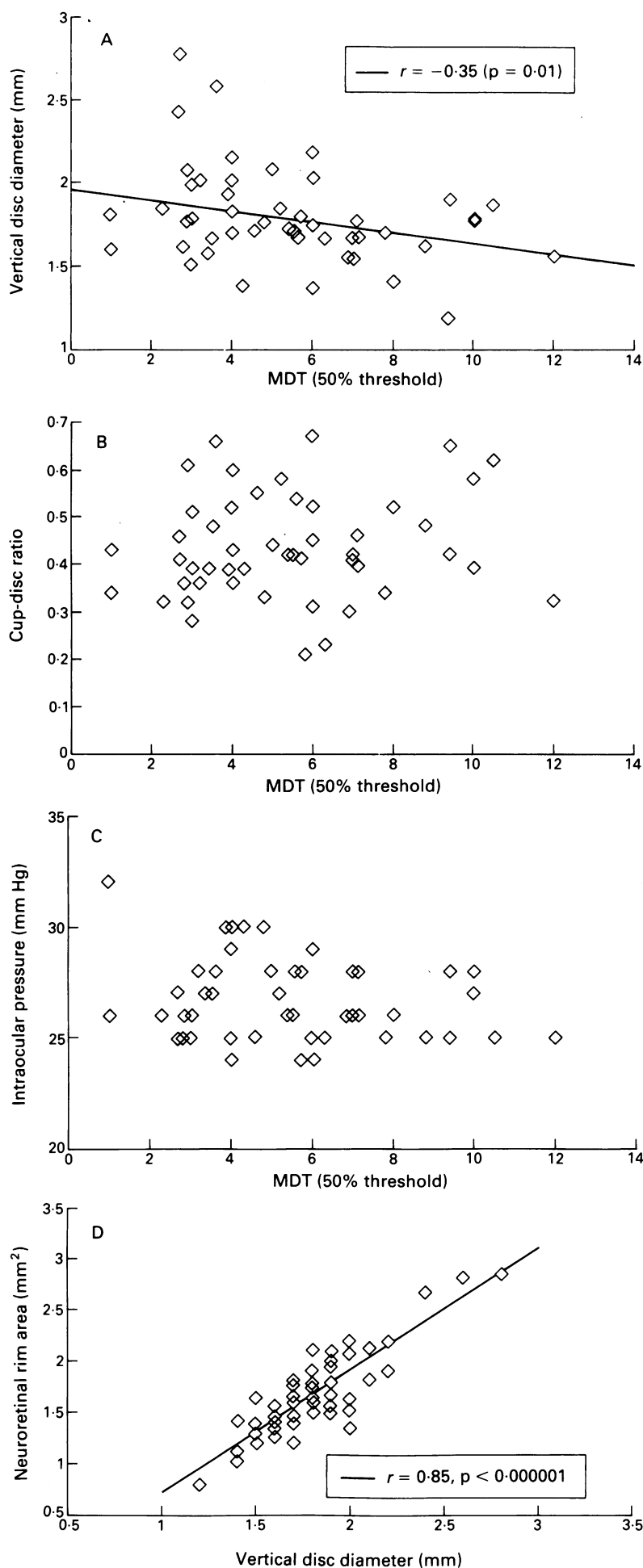


Figure 4 Scattergram of movement displacement threshold (MDT) values plotted against (A) vertical disc diameter; (B) cup-disc ratios; (C) intraocular pressure; (D) neuroretinal rim areas plotted against vertical disc diameter.

## Discussion

Histological studies have shown that there may be significant loss of ganglion cell axons before evidence of functional loss on conventional visual field testing.<sup>7,8</sup> For this reason attention has been focused on alternative, more sensitive ways of detecting early ganglion cell damage. The measurement of movement displacement thresholds may detect early ganglion cell damage, while optic disc measurements provide the anatomical correlate for evidence of tissue loss. If there is diffuse loss of ganglion cell activity this may be detected by more sensitive tests of overall function before focal defects are evident on standard field tests. In addition, the MDT is believed to depend on the integrity of the magnocellular pathways which have been shown to be damaged early in glaucomatous eyes.<sup>6</sup> The significant correlation between MDT values and neuroretinal rim areas suggests that the loss of neural tissue results in this loss of visual function. Both techniques have been shown to be possible predictors of early glaucomatous loss, but the MDT does not require mydriasis, is less time consuming, and is easily repeated.

It could be argued that MDT values are lower in eyes with large optic discs because they are referred to the eye department earlier on account of 'suspicious looking discs', when in fact their neuroretinal rim area is likely to be greater than that of a smaller disc with low cup-disc ratio. However, all patients in this study were referred primarily because of ocular hypertension, irrespective of disc appearance. In addition, our value of  $2.19 \text{ mm}^2$  for disc area closely agrees with the values published previously using the Discdata system which included patients randomly selected from a follow up clinic for glaucoma suspects.<sup>14</sup>

Once the diagnosis of glaucoma has been established, sequential field measurements may provide a more accurate indicator of progression than disc analysis because of the small areas being measured.<sup>9,16</sup> Increasing cup-disc ratios have long been used as evidence of progression in patients with established glaucoma and have also been used as a predictive risk factor in patients with ocular hypertension. However, some patients with ocular hypertension may have a combination of large cup-disc ratio together with a large optic disc but have a normal neuroretinal rim area. For this reason it is thought that measurement of neuroretinal rim area is likely to be a better predictor of early optic nerve damage than cup-disc ratio alone.<sup>11,12</sup> This is supported by the results of this study which show a correlation between movement displacement thresholds and neuroretinal rim areas, but not with cup-disc ratio. This is further supported by the correlation of MDT values with disc diameter, as large discs are likely to have a large neuroretinal rim area unless the cup-disc ratio is extremely high. Neuroretinal rim area is very closely related to vertical disc diameter and it is therefore not unexpected to find a relation between disc size and MDT values in ocular hypertensive eyes with normal fields. In eyes with glaucomatous visual fields, disc size alone may not correlate with MDT, but decreased

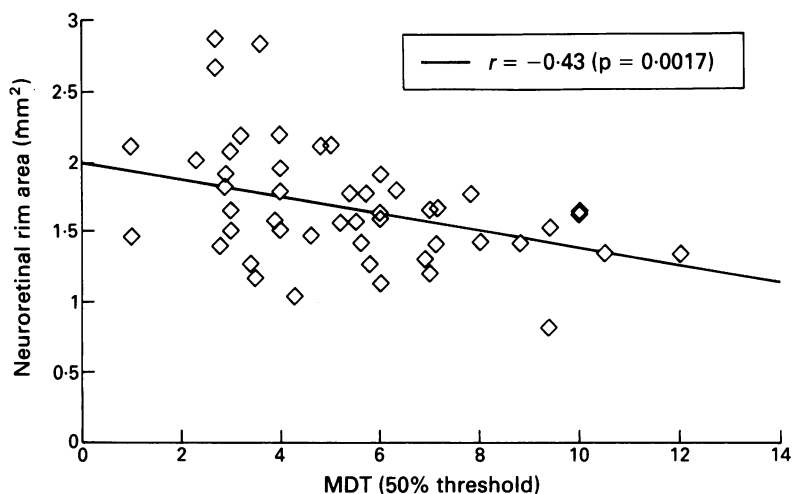


Figure 5 Scattergram of movement displacement threshold (MDT) values plotted against neuroretinal rim area.

neuroretinal rim areas are still likely to reflect early loss of function.

MDT is dependent on retinal eccentricity, luminance, line length, duration of movement, and other factors. By varying these parameters the test may be tuned to allow more selective measurement of loss of ganglion cell function in ocular hypertension. In addition, sensitivity and selectivity may be improved with the use of multiple location testing.<sup>17</sup>

In conclusion, MDT remains a promising new tool for the management of the preglaucomatous state and this is supported by the finding of a significant correlation between MDT and neuroretinal rim area.

Longitudinal studies required to assess the use of MDT in predicting early glaucomatous damage and progression of disease are under way.

- 1 Falco-Reis FM, Spileers W, O'Sullivan F, Arden GB. Macular colour contrast sensitivity in ocular hypertension and glaucoma. *Br J Ophthalmol* 1991; 75: 598-602.
- 2 Yu TC, Falco-Reis FM, Spileers W, Arden GB. Peripheral colour contrast: a new screening test for preglaucomatous visual loss. *Invest Ophthalmol Vis Sci* 1991; 32: 2779-89.
- 3 Hamill TR, Post RB, Johnson CA, Keltner JL. Correlation of colour vision deficits and observable changes in the optic disc in a population of ocular hypertensives. *Arch Ophthalmol* 1984; 102: 1637-9.
- 4 Tyler CW. Specific deficits of flicker sensitivity in glaucoma and ocular hypertension. *Invest Ophthalmol Vis Sci* 1981; 20: 204-13.
- 5 Fitzke FW, Poinoosawmy D, Ernst W, Hitchings RA. Peripheral displacement thresholds in normals, ocular hypertensives and glaucoma. In: Greve EL, Heijl A, eds. *Seventh Int Visual Field Symp* 1986: 447-52.
- 6 Quigley HA, Sanchez RM, Dunkelberger GR, Henaut NL, Baginski TA. Chronic glaucoma selectively damages large optic nerve fibres. *Invest Ophthalmol Vis Sci* 1987; 28: 913-8.
- 7 Quigley HA, Addicks EM, Green WR. Optic nerve damage in human glaucoma. III. Quantitative correlation of nerve fibre loss and visual field defect in glaucoma, ischaemic neuropathy, papilloedema and toxic neuropathy. *Arch Ophthalmol* 1982; 100: 135-46.
- 8 Quigley HA, Dunkelberger GR, Green WR. Retinal ganglion cell atrophy correlated with automated perimetry in human eyes with glaucoma. *Am J Ophthalmol* 1989; 107: 453-64.
- 9 Zeyen TG, Caprioli J. Progression of disc and field damage in early glaucoma. *Arch Ophthalmol* 1993; 111: 62-5.
- 10 Caprioli J, Miller J, Sears M. Quantitative evaluation of the optic nerve head in patients with unilateral visual field loss from primary open angle glaucoma. *Ophthalmology* 1987; 94: 1484-7.
- 11 Airaksinen PJ, Drance SM, Schulzer M. Neuroretinal rim area in early glaucoma. *Am J Ophthalmol* 1985; 99: 1-4.
- 12 Balazsi G, Drance SM, Schulzer M, Douglas GR. Neuroretinal rim area in suspected glaucoma and early chronic open angle glaucoma: correlation with parameters of visual function. *Arch Ophthalmol* 1984; 102: 1011-4.
- 13 Cioffi GA, Robin AL, Eastman RD, Perell HF, Sarfarazi FA, Kelman SE. Confocal laser scanning ophthalmoscope. Reproducibility of optic nerve head topographic measurements with the confocal laser scanning ophthalmoscope. *Ophthalmology* 1993; 100: 57-62.
- 14 Sturmer J, Poinoosawmy D, Broadway DC, Hitchings RA. Intra- and inter-observer variation of optic nerve head measurements in glaucoma suspects using disc data. *Int Ophthalmol* 1992; 16: 227-33.
- 15 Jonas JB, Gusek GC, Naumann GOH. Optic disc morphometry in chronic primary open angle glaucoma. I. Morphometric intrapapillary characteristics. *Graefes Arch Clin Exp Ophthalmol* 1988; 226: 522-30.
- 16 Hitchings RA, Spaeth GL. The optic disc in glaucoma: II. Correlation of the appearance of the optic disc with the visual field. *Br J Ophthalmol* 1977; 61: 107-13.
- 17 Wu X, Wormald R, Fitzke F, Poinoosawmy D, Nagasabramanian S, Hitchings R. Laptop computer perimetry for glaucoma screening. *ARVO Abstracts* 1991; 712: 810.