

Effect of topical β blockers on corneal epithelial wound healing in the rabbit

James J Reidy, Joseph Zarzour, Hilary W Thompson, Roger W Beuerman

Abstract

Topical β adrenergic receptor blocking agents (β blockers) are among the most frequently prescribed ophthalmic drugs. It has been suggested that some of these agents have a toxic effect on the corneal epithelium. In the present study, four β blockers in common therapeutic concentrations, as well as their vehicles, were applied to rabbit corneas that had undergone mechanical removal of epithelium from a 6 mm diameter corneal wound. The tested drugs (0.25% timolol, 0.25% levobunolol, 0.25% betaxolol, and 0.3% metipranolol) were found significantly to accelerate wound closure, compared with saline treatment in controls. Eyes treated with two of the vehicles (betaxolol vehicle and metipranolol vehicle) also demonstrated more rapid healing than controls, but the magnitude of the effect was not as great as that seen with the drugs. Only the β blockers were responsible for wound closure before 60 hours, whereas the saline treated controls and vehicle treated eyes required longer times for wound closure. In this model of wound healing, β blockers appear to have no deleterious effect on corneal epithelial wound healing.

(*Br J Ophthalmol* 1994; 78: 377-380)

The prevalence of glaucoma has been estimated at 1.25% of the population over the age of 40 years.¹ In the United States, topical β adrenergic receptor blocking agents (β blockers) are the most frequently prescribed class of drugs for treating this disease.² While patients benefit from the reduction of intraocular pressure induced by these drugs, they are also exposed to potential systemic side effects such as bradycardia, hypotension, bronchoconstriction, depression, and mental confusion.³ Ocular side effects of topical β blockers are relatively rare and include blurred vision, decreased corneal sensation, decreased tear production, and various corneal epithelial changes.⁴⁻⁶

Adrenergic receptors have been identified on the plasma membranes of corneal epithelial cells. Stimulation of these surface receptors results in increased chloride transport out of the cell, elevated intracellular cyclic AMP, and a decrease in the mitotic rate.^{7,8} The clinical significance of blocking these receptors is not well understood. Previous studies have shown that topical application of β blockers is followed by a temporary reduction in corneal sensitivity.⁹ Stabilisation of axonal membranes may account for this local anaesthetic effect.¹⁰ The cornea is a highly innervated structure that receives sensory innervation from the ophthalmic division of the

trigeminal nerve and sympathetic innervation from the superior cervical ganglion.¹¹⁻¹³ Nerve fibres enter the corneal stroma at the corneoscleral limbus and terminate in the epithelial layer. These autonomic and sensory nerve fibres have been shown to play an important role in the maintenance of normal epithelial function.¹⁴ Partial or complete destruction of these nerve fibres can result in corneal anaesthesia and chronic defects in the corneal epithelium.^{14,15}

All topical β blocking agents currently available in the United States contain the preservative benzalkonium chloride in concentrations varying from 0.004% to 0.01%. While this substance has been demonstrated to be an effective antimicrobial agent, it also exerts a toxic effect on cellular membranes.¹⁶ The toxicity results in increased cellular permeability and damage to the superficial layers of the epithelium.¹⁷

In the study reported here, we measured closure of experimental keratectomy wounds in the rabbit eye, which is a well established experimental means of evaluating corneal toxicity of topically applied ocular pharmaceutical agents,¹⁸ to evaluate the effects of currently available topical β blockers and their preserved vehicles on corneal epithelial wound healing.

Materials and methods

ANIMALS

Forty five New Zealand white rabbits weighing 2-3 kg each were treated in accordance with the ARVO resolution on the use of animals in research. Anaesthesia was achieved with an intramuscular injection of ketamine hydrochloride (35 mg/kg) and xylazine hydrochloride (5 mg/kg). One drop of 0.5% proxymetacaine (proparacaine) hydrochloride was administered for surface anaesthesia before corneal wounding.

CORNEAL WOUNDING

A standard 6 mm diameter central corneal wound was made in each eye using previously established techniques.¹⁸ After the eye was gently proptosed, a sterile 6 mm corneal trephine was centred over the pupil and a circular imprint was impressed on the epithelium. A sterile Kimura spatula was used to remove the corneal epithelium within the circular imprint, with visualisation under an operating microscope. In this fashion, the wound site was denuded of epithelium, leaving the basal lamina intact. Then the cornea was irrigated with sterile saline to remove debris and residual topical anaesthetic.¹⁸

Department of
Ophthalmology, State
University of New York at
Buffalo, USA

J J Reidy
J Zarzour

Lions Eye Research
Laboratories, Laboratory
for the Molecular Biology
of the Ocular Surface,
LSU Eye Center,
Louisiana State
University School of
Medicine, New Orleans,
USA

H W Thompson
R W Beuerman

Correspondence to:
Dr Roger W Beuerman, LSU
Eye Center, 2020 Gravier
Street, Suite B, New Orleans,
LA 70112, USA.

Accepted for publication
26 November 1993

TREATMENT GROUPS

The rabbits were randomly assigned to one of nine treatment groups; each group consisted of five rabbits (10 eyes). One group served as saline treated controls. In four groups, each rabbit received one drop of drug in both eyes every 12 hours; in the remaining four groups, each rabbit received one drop of vehicle alone in both eyes on the same schedule. The four β blockers, their trade names and manufacturers, and the constituents of the vehicles, are given in Table 1. Vehicles and the information concerning their constituents were provided by the manufacturers.

WOUND ANALYSIS

To evaluate the progression of healing, both eyes of each rabbit were photographed immediately after corneal wounding and 4, 10, 18, 26, 32, 48, 54, and 73 hours later. In this procedure, dilute fluorescein was instilled into the eye and colour photographs were taken using a 35 mm camera equipped with a 105 mm macro lens with a 1:1 magnification ratio and a yellow barrier filter. The flash unit had a cobalt blue excitation filter attached. The 35 mm colour slide images were projected at a fixed distance and the perimeter of the corneal wound from each eye was manually traced onto paper. The traced images were then manually digitised with a digitising pad (Summa Graphics, Fairfield, CT, USA) connected to a personal computer. The total area of the epithelial defect was calculated with the assistance of planimetry software (The Morphometer, Woods Hole Oceanographic Institute, Woods Hole, MA, USA). Each area calculation was then mathematically transformed to yield a wound radius corrected for curvature according to the method described by Crosson *et al.*¹⁸

STATISTICAL ANALYSIS

The results were analysed using the statistical analysis system.¹⁹ A nested design in the repeated measures analysis of variance (ANOVA) was

Table 1 β adrenergic receptor blocking drugs and vehicle constituents

Drug	Vehicle	Trade name/source
Timolol maleate	Benzalkonium chloride 0.1% Monobasic and dibasic sodium phosphate Sodium hydroxide Water	Timoptic 0.25%/Merck, Sharp & Dohme, West Point, PA, USA
Levobunolol	Polyvinyl alcohol 1.4% Benzalkonium chloride 0.004% Monobasic sodium phosphate Sodium chloride Monobasic potassium phosphate Edetate disodium Sodium metabisulphate Hydrochloric acid/sodium hydroxide Purified water	Betagan 0.25%/Allergan Pharmaceuticals, Hormigueros, Puerto Rico
Betaxolol	Benzalkonium chloride 0.01% Mannitol Poly(styrene-divinyl benzene) sulphonic acid Carbomer 934P Edetate disodium Sodium hydroxide/hydrochloric acid Purified water	Betoptic S 0.25%/Alcon Pharmaceuticals, Fort Worth, TX, USA
Metipranolol	Glycerol Sodium chloride Edetate disodium Povidone Hydrochloric acid/sodium hydroxide Purified water	Optipranolol 0.3%/Bausch & Lomb Pharmaceuticals, Tampa, FL, USA

Table 2 Effect of β blockers on wound closure in rabbit eye

Treatment	Mean wound radius (mm) at 50% closure	p Value compared with saline treated control	Slope (SD) of healing curve ($\mu\text{m/h}$)
Saline treated control	1.76	—	4.76 (0.19)
Timolol	1.63	0.0001	5.04 (0.22)
Levobunolol	1.58	0.0001	5.00 (0.24)
Betaxolol	1.63	0.0001	4.86 (0.20)
Metipranolol	1.59	0.0001	4.92 (0.22)
Timolol vehicle	1.75	0.2045	4.77 (0.22)
Levobunolol vehicle	1.76	0.3994	4.80 (0.18)
Betaxolol vehicle	1.70	0.0106	4.80 (0.23)
Metipranolol vehicle	1.64	0.0001	4.78 (0.20)

performed on all the data. The main effects considered to account for differences in the wound radius were the time after the wound was made and the drug or vehicle administered. Blocking effects that accounted for experimental variability including the variability in eyes within one rabbit and rabbits observed at each time within treatment groups. The overall ANOVA was followed by specific effects tests of the differences between control, treatment, and vehicle on the change in wound radius over time. These tests were conducted by contrasts of treatment, vehicle, and control effects, and took into account common variance and covariance of all means as revealed by the ANOVA.²⁰ Linear regression was conducted on each treatment group in order to determine the rate of epithelial closure.

Results

The results showed that the drug treated eyes appeared to heal faster than the saline treated controls, and healing rates in the vehicle treated eyes were not significantly different from the rates in saline treated controls (Table 2). The β blocker treated corneas showed projected healing times of less than 60 hours, whereas the saline treated controls and vehicle treated eyes took longer to heal, with most of these groups requiring more than 74 hours for wound closure (Fig 1).

Tests for differences in wound size were conducted on mean wound radii derived from the ANOVA calculations of the treatment means at the mean postwounding time or 50% closure time (32 hours after wounding), and were based on a common standard error of these least square means of 0.024. At 50% closure time, wound radius was significantly smaller in drug treated eyes, compared with saline treated control eyes ($p=0.0001$, for all). There were, however, no significant differences among the four drug treated groups at any time after wounding ($p<0.0746$ to $p<0.9578$, ANOVA).

At 50% closure time, wound size in vehicle treated eyes was significantly smaller than in the saline treated controls ($p<0.0319$) and larger than in the drug treated groups ($p<0.0002$). When the vehicle treated groups were compared individually with the saline treated controls, wound size was significantly smaller in the groups treated with betaxolol and metipranolol vehicles ($p<0.0106$ and $p<0.0001$ respectively, ANOVA), but indistinguishable from groups

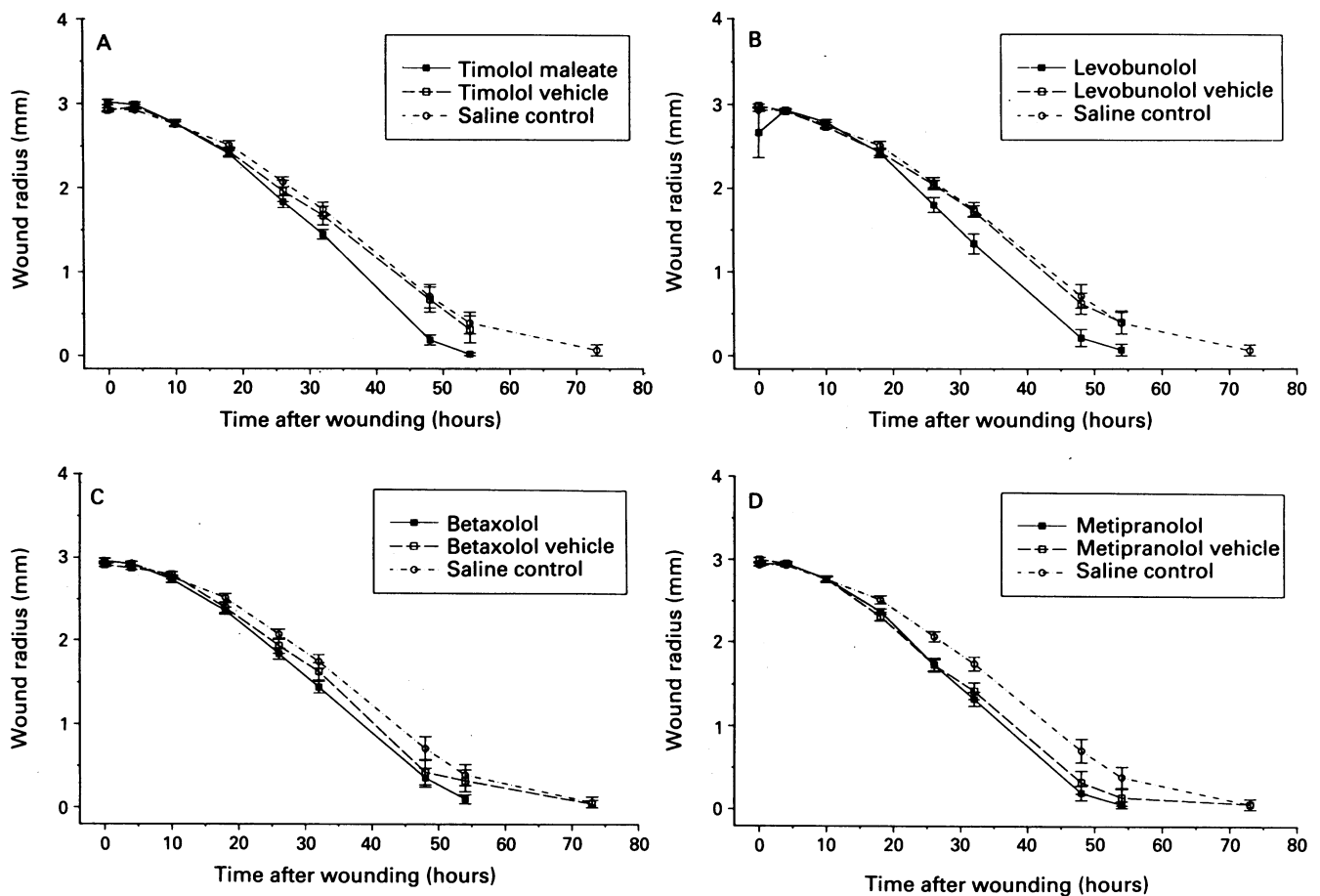


Figure 1 Wound radius as a function of post wound time for the β blockers and their vehicles. Each drug and vehicle is plotted with saline treated control data. (A) Timolol, (B) levobunolol, (C) betaxolol, (D) metipranolol. Points represent means and bars shown at each point are standard errors. Healing curves are shown to terminate when data from the next time point (74 hours) showed complete healing. However, only the drug treated corneas had projected healing times of less than 60 hours. Conclusions concerning significant differences among the data in these plots were made on the basis of the ANOVA and subsequent a posteriori testing of the means (see Results and Table 2).

treated with timolol and levobunolol vehicles ($p < 0.2045$ and $p < 0.3994$, respectively, ANOVA) (Table 2).

The time course of corneal wound healing for each drug and its respective vehicle, as well as the saline treated controls, is depicted in Figure 1. The slopes of the wound healing curves of each treatment group were determined using linear regression, during the linear phase of wound healing, 10 hours to 73 hours after wounding (Table 2). The slope of the curve provides the average rate of wound healing in each treatment group. Among the drug treated corneas, the group treated with betaxolol exhibited a slower rate of wound healing than the groups treated with levobunolol, metipranolol, or timolol, but all of the drug treated groups healed faster than the saline treated control groups, as shown by the significant difference between wound radii ($p < 0.0001$) (Table 2). In fact, the projected time to closure for the drug treated groups showed that all of these eyes would have healed before 60 hours. There were no significant differences in the rate of healing among the four vehicle treated groups, or when the vehicle treated groups were compared with the saline treated control group.

Discussion

In this study, corneal wounds were produced mechanically, without the application of chemicals (n-heptanol, iodine vapour). All the currently available topical β blockers were used in similar, therapeutic level concentrations. Vehicles without drug were obtained from each

manufacturer. Drug and vehicles were applied every 12 hours, the average maximal dosage used in humans. Serial photography at frequent time intervals was used to characterise precisely the active phase of wound healing. Computerised analysis of wound area was applied to every eye at each postwounding time. Total wound area was mathematically transformed into wound radius to reflect more accurately the dynamics of corneal epithelial wound healing.¹⁸

Previous studies that have attempted to analyse the effect of topical β blockers on corneal epithelial wound healing used several different approaches, and are therefore difficult to compare.²¹⁻²³ O'Brien *et al*²¹ concluded that frequent applications of 0.5% timolol maleate did not interfere with corneal epithelial wound healing, but the authors felt that some element in the drug vehicle delayed wound healing. In our study, all the drug treated groups healed faster than the saline treated controls, and the rate of wound healing for vehicle treated groups was not significantly different from the rate for saline treated controls. Nork and colleagues²² demonstrated that, although frequently applied 4% timolol inhibited the early phases of corneal epithelial wound healing, 0.5% timolol applied every 12 hours did not. In their study, 0.5% timolol, 0.5% betaxolol, and 0.5% levobunolol did not produce differences in wound healing during the first 24 hours after wounding, but appeared to retard corneal epithelial wound healing at 48 and 72 hours, compared with a control group treated with phosphate buffered saline. Trope *et al*²³ found that a group treated with timolol healed more slowly than a group

treated with betaxolol over 48 hours, and more slowly than groups treated with betaxolol or levobunolol over 72 hours after wounding. Recently, it was found that timolol and superior cervical ganglionectomy both resulted in increased corneal wound healing rates, compared with saline treated controls,²⁴ whereas the removal of the sensory innervation of the cornea resulted in markedly slowed healing.^{10,24}

Our results suggest that topically applied 0.25% timolol, 0.25% levobunolol, 0.25% betaxolol, and 0.3% metipranolol applied every 12 hours did not impede experimental corneal epithelial wound healing, compared with saline treated controls. Although the rates of wound healing varied, all of the β blockers were found to facilitate wound healing. The explanation for this seemingly paradoxical phenomenon is uncertain. Stimulation of β adrenergic receptors on corneal epithelial cells results in increased chloride transport out of the cell, elevated intracellular cyclic AMP, and a decrease in the mitotic rate.^{12,13} It is clear that blockage of these receptors alters the cellular response to exogenously applied adrenergic receptor agonists. The effect of prolonged adrenergic receptor blockade on intrinsic corneal sympathetic stimulation and, in turn, on various aspects of cellular metabolism, remains to be elucidated.

When the corneal epithelium is wounded, cells at the wound margin are transformed from a static to a motile state.¹⁸ These cells then migrate across the wound until the wound is covered.²⁵ Mitosis occurs, and the multilayer structure of the corneal epithelium is eventually restored. Blockade of adrenergic receptors on the corneal epithelium may be reflected in the sequence of early immediate and late gene expression that has been suggested to control the cellular response to wounding.²⁶ Previous studies have indicated that the number of cells undergoing mitosis in the area around a wound is reduced by sensory denervation and somewhat increased by cervical sympathectomy.²⁷

These results also demonstrate that the various drug vehicles, in and of themselves, appear to exert little effect on epithelial wound healing. While the vehicles alone did not affect the rate of wound closure to as great an extent as the β blockers, it is possible that various constituents of the vehicles (that is, benzalkonium chloride) exert toxic effects on the corneal epithelium that may not be demonstrated in this experimental model.^{16,17,28} Surfactants and detergents such as benzalkonium chloride and Tween 80 have been shown to be more toxic than polymeric compounds in an assay of cell spreading,²⁹ and it may well be that the toxicities of compounds are best determined in assays that involve a pertinent cell behaviour, such as spreading, which is part of the cell motility necessary in wound repair. Toxic levels can vary considerably; however, it is likely that glycerol and mannitol may be less toxic than the surfactants.^{28,29}

In summary, this study provides evidence that the commonly applied β blockers and their

vehicles may have little or no effect on wound healing in recipient eyes and, therefore, that their use may not contribute to healing problems in eyes undergoing trauma or surgery in patients requiring these drugs for the control of intraocular pressure.

This work was supported by US Public Health Service grants EY04074 and EY02377 from the National Eye Institute, National Institutes of Health, Bethesda, Maryland, and an unrestricted grant from Research to Prevent Blindness, Inc, New York.

- 1 Bengtsson B. The prevalence of glaucoma. *Br J Ophthalmol* 1981; 65: 46-9.
- 2 National Disease Therapeutic Index. Ambler, PA: IMS America, 1985.
- 3 Lewis RA. Medical therapy of glaucoma. In: Tassman W, Jaeger EA, eds. *Duane's clinical ophthalmology*. Volume 3. Philadelphia: JB Lippincott, 1989: chapter 56: 1-24.
- 4 Van Buskirk EM. Adverse reactions from timolol administration. *Ophthalmology* 1980; 87: 447-50.
- 5 Van Buskirk EM. Corneal anesthesia after timolol maleate therapy. *Am J Ophthalmol* 1979; 88: 739-43.
- 6 Wilhelmus KR, McCulloch RR, Gross RL. Dendritic keratopathy associated with β -blocker eye drops. *Cornea* 1990; 9: 335-7.
- 7 Klyce SD, Beuerman RW, Crosson CE. Alteration of corneal epithelial ion transport by sympathectomy. *Invest Ophthalmol Vis Sci* 1985; 26: 434-42.
- 8 Mishima S. Ocular effects of beta adrenergic agents. XII Jules Stein lecture. *Surv Ophthalmol* 1982; 27: 187-208.
- 9 Weissmann SS, Asbell PA. Effects of topical timolol (0.5%) and betaxolol (0.5%) on corneal sensitivity. *Br J Ophthalmol* 1990; 4: 409-12.
- 10 Martin XD, Safran AB. Corneal hypoesthesia. *Surv Ophthalmol* 1988; 33: 28-40.
- 11 Klyce SD, Jenison GL, Crosson CE, Beuerman RW. Distribution of sympathetic nerves in the rabbit cornea. *Invest Ophthalmol Vis Sci* 1986; 27 (suppl): 354.
- 12 Rozsa A, Beuerman RW. Density and organization of free nerve ending of rabbit corneal epithelium. *Pain* 1982; 14: 105-20.
- 13 Toivanen M, Tervo T, Portanen M, Vannas A, Hernonen A. A histochemical demonstration of adrenergic nerves in the stroma of human cornea. *Invest Ophthalmol Vis Sci* 1987; 28: 398-400.
- 14 Beuerman RW, Schimmelpfennig B. Sensory denervation of the rabbit cornea affects epithelial properties. *Exp Neurol* 1980; 69: 196-201.
- 15 Schwimann M, Butz M, Breck M. Temporal retrogasserian resection of trigeminal roots nerves controlled selective percutaneous electrocoagulation of the ganglion of Gasser in the treatment of trigeminal neuralgia. Report on a series of 537 cases. *Acta Neurochir (Weiss)* 1972; 26: 33-53.
- 16 Tonjum AM. Effects of benzalkonium chloride upon the corneal epithelium studied with scanning electron microscopy. *Acta Ophthalmol* 1975; 53: 358-66.
- 17 Burnstein NL, Klyce SD. Electrophysiologic and morphologic effects of ophthalmic preparations on rabbit cornea epithelium. *Invest Ophthalmol Vis Sci* 1977; 16: 899-911.
- 18 Crosson CE, Klyce SD, Beuerman RW. Epithelial wound closure in the rabbit cornea: a biphasic process. *Invest Ophthalmol Vis Sci* 1986; 27: 464-73.
- 19 SAS Institute Inc. SAS Users Guide: Statistics. Version 5. Cary, North Carolina: SAS Institute, 1985.
- 20 Freund RJ, Littell RC, Spector PC. SAS System for Linear Models. Cary, North Carolina: SAS Institute, 1986.
- 21 O'Brien WJ, DeCarlo JD, Stern M, Hyndiuk RA. Effects of Timoptic on corneal reepithelialization. *Arch Ophthalmol* 1982; 100: 1331-3.
- 22 Nork TM, Holly FJ, Hayes J, Wentlandt T, Lamberts DW. Timolol inhibits corneal epithelial wound healing in rabbits and monkeys. *Arch Ophthalmol* 1984; 102: 1224-8.
- 23 Trope GE, Liu GS, Basu PK. Toxic effects of topically administered Betagan, Betoptic, and Timoptic on regenerating corneal epithelium. *J Ocular Pharmacol* 1988; 4: 359-66.
- 24 Beuerman RW, Klyce SD, Vigo MC, Dupuy BM, Crosson CE. Modulation of latency and velocity in corneal epithelial wound healing. *Invest Ophthalmol Vis Sci* 1985; 26 (suppl): 91.
- 25 Buschke W. Morphologic change in cells of corneal epithelium in wound healing. *Arch Ophthalmol* 1949; 41: 306-10.
- 26 Beuerman RW, Thompson HW. Molecular and cellular responses of the corneal epithelium to wound healing. *Acta Ophthalmol* 1992; 70 (suppl): 7-12.
- 27 Beuerman RW, Tanelian DL, Schimmelpfennig B. Nerve tissue interactions in the cornea. In: Cavanagh D, ed. *The cornea: transactions of the world congress on the cornea III*. New York: Raven Press, 1988: 59-62.
- 28 Pfister RR, Burnstein NL. The effects of ophthalmic drugs, vehicles, and preservatives on corneal epithelium: a scanning electron microscope study. *Invest Ophthalmol Vis Sci* 1976; 15: 246-59.
- 29 Salonen, E-M, Vaheri A, Tervo T, Beuerman R. Toxicity of ingredients in artificial tears and ophthalmic drugs in a cell attachment and spreading test. *J Toxicol-Cut Ocular Toxicol* 1991; 10: 157-66.