

in a rabbit model,⁷ we did not encounter side effects in our patient. The favourable outcome of the case presented suggests that topical amikacin should be considered an effective and safe drug for the treatment of *Nocardia* keratitis.

PETER OLIVER DENK
 SOLON THANOS
 HANS-JÜRGEN THIEL

University Eye Clinic, Tübingen, Germany

Correspondence to: Oliver Denk, Schleichstrasse 12, 72076 Tübingen, Germany.

Accepted for publication 28 June 1996

- Boiron P, Provost F, Chevrier G, Dupont B. Review of nocardial infections in France 1987-1990. *Eur J Clin Microbiol Infect Dis* 1992; 11:709-14.
- Chen CJ. *Nocardia asteroides* endophthalmitis. *Ophthalmic Surg* 1983;14:502-5.
- Dewsnup DH, Wright DN. In vitro susceptibility of *Nocardia asteroides* to 25 antimicrobial agents. *Antimicrob Agents Chemother* 1984;25: 165-7.
- Douglas RM, Grove DJ, Elliott J, Looke DFM, Jordan AS. Corneal ulceration due to *Nocardia asteroides*. *Aust NZ J Ophthalmol* 1991;19:317-20.
- Helm CJ, Holland GN, Lin R, Berlin OGW, Bruckner DA. Comparison of topical antibiotics for treating mycobacterium fortuitum keratitis in an animal model. *Am J Ophthalmol* 1993;116: 700-7.
- Hirst LW, Harrison GK, Merz WG, Stark WJ. *Nocardia asteroides* keratitis. *Br J Ophthalmol* 1979;63:449-54.
- Husain N, Matoba AY, Wilhelmus KR, Jones DB. Isolation and therapy of *Nocardia* keratitis. *Invest Ophthalmol Vis Sci* 1995;36 (Suppl):S155.

Recurrent systemic B cell lymphoma of the iris

EDITOR.—Recognised clinical findings of intraocular lymphoma include vitritis, solid retinal pigment epithelial detachments, diffuse retinal and choroidal infiltrates, retinal haemorrhage, perivasculitis, retinal necrosis, and optic neuritis.¹ Anterior uveitis secondary to posterior segment intraocular lymphoma is recognised, but isolated primary or recurrent iris lymphoma is rare. We report a case of non-Hodgkin's lymphoma involving only the iris.

CASE REPORT

A 25-year-old white woman reported blurred vision in the right eye for 3 weeks. Eighteen months earlier, she had presented with a right seventh nerve palsy and was found to have a right nasopharyngeal and parapharyngeal mass extending posteriorly to the right carotid sheath with perineural spread. Biopsy revealed diffuse large B cell lymphoma and lumbar puncture was positive for malignant lymphocytes. She was managed with systemic cyclophosphamide, vincristine, and doxorubicin, and intrathecal methotrexate and cytarabine, followed by external beam radiotherapy to the nasopharyngeal area with eye shielding. At completion of therapy, all repeat studies including cerebrospinal fluid examination were normal and she remained in remission until presentation 18 months later.

On examination, the visual acuity was 20/30 in the right eye and 20/20 in the left. Intraocular pressures were 16 mm Hg in both eyes. The left eye was normal, the right showed central corneal oedema with fine diffuse keratic precipitates and moderate cells and flare in the anterior chamber. The entire right iris was thickened and a diffuse solid mass was present superiorly (Fig 1). There was noticeable iris heterochromia, with the right iris

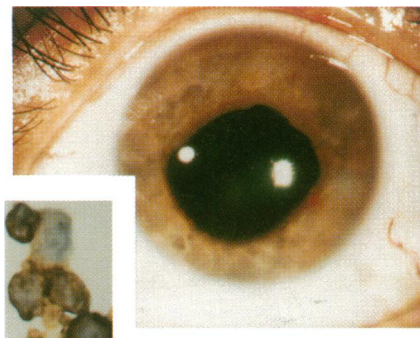


Figure 1 Slit-lamp photograph of the right eye showing diffuse nodular iris thickening. Inset: high power photomicrograph of cytological specimen showing lymphoma cells and positive immunocytochemical staining for the pan B cell marker CD20 (L26).

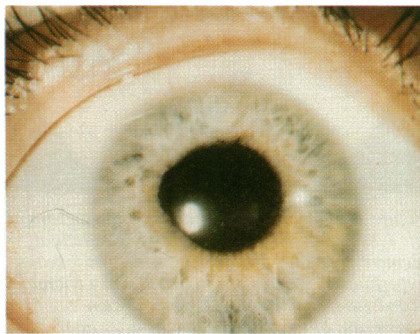

Figure 2 Slit-lamp photograph of the right iris showing iris crypts and mild persistent ectropion 3 months after radiotherapy. There is no residual iris thickening.

brown and the left iris blue. Ectropion uvea was present superiorly, but there was no iris neovascularisation or lens abnormality. The posterior segment examination was unremarkable. Systemic examination was normal. Uncomplicated fine needle aspiration biopsy of the solid mass was performed via a superior temporal approach. Cytological evaluation of the specimen showed the presence of large atypical lymphocytes, morphologically compatible with non-Hodgkin's lymphoma. Immunocytochemical studies revealed positive staining of the cells for CD20 (L26) (Fig 1: inset), a pan B cell marker, and negative staining for CD45RO (UCHL1), a pan T cell marker. The patient underwent anterior external beam radiotherapy to the right iris, receiving 1980 cGy in 11 equal fractions. Three months later, the visual acuity was 20/20 and there was no thickening of the iris in the right eye, although the iris was less mobile than the left and there was some persistent ectropion uvea of the pupillary margin (Fig 2).

COMMENT

Anterior segment intraocular lymphoma in the presence of a normal fundus is rare. The first case reported was one in which an iris nodule was confirmed to be a lymphomatous lesion histopathologically after enucleation.² To our knowledge, six other cases have been fully reported,²⁻⁵ two presenting with non-granulomatous uveitis,^{3,4} one with neovascular glaucoma,² and three with diffuse iris thickening.^{3,5} In all six cases, as well as in this case, the iris lymphoma was associated with systemic non-Hodgkin's lymphoma, which had been previously diagnosed in five, rather than primary CNS lymphoma. This is not surprising as systemic lymphoma is typically associated with uveal tract ocular involvement,

whereas primary CNS lymphoma frequently involves the retina and optic nerve. However, it was unusual that all four of the six cases that reported cell type were T cell lymphoma^{3,5} since only 5% of systemic lymphoma is of T cell or mycosis fungoides origin. As more cases of iris lymphoma are categorised accurately by immunofluorescent cell surface marker antigens, and as our case suggests, B cell iris lymphoma may be diagnosed more frequently. The mechanism of involvement of the right iris from the ipsilateral nasopharynx could have included direct extension along the sympathetic chain, CNS spread secondary to perineural involvement, or metastasis.

Three reported patients were treated with systemic chemotherapy,^{3,4} two because of simultaneous recurrence of systemic lymphoma,^{2,3} two were enucleated,^{3,5} and one was treated with external beam radiotherapy.³ One patient treated by systemic chemotherapy had progression of the ocular lesion but the other three cases treated conservatively regressed after therapy.

While combination chemotherapy is indicated for iris lymphoma with systemic involvement, we suggest external beam radiotherapy may be justified in isolated ocular cases. Radiation induced cataract is expected although this may not be a major consideration if life expectancy is short.

Support provided by the Eye Tumor Research Foundation, Philadelphia, PA, USA.

PHILIP G HYKIN
 Ocular Oncology Service and the Retina Service,
 Wills Eye Hospital,
 Thomas Jefferson University, Philadelphia, PA, USA

JERRY A SHIELDS
 CAROL L SHIELDS
 Ocular Oncology Service, Wills Eye Hospital,
 Thomas Jefferson University, Philadelphia, PA, USA

HORMOZ EHYA
 Department of Pathology, Fox Chase Cancer Center,
 Philadelphia, PA, USA

ELIZABETH SIDERIDES
 St Joseph Medical Centre, Stamford, CT, USA

Correspondence to: Jerry A Shields, MD, Ocular Oncology Service, Wills Eye Hospital, 900 Walnut Street, Philadelphia, PA 19107, USA.

Accepted for publication 28 June 1996

- Shields JA, Shields CL. *Intraocular tumors: a text and atlas*. Philadelphia: WB Saunders, 1992:498-510.
- Locasio JA. Neoplastic causes of anterior segment inflammation. *Int Ophthalmol Clin* 1983; 23:111-21.
- Goldey SH, Stern GA, Oblon DJ, Mendenhall NP, Smith LJ, Duque RE. Immunophenotypic characterisation of an unusual T-cell lymphoma presenting as anterior uveitis. *Arch Ophthalmol* 1989;107:1349-53.
- Hanamura A, Maeda H, Kuwayama W, Takano Y. Infiltration into the aqueous humor in a patient with malignant lymphoma. *Jap J Clin Haematol* 1992;33:1845-50.
- Jensen OA, Johansen S, Kiss K. Intraocular T-cell lymphoma mimicking intraocular disease. *Graefes Arch Clin Exp Ophthalmol* 1994;32: 148-52.

Treatment of subfoveal pigment epithelial detachments with distant extrafoveal choroidal neovascular membranes

EDITOR.—Subfoveal retinal pigment epithelial detachments larger than 1 disc diameter in patients over the age of 55 have a poor visual prognosis.¹ Laser photocoagulation of a contiguous extrafoveal choroidal neovascular membrane sometimes causes flattening of a retinal pigment epithelial detachment and