

COMMENT

Microscopic analysis of the tumour indicated that it was a fibrosarcoma. Many fibrosarcomas in previous reports were described as non-encapsulated or poorly circumscribed.³⁻⁵ In contrast, the tumour in this case had unique radiological and pathological features. Results of computed tomography of the orbit showed a relatively well defined mass attached to the posterior pole of the globe. The magnetic resonance imaging and pathological findings indicated that the fibrosarcoma in this case developed primarily in the scleral stroma and was invasive in the sclera.

KENJI OHTSUKA
KUMI SAITO

Department of Ophthalmology,
Sapporo Medical University,
School of Medicine Sapporo, Hokkaido, Japan

Correspondence to: Dr Kenji Ohtsuka, Department of Ophthalmology, Sapporo Medical University, School of Medicine, S-1, W-16, Chuo-ku, Sapporo 060, Japan.

Accepted for publication 28 June 1996

- 1 Stout AP. Fibrosarcoma: the malignant tumor of fibroblasts. *Cancer* 1948;1:30-59.
- 2 Forrest AW. Intraorbital tumors. *Arch Ophthalmol* 1949;43:198-232.
- 3 Yanoff M, Scheie H. Fibrosarcoma of orbit. *Cancer* 1966;19:1711-6.
- 4 Jakobiec FA, Tannenbaum M. The ultrastructure of orbital fibrosarcoma. *Am J Ophthalmol* 1974; 77:899-917.
- 5 Scott SM, Reiman HM, Pritchard DJ, Ilstrup DM. Soft tissue fibrosarcoma: a clinicopathologic study of 132 cases. *Cancer* 1989;64:925-31.

CORRESPONDENCE

A new mounting bracket for donor eye holder

EDITOR,—Morphometry of corneal endothelial cells is now recognised as indispensable for evaluation of corneal function in many clinical and research situations.¹ It may be performed by physical counting of endothelial cells within a rectangular boundary from specular photomicrographic negatives, or with digitisers and image analysers which require manual tracing of the cell boundaries or their apices after endothelial specular photomicrography.² These methods are time consuming, tedious, and liable to human error and bias.

Advances in instrumentation and computer technology have resulted in new contact and non-contact semiautomatic clinical specular microscopes³ which feature an autofocusing device for instant acquisition of endothelial images. In addition, some have an inbuilt semiautomatic image analysis programs, while yet others have been adapted for use with separate computers which provide rapid and comprehensive analysis of cell variables.¹ These improvements have eased the tedium and drudgery of the earlier methods,² and minimised the elements of human error and bias.

Furthermore, evaluation of the corneal endothelium in the presence of significant stromal oedema has become a practical reality with the advent of the confocal microscope.⁴ It would be desirable to take advantage of these advances in the context of donor cornea assessment and morphometry.

Donor eye holders for supporting the intact globe for specular microscopy have been dedi-

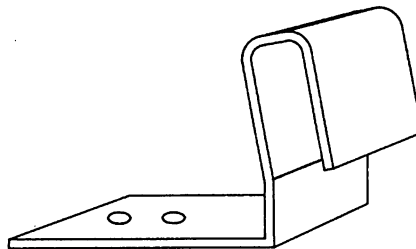


Figure 1 Diagram of the mounting bracket.




Figure 2 Photograph of eye holder with a globe in situ mounted on a non-contact specular microscope by means of the bracket for morphometry of the corneal endothelium.

cated to particular instruments,⁵⁻⁷ and are, therefore, not interchangeable. In addition, they may not fit the new semiautomatic contact and non-contact specular microscopes. This makes it difficult to harness the advantages of the various specular microscopes and to compare them. A universal holder for supporting the intact globe which can be attached to most clinical microscopes would be useful and desirable.

Given the limitations of the donor eye holders which have been dedicated to particular specular microscopes, and the need to take advantage of recent advances in morphometric analysis with the new semiautomatic specular microscopes, in the context of donor cornea assessment and morphometry, I have designed, produced, and tested a new and simple mounting bracket for the Narthey donor eye holder.⁸

The mounting bracket (Fig 1) is made of brass and consists of flat horizontal and vertical limbs. The horizontal limb bears two holes at its distal end. The vertical limb is inclined slightly backwards at its upper two thirds, and angled forwards at its proximal end for attachment to a headrest. Either hole on the horizontal limb can be aligned with that for a thumbscrew halfway up the side of the eye holder. The mounting bracket is attached to the eye holder by first engaging the aligned holes with the thumbscrew. Tightening the thumbscrew secures the mounting bracket firmly to the side of the holder.

This permits the holder, without its base plate, but with a donor eye in situ, to be attached horizontally to the headrest of contact and non-contact specular microscopes (Fig 2) for visualisation, assessment, photography, and/or morphometric analysis of the donor corneal endothelium in the intact globe.

A smaller mounting bracket of similar design, but with a narrower angle at the proximal end of its vertical limb, can be used with the Haag-Streit slit-lamp and the tandem scanning confocal microscopes which have a plastic headrest.

It is believed this innovation is an advance and should facilitate research and objective assessment of the donor cornea in the intact globe.

I am very grateful to Mr Roger Buckley for reading the manuscript and for his helpful suggestions. I thank Mrs Ann Patmore and Mr N Wingate for permission to use the confocal and the S-P 1000 (Topcon) microscopes, and Mr P Johnson for technical assistance.

ISRAEL N NARTEY
Moorfields Eye Bank, Moorfields Eye Hospital,
City Road, London EC1V 2PD

- 1 Siertsema JV, Landesz M, Van Den Brom, Van Rij G. Automated video image morphometry of the corneal endothelium. *Doc Ophthalmol* 1993;85:35-44.
- 2 Waring GO, Ford GE, Harris RR, Rosenblatt LS. Four methods of measuring human corneal endothelial cells from specular micrographs. *Arch Ophthalmol* 1980;98:848-55.
- 3 Landesz M, Siertsema J V, Van Rij, G. Comparative study of three semi-automated specular microscopes. *J Cataract Refract Surg* 1995;21: 409-16.
- 4 Lemp FB, Dilly PN, Boyde A. Tandem confocal microscopy of full thickness cornea. *Cornea* 1985;4:205-9.
- 5 Hoefle FB, Maurice DM, Sibley RC. Human donor material: a method of examination before keratoplasty. *Arch Ophthalmol* 1970;84:741-4.
- 6 Bigar F, Schimmelpennig B, Gieseler R. Routine evaluation of endothelium in human donor corneas. *Graefes Arch Klin Exp Ophthalmol* 1976; 200:195-200.
- 7 Matsuda M, Yee RW, Glasser DB, Geroski DH, Edelhauser HF. Specular microscopic evaluation of donor corneal endothelium. *Arch Ophthalmol* 1986;104:259-62.
- 8 Narthey IN. Mastering the infant donor eye: a new device for obtaining corneoscleral buttons for storage and corneal discs for keratoplasty. *Br J Ophthalmol* 1991;75:38-41.

BOOK REVIEWS

The Eye: Basic Sciences in Practice. By J V Forrester, A D Dick, P McMenemy, W R Lee. Pp 320. £45. London: W B Saunders, 1995.

Here is a textbook which seeks to guide the novice trainee ophthalmologist on the path to success in primary professional examination(s). It tackles, in a simple didactic style, the rudiments of anatomy, embryology, genetics, biochemistry, physiology, pharmacology, immunology, microbiology, and pathology. Candidates will find it a concise review of information learnt in medical school and not long forgotten.

By far the most useful chapters are those on biochemistry, pharmacology, and immunology. These are clearly written, and are pitched at exactly the right level. Topics of contemporary research have been dealt with in an admirably lucid manner, such as integrins, extracellular matrix proteins and proteoglycans, adhesion molecules, ligand/receptor/second messenger systems, retinal neurotransmitters, cytokines, immunoglobulin genes, cluster of differentiation (CD) numbers, and T cell receptors.

The sections on biochemistry and immunology make good use of a format which has been common in American books: 'boxes' demarcate from the main text a number of detours which provide helpful glossaries and encyclopaedia-type entries on supplementary and background information. In the pharmacology section, and in an attractive and concise chapter on microbiology, the boxes