

LETTERS TO THE EDITOR

Microphthalmos in association with Gorlin's syndrome

EDITOR,—Gorlin's syndrome is a well characterised autosomal dominant condition described by Gorlin and Goltz.¹ The gene responsible has been localised to chromosome 9 and shows no heterogeneity.² The syndrome occurs in 1 in 200 patients with basal cell carcinomas (BCC) and displays an approximate 40% spontaneous mutation rate.³

The phenotype may potentially manifest around 100 features and according to their frequency, major and minor diagnostic criteria have been established.⁴ Principally, the syndrome is characterised by multiple BCCs, odontogenic keratocysts, palmar and plantar pits, skeletal abnormalities (kyphoscoliosis and bifid ribs), and intracranial pathology (medulloblastoma). Several ocular abnormalities have been described including coloboma, esotropia, glaucoma, and cataract.^{2 4 5} We present here a case of non-colobomatous microphthalmos in association with Gorlin's syndrome.

CASE REPORT

A girl was born at term to a mother with established Gorlin's syndrome, manifested principally by multiple BCCs. Her older brother was also Gorlin's phenotype. At 8 months, she presented with left non-colobomatous microphthalmos (Fig 1). Soft tissue facial asymmetry was noted initially but has become less marked with subsequent development. The cornea of the microphthalmic eye was initially covered by a plaque overlying a formed anterior chamber.

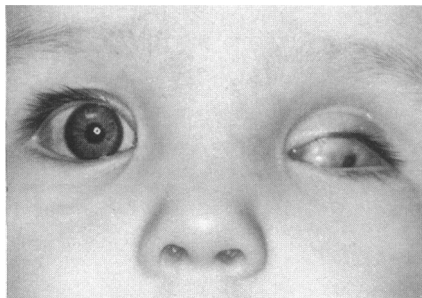

Figure 1 Microphthalmic left eye.

Examination of the right eye was normal with central, steady, and maintained vision. Electrophysiological tests (electroretinogram and visual evoked potentials) performed on this eye were normal.

General examination was unremarkable at presentation but has subsequently revealed an increasing occipitofrontal head circumference above the 97th centile while her weight remains on the 50th centile. Serial cranial ultrasonography suggests no intracerebral pathology. Vertebral and chest x rays have been normal; however, the most recent facial views have demonstrated the presence of two odontogenic keratocysts. Abdominal ultrasound has revealed a single kidney.

Her continuing orbital and visual development is under close review and the fitting of a cosmetic shell is planned.

COMMENT

According to the criteria given by Evans *et al*,⁴

the diagnosis of Gorlin's syndrome can be made in this young child with assurance in view of her strongly positive family history, the presence of an odontogenic keratocyst, and her large occipitofrontal diameter.

As far as the authors are aware, the presence of microphthalmos is a newly reported presenting sign in Gorlin's syndrome. Such a finding adds to the spectrum of associated ocular pathology. Interestingly, there was no evidence of coloboma which is a well recognised minor diagnostic criteria for Gorlin's syndrome.⁴ We suggest, therefore, that Gorlin's syndrome should be considered in the differential diagnosis of microphthalmos and other features sought in probands and their relatives.

R M MANNERS

R J MORRIS

P J FRANCIS

Department of Ophthalmology,
Southampton Eye Unit

E HATCHWELL

Genetics Department,
Southampton General Hospital

Correspondence to: Miss R M Manners, Southampton Eye Unit, Southampton General Hospital, Tremona Road, Southampton SO16 6YD.

Accepted for publication 30 November 1995.

- Gorlin RJ, Goltz RW. Multiple nevoid basal cell epithelioma, jaw cysts and bifid rib: a syndrome. *N Engl J Med* 1960; 262: 908.
- Fardon PA, Del Mastro RG, Evans DG, Kilpatrick MW. Location of gene for Gorlin's syndrome. *Lancet* 1992; 339: 581-2.
- Stanley S, Ratcliffe J, Hockey A, Haan E, Oley C, Ravine D, *et al*. Nevoid basal cell carcinoma syndrome: review of 118 patients. *Am J Med Genet* 1994; 50: 292-9.
- Evans DG, Ladusans EJ, Rimmer S, Burnell LD, Thakker N, Fardon PA. Complications of the nevoid basal cell carcinoma syndrome: results of a population based study. *J Med Genet* 1993; 30: 460-4.
- Gorlin RJ. Nevoid basal cell carcinoma syndrome. *Medicine* 1987; 66: 98-113.

Bilateral congenital dentiform cataract and extreme microcornea in eyes with uveal colobomas and persistent hyperplastic primary vitreous

EDITOR,—Congenital abnormalities of the lens include lentiglobus (lenticonus),¹ colobomas, and, most commonly, partial or total cataracts.² Cataracts may occur isolated or as part of a generalised ocular developmental defect, with or without systemic disorders. Jain *et al* found 46% of congenital cataracts in

their series to be of 'idiopathic origin' and only 20% to be hereditary.³ Hereditary cataracts typically are symmetrical in affected individuals, but they may show a considerable interocular phenotypic variability peaking in a unilateral occurrence.⁴ The classic combination of congenital cataract and microcornea is often an X linked recessive syndrome, or is transmitted as an autosomal dominant trait with a high degree of penetrance.⁵

In contrast, we report on a healthy woman with sporadically appearing, bilateral congenital dentiform cataract in eyes with extreme microcornea.

Case report

A 33-year-old white woman with known congenital cataract, but without systemic physical abnormalities and without mental retardation, complained of increasing glare and reduced vision over the previous 5 years. Family history and perinatal history were unremarkable.

Visual acuity of the right eye (total length 24.8 mm) was perception of light with intact projection, visual acuity of the left eye (total length 25.2 mm) was 1/35 (in 1 metre) without improvement by glasses. Intraocular pressure was normal in both eyes. Visual fields (Goldmann) of the right eye showed a residual island of 10° in the left lower quadrant about 50° from the centre (V4), and a 10° (para-) central island (III4) in the left eye. Rotatory nystagmus allowed endothelial cell count only in the left eye (1834 cells/mm²). Electroretinography revealed residual scotopic potentials, predominantly in the left eye.

Morphological findings included microcornea (6.5×6.5 mm) in both eyes, retrocorneal pigment dispersion (more pronounced in the left eye), a moderate amount of uveal tissue covering the trabecular meshwork in the anterior chamber angle (predominantly in the left eye); nasally and inferiorly subluxated lenses with (hyper-) mature cataracts, nasally and inferiorly located colobomas of the iris (Fig 1). Ophthalmoscopic evaluation of the vitreous and fundus was not possible at that time.

Ultrasonography showed a 'persistent hyaloid artery' reaching from the posterior part of a pyramidal-shaped lens to a prominent (para-) papillary region. Computer tomography of the skull was unremarkable. Computer tomography of the orbit detected a deformed right globe with flattening of the

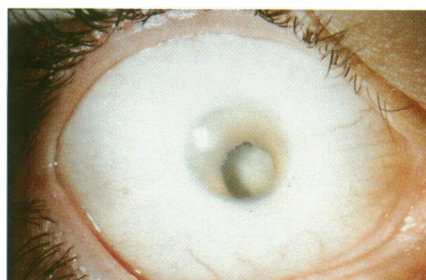


Fig 1A

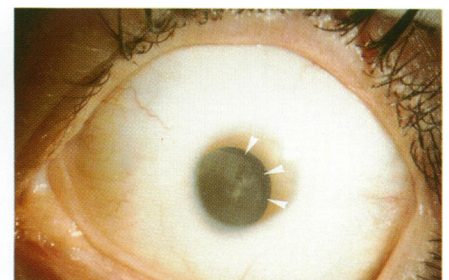


Fig 1B

Figure 1 Female patient aged 33 years. (A) Right eye with microcornea (6.5×6.5 mm), iris coloboma inferonasally, and subluxated lens with hypermature cataract. (B) Left eye with microcornea (6.5×6.5 mm), iris coloboma inferonasally, and subluxated lens with mature cataract. Arrowheads indicate the visible margin of the lens.

OBITUARY

ALISON McCARTNEY

Alison McCartney died on 8 March 1996 after a short and valiant battle with breast cancer just 3 weeks short of her 46th birthday. In her relatively short career she had quickly risen to being a major international figure in the world of ophthalmic pathology.

She studied medicine at Girton, Cambridge and St Bartholomew's Hospital, London, qualifying in 1975 and quickly entered pathology at St Stephen's and the Charing Cross hospitals in London, obtaining MRC Path in 1981. She was appointed senior lecturer at Charing Cross in 1982 and in 1985 was appointed to the Institute of Ophthalmology, London and Moorfields Eye Hospital, and it was here that her career blossomed. She was subsequently elected FRCOphth, FRC Path, and was awarded her MD.

She developed two major interests, corneal disease and tumours of the eye and adnexa. She was a refreshing introduction of new blood into the Institute and her enthusiasm for her subject was infectious. She was soon much in demand as a co-author on many projects with the junior staff at Moorfields and the Institute and despite her own heavy schedule she always found time to spend on these projects. She also had an uncomfortable habit of not accepting conventional theories at face value and a number of people found themselves having to do a bit more thinking as a result of Alison's perceptive comments. As well as her service commitment she was busy in research and teaching and took an active part in national and international events.

In 1993, she was appointed to the United Medical and Dental Schools of Guy's and St Thomas's as Iris Fund senior lecturer and a new stage of her career in ophthalmic pathology began with great promise. Surely a chair was only a short time away. Tragically, soon after the birth of her third child, advanced breast cancer was diagnosed. Despite this devastating blow she undertook a formidable workload, continuing not only a prolific output of scientific papers and research but also organising a most successful international congress on ophthalmic pathology. In addition, spurred on by her illness she made a television film about breast cancer and helped establish support groups for women less able to cope than herself. She continued working until a very short time before her death.

Alison McCartney was no dry, dusty academic but had considerable style and *joie de vivre*. She maintained an active family life

with her husband Peter, a general practitioner, and their three children. She had considerable musical talent and sang soprano delightfully when she could be persuaded. She was a wonderful colleague and friend and enjoyed the cut and thrust of debate whether discussing anything from politics to oncology. Her loss will be keenly felt both on a professional and a personal basis.

COLIN M KIRKNESS

NOTICES

The Brian Harcourt Memorial Symposium

The 7th Brian Harcourt Memorial Symposium will take place on 2 July 1996. The symposium topic will be glaucoma. Further details: Mr Mitchell Ménage, Eye Department, Leeds General Infirmary, Clarendon Wing, Belmont Grove, Leeds LS2 9NS. (Tel: 0113 243 2799; Fax: 0113 292 6479.)

Course for Standardised Ophthalmic Echography

A course for standardised ophthalmic echography will be held at the IInd University Eye Hospital, University of Vienna, Austria, on 26-31 August 1996. Further details: Professor Dr P Till, IInd University Eye Hospital Vienna, AKH, Wöhringer Gürtel 18-20, 1090 Vienna, Austria.

International Congress New Developments in Ophthalmology 1996

An international congress on 'New developments in ophthalmology' will be held on 29-31 August 1996 in Nijmegen, the Netherlands. Further details: Professor Dr AF Deutman/Mrs Y Hennink, University Hospital, Department of Ophthalmology, PO Box 9101, 6500 HB Nijmegen, the Netherlands. (Tel: (31) 24 361 5105; Fax: (31) 24 354 0522.)

European Association for Study of Diabetes (EASDEC)

The study group on eye complications of the European Association for Study of Diabetes (EASDEC) will hold its 6th meeting on 31

August-1 September 1996 at the Bristol Hotel, Vienna, Austria in conjunction with the 32nd annual meeting of the EASD. Further details: Mondial Congress, Faulmannsgasse 4, A-1040 Vienna, Austria. (Tel: +43 1 58804 0; Fax: +43 1 5869185.)

Baylor/Welsh Cataract & Refractive Surgical Congress 1996

The Baylor/Welsh Cataract & Refractive Surgical Congress 1996 will be held at the Hyatt Regency Hotel, Houston, Texas on 5-7 September 1996. Further details: Eula Mae Childs, Cullen Eye Institute, Baylor College of Medicine, 6501 Fannin (NC200), Houston, TX 77030, USA. (Tel: 713-798-5941; Fax: 713-798-4364.)

International Symposium on Fluorescence Angiography

The International Symposium on Fluorescence Angiography will be held at the University of St Gall, St Gall, Switzerland on 8-12 September 1996. Further details: ISFA'96, c/o AKM Congress Service, Clarastrasse 57, PO Box, CH-4005 Basel, Switzerland. (Tel: ++41 61 691 51 11; Fax: ++41 61 691 81 89.)

British and Eire Association of Vitreo-Retinal Surgeons (BEAVRS)

The next meeting of the British and Eire Association of Vitreo-Retinal Surgeons (BEAVRS) will be held at the Manor House Hotel, Morehampstead, Devon on 17-18 October 1996. Further details: Mrs Jill Gledhill, Torbay Hospital, Lawes Bridge, Torquay TQ2 7AA. (Tel: 01803 654825; Fax: 01803 655 011.)

2nd International and 4th European Congress on Ambulatory Surgery

The 2nd International and 4th European Congress on Ambulatory Surgery will be held at the Queen Elizabeth II Conference Centre, Westminster, London on 15-18 April 1997. Further details: Congress Secretariat, Kite Communications, The Silk Mill House, 196 Huddersfield Road, Meltham, West Yorkshire HD7 3AP. (Tel: +44 1484 854575; Fax: +44 1484 854576.)

Correction

An authors' error occurred in the ordering of the authors in a letter to the editor published in the April issue of the *BJO* (1996;80:378). The correct order should be Francis P J, Hatchwell E, Morris R J, Manners R M.