

## LETTERS TO THE EDITOR

**Long term effect of repeated hyperbaric oxygen therapy on visual acuity in inflammatory cystoid macular oedema**

EDITOR.—Cystoid macular oedema is a well known complication of chronic uveitis and is the major cause of visual disability accounting for 29% of blindness and 41% of visual impairment in this group.<sup>1</sup>

Therapy consists of control of inflammation with both topical and systemic agents. Symptomatic treatment with acetazolamide orally and grid laser photocoagulation have been shown to reduce cystoid macular oedema as well as vitrectomy.<sup>2,3</sup>

Treatment of cystoid macular oedema has been reported with good results by hyperbaric oxygen, but only limited follow up was presented.<sup>4-7</sup>

**CASE REPORT**

In 1986 a 46-year-old woman developed bilateral posterior uveitis with vitritis and periphlebitis of unknown origin. Routine uveitis screening disclosed no abnormalities. Despite locally administered drugs, high doses of systemic prednisolone, and acetazolamide cystoid macular oedema increased and persisted. Grid laser treatment of the right macula resulted in resolution of the cystoid macula oedema but did not improve visual acuity. Cyclosporine was added to therapy with no positive results; later it had to be withdrawn because of systemic side effects.

Visual acuity in 1992 decreased to 20/200 right eye and 20/80 left eye and the eye was clinically quiet. While continuing systemic steroids, we started treatment with hyperbaric oxygen therapy in February 1994 (see Fig 1), five times a week over 5 weeks. One hyperbaric session involved 100% oxygen (8 litres/min) administered by a nose/mouth mask subsequently pressuring the multiplace chamber (98 m<sup>3</sup>) with compressed air from 1 atmosphere to 3 atmospheres in 12 minutes, followed by a period of 75 minutes at 3 atmospheres and finally decompression at 1 atmosphere. Visual acuity gradually improved to 20/100 right eye and 20/40 left eye within 2 months. The visual evoked potential by pattern onset stimuli showed that the minimal check size minimally evoking a response decreased in the right eye just after the onset of treatment and stabilised around 6 minutes, and in the left eye it decreased from 6 minutes to 3 minutes, therefore showing the same effect as the Snellen visual acuity. Visual acuity stabilised around 20/160 right eye and 20/64 left eye for 7 months and then decreased again (see Fig 1). Fluorescein angiography did not reveal any significant changes in cystoid macular oedema as documented before, during, or after therapy.

Ten months after the first treatment we decided to repeat it, which resulted again in a considerable improvement of visual acuity to more than 20/64 right eye and 20/40 left eye (Fig 1). This time no change in the pattern of the visual evoked potential could be documented. Seven months after this repeated treatment the visual acuity had gradually decreased to 20/200 right eye and 20/64 left

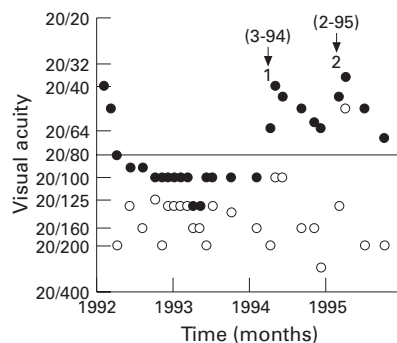


Figure 1 Change in best corrected visual acuity, as log minimal angle of resolution, as influenced by treatment with hyperbaric oxygen. Open circles indicate right eye and closed circles indicate left eye; arrow 1 indicates first treatment and arrow 2 indicates second treatment.

eye. Again, fluorescein angiography showed no changes of macular oedema.

**COMMENT**

Hyperbaric oxygen has many effects on ocular functions: it is known to influence ocular oxygenation and blood flow in several experimental studies. Human visual function has been influenced by this treatment—for example, contrast sensitivity, visual field, and dark adaptation. It is also used therapeutically in patients with mucormycosis of the orbit, periorbital reconstruction, and radiation induced optic neuropathy.<sup>8</sup>

Several reports have shown the favourable influence of hyperbaric oxygen treatment in cystoid macular oedema of various causes but none of these reports describe results over a period longer than 3 months.<sup>4-7</sup> We demonstrated that this treatment had a positive and reproducible effect on the visual acuity of a patient with long standing cystoid macular oedema caused by uveitis. This effect lasted up to 7 months and post-treatment visual acuity of the better left eye never reached values as low as the 2 years before oxygen treatment. The visual improvement in our patient was asymmetrical, probably because of coexisting ischaemia.

This case illustrates that hyperbaric oxygen can be a valuable adjuvant in patients with sight threatening macular oedema.

M S A SUTTORP-SCHULTEN  
F C C RIEMSLAG  
A ROTHOVA

Netherlands Ophthalmic Research Institute,  
Amsterdam, the Netherlands

A J VAN DER KLEY  
Department of Surgery, Academic Medical Center  
Amsterdam, the Netherlands

F C C RIEMSLAG  
Department of Ophthalmology, Academic Medical  
Center Amsterdam, the Netherlands

Correspondence to: M S A Suttorp-Schulten, MD,  
Netherlands Ophthalmic Research Institute, PO Box  
12141, 1100 AC Amsterdam, the Netherlands.

Accepted for publication 15 November 1996

1 Rothova A, Suttorp-Schulten MSA, Treffers WF, Kijlstra A. Causes and frequency of blindness in

patients with intraocular inflammatory disease. *Br J Ophthalmol* 1996;80:332-6.

2 Dick AD. The treatment of chronic uveitic macular oedema. *Br J Ophthalmol* 1994;78:1-2.

3 Suttorp-Schulten MSA, Feron E, Postema F, Kijlstra A, Rothova A. Macular grid laser photocoagulation in uveitis. *Br J Ophthalmol* 1995;79:821-4.

4 Pfoff DS, Thom SR. Preliminary report on the effect of hyperbaric oxygen on cystoid macular oedema. *J Cataract Refract Surg* 1987;13:136-40.

5 Benner JD, Xiaoping M. Locally administered hyperoxic therapy for aphakic cystoid macular oedema. *Am J Ophthalmol* 1992;113:104-5.

6 Miyake Y, Awaya S, Takahashi H, Tomita N, Hirano K. Hyperbaric oxygen and acetazolamide improve visual acuity in patients with cystoid macular oedema by different mechanisms. *Arch Ophthalmol* 1993;111:1605-6.

7 Ogura Y, Takahashi M, Ueno S, Honda Y. Hyperbaric oxygen treatment for chronic cystoid macular oedema after branch retinal vein occlusion. *Am J Ophthalmol* 1987;103:301-2.

8 Butler C. Diving and hyperbaric oxygen. *Surv Ophthalmol* 1995;39:347-66.

**Sarcoidosis presenting as a cutaneous eyelid mass**

EDITOR.—Sarcoidosis is a multisystem granulomatous disorder of unknown aetiology, most commonly affecting young adults and presenting most frequently with bilateral lymphadenopathy, with or without pulmonary infiltration, and with skin or eye lesions. Cutaneous involvement is present in 25% of patients with chronic sarcoidosis and 11% of patients without ocular sarcoidosis.<sup>1</sup> We report a patient with unilateral palpebral sarcoid but without any other evidence of ocular or cutaneous sarcoidosis.

**CASE REPORT**

A 65-year-old woman presented with a large, firm non-tender cutaneous mass involving the left lateral canthus (Fig 1). It had developed over a 6 week period. The lesion first presented in the lateral quarter of the left upper lid and then extended to the lower lid.

She denied any systemic symptoms and physical examination was unremarkable. Ophthalmic examination showed a best corrected visual acuity of 6/6 in each eye. A discrete, large, prominent cutaneous mass without erythema was present in the lateral canthus, involving the upper and lower eyelids. Results of slit-lamp and fundus examination were normal. A biopsy specimen of the mass was obtained. Microscopic examination revealed the presence of non-caseating granulomata of epithelioid cell type with multinucleate cells (Figs 2 and 3). Stains for acid fast bacilli and

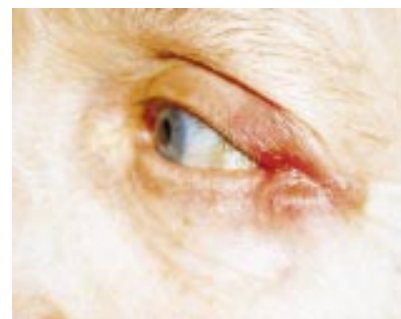


Figure 1 Cutaneous mass involving the lateral canthus, the upper and lower lid.

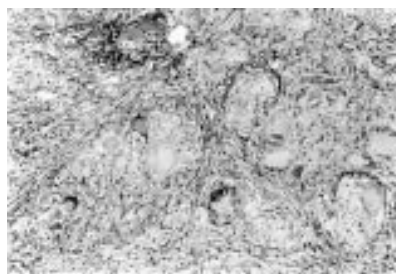


Figure 2 Discrete granulomata occupy the entire dermis in the incisional biopsy.

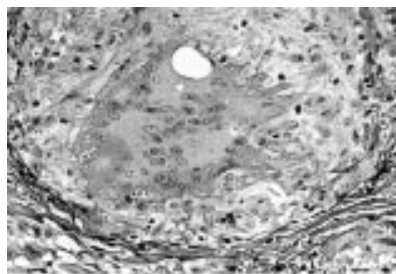


Figure 3 Typical sarcoid granulomata with epithelioid and multinucleate cells.

fungi were negative. Serum angiotensin converting enzyme (ACE) level was 113 U/l (range 3–75 U/l). A skin test with purified protein derivative (PPD) was non-reactive. Chest x ray showed the presence of an enlarged lobular contour at the right hilum indicating lymph node enlargement and some non-specific opacification in the right mid zone suggestive of pulmonary infiltration or scarring (grade II involvement).

The lesion remained unchanged for several months as treatment was delayed in the hope that spontaneous resolution would occur. However, in the absence of any significant change, the lesion was injected with Depo-Medrone (methylprednisolone), which produced a reduction in size. Despite this, a repeat biopsy after 9 months revealed persistence of active granulomatous reaction.

#### COMMENT

In this case sarcoidosis was diagnosed on the basis of histological evidence of non-caseating granulomata, negative culture for acid fast bacilli or fungi, the high serum level of ACE, anergy to PPD, and routine chest roentgenography.

The prevalence of ophthalmic manifestation in sarcoidosis is 22%.<sup>1</sup> Ocular involvement includes anterior and posterior uveitis, secondary glaucoma, cataracts, lesions of lacrimal gland, conjunctiva, cornea, sclera, and optic nerve.<sup>2</sup> Eyelid nodules are present in 3% of the patients with chronic sarcoid.<sup>3</sup> The most common manifestations are small papules,<sup>1</sup> though papular eruptions, larger nodules, lupus pernio, ulcerated nodules, and plaques and swollen eyelids have been reported.<sup>2</sup> The ocular and adnexal involvement is more easily recognised in a patient with known sarcoidosis. The localised eyelid involvement seen in our patient, as a presenting feature of sarcoidosis, is an unreported finding.

Intralesional corticosteroid injection appears to be the only useful treatment of cosmetically disfiguring sarcoid eruptions.<sup>4</sup> Recurrence of cutaneous lesions after treatment with systemic corticosteroid therapy has been reported before.<sup>2</sup>

MATTEO CACCIATORI  
Department of Ophthalmology, Princess Alexandra Eye Pavilion, Edinburgh

KATHRYN M MCLAREN  
Department of Pathology, University of Edinburgh

PATRICK P KEARNS  
Department of Ophthalmology, Princess Alexandra Eye Pavilion, Edinburgh

Correspondence to: Dr Patrick Kearns, Princess Alexandra Eye Pavilion, Chalmers Street, Edinburgh EH3 9HA.

Accepted for publication 15 November 1996

- Hall JG, Cohen KL. Sarcoidosis of the eyelid skin. *Am J Ophthalmol* 1995;119:100–1.
- Brownstein S, Liszauer AD, Carey WD, Nicolle DA. Sarcoidosis of the eyelid skin. *Can J Ophthalmol* 1990;25:256–9.
- Jabs DA, Johns CJ. Ocular involvement in sarcoidosis. *Am J Ophthalmol* 1986;102:297–301.
- Bersani TA, Nichols CW. Intralesional triamcinolone for cutaneous palpebral sarcoidosis. *Am J Ophthalmol* 1985;99:561–2.

#### Orbital metastasis from carcinoma of cervix

EDITOR,—The sites of primary tumour metastatic to the orbit have been well documented by several major surveys. Metastatic breast, lung, and prostate carcinoma account for most of the orbital metastases.<sup>1–7</sup> To our knowledge, orbital metastasis from carcinoma of the cervix has not been described before. We report a 46-year-old Chinese woman in whom orbital metastasis developed 4 months after she was diagnosed to have squamous carcinoma of the cervix.

#### CASE REPORT

A 46-year-old Chinese woman was diagnosed to have squamous cell carcinoma of the cervix FIGO stage IIB in February 1993. She received radiation therapy to the pelvis from 16 March to 22 April 1993. She started to develop a right proptosis in June and presented to us in late October 1993 (Fig 1). Ocular examination showed a visual acuity of 6/24 right and 6/9 left with normal colour vision. Hertel's exophthalmometer confirmed the right proptosis (23 mm right, 15 mm left). Ocular movement was limited in all directions of gaze. Intraocular pressures were 25 mm Hg right and 18 mm Hg left. The pupillary reactions were normal. Fundus examination did not reveal any disc swelling. Computer tomography of the orbit revealed a mass with its epicentre in the lateral orbital wall, within the greater wing of the right sphenoid bone; the mass had extended into the orbit, deviating the lateral rectus muscle and compressing the optic nerve at the orbital apex. It also extended into the anterior aspect of middle cranial fossa and the right frontal sinus (Fig 2). One week later, she presented with

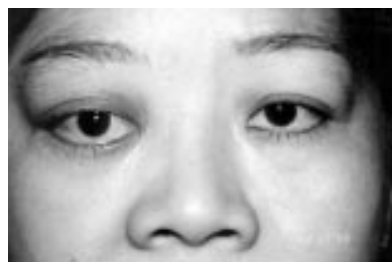

Figure 1 Frontal view of the patient. Note the right proptosis.

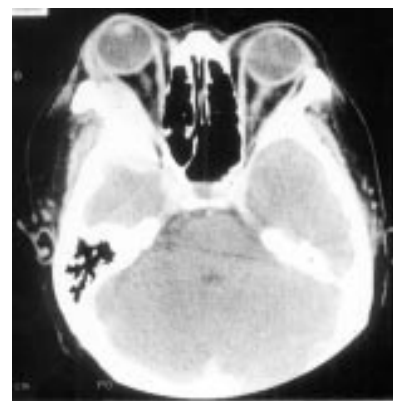

Figure 2 Computed tomography scan showing right lateral orbital mass extending into the orbit, deviating the lateral rectus muscle, and compressing the optic nerve at the orbital apex. The mass has also extended into the anterior aspect of middle cranial fossa and the right frontal sinus.

severe right proptosis and sudden loss of vision in the right eye. Ocular examination showed a vision of no light perception in the right and 6/9 in the left. Right relative afferent pupillary defect was present. Emergency lateral canthotomy and inferior cantholysis followed by tarsorrhaphy were performed for the right proptosis. Fine needle biopsy of the right orbital tissue showed scattered sheets of malignant epithelial cells with hyperchromatic, pleomorphic nuclei and abundant but non-keratinising cytoplasm, consistent with the diagnosis of a large cell non-keratinising carcinoma from the cervix (Fig 3). The patient subsequently received a low dose radiation therapy to the orbit from 22 November to 3 December 1993. Her proptosis improved, but her right vision remained at that of no light perception. She died in February 1994.

#### COMMENT

Malignant neoplasm from a distant primary site generally metastasises by haematogenous route to the orbit in which lymphatic channels are absent.<sup>1</sup> Several major surveys have shown that breast, lung, and prostate carcinoma comprise the largest groups of metastatic cancer to the orbit with occult primary tumour also forming a significant proportion.<sup>1–7</sup> To our knowledge, orbital metastasis from carcinoma of the cervix has not been reported before even though carcinoma of the cervix is one of the commonest tumours in women.<sup>8–10</sup>

Proptosis and motility disturbance are the commonest presenting symptoms and signs of orbital metastasis.<sup>1–7</sup> The onset of symptoms is typically rapid, unremitting, and progressive over a few days or months,<sup>7</sup> as demonstrated in our case in which the patient became blind within 4 months of onset of symptoms.

Most patients die within a year of diagnosis of orbital metastasis<sup>1</sup> and our patient is no exception. This case also illustrates the importance of fine needle aspiration biopsy as an adjunctive tool in the diagnosis of orbital metastasis as it is less invasive than open biopsy. Several studies have shown that about a quarter of patients with orbital metastases develop ocular symptoms before the diagnosis of primary neoplasm.<sup>1</sup> Hence a high index of suspicion and good clinical judgment on the part of ophthalmologists are important in leading to an earlier diagnosis of systemic cancer which will have a profound impact on the

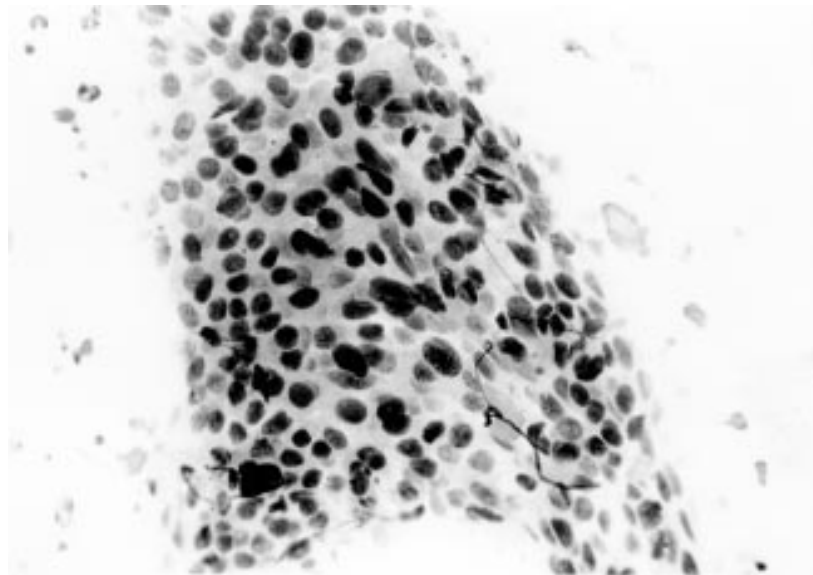


Figure 3 Fine needle aspiration biopsy sample of right retrobulbar mass showing sheets of non-keratinising epithelial cells with pleomorphs and overlapping nuclei. These features are compatible with a large cell non-keratinising carcinoma from the cervix.

patient's prognosis. This case suggests that screening for malignancy of the cervix might be useful as part of the systemic examination for cases of orbital metastases without known primary tumour sites.

H M LEE  
C T CHOO

Singapore National Eye Centre

W T POH

Department of Pathology, Singapore General Hospital

Correspondence to: Choo Chaiteck, Singapore National Eye Centre, 11, Third Hospital Avenue, Singapore 168751.

Accepted for publication 4 November 1996

- Shields CL, Shields JA. Metastatic tumors to the orbit. *Int Ophthalmol Clin* 1993;33:189–202.
- Shields CL, Shields JA, Peggs M. Tumors metastatic to the orbit. *Ophthalmic Plast Reconstr Surg* 1988;4:73–80.
- Bullock JD, Yanes B. Metastatic tumors of the orbit. *Ann Ophthalmol* 1980;12:1392–4.
- Albert DM, Rubenstein RA, Scheie HG. Tumor metastases to the eye. I Incidence in 213 adult patients with generalized malignancy. *Am J Ophthalmol* 1967;63:723–32.
- Shields JA, Bakewell B, Angsbuerg JJ, Flanagan JC. Classification and incidence of space-occupying lesions of the orbit. A survey of 645 biopsies. *Arch Ophthalmol* 1984;102:1606–11.
- Ferry AP, Font RL. Carcinoma metastatic to the eye and orbit. I A clinicopathologic study of 227 cases. *Arch Ophthalmol* 1974;92:276–86.
- Goldberg RA, Rootman J, Cline RA. Tumors metastatic to the orbit: a changing picture. *Surv Ophthalmol* 1990;35:1–24.
- Badib AO, Kurohara SS, Webster JH, Pickren JW. Metastasis to organs in carcinoma of the uterine cervix: influence of treatment on incidence and distribution. *Cancer* 1968;21:434–9.
- Carlson V, Delclos L, Fletcher GH. Distant metastasis in squamous cell carcinoma of the uterine cervix. *Radiology* 1967;88:961–6.
- Lee HP, Chia KS, Shanmugaratnam K. Cancer incidence in Singapore 1983–1987 Cancer Registry.

### 'Pogs and slammers': ocular injury caused by a new game

EDITOR,—'Pogs and slammers' is a very popular new game among children. 'Pogs' are round pieces of thick card, and 'slammers' are round or serrated edged pieces of plastic or metal, both of which are decorated with pictures or symbols (Fig 1). The 'pogs' are placed on the ground or any flat surface and

the aim of the game is to hit them with the 'slammers' in an attempt to turn them over. In order to achieve this, children throw the 'slammers' with great force against the ground causing them to bounce back, frequently at high speed. Such repelled 'slammers' acting as missiles could potentially injure either player or bystander. A case of serious ocular injury caused by this new game is described.

#### CASE REPORT

A 10-year-old girl presented to the eye casualty department complaining of decreased vision in her left eye. She had been hit in that eye by a bouncing metallic 'slammer' a few hours earlier as she was walking past an area where some other children were playing 'pogs and slammers'. On examination, her visual acuity (VA) was 6/6 in the right eye and 6/36 in the left. The left eye had two linear corneal abrasions and a microhyphaema in the anterior chamber (AC). The intraocular pressure (IOP) was 19 mm Hg, pupillary reactions were normal, and there were no signs suggestive of perforating eye injury. Funduscopy through the dilated pupil revealed a vitreous haemorrhage which obscured detailed fundus examination but the retina was flat. Examination of the right eye was unremarkable. She was treated conservatively with topical betamethasone/neomycin and atropine drops and bed rest was recommended. Upon review 2 weeks later, her left VA was 6/36 improving to 6/18 with pinhole, the cornea was clear, and the AC was quiet. The IOP remained normal but a central area of anterior subcapsular lens



Figure 1 'Pog' (left), metallic serrated edged 'slammer' (right), and 50 pence coin (middle) for size comparison.

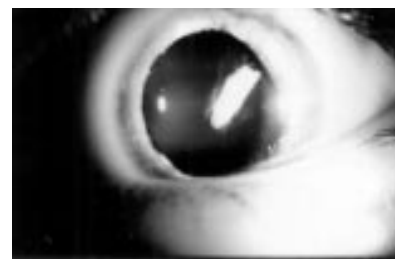

Figure 2 Anterior subcapsular lens opacity.

opacity was noted (Fig 2). The vitreous haemorrhage had settled and allowed complete retinal examination which was normal and the treatment was discontinued. On her last visit 3 months after the injury, her VA was 6/6 in the right eye and 6/24 improving to 6/18 with the pinhole in the left. The vitreous haemorrhage resolved and the retina remained flat. However, she still has a cataract for which no action has been taken but it is thought that surgery may be required in the future.

#### COMMENT

Eye injuries are a leading cause of monocular blindness in children, and often result in significant ocular morbidity less serious than blindness.<sup>1</sup> Studies have shown that children are disproportionately liable to severe ocular injuries<sup>2,3</sup> many of which are preventable<sup>4,5</sup> and usually occur in school age children.<sup>3,6</sup> It is known that such injuries frequently result from playing with a dangerous toy<sup>3,6,9</sup>; however, few reports are available on toys potentially hazardous to the eye.<sup>8,9</sup> In the USA, the Department of Health found toys to be responsible for approximately 600 000 injuries per year<sup>10</sup> which stresses the importance of reporting such injuries.

This case describes the first reported incident of an ocular injury caused by 'pogs and slammers'. The injury resulted in permanent visual impairment due to blunt trauma and cataract formation, but there is also clearly a risk of penetrating eye injury associated with the use of slammers with serrated edges. This report emphasises the potential risk and severity of eye injuries caused by this popular game, and underlines the need for better education to prevent such ocular hazards.

N G ZIAKAS  
A S RAMSAY  
M P CLARKE  
K P STANNARD

Department of Ophthalmology, Royal Victoria Infirmary, Newcastle upon Tyne

Correspondence to: N G Ziakas, Department of Ophthalmology, Royal Victoria Infirmary, Newcastle upon Tyne NE1 4LP.

Accepted for publication 20 November 1996

- National Society to Prevent Blindness. Fact Sheet. New York: National Society to Prevent Blindness, 1980.
- Schein OD, Hibberd PL, Shingleton BJ, Kunzweiler T, Frambach DA, Seddon JM, et al. Spectrum and burden of ocular injury. *Ophthalmology* 1986;95:300–5.
- Macewen CJ. Eye injuries: a prospective survey of 5671 cases. *Br J Ophthalmol* 1989;73:888–94.
- Nelson LB, Wilson TW, Jeffers JB. Eye injuries in childhood: demography, etiology, and prevention. *Pediatrics* 1989;84:438–41.
- Strahlman E, Elman M, Daub E, Baker S. Causes of pediatric eye injuries: a population-based study. *Arch Ophthalmol* 1990;108:603–6.
- Grin TR, Nelson LB, Jeffers JB. Eye injuries in childhood. *Pediatrics* 1987;80:13–7.
- LaRoche GR, McIntyre L, Schertzer RM. Epidemiology of severe eye injuries in childhood. *Ophthalmology* 1988;95:1603–7.

- 8 Maltzman BA, Pruzon H, Mund ML. A survey of ocular trauma. *Surv Ophthalmol* 1976;21:285-90.
- 9 Charteris DG. Ocular injuries caused by a suction toy. *J R Coll Surg Edinb* 1989;34:338-9.
- 10 Centers for Disease Control. Toy safety—United States 1983. *MMWR* 1984;33:697-8.

### Canalicular stenosis in the course of primary herpes simplex infection

EDITOR.—Herpetic canaliculitis is rare. A report in the British literature suggests, however, that it is more common than is generally appreciated.<sup>1</sup> The condition has been recognised as a distinct clinical entity only recently.<sup>2</sup> Bouzas<sup>3</sup> found canalicular involvement in one out of 12 patients with primary ocular herpes simplex infection and estimated the incidence at about 8%. Among 130 cases of canalicular obstruction Coster and Welham<sup>4</sup> considered herpes simplex infection the responsible agent in 20 cases, being 15%. We would like to report on an additional two cases of stenosis of the lacrimal canaliculi in the course of primary herpes simplex infection.

#### CASE REPORTS

The cases were virtually identical except for the age of the patients, respectively 14 and 12 years, and the eyes involved, respectively the right and the left eye. Both patients presented with a primary herpes simplex infection. On the skin of the eyelids and on the lid margin vesicles surrounded by a hyperaemic area were observed (Fig 1).

Initially, the content of the vesicles was transparent, but later the intravesicular fluid became turbid and after rupture of the vesicles, ulcers, and crusts, particularly on the lid margin, developed. There was oedema of the eyelids and preauricular lymphadenopathy as well as a follicular conjunctivitis and epithelial keratitis with lacrimation.

Herpes simplex type 1 virus was isolated in both cases. Lacrimation persisted well beyond the resolution of the acute inflammatory signs and therefore canalicular obstruction was sus-

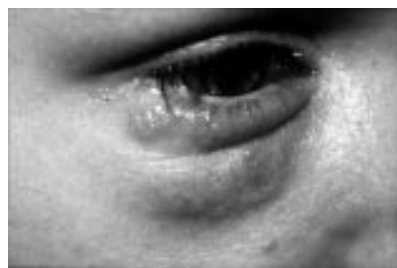

Figure 1 Primary herpes simplex infection in a 14-year-old girl.

Table 1 Characteristics of all patients documented with stenosis of the canaliculi as a result of primary herpes simplex infection

Author	Year	Number	Sex		Age		Culture positive
			M	F	<20	>20	
Bouzas <sup>2</sup>	1965	1	?	?	—	1	—
Sanford-Smith <sup>7</sup>	1970	1	—	1	1	—	—
Bouzas <sup>3</sup>	1973	4	—	—	?	?	—
Coster <sup>1</sup>	1979	20	3	17	19	1	3
Harris <sup>5</sup>	1981	5	—	5	4	1	1
de Koning <sup>8</sup>	1983	6	—	6	6	—	6
Jager	1996	2	—	2	2	—	2
Total		39	3	31	32	3	12

pected. There appeared to be a stenosis in the upper and the lower canaliculus on the affected side. The stenosis was in the mid portion of the canaliculi starting at about 5 mm from the punctae.

Up until now a total of 37 cases of canalicular stenosis in the course of primary herpes simplex infection have been reported. In Table 1 the characteristics of the cases are shown. There is a strong preponderance for females to contract stenosis of the canaliculi in the course of a primary herpetic infection. Most patients were under the age of 20 years; this is not surprising as primary herpetic infection is a disease of youth. There are two peaks of the infection; the first is between 0.5 and 5 years. At the age of 5, 60% has been infected with herpes virus. The second peak is in adolescence; at the age of 20 years 90% are infected with HSV.

#### COMMENT

Herpes simplex is an intracellular parasite. The canaliculi have a very narrow lumen, the diameter being estimated to measure 0.5 mm in the horizontal portion, and are lined by non-keratinised stratified squamous epithelium continuous with that of the conjunctiva. Infection of the canalicular epithelium with subsequent exfoliation, apposition of the tissues, inflammatory oedema, and subsequent cicatrization before epithelial regeneration occurs, would result in stenosis.

As stenosis develops during the course of the primary herpes simplex infection, and as the cultures are positive for HSV, there is strong circumstantial evidence that the obstruction is a direct consequence of viral infection of the epithelium of the canaliculi. In fact, Coster and Welham<sup>4</sup> demonstrated, using electron microscopy, in biopsy specimen particles with a size and morphology compatible with HSV.

Freeman *et al*<sup>5</sup> never found total occlusion of the canaliculi in acutely herpes simplex infected rabbits. They doubted, from the lack of ductal epithelial damage in their animal model, the mechanism proposed by Harris *et*

*al*<sup>5</sup> to explain canalicular obstruction. As canalicular obstruction is a well recognised complication of primary herpetic ocular infection in humans it seems more likely that Freeman *et al* did not use a suitable animal model.

Moreover, Kaufman *et al*<sup>6</sup> pointed out that disease patterns in HSV infection were, to a large degree, dependent on strain specific differences in the amount and types of glycoprotein produced, which is manifested by differences in virulence and antigenity.

We believe that the incidence of canalicular stenosis may be higher than can be inferred from the published cases because if only one canaliculus is obstructed the condition probably escapes attention.

We feel very strongly that all patients with ocular primary herpes simplex infection should be prophylactically intubated with silicone lacrimal stents in order to prevent herpetic cicatricial canalicular stenosis.

G V JAGER

Overvecht Ziekenhuis Utrecht

O P VAN BIJSTERVELD

Oogcentrum Houten, Netherlands

Correspondence to: Dr G V Jager, Overvecht Ziekenhuis Utrecht, Parandreef 2, 3563 AZ, Utrecht, Netherlands.

Accepted for publication: 25 November 1996

- 1 Coster DJ, Welham RAN. Herpetic canaliculitis obstruction. *Br J Ophthalmol* 1979;63:259-62.
- 2 Bouzas A. Canalicular inflammation in ophthalmic cases of herpes zoster and herpes simplex. *Am J Ophthalmol* 1965;60:713-6.
- 3 Bouzas A. Virus aetiology of certain cases of lacrimal obstruction. *Br J Ophthalmol* 1973;57:849-51.
- 4 Freeman GM, Biennenstock J, Wong CL, Rawls WE. Canalicular funtion during herpetic keratoconjunctivitis in rabbits. *Arch Ophthalmol* 1983;101:121-4.
- 5 Harris GJ, Hyndiuk RA, Fox MJ, Taugher PJ. Herpetic canalicular obstruction. *Arch Ophthalmol* 1981;99:282-3.
- 6 Kaufman HE, Centifanto-Fitzgerald ED, Varnell BS. Herpes simplex keratitis. *Ophthalmology* 193;90:700-6.
- 7 Sanford-Smith JH. Herpes simplex canalicular obstruction. *Br J Ophthalmol* 1970;54:456-60.
- 8 Koning EWJ de, Bijsterveld OP van. Herpes simplex virus canaliculitis. *Ophthalmologica* 1983;186:173-6.

## CORRESPONDENCE

### Ocular and cerebral trauma in non-accidental injury in infancy

EDITOR.—We read with interest the paper by Green *et al.*<sup>1</sup> We agree with the authors about the importance of ophthalmoscopic examination in the 'battered child syndrome'. However, we feel that some considerations on the pathogenesis should be discussed.

Firstly, we believe, based on personal clinical and not autopsical cases, that there is a possible association between subdural and intraocular haemorrhages. Nevertheless, we want to underline that intraocular haemorrhages could be isolated manifestations in battered child syndrome; sometimes not due to a direct bulbar trauma.<sup>2</sup>

Traumas of various types, even not ocular, may involve the retinal vascular system, as previously described by Purtscher at the beginning of this century.<sup>3</sup>

Several unilateral or bilateral retinopathies similar to those observed by Purtscher have been reported after compressive thoracic injuries (for example, seat belt injuries), head trauma, and violent deceleration.<sup>4-6</sup>

Various pathogenetic mechanisms of these retinal vascular alterations have been reported—sudden rise in intrathoracic venous pressure,<sup>4</sup> arterial angiospasm, retinal vessel occlusion by gas, and lipid embolisms or aggregates of granulocytes.

In the case of shaking, the pathogenesis of retinohoroidal haemorrhage basically can be caused by: (1) transient blood flow arrest due to rapid bending of the neck or rapid movement of the head, both resulting in direct trauma of the carotid-ophthalmic vascular system and/or retinal vasospasm. This mechanism is the same as the one that occurs in some cases of whiplash lesions; (2) acute thoracic compression probably due to a rapid muscular contraction with closed glottis, resembling a Valsalva's manoeuvre. Such compression would give rise to a venous pressure wave transmitted to the eye, as a result of the lack of antireflux valves between the caval vein and the eye. The unilaterality or bilaterality of the symptoms may be explained by the anatomical distribution of the cervical veins and the position of the neck at the moment of shaking; (3) acute thoracoabdominal compression by catching, that leads to an event's sequelae similar to those described in hypothesis (2); (4) a mechanism similar to that causing subdural haemorrhage according to Green *et al.*—namely, the effect of inertial movements of the vitreous body within the eye during cycles of acceleration-deceleration during shaking. Optic nerve sheath haemorrhage is, in their opinion, the result of angular, rotational, or axial movement of the eye about a point in the most anterior part of the optic nerve, posterior to the sclera.

Our hypothesis is based on clinical evidence of similar cases such as choroidoretinal haemorrhages in road accidents (whiplash lesion with and without seat belts).

Therefore, we agree with Green *et al.* about the importance of choroidoretinal haemorrhages as alarm signs for cerebral haemorrhages, but we would like to point out the medicolegal importance of the ocular lesions

without other complications, for suspecting a battered child syndrome, otherwise difficult or impossible to diagnose. We suggest, therefore, that an accurate ophthalmoscopic examination should be mandatory in those cases.

GIOVANNI LIGUORI  
MAURIZIO CIOFFI  
ADOLFO SEBASTIANI

Department of Ophthalmology,  
University of Naples Federico II,  
via S Pansini, 5,  
580131 Napoli, Italy

- Green MA, Lieberman G, Milroy CM, Parsons MA. Ocular and cerebral trauma in non-accidental injury in infancy: underlying mechanisms and implications for paediatric practice. *Br J Ophthalmol* 1996;80:282-7.
- Liguori G, Cioffi M, Sebastiani A. Unilateral retinopathy after whiplash lesion: considerations on pathogenesis and medico legal implications. *Eye* (in press).
- Madsen PH. Traumatic retinal angiopathy. *Acta Ophthalmol* 1965;43:776-86.
- Archer DB, Earley OE, Page AB, Johnston PB. Traumatic retinal angiopathy associated with wearing of car seat belts. *Eye* 1988;2:650-9.
- Archer DB, Earley OE, Page AB, Johnston PB. Retinal vascular alterations following head injury. *Proceedings of the Retina Workshop*. Florence, Italy, May 1986:105-12.
- Jain BK, Talbot EM. Bungee jumping and intraocular haemorrhage. *Br J Ophthalmol* 1994;78:236-7.

### Reply

EDITOR.—The meticulous work of Green *et al.*<sup>1</sup> has provided an important insight into the mechanisms responsible for the ocular signs in fatal non-accidental injury (NAI). While vitreous traction is likely to be a major factor in the pathogenesis of intraocular pathology, such as retinal detachment, there is indirect evidence that intravascular perfusion changes contribute to the characteristic intraretinal and preretinal haemorrhages.

Firstly, haemorrhages of the same appearance and distribution as in NAI, often with vitreous haemorrhages, occur as a result of an acute rise in intracranial pressure (ICP). These signs may be seen in subarachnoid haemorrhage (Terson's syndrome) and with an acute cerebral venous sinus thrombosis. Retinal haemorrhages are thought to occur in these cases because blood flow is occluded in the central retinal vein by the acute rise in ICP as the vein traverses the subarachnoid space in the optic nerve sheath. Flow continues in the central retinal artery, rupturing the preretinal capillary plexuses.<sup>2</sup> An analogous acute rise in central retinal venous pressure may occur in shaking injuries in children. In these cases there is often evidence from ribcage bruising that the child has been gripped around the thorax, preventing venous return while cardiac output continues. This mechanism is thought to explain the occurrence of retinal haemorrhages with prolonged retching or vomiting. Moreover, intracranial pressure may rise acutely in NAI as a result of subarachnoid haemorrhage. Other causes of retinal haemorrhages associated with raised retinal venous pressure include asphyxia and epileptic fits.<sup>3</sup>

Secondly, in acute central retinal vein occlusion, which is usually due to a localised vascular event, deep retinal haemorrhages extending to the periphery are seen. A similar pattern is seen in NAI suggesting a common mechanism via perfusion/pressure changes within the central retinal vein.

We suggest that while vitreous traction forces, as a result of vitreous inertia, may well be

the cause of the more severe ocular injuries such as retinal detachment, changes in retinal venous pressure are a cause of the retrohyaloid, preretinal, and intraretinal haemorrhages.

S J TALKS  
J S ELSTON

Eye Hospital, Radcliffe Infirmary,  
Woodstock Road, Oxford OX2 6HE

- Green MA, Lieberman G, Milroy CM, Parsons MA. Ocular and cerebral trauma in non-accidental injury in infancy: underlying mechanisms and implications for paediatric practice. *Br J Ophthalmol* 1996;80:282-7.
- Troost BD, Glaser JS. Aneurysms, arteriovenous communications and related vascular malformations. In: Glaser JS, ed. *Neuro-Ophthalmology*. 2nd ed. Philadelphia: JB Lippincott, 1990:521.
- Cavanagh N. Non-accidental injury. In: Taylor D, ed. *Paediatric ophthalmology*. Boston: Blackwell, 1990:545-50.

### Authors' reply

EDITOR.—We are grateful to Liguori *et al.* and to Talks and Elston for their helpful comments on our paper on non-accidental injury (NAI) in infancy, in particular those related to the possible effect of increased vascular pressure in the pathogenesis of retinal haemorrhages in this condition.

All of our cases died as a result of their injuries, and we are interested to hear that Liguori *et al.* believe that they have a similar 'possible association between subdural haemorrhage and intraocular haemorrhages' in non-fatal cases of NAI, although it is unclear whether their cases are the result of direct head or eye trauma. It is important to emphasise that in all our cases brain injuries were as a result of indirect trauma, with no evidence of direct trauma either to the head or the eyes.

We agree that it is well established that retinal haemorrhages can be associated with a range of conditions, including subarachnoid haemorrhage (Terson's syndrome) and other causes of raised intracranial pressure; and with raised intraocular or intrathoracic venous pressure, such as in central retinal vein thrombosis or acute thoracic compression injuries (such as may occur if the chest of an infant is compressed during shaking). While we agree that all of these conditions can be associated with choroidal, retinal, and preretinal haemorrhages, the haemorrhages associated with such conditions tend to be most severe in peripapillary areas, and decrease in intensity towards the retinal periphery (with no equatorial sparing); haemorrhages in these conditions are not associated with focal areas of retinal detachment.

In our study we have shown that in NAI due to violent shaking of the child the equatorial zone of the fundus is relatively spared, and that haemorrhages are most frequent and severe at the retinal periphery, followed by peripapillary areas (this distribution is usually easily seen on macroscopic examination of the retina). In addition, however, there are often focal areas of retinal detachment related to haemorrhages, and in the same zonal distribution. In particular, we frequently see a 'compound retinal lesion', consisting of focally coincident subhyaloid (preretinal) haemorrhage, intraretinal haemorrhage, and haemorrhagic retinal micro-detachment in NAI. We believe that such compound retinal lesions, in a distribution which spares equatorial areas, are a highly specific feature of NAI in infants. This particular distribution of haemorrhages and associated retinal detachment indicates, we believe with little

room for doubt, that the primary pathogenesis of the injuries is via vitreoretinal traction. The association of such retinal injuries with subdural haemorrhages strengthens this belief, as these are caused by a similar relative motion of the brain with respect to fixed points of the skull and meninges.

It remains theoretically possible that raised intracranial or intravascular pressure transmitted to intraocular vessels might be a contributory component in the pathogenesis of intraocular haemorrhages in NAI, although this cannot explain either the equatorial retinal zone sparing or focal retinal detachment seen in our series. Talks and Elston argue in their letter that 'changes in retinal venous pressure are a cause of retrohyaloid, preretinal, and intraretinal haemorrhages' but that 'vitreous traction forces, as a result of vitreous inertia, may well be the cause of more severe ocular injuries, such as retinal detachment'. The problem with this argument is that the most severe cases of trauma would also have the haemorrhages associated with less severe trauma and, if the less severe injury is due to raised venous pressure, the equatorial zone would not be spared (see above)—to be so a mechanism of removal of equatorial haemorrhage (seen as part of the distribution of retinal haemorrhages in raised venous pressure) would have to be invoked. A hypothetical combination of raised intravascular pressure and vitreoretinal rotational traction might conceivably lead to very severe haemorrhages affecting all zones of the retina and the vitreous (in extremely severe shaking of an infant), producing haemorrhages similar, perhaps, to those seen in other non-traumatic causes. In such a case, however, areas of haemorrhagic retinal microdetachment in peripheral and peripapillary retina would provide evidence of rotational trauma, and the patient's history would determine whether this was accidental or NAI.

In summary, we believe that overwhelming evidence points towards vitreoretinal traction as the major cause of intraocular injuries in NAI. We agree with Liguori *et al* (as stated in our paper) that accidental causes of whiplash (such as could occur in severe seat belt injuries, head trauma, and violent deceleration) could cause similar ocular injuries, related to similar rotational vitreoretinal traction forces. Raised intracerebral or vascular pressure may be a relatively minor factor contributing to intraocular haemorrhage, but in the absence of vitreoretinal traction does not explain the relative sparing of the equatorial fundus.

Finally, we have recently found (unpublished observations) that some infants dying of head injury due to NAI have, in addition to recent intraocular haemorrhages, areas of Perls' Prussian blue staining of haemosiderin deposits in ocular tissues, indicating earlier episodes of haemorrhage, from which the child recovered. This emphasises the point made by Liguori *et al* in their letter that 'intraocular haemorrhages could be isolated manifestations of "battered child syndrome", presumably due to direct or indirect trauma'.

M A GREEN  
G LIEBERMAN  
C M MILROY  
M A PARSONS

University of Sheffield, Ophthalmic Sciences Unit,  
Royal Hallamshire Hospital, Sheffield S10 2JAF

## OBITUARY

### PHILIP JARDINE

Philip Jardine was born in Edinburgh in 1914 and died in Bristol on the day after his 81st birthday, 4 December 1995. He was an ophthalmic surgeon of distinction. He was a resident in Moorfields (1942–4) under Ida Mann's tutelage. Having obtained his Edinburgh fellowship, his consultant appointment at the Bristol Eye Hospital was delayed by service with the RAF. His 33 years on the staff encompassed many advances to which he contributed. He is remembered for his bilateral cataract surgery; however, he first inserted an intraocular lens in 1951 and passed through a variety of techniques to finish with endocapsular surgery in 1981. An enthusiastic supporter of junior staff, especially the Australasians, he gave constructive support to their research particularly in 1958 on B12 and tobacco amblyopia, and in 1960 work on toxocariasis. He was president of the South Western Ophthalmological Society in 1969–70. His extensive knowledge of literature and mastery of language extended to French and German. This he supplemented with a working knowledge of Russian and Spanish in retirement. His scientific turn of mind became apparent in his prime hobby, gardening, from which he derived great pleasure.

V J MARMION

## NOTICES

### International Symposium on Ocular Tumors

The International Symposium on Ocular Tumors will be held on 6–10 April 1997 in Jerusalem, Israel. Further details: Professor J Pe'er, Tumors, PO Box 50006, Tel Aviv 61500, Israel. (Tel: 972 3 5140000; fax: 972 3 5175674 or 514007.)

### 2nd International and 4th European Congress on Ambulatory Surgery

The 2nd International and 4th European Congress on Ambulatory Surgery will be held at the Queen Elizabeth II Conference Centre, Westminster, London on 15–18 April 1997. Further details: Congress Secretariat, Kite Communications, The Silk Mill House, 196 Huddersfield Road, Meltham, West Yorkshire HD7 3AP. (Tel: +44 1484 854575; fax: +44 1484 854576.)

### Second European Forum on Quality Improvement in Health Care

The Second European Forum on Quality Improvement in Health Care will take place

on 24–26 April 1997 in Paris, France. The forum will consist of one day teaching courses, invited presentations, posters and presentations selected from submissions, and a scientific session. Further details: BMA, Conference Unit, PO Box 295, London WC1H 9TE. (Tel: +44 (0) 171 383 6478; fax: +44 (0) 171 383 6869.)

### Association for Research in Vision and Ophthalmology (ARVO)

The Association for Research in Vision and Ophthalmology (ARVO) is holding its annual meeting on 11–16 May 1997 at the Fort Lauderdale Convention Center, Fort Lauderdale, Florida, USA. Further details: ARVO, 9650 Rockville Pike, Bethesda, MD 20814-3998. (Tel: (301) 571-1844; fax: (301) 571-8311.)

### 30th Panhellenic Ophthalmological Congress

The 30th Panhellenic Ophthalmological Congress organised by the Hellenic Ophthalmological Society will be held at the Astir Palace Hotel, Vouliagmeni on 28 May to 1 June 1997. Further details: T Kouris, CT Congress, Creta Travel, 19 Amerikis 106 72 Athens, Greece. (Tel: (01) 3607 120, 3635 104; fax: 3603392.)

### Conferences on Angiography in Créteil

A conference on clinical cases in ICG will be held on 9 June 1997 at the University of Créteil. Further details: Professor Gisèle Soubrane, Clinique Ophthalmologique Universitaire de Créteil, 40 Avenue de Verdun, 94010 Créteil Cédex, France. (Tel: 45 17 52 22.)

### British Council International Seminar

A British Council international seminar (number 97031) entitled 'Corneal and external eye disease: new surgical techniques' with Professor D L Easty as director will be held on 29 June to 5 July 1997 in Bristol, UK. The seminar will be of particular interest to all young eye surgeons from the developing and developed world. Further details: Promotions Manager, International Seminars, The British Council, 1 Beaumont Place, Oxford OX1 2PJ, UK (Tel: +44 (0) 1865 316636; fax: +44 (0) 1865 557368/516590; E-mail: International.Seminars@britcoun.org)

### European Association for the Study of Diabetic Eye Complications (EASDEC)

The 7th meeting of EASDEC will be held on 18–19 July 1997 at the Okura Hotel, Amsterdam, the Netherlands, as a pre-congress symposium of the 16th International Diabetic Federation (IDF) congress. Further details: Professor BCP Polak, Rotterdam Eye Hospital, PO Box 70030, 3000 LM Rotterdam, the Netherlands. (Fax: (31) 10 4017655.)

### Continuing Medical Education

The 17th annual current concepts in ophthalmology will be held on 25–27 July 1997 at the San Diego Marriott Mission Valley, San

Diego, California, USA. Further details: Marie Krygier, Medical Education Coordinator, San Diego Eye Bank, 9444 Balboa Avenue, Suite 100, San Diego, CA 92123, USA. (Fax: (619) 565-7368.)

#### **5th International Symposium on Ocular Circulation and Neovascularisation**

The 5th International Symposium on Ocular Circulation and Neovascularisation will be held on 15–19 September 1997 in Kyoto, Japan. Further details: Professor Dr Masanobu Uyama, Secretary General of the Organising Committee, Department of Ophthalmology, Kansai Medical University, Moriguchi, Osaka 570, Japan. (fax: 81-6-997-3475.)

#### **2nd International Symposium on ARMD**

The 2nd International Symposium on ARMD will be held at Glasgow University, Scotland under the auspices of the Royal College of Ophthalmologists on 16–18 September 1997. Further details: Dr G E Marshall, Eye

Department, Western Infirmary, 38 Church Street, Glasgow G11 6NT, UK. (Tel: 0141 211 2094; fax: 0141 339 7485; email: gem1b@clinmed.gla.ac.uk)

#### **6th International Paediatric Ophthalmology Meeting**

The 6th International Paediatric Ophthalmology Meeting will be held on 24–25 September 1997 in Dublin, Ireland. Topics include grand round, neuro-ophthalmology, strabismus, childhood tumours. Further details: Ms Kathleen Kelly, Suite 5, Mater Private Hospital, Eccles Street, Dublin 7, Ireland. (Tel: +3531 838 4444, ext 1759; fax: +3531 838 6314.)

#### **British and Eire Association of Vitreoretinal Surgeons (BEAVRS)**

A meeting of the British and Eire Association of Vitreoretinal Surgeons (BEAVRS) will be held in Birmingham on 16–17 October 1997. Further details: Mr Graham R Kirkby, consultant ophthalmic surgeon, The Birming-

ham and Midland Eye Centre, City Hospital, NHS Trust, Birmingham B18 7QU. (Tel: 0121-554 3801; fax: 0121-507 6791.)

#### **XXVIIIth International Congress of Ophthalmology**

The XXVIIIth International Congress of Ophthalmology will be held in Amsterdam on 21–26 June 1998. Further details: Eurocongres Conference Management, Jan van Goyenkade 11, 1075 HP Amsterdam, the Netherlands. (Tel: +31-20-6793411; fax: +31-20-6737306; internet <http://www.solution.nl/ico-98/>)

#### **2nd International Conference on Ocular Infections**

The 2nd International Conference on Ocular Infections will be held on 22–26 August 1998 in Munich, Germany. Further details: Professor J Frucht-Pery, Ocular Infections, PO Box 50006, Tel Aviv, 61500, Israel. (Tel: 972 3 5140000; fax: 972 3 5175674 or 5140077.)