

# Correlation between surface water contamination with amoeba and the onset of symptoms and diagnosis of amoeba-like keratitis

William D Mathers, John E Sutphin, James A Lane, Robert Folberg

## Abstract

**Aim**—A seasonal variation was noted in the incidence of amoeba-like keratitis in Iowa. The level of contamination of amoeba in surface water has been found previously to vary on a monthly basis for Tulsa, Oklahoma, a region with a similar climate. It was hypothesised that this seasonal variation in amoeba-like keratitis correlated with the concentration of amoeba in surface water.

**Methods**—The monthly variation in the onset of symptoms was determined and date of diagnosis in 137 cases of amoeba-like keratitis, in Iowa, from January 1993 to the end of December 1996.

**Results**—Over a 4 year period a significant variation was found, on a monthly basis, in the onset of symptoms as reported by the patient. There were two peak periods per year when the onset of symptoms was most frequent: June and November. This corresponded closely with the concentration of amoeba in the ground water reported for a similar region in the mid-west (Tulsa, Oklahoma). A yearly increase was found in the number of cases diagnosed from January 1993 to the end of December 1996.

**Conclusions**—This study supports the hypothesis that the concentration of amoeba in surface water may influence the rate of an amoeba-like keratitis infection.

(Br J Ophthalmol 1998;82:1143–1146)

*Acanthamoeba* is a waterborne pathogen responsible for a wide spectrum of keratitis.<sup>1-4</sup> *Acanthamoeba* keratitis has also frequently been associated with contact lens use.<sup>5-7</sup> We have reported a large increase in the number of cases of keratitis presumed to be *acanthamoeba* since we began, in 1993, to use confocal microscopy combined with epithelial biopsy to make this diagnosis.<sup>8-9</sup> The number of cases we have diagnosed since 1993 has reached 187. Some of these cases clinically resembled typical *acanthamoeba* keratitis while many were considerably less severe. We have labelled these cases “amoeba-like keratitis” in this report since the exact identification of the organisms involved has not been established. Routine histology cannot differentiate between species of *Acanthamoeba* or even reliably identify the type of amoeba involved. We report here a monthly variation, which has been repeated yearly, in the onset of symptoms for

cases of this amoeba-like keratitis at our institution.

A history of exposure to contaminated water has frequently been associated with the onset of *acanthamoeba* keratitis.<sup>10</sup> The concentration of amoeba in the ground water in a region is not likely to be constant over the year if the surface water is subject to significant temperature changes. Oklahoma has a four season climate similar to the referral area of this institution, and a seasonal distribution of pathogenic free living amoeba has been reported for surface water in ponds in that area.<sup>11</sup> We instituted a retrospective study for the period between June 1993 and December 1996 to assess the monthly variation in the onset of symptoms and the date of diagnosis of amoeba-like keratitis at our institution. We proposed the data would verify an association between the seasonal distribution of amoeba in our surface water and the variation per month in the incidence of amoeba-like keratitis.

## Methods

We retrospectively reviewed the records of 137 consecutive patients seen at our institution between January 1993 to the end of December 1996 with the diagnosis of amoeba-like keratitis. For each patient, a careful history had been obtained which permitted us to estimate the date of the onset of symptoms attributable to the amoeba-like keratitis.

All patients were examined in the cornea clinic of the University of Iowa. Following a careful history and complete eye examination, each patient was examined clinically with tandem scanning confocal microscopy.<sup>8-12-13</sup> A record of every confocal examination performed on each patient was made. In each of our positive cases, evidence was obtained, using confocal microscopy, which suggested the presence of amoeba-like organisms. These have previously been described as being highly reflective ovoid objects, usually 10–25 µm in diameter, in the superficial and deep epithelium and sometimes in the anterior stroma.<sup>8-12-14</sup> Occasionally, amoeboid forms were also seen which had an irregular pseudopodal appearance.<sup>15</sup> Following confocal microscopic examination, the epithelium of each patient was biopsied using a Kimura spatula by one of two authors (WDM or JES). The specimen was dragged across a glass slide to dislodge the organism. Each specimen was then fixed in 10% formalin and stained with haematoxylin and eosin. The slides were evaluated in masked fashion by an ophthalmic

University of Iowa  
Hospitals, Department  
of Ophthalmology  
W D Mathers  
J E Sutphin  
J A Lane  
R Folberg

Correspondence to:  
William D Mathers, MD,  
University of Iowa Hospitals,  
Department of  
Ophthalmology, 200  
Hawkins Drive, Iowa City,  
IA 52242, USA.

Accepted for publication  
15 April 1998

Table 1 Summary of confocal examinations for amoeba-like keratitis

	Epithelial biopsy	1993	1994	1995	1996	Total
Total examinations		62	490	754	420	1726
Patients examined		37	249	361	218	865
Confocal positive	no biopsy	18	211	330	100	659
Confocal negative	no biopsy	37	270	356	250	913
Confocal negative	biopsy neg	0	0	0	20	20
Confocal positive	biopsy neg	1	10	8	8	27
Confocal positive	biopsy pos	6	39	60	32	137

pathologist (RF). Organisms were identified as trophozoites if the cytoplasmic borders were sharply defined and the structure contained a nucleus with a well defined karyosome. Cysts were identified on the basis of size and polygonal shape.<sup>16</sup> Some specimens were also stained for the presence of acanthamoeba with calcofluor white or acridine orange.<sup>17,18</sup> Only those patients with histological evidence of amoeba were considered positive for this study.

Specimens from 39 patients were submitted for amoeba culture. Fourteen patients with a clinical history and slit lamp examination consistent with bacterial corneal ulcer were also examined with confocal microscopy and their epithelium was submitted for histological examination for the presence of amoeba. Twenty patients with clinical evidence suggesting amoeba-like keratitis and who were negative for amoeba by confocal microscopy were also subjected to epithelial biopsy

## Results

Between January 1993 and December 1996, we performed and recorded 1726 examinations with the confocal microscope on 865

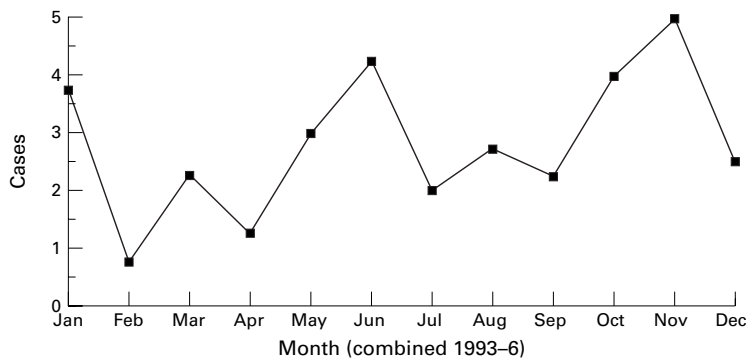


Figure 1 Monthly variation in the date of onset of symptoms of acanthamoeba keratitis reported by the patient.

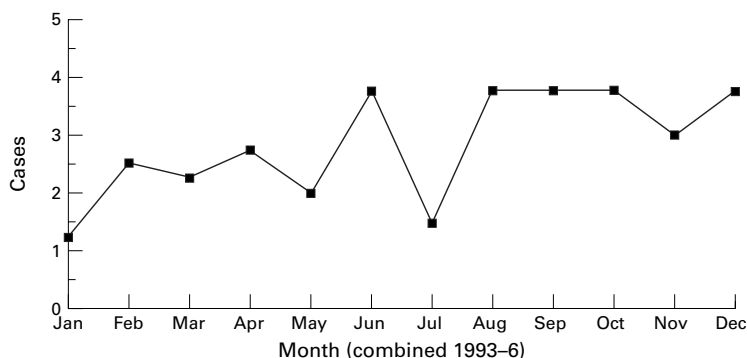


Figure 2 Monthly variation in the date of diagnosis of acanthamoeba keratitis determined clinically.

patients with corneal disease (Table 1). We identified 137 cases that demonstrated a positive identification of amoeba by confocal microscopy and a positive identification of amoeba by epithelial biopsy. There were 659 examinations with confocal microscopy which identified amoeba but no biopsy was performed. Most of these were multiple repeat examinations of patients identified previously as positive for amoeba. There were 913 confocal examinations for amoeba which failed to identify any organisms. Many of these were patients who had been identified as positive and were treated and cured of their infection.

There were 20 patients strongly suspected on the basis of clinical signs and symptoms of having amoeba-like keratitis despite a negative confocal examination. In each of these the epithelial biopsy was also negative. In another 17 patients with clinical evidence of amoeba-like keratitis the confocal examination was positive for amoeba but the epithelial biopsy and histological examination were negative. These were considered negative for amoeba-like keratitis in this study.

To assess the rate of false positive diagnosis of amoeba organisms in bacterial keratitis, 14 corneal ulcers highly suspected to be routine bacterial keratitis were also examined with the confocal microscope. All were negative for amoeba organisms based on the confocal microscopic examination. Each of these 14 epithelial biopsies was also negative for amoeba.

We found a significant variation, using Poisson regression analysis ( $p < 0.0044$ ), in the onset of symptoms per month with February being the lowest month averaging 0.75 cases (range 0-2). The incidence of onset of symptoms per month increased through November with a peak in June which averaged 4.25 (range 2-6) and in November with 5.0 (range 3-8) (Fig 1). We also evaluated the number of cases of amoeba-like keratitis diagnosed per month and found an apparent increase from January to the end of December, the lowest month being January which averaged 1.25 per month and the highest being June, August, October, and December each averaging 3.75 (range 1 to 9) (Fig 2). Based on Poisson regression, the data did not demonstrate a significant difference in the rate of diagnosis for any month.

We also observed an apparent yearly increase in the total number of cases of amoeba-like keratitis diagnosed between 1993 and 1995 based on when the diagnosis was made and also when the symptoms began ( $p < 0.0001$ ) (Table 1). In 1996 the trend did not continue as we found a decrease in the number of patients diagnosed with amoeba-like keratitis based on both the diagnosis and the onset of symptoms. The rate of diagnosis for 1997 has returned to the levels observed for 1995.

The majority of patients reported a short interval, 1 week or less, between the onset of symptoms and our diagnosis of amoeba-like keratitis. However, the range was very large as noted in Table 2. This interval did not change significantly over the period of this study

Table 2 Interval between symptoms and diagnosis in weeks

Year, cases	Mean	Range	< 1 week	>1 week
1993, 6	8	2–26	0	3 (50%)
1994, 39	19	1–175	9 (25%)	17 (4%)
1995, 60	9.7	1–110	20 (33%)	36 (60%)
1996, 132	16.5	1–66	13 (40%)	18 (50%)

despite our heightened clinical awareness of this diagnosis. In three cases, it was not possible to determine when the symptoms associated with amoeba-like keratitis began. Each of these patients had a history consistent with herpes simplex keratitis, which could not be differentiated from that caused by the amoeba organism. A calcofluor white stain was positive in two out of two cases examined and acridine orange was positive in four out of seven cases. Of the 39 specimens submitted for amoeba-like culture, two were positive.

Thirty nine per cent (52 patients) diagnosed with amoeba-like keratitis reported contact lens use. An additional 17% (24) of patients noted exposure to contaminated water. This was typically during scuba diving or exposure of their corneas to water from ponds or lakes. Thirty one per cent (43) of patients either presented with the diagnosis of herpes simplex keratitis or were known to have had herpes simplex keratitis previously. Ten per cent (14) of the patients could identify an episode of ocular trauma associated with the onset of their amoeba-like keratitis.

All patients were treated initially with one or more topical medications which included Brolene (propamidine), polyhexylmethyl biguanide, chlorhexidine and some were also treated with oral medications including itraconazole, fluconazole, and natamycin. The majority of patients were cured of their amoeba-like keratitis with only the use of topical medications. Thirteen patients required corneal transplantation and seven of these were found to have organisms typical of *Acanthamoeba* in the resected corneal button. Only one of these was culture positive. *Acanthamoeba* was also identified by electron microscopy in one of these specimens.

### Discussion

*Acanthamoeba* is a waterborne pathogen.<sup>19</sup> It has recently been reported that in sampled aquatic environments from three local ponds in Tulsa, Oklahoma, the presence of amoeba organisms varied on a monthly basis with the highest concentration in spring and autumn.<sup>11</sup> The prevalence of pathogenic free living amoeba in the sampled waters was one pathogen per 3.4 litres of water. In the present study, we report a relation between climate and the onset of symptoms of amoeba-like keratitis. Our lowest incidence of the onset of symptoms occurred in the coldest period of the year and increased from the winter months through the warm summer and autumn. We likewise found two similar peaks in the onset of symptoms; one in the early summer and one in the late autumn, corresponding roughly with the reported bimodal rise in the concentration of

pathogens in the surface water of Tulsa, Oklahoma. This result is consistent with an effect of the environment on the incidence of amoeba-like keratitis.

Fifty six per cent of our cases of amoeba-like keratitis were associated with either contact lens wearing or with some type of water contamination.<sup>8</sup> Both of these could be influenced by amoeba in the environment. Modern water treatment methods are very effective in removing amoeba contamination from municipal water systems. Amoeba contamination is, therefore, not likely to occur simply through a contaminated municipal water supply. As in many other states with large rural populations, much of the water to homes in Iowa is supplied by small wells which are not subject to purification. This remains a potential source of contamination. A yearly variation in temperature should not, however, affect these deep wells and should not lead to the variation in incidence we report here. Surface water is subject to these extreme temperature changes, but how this would lead to contact lens contamination with amoeba is not known. Thus, the precise link between the level of amoeba in surface water and the incidence of amoeba-like keratitis remains obscure.

We also noted a decreased incidence in the number of cases of amoeba-like keratitis in our clinic during 1996. That year the state of Iowa experienced the coolest average temperature since 1917, whereas the rainfall in 1996 in Iowa was approximately normal, ranking 45th out of the last 124 years of state records.<sup>20</sup> We have recently submitted a report associating the flood which occurred in Iowa in 1993 with an increased incidence of amoeba-like keratitis noted in our clinic. A case controlled study, found an increased incidence of referrals for amoeba-like keratitis from counties whose water supply was affected by the severe flooding which occurred during that time in Iowa (in press) We attributed the increased incidence of amoeba-like keratitis over the next several years to possible contamination of the water supply which occurred during this flood and also to our increased ability to detect early cases of amoeba-like keratitis using confocal microscopy. This instrument has permitted identification when only a very small number of organisms are present. This allows one to make a diagnosis sooner and much more easily than would otherwise be possible. It has also raised our clinical suspicion for amoeba as a causative agent for keratitis in patients with other diagnoses such as herpes simplex keratitis.

Very few of our cases have been positive for *acanthamoeba* using standard culturing techniques. Repeated efforts to culture the organism in the microbiology laboratory at the University of Iowa were mostly unsuccessful. Efforts to culture the organism at outside laboratories, including Indiana University, have also proved unsuccessful. In lieu of positive cultures, we have continued to rely on histological examination of the scraped epithelium results to confirm the diagnose and follow patients with this clinical disease. When a

larger piece of tissue was available for examination following corneal transplantation, which occurred in 13 patients, we were able to make a positive identification of amoeba in histological cross section in seven of these cases. This supports our hypothesis that these organisms are present even without positive cultures.

Herpes simplex keratitis was the most common diagnosis for patients included in this study.<sup>1 21 22</sup> We have recently reported a series of nine patients with proven herpes simplex who also demonstrated evidence of amoeba-like keratitis.<sup>23</sup> This should not be unexpected since amoeba is an opportunistic pathogen and likely to invade a compromised epithelium such as that found in patients with herpes simplex keratitis.<sup>24</sup> From these data it is apparent that patients with herpes may also harbour amoeba organisms in their cornea. These dual infections can be difficult to treat effectively without reliable evidence to indicate which disease is active.

It is entirely possible that many of the amoeba organisms we identified are not a known pathogenic species such as *Acanthamoeba culbertsoni* or *polyphagia*. The clinical manifestations we usually found were in many ways similar to typical acanthamoeba keratitis although in many cases the findings remained more stable and were much less severe than expected. In some cases the organism appeared to be present with very little evidence of active clinical disease. We hypothesised that these organisms may be another species of *Acanthamoeba* or even a related species such as *Valkampfia* or *Hartmannella* which have been reported to cause keratitis in humans.<sup>25</sup>

The clinical course of the disease also suggests that our diagnosis of an amoeba-like keratitis is correct. The majority of patients treated for acanthamoeba keratitis showed clinical improvement using standard therapy and ultimately resolved their infection. The findings with the confocal microscope also resolved with therapy.

1 Bacon AS, Frazer DG, Ficker LA, et al. A review of 72 consecutive cases of Acanthamoeba keratitis, 1984–1992. *Eye* 1993;7:719–25.

- 2 Auran JD, Starr MB, Jakobiec FA. Acanthamoeba keratitis. A review of the literature. *Cornea* 1987;6:2–26.
- 3 McCulley JP, Alizadeh HA, Niederkorn JY. Acanthamoeba keratitis. *CLAO* 1995;21:73–6.
- 4 Stehr-Green JK, Bailey TM, Visvesvara GS. The epidemiology of Acanthamoeba keratitis in the United States. *Am J Ophthalmol* 1989;107:331–6.
- 5 Cohen EJ, Buchanan HW, Laughrea PA, et al. Diagnosis and management of Acanthamoeba keratitis. *Am J Ophthalmol* 1985;100:389–95.
- 6 Redford CF, Dart JK, Minassian DC. Risk factors for acanthamoeba keratitis. *BMJ* 1996;312:183.
- 7 Duguid GI, Dart JK, Morlet N, et al. Outcome of Acanthamoeba keratitis treated with polyhexamethyl biguanide and propamidine. *Ophthalmology* 1997;104:1587–92.
- 8 Winchester K, Mathers WD, Sutphin JE, et al. Diagnosis of Acanthamoeba keratitis in vivo with confocal microscopy. *Cornea* 1995;14:10–17.
- 9 Mathers WD, Sutphin JE, Folberg R, et al. Outbreak of keratitis presumed to be caused by Acanthamoeba [see comments]. *Am J Ophthalmol* 1996;121:129–42.
- 10 Seal D, Stapleton F, Dart J. Possible environmental sources of Acanthamoeba spp in contact lens wearers. *Br J Ophthalmol* 1992;76:424–7.
- 11 John DT, Howard MJ. Seasonal distribution of pathogenic free-living amoebae in Oklahoma waters. *Parasitol Res* 1995;81:193–201.
- 12 Mathers WD, Sutphin JE, Folberg R, et al. Outbreak of keratitis presumed to be caused by Acanthamoeba. *Am J Ophthalmol* 1996;121:129–42.
- 13 Cavanagh HD, Petroll WM, Alizadeh H, et al. Clinical and diagnostic use of in vivo confocal microscopy in patients with corneal disease. *Ophthalmology* 1993;100:1444–54.
- 14 Auran JD, Starr MB, Koester CJ, et al. In vivo scanning slit confocal microscopy of Acanthamoeba keratitis. *Cornea* 1994;13:183–5.
- 15 Pfister DR, Cameron MD, Krachmer JH, et al. Confocal microscopy findings of Acanthamoeba keratitis. *Am J Ophthalmol* 1996;121:119–28.
- 16 Newsome AL, Curtis FT, Culbertson CG, et al. Identification of Acanthamoeba in bronchoalveolar lavage specimens. *Diagn Cytopathol* 1992;8:231–4.
- 17 Wilhelmus KR, Osato MS, Font RL, et al. Rapid diagnosis of Acanthamoeba keratitis using calcofluor white. *Arch Ophthalmol* 1986;104:1304–12.
- 18 Gomez JJ, Robinson NM, Osato MS, et al. Comparison of acridine orange and Gram stain in bacterial keratitis. *Am J Ophthalmol* 1988;106:735.
- 19 Visvesvara GS, Stehr-Green JK. Epidemiology of free-living amoeba infections. *J Protozool* 1990;37:25S–3S.
- 20 Hillaker HJ. Iowa preliminary 1996 annual weather summary 17-Ag835CO 24B:1996, 1–2 1996. Des Moines, IA: Department of Agriculture and Land Stewardship (GENERIC) ref type: report.
- 21 Illingworth CD, Cook SD, Karabatsas CH, et al. Acanthamoeba keratitis: risk factors and outcome. *Br J Ophthalmol* 1995;79:1078–82.
- 22 Tay-Kearney ML, McGhee CN, Crawford GJ, et al. Acanthamoeba keratitis: a masquerade of presentation in six cases. *Aust NZ J Ophthalmol* 1993;21:237–45.
- 23 Mathers WD, Goldberg MA, Sutphin JE, et al. Coexistent Acanthamoeba and herpes simplex. *Arch Ophthalmol* 1997;115:714–17.
- 24 Jones DB. Acanthamoeba: the ultimate opportunist? *Am J Ophthalmol* 1986;102:527–30.
- 25 Aitken D, Hay J, Kinnear FB, et al. Amebic keratitis in a wearer of disposable contact lenses due to a mixed *Vahlkampfia* and *Hartmannella* infection. *Ophthalmology* 1996;103:485–94.