

Videofunduscopy and videoangiography using the scanning laser ophthalmoscope in Vogt-Koyanagi-Harada syndrome

Annabelle A Okada, Tsuyoshi Mizusawa, Jun-ichi Sakai, Masahiko Usui

Abstract

Aim—To observe pathophysiological changes in patients with Vogt-Koyanagi-Harada (VKH) syndrome using the scanning laser ophthalmoscope (SLO) to perform videofunduscopy, and indocyanine green (ICG) and fluorescein videoangiography.

Methods—18 patients diagnosed with VKH syndrome were studied. 15 patients were examined in both acute and convalescent phases, and three patients were examined in the convalescent phase only. Retrospective review of charts was performed to obtain data on visual acuities, clinical findings, and results of cerebrospinal fluid cytology and histocompatibility leucocyte antigen D locus testing.

Results—Videofunduscopy revealed abnormalities in the central macula at the level of the retinal pigment epithelium or choroid in 40% of patients in the acute phase and 83% of patients in the convalescent phase. ICG videoangiography showed irregular hypofluorescence (80%), slow or patchy filling (67%), indistinct or fewer choroidal vessels (73%), filling defects (73%), and focal leakage (33%) in patients in the acute phase. These changes improved with systemic corticosteroid treatment, although at least one ICG videoangiographic abnormality persisted into the convalescent phase in 83% of patients in the absence of clinical inflammation. In contrast, fluorescein videoangiography revealed fewer and decreased severity of abnormalities, with greater resolution in the convalescent phase when compared with ICG videoangiography.

Conclusions—SLO videofunduscopy and videoangiography revealed numerous abnormalities in patients with VKH syndrome, many of which persisted well after clinical recovery, suggesting the development of permanent morphological changes in the fundus. ICG videoangiography was more sensitive than fluorescein videoangiography in delineating abnormalities in layers deep to the sensory retina.

(*Br J Ophthalmol* 1998;82:1175-1181)

Vogt-Koyanagi-Harada (VKH) syndrome is a multisystem inflammatory disorder involving aseptic meningitis, skin manifestations such as vitiligo and poliosis, hearing disturbances such as dysacusis and tinnitus, and uveitis.^{1,2} Its

cause is unknown, although the pathogenic mechanism is believed to be autoimmune in nature. In the department of ophthalmology at the Tokyo Medical College Hospital, VKH patients represented 9.1% of all patients followed in the uveitis clinic over a 5 year period from 1989 to 1993.³ The uveitis observed in VKH syndrome generally starts with an iridocyclitis, followed within a few days by the appearance of choroiditis and varying degrees of serous retinal detachment. The eye disease is almost always bilateral, and its onset is frequently preceded by complaints of flu-like symptoms.

Since the primary focus of posterior eye inflammation in VKH syndrome lies in the choroid,^{1,4} it has been difficult to study the pathophysiological mechanisms involved in vivo using conventional fluorescein angiography. Choroidal fluorescence of the dye is blocked by melanin in the retinal pigment epithelium (RPE), and high permeability of the small molecular weight dye results in poor resolution of choroidal vessels. However, the advent of clinical indocyanine green (ICG) angiography has led to improved assessment of choroidal anatomy and choroidal blood flow, because of better visualisation of fluorescence of the ICG dye through the RPE, as well as through overlying blood and/or lipid within the retina.⁵⁻⁹ Moreover, because about 98% of injected ICG molecules are bound to serum proteins, the resulting high molecular weight compound has reduced vascular permeability, allowing for better delineation of the choroidal circulation.⁹

The addition of video technology and use of the scanning laser ophthalmoscope (SLO) have further improved both the spatial and temporal resolution of ICG angiography.¹⁰⁻¹⁴ In particular, the SLO used in the confocal mode has enabled imaging of distinct layers in the fundus, not discernible by conventional fundus photography or observed in many instances on clinical examination.¹⁴ Thus, using the SLO it is easier to identify the depth of a lesion or an angiographic finding, or conversely to observe an abnormality previously undetected because it was non-pigmented and located deep to the sensory retina.

In this study, we used the Rodenstock SLO to perform videofunduscopy and videoangiography in patients with VKH syndrome in acute and convalescent phases. Our purpose was, firstly, to observe findings using the SLO for videofunduscopy and, secondly, to analyse the usefulness of ICG angiographic

Department of
Ophthalmology, Tokyo
Medical College
Hospital, Tokyo, Japan
A A Okada
T Mizusawa
J Sakai
M Usui

Correspondence to:
Annabelle A Okada, MD,
Department of
Ophthalmology, Tokyo
Medical College Hospital,
6-7-1 Nishishinjuku,
Shinjuku-ku, Tokyo 160,
Japan.

Accepted for publication
15 April 1998

Table 1 Patient characteristics and clinical findings

No.	Age	Sex	Initial examination*			Ancillary tests		Last examination		Follow up (months)
			VA RE, LE	AC cells	Posterior findings	CSF cells	HLA-D locus	VA RE, LE	Posterior findings	
1	37	F	20/15, 20/50	-	SRD both eyes	+	DR 4, 9, 53; DQ 3, 4	20/15, 20/20	mild retinal atrophy both eyes	42
2	53	M	20/35, 20/35	+	disc oedema, ME both eyes	+	NE	20/25, 20/25	sunset fundus both eyes, atrophic spot right eye	42
3	43	M	20/70, HM	+	sunset fundus both eyes	NE	DR 4, 6, 52, 53; DQ 4, 6	20/20, CF	sunset fundus both eyes	7
4	25	M	20/200, 20/100	+	disc oedema, SRD both eyes	+	DR 3, 9	20/15, 20/15	sunset fundus, atrophic spots both eyes	39
5	44	F	20/35, 20/35	+	SRD both eyes	+	DR 4, 6, 52, 53; DQ 1, 4	20/20, 20/20	mild retinal atrophy both eyes	8
6	26	M	20/100, 20/40	+	disc oedema, SRD both eyes	+	DR 4, 53; DQ 4	20/15, 20/15	sunset fundus both eyes	20
7	48	F	20/70, 20/15	-	disc oedema, SRD both eyes	+	DR 4, 9, 53; DQ 3, 4	20/20, 20/20	sunset fundus both eyes	34
8	48	M	CF, 20/60	+	ME and CD both eyes	+	NE	20/25, 20/30	sunset fundus, atrophic spots both eyes	34
9	26	F	20/15, 20/60	+	ME left eye	NE	DR 2, 4, 53; DQ 1, 3	20/15, 20/15	mild retinal atrophy both eyes	6
10	30	F	20/50, 20/20	+	SRD both eyes	+	DR 4, 9, 53; DQ 3, 4	20/15, 20/15	mild retinal atrophy both eyes	8
11	57	M	20/100, 20/100	+	sunset fundus both eyes	NE	DR 4, w12	20/25, 20/50	sunset fundus, atrophic spots both eyes	90
12	40	F	20/20, 20/20	+	SRD both eyes	+	DR 4, 53; DQ 4	20/20, 20/20	mild retinal atrophy both eyes	26
13	21	F	20/70, 20/200	+	SRD both eyes	NE	DR 2, 9, 53; DQ 1, 3	20/20, 20/20	sunset fundus both eyes	25
14	63	F	20/400, 20/200	+	SRD, CD both eyes	+	DR 4, 53; DQ 4	20/20, 20/15	sunset fundus both eyes	20
15	25	F	20/50, 20/200	+	disc oedema, SRD both eyes	+	DR 6, 12, 52; DQ 1, 7	20/15, 20/15	sunset fundus, atrophic spots both eyes	20
16	46	M	20/50, 20/60	+	disc oedema, SRD both eyes	+	DR 1, 4, 53; DQ 1, 4	20/25, 20/25	sunset fundus both eyes	16
17	43	F	20/30, 20/35	+	SRD both eyes	+	NE	20/15, 20/20	sunset fundus both eyes	14
18	28	F	20/20, 20/250	+	SRD both eyes	-	DR 4, 9, 53; DQ 3, 4	20/15, 20/60	sunset fundus both eyes	17

VA=best corrected visual acuity; AC=anterior chamber; CSF=cerebrospinal fluid; HLA=histocompatibility leucocyte antigen; SRD=serous retinal detachment; ME=macular oedema; NE=not examined; HM=hand movements; CF=counting fingers; CD=choroidal detachment.

*Initial examination data are for the acute phase in all cases except for in patients 3 and 11 who presented with persistent anterior segment inflammation bilaterally 6 months and 3 years after the onset of uveitis, respectively.

examination in this disease by comparing the SLO based findings of ICG videoangiography with those of fluorescein videoangiography.

Patients and methods

PATIENTS AND CLINICAL DEFINITIONS

Eighteen patients with VKH syndrome (36 eyes) were examined from June 1993 to the end of February 1997 in the uveitis clinic of the department of ophthalmology at the Tokyo Medical College Hospital. Charts were reviewed retrospectively to obtain data on visual acuity (VA), presence or absence of anterior

chamber cells, posterior findings (such as serous retinal detachment, or macular oedema), and results of cerebrospinal fluid (CSF) cytology and histocompatibility leucocyte antigen (HLA) D locus testing. Clinical diagnosis of disease in the "acute phase" was based on the acute onset of choroiditis, serous retinal detachment or disc oedema in both eyes, in association with at least one systemic finding, either auditory (for example, tinnitus or dysacusis) or related to inflammation of the meninges (for example, stiff neck or headache). Presence of inflammatory cells in the anterior chamber was not required for diagnosis, but occurred some time during the acute phase of disease in most patients. The "convalescent phase" was defined as the period of time at least 1 month following the initiation of systemic corticosteroid therapy, at which time there was no evidence of either anterior or posterior segment inflammation by clinical examination.

SLO VIDEOFUNDUSCOPY AND VIDEOANGIOGRAPHY
Before first time videoangiography, patients were routinely given an intradermal test dose of ICG (Daiichi Pharmaceutical, Tokyo, Japan, 2.5 mg in 0.1 ml aqueous solvent) and/or fluorescein (Alcon Japan, Tokyo Japan, 0.1 ml of 10% w/v) as appropriate and monitored for adverse reactions. Examinations were performed using a scanning laser ophthalmoscope (Rodstock Instruments, Munich, Germany, Model 101) in the confocal mode to image the fundus at a rate of 50 frames/second. Videofunduscopy was performed first using argon, helium-neon, and infrared lasers to visualise features in approximately the superficial retina,

Table 2 Summary of SLO videofunduscopy and videoangiographic findings

	No of patients (percentage)		p Value‡
	Acute (n=15)*	Convalescent (n=18)†	
Videofunduscopy			
retinal folds (argon)	13 (87%)	2 (11%)	<0.05
RPE/choroidal abnormality (infrared)	6 (40%)	15 (83%)	<0.05
any abnormality	14 (93%)	16 (89%)	0.570
ICG videoangiography			
irregular hypofluorescence	12 (80%)	2 (11%)	<0.05
slow or patchy filling	10 (67%)	8 (44%)	0.178
indistinct/fewer choroidal vessels	11 (73%)	2 (11%)	<0.05
filling defects	11 (73%)	7 (39%)	0.051
focal leakage	5 (33%)	1 (6%)	0.053
any abnormality	15 (100%)	15 (83%)	0.150
Fluorescein videoangiography			
punctate staining	11 (73%)	7 (39%)	0.051
disc hyperfluorescence	10 (67%)	5 (28%)	<0.05
macular oedema	9 (60%)	4 (22%)	<0.05
subretinal pooling	6 (40%)	0 (0%)	<0.05
focal leakage	4 (27%)	0 (0%)	<0.05
pigment epithelial detachment	2 (13%)	1 (6%)	0.430
any abnormality	15 (100%)	9 (50%)	<0.05

SLO=scanning laser ophthalmoscope; RPE=retinal pigment epithelium; ICG=indocyanine green.

*Data for the acute phase was taken at a mean of 1 week after onset.

†Data for the convalescent phase was taken at a mean of 16 months after onset.

‡Proportions were compared by Fisher's exact test.

deeper retina, and RPE/choroid, respectively. Videoangiography was then performed by injection into the antecubital vein of one dye (either 25 mg ICG in 1.0 ml aqueous solvent, or 5 ml of 10% w/v fluorescein, order determined at random) and SLO imaging for 10 minutes, followed by injection of the other dye and SLO imaging for a further 10 minutes. The resulting data were stored on 8 mm videotape and viewed using a high resolution monitor (Sony, Tokyo, Japan, Model PVM-2045MD). The SLO videofundoscopic and videoangiographic images shown were reproduced from hard copies produced by a multiscan video printer (Sony, Tokyo, Japan, Model UP-930). However, study findings were based on careful examination of videotapes played over real time, and were more striking in all cases compared with hard copy images.

STATISTICAL ANALYSIS

Proportions were compared by Fisher's exact test, and differences between means were analysed by two sided unpaired *t* test. A confidence limit of $p < 0.05$ was considered to be statistically significant.

Results

Table 1 summarises the clinical characteristics of patients included in the study. All patients were admitted to the hospital for systemic corticosteroid therapy. Thirteen of 14 patients in the acute phase examined by lumbar puncture had more than $10^6/l$ of CSF, predominantly lymphocytes in all cases. Of 15 patients tested, 12 (80%) were positive for HLA-DR4, 12 (80%) for DR53, and 10 (67%) for DQ4. For comparison, the frequencies for these HLA haplotypes in the general Japanese population are roughly 42% for DR4, 69% for DR53, and 31% for DQ4.¹⁵ Overall mean follow up was 26 months, and all patients developed some degree of retinal atrophy or frank sunset glow fundus by the time of the last examination. Five of the 18 patients developed atrophic spots in the peripheral retina. All patients recovered good VA with the exception of patient 3 who had a history of amblyopia in the left eye.

Table 2 summarises the results of SLO videofunduscopy and videoangiography for all patients. SLO examination was performed in both acute and convalescent phases in 15 of the

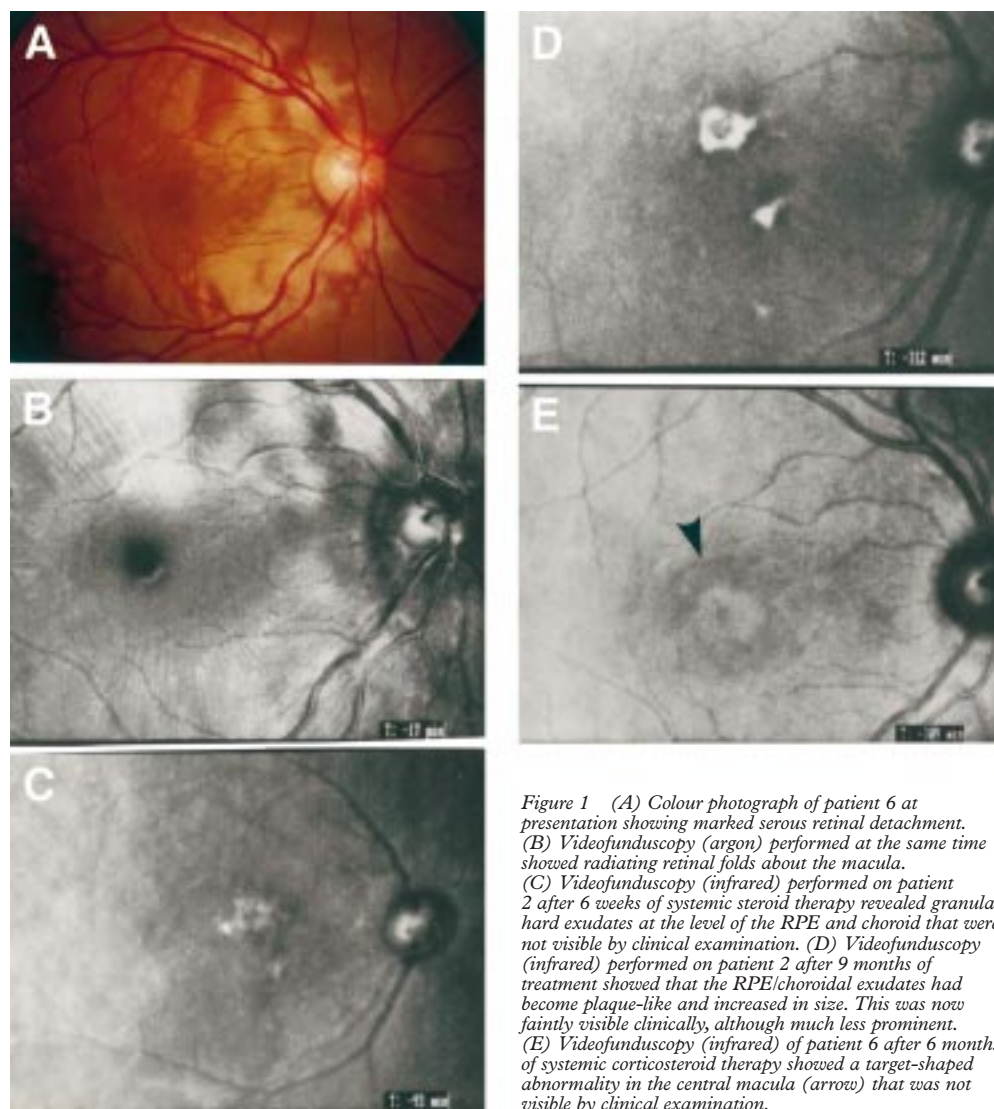


Figure 1 (A) Colour photograph of patient 6 at presentation showing marked serous retinal detachment. (B) Videofunduscopy (argon) performed at the same time showed radiating retinal folds about the macula. (C) Videofunduscopy (infrared) performed on patient 2 after 6 weeks of systemic steroid therapy revealed granular hard exudates at the level of the RPE and choroid that were not visible by clinical examination. (D) Videofunduscopy (infrared) performed on patient 2 after 9 months of treatment showed that the RPE/choroidal exudates had become plaque-like and increased in size. This was now faintly visible clinically, although much less prominent. (E) Videofunduscopy (infrared) of patient 6 after 6 months of systemic corticosteroid therapy showed a target-shaped abnormality in the central macula (arrow) that was not visible by clinical examination.

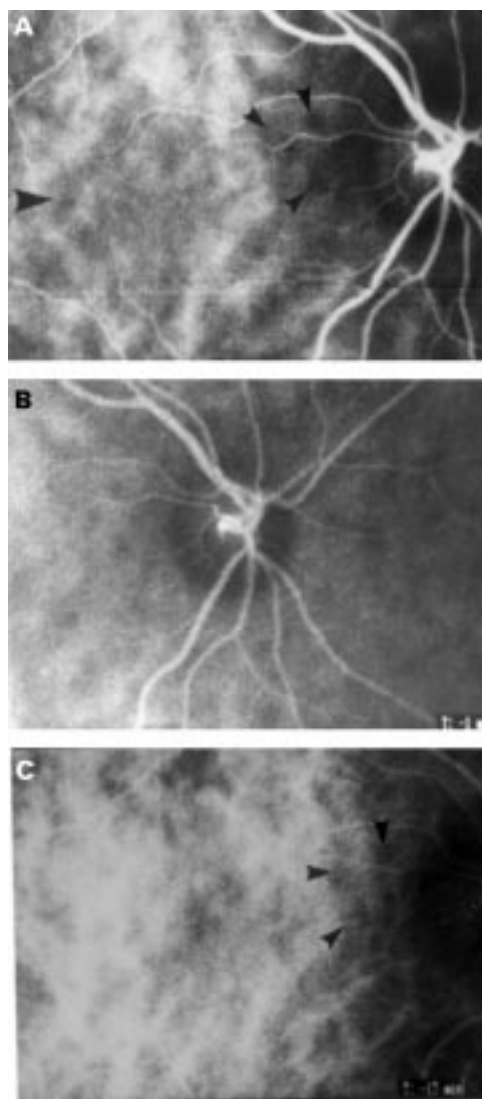


Figure 2 (A) ICG videoangiography performed on patient 6 at presentation revealed irregular hypofluorescence of the central macula (large arrow), corresponding to areas of chorioretinal thickening observed clinically. Numerous filling defects approximately 1/5 disc diameter in size (small arrows) were also present. (B) The filling defects were most prominent surrounding the optic disc. (C) After 6 months of treatment, ICG videoangiography showed marked improvement of the hypofluorescence of the macula but persistence of some filling defects (arrows).

18 patients, and in only the convalescent phase in the remaining three patients (nos 3, 9, and 11). SLO videofunduscopy revealed that, of the 15 patients examined in the acute phase, retinal folds radiating from the central macula (Fig 1A and 1B) were well visualised in 13 patients (87%). In addition, granular exudates at the level of the choroid (Fig 1C) were observed in six patients (40%). In contrast, of the 18 patients examined by SLO videofunduscopy in the convalescent phase, only two patients (11%) showed evidence of residual retinal folds, and these were much less prominent than before. However, 15 patients (83%) revealed either granular, plaque-like, or other subtle abnormalities at the level of the RPE and/or choroid (Fig 1D and 1E), many of which were either not visible or much less prominent by clinical examination.

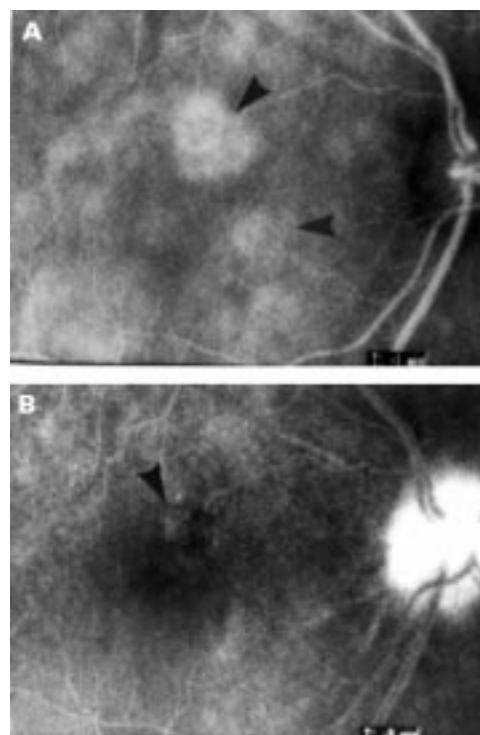


Figure 3 (A) ICG videoangiography of patient 2 in the acute phase showed focal hyperfluorescent areas (arrows). (B) Fluorescein videoangiography taken at the same time showed only faint RPE staining in one area (arrow).

The most frequent finding on ICG videoangiography for patients in the acute phase was widespread irregular hypofluorescence of the macula (Fig 2A, large arrow) seen in early images in 12 of 15 patients (80%). Other related findings included slow or patchy ICG filling in the first minute after ICG injection seen in 67% of patients, and indistinct or fewer choroidal vessels seen in 73% of patients. At least one of these three findings was present in all cases examined during the acute phase of VKH. Filling defects were seen in 73% of patients during the acute phase of disease (Fig 2A, small arrows) and these did not correspond with any fundus lesions by clinical examination. They were observed from the earliest ICG videoangiographic images and remained unchanged in size into the late images, although they became gradually more difficult to distinguish against the fading background fluorescence. Furthermore, the filling defects were particularly prominent about the optic discs (Fig 2B), were better visualised where there was no overlying serous retinal detachment, and were approximately 1/5 disc diameter in size. In some cases, similar filling defects were also present transiently, albeit only faintly seen, during choroidal flush images on fluorescein videoangiography. However, the filling defects always appeared smaller on fluorescein videoangiography when compared with ICG videoangiography, and usually disappeared within the first 1–2 minutes. Focal ICG leakage (Fig 3A, arrows) that increased in size in late images was observed in five of the 15 patients (33%). In each case,

Table 3 Detection of indocyanine green (ICG) versus fluorescein videoangiographic findings

	Mean no of abnormalities*		p Value†
	ICG (n=30 eyes)	Fluorescein (n=38 eyes)	
Acute phase	3.27 (1.01)	2.43 (1.31)	<0.05
Convalescent phase	1.78 (1.05)	1.28 (1.23)	0.060

*Mean number (SD) of abnormal findings out of a total possible of 5 for ICG videoangiography and 6 for fluorescein videoangiography.

†Means were compared by unpaired *t* test.

there was no corresponding leakage seen on fluorescein videoangiography in the same location although RPE staining was occasionally observed (Fig 3B).

The frequency of all ICG videoangiography findings decreased into the convalescent phase, with the most persistent findings being slow or patchy ICG filling, and filling defects (Fig 2C, arrows). However, 15 of the 18 patients (83%) examined in convalescence had the presence of at least one of the ICG videoangiographic abnormalities listed in Table 2. It should be noted that, at this time, there was no clinical evidence of posterior inflammation in any of these patients, and most eyes had developed bilateral sunset glow fundi.

Fluorescein videoangiography in the 15 patients examined in the acute phase revealed punctate staining as the most common finding (73%), followed by disc hyperfluorescence in late angiographic images (67%) and macular oedema (60%). Other less common findings included subretinal pooling (40%), focal leakage (27%), and pigment epithelial detachment (13%). All findings improved with systemic corticosteroid treatment, although nine patients (50%) still showed at least one abnormality by fluorescein videoangiography in the convalescent phase.

Proportions of SLO findings in the acute versus convalescent phases were compared by Fisher's exact test (Table 2). Although the

abnormalities of irregular hypofluorescence and indistinct or fewer choroidal vessels by ICG videoangiography were significantly decreased in the convalescent phase compared with the acute phase, the remaining three ICG abnormalities as well as the proportion of patients with any ICG abnormality were not significantly different. In contrast, four of six fluorescein abnormalities were significantly decreased in the convalescent phase compared with the acute phase, as was the proportion of patients that exhibited any fluorescein abnormality. Table 3 shows the mean number of abnormalities by ICG versus fluorescein videoangiography in the acute and convalescent phases, respectively. Although ICG and fluorescein videoangiographies examine different layers of the fundus and therefore are not equivalent methods, this analysis shows that ICG videoangiography showed a greater mean number of abnormalities in both acute and convalescent phases of disease when compared with fluorescein videoangiography. Finally, Table 4 shows an analysis of ICG and fluorescein abnormalities in two arbitrarily set groups of VA at the time of videoangiographic examination in the acute phase of disease. Compared with eyes with a VA of better than 20/40, eyes with a VA of 20/40 or less had a significantly increased rate of irregular hypofluorescence and filling defects by ICG videoangiography, and subretinal pooling by fluorescein videoangiography.

Discussion

Japanese case reports of ICG angiographic findings in VKH syndrome have shown decreased number of large choroidal vessels, patchy areas of hypofluorescence, delayed filling and large plaques of subretinal staining in patients with acute inflammation.¹⁶⁻¹⁹ A case report from Italy has also shown large hyperfluorescent plaques in the macula.²⁰ However, these studies did not have the advantage of increased visualisation using the SLO. Furthermore, they were limited by examination of too few patients, lack of repeat angiography in the convalescent phase, and/or lack of systematic comparison with findings by fluorescein angiography. One recent study which did utilise the SLO on some but not all patients described macular hypofluorescence in the acute phase by ICG angiography, and suggested that a temporary choroidal circulatory disturbance was occurring with inflammation.²¹

The first goal of the present study was to use the clarity of the SLO to evaluate videofundoscopic images of the macula in a large number of patients with VKH syndrome in acute and convalescent phases. This revealed numerous abnormalities at the level of the RPE and choroid that were either not observed or much less prominent by clinical examination. Despite the lack of any evidence of active inflammation, these abnormalities increased in frequency in convalescence. They may represent either frank fibrosis (as in the case of plaques) or more subtle changes in tissue morphology (as in the case of target lesions).

Table 4 SLO videofundoscopic and videoangiographic findings in the acute phase by visual acuity

	No of eyes (percentage)		p Value‡
	VA >20/40 (n=17)*	VA ≤20/40 (n=13)†	
Videofunduscopy			
retinal folds (argon)	14 (82%)	12 (92%)	0.409
RPE/choroidal abnormality (infrared)	7 (41%)	5 (38%)	0.590
ICG videoangiography			
irregular hypofluorescence	11 (65%)	13 (100%)	<0.05
slow or patchy filling	12 (71%)	8 (62%)	0.446
indistinct/fewer choroidal vessels	13 (76%)	9 (69%)	0.485
filling defects	10 (59%)	12 (92%)	<0.05
focal leakage	5 (29%)	5 (38%)	0.446
Fluorescein videoangiography			
punctate staining	12 (71%)	10 (77%)	0.515
disc hyperfluorescence	11 (65%)	9 (69%)	0.554
macular oedema	9 (53%)	9 (69%)	0.301
subretinal pooling	3 (18%)	9 (69%)	<0.05
focal leakage	3 (18%)	5 (38%)	0.195
pigment epithelial detachment	3 (18%)	1 (7%)	0.409

SLO=scanning laser ophthalmoscope; VA=visual acuity; RPE=retinal pigment epithelium; ICG=indocyanine green.

*Visual acuity better than 20/40 at the time of videoangiography.

†Visual acuity 20/40 or worse at the time of videoangiography.

‡Proportions were compared by Fisher's exact test.

The second goal of this study was to evaluate the usefulness of SLO based ICG videoangiography in VKH syndrome, in comparison with fluorescein videoangiography performed in the same manner. Among findings by ICG videoangiography, eyes in the acute phase showed irregular widespread hypofluorescence, slow or patchy choroidal filling, and indistinct or fewer choroidal vessels similar to previous findings. These were totally undetected by fluorescein videoangiography, and most likely represent different manifestations of the same phenomenon of choroidal oedema and thickening, presumably due to the acute infiltration of inflammatory cells into the choroid known to occur in VKH syndrome.^{1 22 23}

ICG videoangiography in the acute phase of VKH also revealed small filling defects that did not correlate with any clinical fundus lesions. Smaller and less prominent filling defects were also visible transiently in a few VKH eyes by fluorescein videoangiography during the initial choroidal flush and thus these appear to be at the level of the choroid or more specifically the choriocapillaris. Although filling defects can also be observed on ICG videoangiography performed on some healthy individuals, they invariably disappear within the first minute. The filling defects detected by ICG videoangiography in VKH patients persisted unchanged in many cases into the convalescent phase in the absence of active disease, in contrast with a previous report.²¹ We speculate that the choroidal inflammation associated with VKH syndrome may be causing reversible and/or irreversible occlusion of single lobules within the choriocapillaris, each supplied by its own end arteriole.²⁴ Since lobules within the human choriocapillaris have been estimated to be approximately 1/4 disc diameter or less in size (by fluorescein angiography criteria),²⁵ lobular occlusion would theoretically fit with the observation of filling defects seen in this study. A similar hypothesis has been proposed to explain some ICG angiographic findings seen in patients with acute posterior multifocal placoid pigment epitheliopathy.²⁶

Five patients in the acute phase of VKH were also observed to have focal areas of ICG dye leakage that were not seen by fluorescein videoangiography, and thus presumed to be intrachoroidal in location. These lesions resolved in four of the five patients in the convalescent phase, and may represent pools of exudation within intrachoroidal areas of inflammatory cell infiltration. Normally, the large size of serum protein bound ICG molecules would prevent marked leakage from large choroidal vessels, although some leakage through fenestrations in the choriocapillaris might occur.⁵ Frankly visible intrachoroidal leakage on ICG angiography would have to arise from breakdown of vascular integrity of larger choroidal vessels secondary to acute inflammation, and would disappear in many instances with the resolution of inflammation.

Findings by fluorescein videoangiography that were observable in this study were typical for VKH syndrome, and are described in detail elsewhere.^{1 2} Overall, ICG videoangiographic abnormalities were more numerous and persisted far longer into the convalescent phase in comparison with those seen by fluorescein videoangiography. Furthermore, although poorer VA in the acute phase was associated with the findings of irregular hypofluorescence and filling defects by ICG videoangiography and subretinal pooling by fluorescein videoangiography, all patients recovered good VA in the convalescent phase despite the persistence of videofunduscopy and videoangiographic abnormalities. These results suggest that VA may not be a good overall indicator of structural and functional integrity of the fundus. Indeed, although not quantified, many of our VKH patients in the convalescent phase complained of non-specific disturbances in their vision, despite good VA and the absence of active inflammation. Subtle visual disturbances may relate to changes at the level of the RPE and choroid, layers of the fundus often affected in uveitic diseases such as VKH syndrome that may be observed using SLO based video-imaging.

A Okada was supported in part by a grant from the Japanese Ministry of Education.

- 1 Sugiura S. Vogt-Koyanagi-Harada disease. *Jpn J Ophthalmol* 1978;22:9-35.
- 2 Snyder DA, Tessler HH. Vogt-Koyanagi-Harada syndrome. *Am J Ophthalmol* 1980;90:69-75.
- 3 Yokoi H, Goto H, Sakai J, et al. Incidence of uveitis at Tokyo Medical College Hospital. *Nippon Ganka Gakkai Zasshi* 1995;99:710-14.
- 4 Lubin JR, Ni C, Albert DM. A clinicopathological study of the Vogt-Koyanagi-Harada syndrome. *Int Ophthalmol Clin* 1982;22:147-56.
- 5 Scheider A, Nasemann JE, Lund OE. Fluorescein and indocyanine green angiographies of central serous chorioidopathy by scanning laser ophthalmoscopy. *Am J Ophthalmol* 1993;115:50-6.
- 6 Guyer DR, Yannuzzi LA, Slakter JS, et al. Digital indocyanine green videoangiography of central serous chorioretinopathy. *Arch Ophthalmol* 1994;112:1057-62.
- 7 Ie D, Glaser BM, Murphy RP, et al. Indocyanine green angiography in multiple evanescent white-dot syndrome. *Am J Ophthalmol* 1994;117:7-12.
- 8 Guyer DR, Puliafito CA, Mones JM, et al. Digital indocyanine-green angiography in chorioretinal disorders. *Ophthalmology* 1992;99:287-91.
- 9 Yannuzzi LA, Slakter JS, Sorenson JA, et al. Digital indocyanine green videoangiography and choroidal neovascularization. *Retina* 1992;12:191-223.
- 10 Scheider A, Shroedel C. High resolution indocyanine green angiography with a scanning laser ophthalmoscope (letter). *Am J Ophthalmol* 1989;108:458-9.
- 11 Scheider A, Kaboth A, Neuhauser L. Detection of subretinal neovascular membranes with indocyanine green and an infrared scanning laser ophthalmoscope. *Am J Ophthalmol* 1992;113:45-51.
- 12 Wolf S, Wald KJ, Elsner AE, et al. Indocyanine green choroidal videoangiography: a comparison of imaging analysis with the scanning laser ophthalmoscope and the fundus camera (letter). *Retina* 1993;13:266-9.
- 13 Bartsch D-U, Weinreb RN, Zinser G, et al. Confocal scanning infrared laser ophthalmoscopy for indocyanine green angiography. *Am J Ophthalmol* 1995;120:642-51.
- 14 Sharp PF, Manivannan A. The scanning laser ophthalmoscope. *Phys Med Biol* 1997;42:951-66.
- 15 Joko S, Numaga J, Fujino Y, et al. HLA and uveitis in leprosy. *Nippon Ganka Gakkai Zasshi* 1995;99:1181-95.
- 16 Yuzawa M, Kawamura A, Matsui M. Indocyanine green video-angiographic findings in Harada's disease. *Jpn J Ophthalmol* 1993;37:456-66.
- 17 Matsunaga H, Matsubara T, Fukushima I, et al. Indocyanine green fluorescence angiography in Harada disease. *Nippon Ganka Gakkai Zasshi* 1994;98:852-7.

- 18 Masaoka N, Yasuoka K, Ueno H. Indocyanine green angiography in Harada's disease. *Rinsho Ganka* 1994;**48**:569-72.
- 19 Iida T, Hagimura N, Otani T, *et al.* Choroidal vascular lesions in serous retinal detachment viewed with indocyanine green angiography. *Nippon Ganka Gakkai Zasshi* 1996;**100**:817-24.
- 20 Pece A, Bolognesi G, Introini U, *et al.* Indocyanine green angiography in Vogt-Koyanagi-Harada disease. *Arch Ophthalmol* 1997;**115**:804-6.
- 21 Oshima Y, Harino S, Hara Y, *et al.* Indocyanine green angiographic findings in Vogt-Koyanagi-Harada disease. *Am J Ophthalmol* 1996;**122**:58-66.
- 22 Perry HD, Font RL. Clinical and histopathological observations in severe Vogt-Koyanagi-Harada syndrome. *Am J Ophthalmol* 1977;**83**:242-54.
- 23 Chan CC, Palestine AG, Kuwabara T, *et al.* Immunopathologic study of Vogt-Koyanagi-Harada syndrome. *Am J Ophthalmol* 1988;**105**:607-11.
- 24 Hayreh SS. In vivo choroidal circulation and its watershed zones. *Eye* 1990;**4**:273-89.
- 25 Hayreh SS. Physiological anatomy of the choroidal vascular bed. *Int Ophthalmol* 1983;**6**:85-93.
- 26 Howe LJ, Woon H, Graham EM, *et al.* Choroidal hypoperfusion in acute posterior multifocal placoid pigment epitheliopathy. *ophthalmology* 1995;**102**:790-8.

British Journal of Ophthalmology - <http://www.bjophthalmol.com>

Visitors to the world wide web can now access the *British Journal of Ophthalmology* either through the BMJ Publishing Group's home page (<http://www.bmjpg.com>) or directly by using its individual URL (<http://www.bjophthalmol.com>). There they will find the following:

- Current contents list for the journal
- Contents lists of previous issues
- Members of the editorial board
- Information for subscribers
- Instructions for authors
- Details of reprint services.
- BMJ Publishing Group home page
- British Medical Association web site
- Online books catalogue
- BMJ Publishing Group books.

A hotlink gives access to:

The web site is at a preliminary stage and there are plans to develop it into a more sophisticated site. Suggestions from visitors about features they would like to see are welcomed. They can be left via the opening page of the BMJ Publishing Group site or, alternatively, via the journal page, through "about this site".