

MAILBOX

Paediatric neuro-Behçet's disease presenting with optic nerve head swelling

EDITOR,—Involvement of the central nervous system in Behçet's disease (BD) occurs in approximately 10–49%¹ of patients and the frequency of ocular manifestations is believed to be in the range of 28–80%.² Neuropapillitis has been reported very rarely as a manifestation of Behçet's disease.³ As far as we know, there has been no report of paediatric onset neuropapillitis in BD. Here we report a case of neuropapillitis in a 10 year old girl.

CASE REPORT

A 10 year old Omani girl presented in August 1998 with complaint of right sided headache and blurring of vision in the right eye for 10 days and complete loss of vision in the same eye for 5 days. There was no history of vomiting, loss of consciousness, convulsion, or any other neurological deficit. On admission, examination revealed total vision loss in the right eye. The vision was 20/20 in the left eye. Examination of right eye showed relative afferent pupillary defect and fundus examination revealed blurred disc margins with no apparent cup. There was a 2 dioptre elevation of the disc (Fig 1).

Visual evoked potentials (VEP) and brainstem auditory evoked potentials (BAEP) on the right side were prolonged in latency and poorly formed. Magnetic resonance imaging of the brain revealed left sided temporoparietal lesion suggestive of inflammation/demyelination. The child was started on methylprednisolone 500 mg intravenously in two doses followed by 15 mg/day for 2 weeks. Vision returned on day 2 with perception of hand movements, finger counting day 4, and complete recovery on day 8. VEP was repeated and showed normal response. She was admitted in September 1995 with complaint of headache, diplopia, and visual blurring. She had meningeal signs, left lateral rectus palsy, and bilateral papilloedema. Cerebrospinal fluid (CSF) examination showed opening pressure of 210 mm H₂O, closing pressure of 140 mm H₂O, with CSF protein 0.36 (0.15–0.50 g/l), glucose 3.8 (2.2–3.9 mmol/l). White blood cells (WBC) 23, 60% lymphocytes, 40% polymorphs, RBC 10, and no organisms. Chest x ray was normal, Mantoux test was negative, blood culture and CSF had no growth after 48 hours. The clinical picture was suggestive of aseptic meningitis with raised intracranial pressure. The child

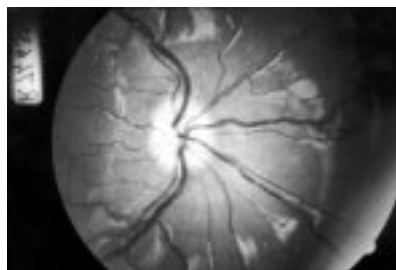


Figure 1 The right eye fundus picture shows blurred disc margins with full cup and elevation of 2 disc diameters.

was treated with systemic steroids over 2 weeks and improved with complete recovery of the sixth nerve palsy and resolution of papilloedema. In November 1995, she presented with left supranuclear facial nerve palsy and left hemiparesis, with hemihypoesthesia. There was no papilloedema. CT showed right side thalamic and posterior internal capsule infarct. There was complete recovery after 1 month. During follow up the child had aphthous ulcer and skin rash. Skin biopsy showed prominent lymphocytic infiltration of the vessels in the dermis consistent with vasculitis, possibly Behçet's disease.

COMMENT

Neuro-Behçet's disease is an uncommon presentation in childhood.⁴ This patient had four episodes of neurological involvement and a skin rash once. Initial manifestation was raised intracranial pressure with aseptic meningitis-like picture and no underlying cause was found. The child recovered with steroids (prednisolone) and diuretics (acetazolamide), which are recommended in the severe form of Behçet's disease.² Later the child had a cerebrovascular accident that also recovered with steroids. There was no underlying cause found. It was on follow up, when the child had aphthous ulcer and skin rash, that diagnosis of Behçet's disease (neuro-Behçet's) was made. The fourth time (last admission) she presented with loss of vision in right eye and investigations—for example, VEP, suggested neuropapillitis.⁵ The diagnosis of Behçet's disease was made on two major criteria oral aphthous ulcers, eye involvement and minor criteria of skin biopsy suggestive of lymphocytic vasculitis,⁶ CNS involvement and abnormal changes in the magnetic resonance imaging (MRI).⁵ Colvard *et al*⁷ reviewed the ocular manifestations of BD in 32 patients. Inflammatory involvement of the optic nerve in the form of papillitis was reported in their three patients. Our case here is the first reported case of inflammatory optic nerve involvement in the paediatric age group, and clinically resembles multiple sclerosis (MS) as reported in adults by Kansu *et al*.⁴ Multiple sclerosis is rare at this age and the presentation of aseptic meningitis, papilloedema, skin lesion, and aphthous ulcer, with MRI showing a single patch of demyelination, excludes this possibility. The MRI of the optic nerve was normal despite abnormal VEP in our case. Unless the patient presents with clear symptoms, the diagnosis of Behçet's disease is difficult initially. The diagnosis in children is more difficult as the disease is uncommon and usually the diagnosis is made after several systemic presentations and the exclusion of other common diseases.

SANDIP MITRA

R L KOOL

Department of Ophthalmology, Sultan Qaboos University Hospital, PO Box 38, Alkhod, Muscat 123, Sultanate of Oman

Correspondence to: Dr Mitra.

- Di Biasi C, Accorinti M, Trasimeni G, *et al*. Magnetic resonance of encephalon in 17 patients with ocular Behçet's disease. *Radiol Med (Torino)* 1997;93:348–51.
- Klinika za reumatologiju, Vojnomedicinska akademija, Beograd. Behçet's disease—clinical picture and treatment. *Med Pregl* 1996;49:233–6.
- Gallinaro C, Robinet Combes A, Sale Y, *et al*. Neuropapillitis in Behçet's disease. A case. *J Fr Ophthalmol* 1995;18:147–50.
- Kansu T, Kirkali P, Kansu E, *et al*. Optic neuropathy in Behçet's disease. *J Clin Neuro-ophthalmol* 1989;9:277–80.

- Morrissey SP, Miller DH, Heraszewski R, *et al*. Magnetic resonance imaging of the central nervous system in Behçet's disease. *Eur Neurol* 1993;33:287–93.
- International Study Group For Behçet's disease. Criteria for diagnosis of Behçet's disease. *Lancet* 1990;335:1078–80.
- Colvard M, Robertson DM, O'Duffy JD. The ocular manifestations of Behçet's disease. *Arch Ophthalmol* 1977;95:1813–17.

Should diabetic patients be screened for glaucoma?

EDITOR,—In their article, Ellis *et al* claimed to have “reviewed all potentially relevant English language articles from 1966 to 1997.”¹ It is unfortunate that they did not define the method of detecting such articles as it may have cast light upon the omission of perhaps the most complete study yet performed on the subject.² This was published in April 1997, nearly 2 years before the publication of the perspective and approximately 6 months before the Royal College Guidelines on Ocular Hypertension and Glaucoma (although after the “last revision” date). The inclusion of other articles from 1997 in the reference list would appear to indicate that their quoted dates of 1966 to 1997 were inclusive rather than exclusive. The findings of a positive association of open angle glaucoma with diabetes was a result of an analysis of data from the Blue Mountains eye study, a carefully controlled study of a large population of people aged 49 and over. This study would appear to come closest to Ellis *et al*'s ideal in view of the non-IOP based nature of the glaucoma diagnosis and the use of fasting glucose levels in those not already known to be diabetic.

I would encourage all those who read the perspective¹ to study Mitchell *et al*'s paper and thereby come to their own conclusions concerning the question “Should diabetic patients be screened for glaucoma?”

S A VERNON

Consultant ophthalmologist and chairman, Royal College Working Party responsible for the 1997 Guidelines on Ocular Hypertension and Glaucoma

- Ellis JD, Morris AD, MacEwan CJ. Should diabetic patients be screened for glaucoma? *Br J Ophthalmol* 1999;83:369–72.
- Mitchell P, Smith W, Chey T, *et al*. Open angle glaucoma and diabetes. The Blue Mountains Eye Study, Australia. *Ophthalmology* 1997;104:712–18.

Reply

EDITOR,—We are grateful to the chairman of the Royal College Working Party responsible for the 1997 guidelines on ocular hypertension and glaucoma,¹ Mr S Vernon, for highlighting our inadvertent omission of the Blue Mountains eye study paper² which was available to the working party before the publication of the guidelines. The omission of this paper from our review was unintentional and unfortunate.

The strengths of this rigorous study are its population based sampling frame, its careful definition of diabetes, and its definition of glaucoma to include field loss matching disc changes regardless of intraocular pressure. The overall prevalence of diabetes was 7.0% of whom 98% had type 2 diabetes and 15% were newly diagnosed during the course of the study (by fasting glucose test). The prevalence of POAG was 3.0% (108 patients).³

Exactly half the glaucoma cases were newly diagnosed by the researchers. The prevalence of diabetes in the 54 pre-study diagnosed

POAG patients was almost twice that in the 54 “newly diagnosed” cases (nine cases in the former compared with five in the latter; age/sex adjusted odds ratio (OR) 2.12). The prevalence of diabetes in those with POAG differed significantly from that of the general population without glaucoma (6.9%) only in the latter group (age/sex adjusted OR 2.82, 95% CI 1.35–5.87). However tempting to suggest that unmasking bias⁴ may be operative in this group, it is noteworthy that six of the nine patients did not know they had diabetes at the time of diagnosis of POAG. Unmasking bias will only have been operative if the eye clinic is as likely to diagnose diabetes in referrals with possible POAG as it is to diagnose unsuspected POAG in referrals for possible retinopathy or diabetes related cataract. This is unlikely since random blood glucose estimation is probably not a routine test in a busy eye clinic.

Our review asked whether the published information available to clinicians and health planners could support targeted screening of diabetic patients. The suggested method was measurement of intraocular pressure. It is informative that in the Blue Mountains eye study only 25.5% of POAG patients had raised pressure. This then would seem an inappropriately insensitive means for screening.

The paper by Mitchell *et al* adds convincing support to the existence of an association between diabetes and POAG. The problem of how best to cater for this group remains. In light of the available evidence the advice of the Royal College of Ophthalmologists¹ seems apposite; to be aware of the increased risk of POAG in this group of patients who attend for retinopathy screening.

J ELLIS
A D MORRIS
C J MACEWAN

University Department of Ophthalmology, Ninewells
Hospital and Medical School, Dundee DD1 9SY

- 1 Royal College of Ophthalmologists. *Guidelines for the management of ocular hypertension and primary open angle glaucoma*. London: RCO, 1997.
- 2 Mitchell P, Smith W, Chey T, *et al*. Open angle glaucoma and diabetes The Blue Mountains Eye Study, Australia. *Ophthalmology* 1997;104:712–18.
- 3 Dielmans I, de Jong PTVM, Stolk R, *et al*. Primary open angle glaucoma, intraocular pressure, and diabetes mellitus in the general population. *Ophthalmology* 1996;103:1271–5.
- 4 Choi BCK, Noseworthy AL. Classification, direction and prevention of bias in epidemiologic research. *J Occup Med* 1992;34:265–71.

Hertel exophthalmometry: the most appropriate measuring technique

EDITOR.—The common method used in Hertel exophthalmometry involves aligning the corneal apex with the reference cone on the exophthalmometer and noting the position of this alignment on the millimetre scale (method 1). Keeler, the manufacturers of the exophthalmometer, recommend that the reference cone is aligned with the reference line on the millimetre scale and the position of the anterior surface of the cornea on the millimetre scale noted (method 2).

Our study, in which two masked observers of differing experience examined 50 patients using these two methods, was set up to compare the results obtained using the two methods, determine if they could be used interchangeably, and whether we could recommend one method over the other.

Readings obtained by each observer from each eye with one method were compared with the readings of that same observer from the same eye using the different measurement method. A Wilcoxon statistical analysis was performed. Observer 2 was the more experienced.

There was a statistically significant difference between the readings made by observer 2. This is most probably clinically relevant and does show that both methods of measurement cannot be used interchangeably.

There was a 60–70% (method 1) and 30–40% (method 2) interobserver percentage agreement for readings from each eye and each measurement method. Agreement was present if the interobserver readings were within 1 millimetre of each other. These results may reflect the fact that both observers were more familiar with method 1. A follow up study, once the observers were more familiar with the Keeler method, should show an improvement in the agreement rate if this was the case.

We believe this study shows that a failure to make clear the measurement method used in exophthalmometry can lead to clinically significant false positive results which could have serious implications in the management of these patients.

NIALL P O'DONNELL
MEENA VIRDI
EWAN G KEMP

Tennent Institute of Ophthalmology,
Western Infirmary, Glasgow

Correspondence to: Niall P O'Donnell, Southport General Infirmary, Scarisbrick New Road, Southport, Merseyside PR8 6P.

BOOK REVIEWS

Histological Typing of Tumours of the Eye and its Adnexa. By R J Campbell in collaboration with L H Sobin and pathologists in 11 countries. Pp 115. £46. London: Springer, 1998. ISBN 0-483-418800.

This is the long awaited second edition of this volume in the WHO international histological classification of tumours series. With the exception of Dr Sobin, only two of the participants in the second edition were involved in the preparation of the first and, inevitably, this reviewer turned to the first edition to compare it with the second. The second edition is now in a much more user friendly paperback format and the material has been reorganised in a more logical and simpler way than in the first edition. Furthermore, the index is now at the end of the book rather than halfway through as it was in the 1980 version. Another major improvement in the second edition is the addition of the TNM classification of tumours of the eye and its adnexa. It makes sense to have the TNM classification included along with histological typing of tumours rather than having to refer to the separately published TNM classification of malignant tumours whenever one is reporting. The photomicrographs are also generally of a higher quality than in the 1980 edition.

However, the second edition is not entirely an improvement on its predecessor. I would have to take issue with the claim on the back

cover that it “is more extensive and detailed than the previous edition”. It is certainly more extensive with regard to the number of tumours mentioned, but not more detailed, as there are far fewer explanatory notes than in the first edition, and the explanatory notes suffer from a degree of selectivity, the logic for which is not always obvious. Furthermore, the classification suffers from the “overlap syndrome” and descriptions of skin tumours and CNS tumours would be better left to the relevant histological typing volumes. For example, the explanation of glioblastoma multiforme as “anaplastic pleomorphic cells with or without necrosis replace the normal optic tissue” is hardly a helpful description of what is, in reality, an extremely rare tumour of the optic nerve.

Although the photomicrographs are generally of higher quality, there are in fact fewer (112 *v* 150) in the second edition and once again they are highly selected for reasons which are not immediately obvious—for example, there are four figures of a phacomatous choristoma of the eyelid including immunocytochemistry but only one of the much commoner and more difficult problem of conjunctival intraepithelial neoplasia. Final gripes about the photographs relate to the absence of arrows to point out subtle features and inconsistencies in some of the figure legends—for example, “undifferentiated sebaceous adenocarcinoma” when, by definition, there must be evidence of sebaceous differentiation in order for the diagnosis of sebaceous carcinoma to be made.

All in all, I think the second edition is something of an improvement on the first edition. It is now more user friendly and the addition of the TNM classification is very helpful. However, the book still suffers from the problems which bedevil the whole series of WHO histological classifications—selectivity, “lowest common denominator” classification, and the construction of the classification by a small group of monospecialists. Nevertheless, the book will still be useful as a common language for use in ophthalmic oncology and a way of resolving disputes between pathologists at meetings.

J M MACKENZIE

Walsh and Hoyt's Clinical Neuro-Ophthalmology. 5th ed. Vols 1 and 2. By Neil R Miller, Nancy J Newman. Pp 1116 each. £130 each. Baltimore: Williams & Wilkins, 1998. ISBN 0-683-302302 (Vol 1); 0-683-302310 (Vol 2).

The fifth edition of *Walsh and Hoyt's Clinical Neuro-Ophthalmology* is a very extensive piece of work that consists of five volumes and involves over 70 authors. It is the largest textbook in neuro-ophthalmology and is considered to be the reference standard in this area with appeal not only to ophthalmologists but also to neurologists and neurosurgeons. The fourth edition took two authors 14 years to complete and suffered as a result by quickly becoming out of date. To avoid this, the present edition has multiple authors and was completed in the remarkably short time of two years. Volume one examines the visual sensory system, the autonomic system, the ocular motor system, eyelid function, the sensory innervation of the eye and orbit, and non-organic disease. Volume two examines tumours, paraneoplastic diseases, complications of chemotherapy, phacomatosis, and degen-

erative diseases. The other three volumes were not available for review.

This is clearly not a book that can easily be read from cover to cover in one go. Instead I think it is book that one dips into when faced with a difficult management case or where one wishes to find the definitive account of a particular condition or disease. It is extensively illustrated and referenced to the point of exhaustion. Indeed at times the text seems to disappear among the endless list of references that accompanies every statement. Virtually everything one can think of is to be found in this text and usually in great detail. Some of the information and illustrations are duplicated at various points throughout the volumes and perhaps this is to be expected when dealing with a text as large as this. My main criticism is the fact that references are listed without any critical analysis to their worth. Indeed, when looking at topics such as idiopathic intracranial hypertension, it is easy to be fooled by the presence of so many references into the belief that therapies such as acetazolamide, diuretics, steroids, and various surgical therapies are based on good clinical evidence, whereas in fact there is little, if any, clinical evidence for any of the various treatments on offer.

The fifth edition of *Walsh and Hoyt's Clinical Neuro-Ophthalmology* is truly an incredible piece of work and all the authors are to be congratulated for their efforts. It is claimed that this text is the definitive work in this area. One only has to compare the fourth and fifth editions to see the vast leap in our knowledge that has occurred in the past decade and the vast leap that is likely to occur in the next. To date our knowledge has been concentrated on the localisation and structure of diseases. Hopefully, in the near future, techniques such as fMRI and PET scanning will lead to better understanding, not only of the functional abnormalities of disease processes, but also to new avenues of therapy and inevitably a sixth edition.

JOHN A OLSON

Laser Photocoagulation of the Retina and Choroid. By Folk JC, Pulido JS. Pp 292; £75. San Francisco: American Academy of Ophthalmology, 1997. ISBN 1-56055-045-7.

In the preface to this book, the authors state their aim to make this book both practical and useful—a “how to” on laser treatment. They have managed to achieve this goal as well as include considerable detail and suggestions for further reading.

The book begins with an overview of the physics of lasers and the optics of laser delivery systems. It is possible to cover the material quite quickly, as the layout is uncluttered and interspersed with clear diagrams and tables, which aid memorisation of the important points. The complications of laser photocoagulation are covered in some detail, together with a description of the different wavelengths of lasers available and their different indications.

With the exception of a chapter devoted to a selection of miscellaneous conditions at the end of the book, each major chorioretinal condition is allocated a separate chapter. There are chapters on diabetic macular oedema, proliferative diabetic retinopathy, retinal vein occlusion, peripheral retinal neovascularisation, including retinopathy of prematurity and choroidal neovascularisation.

Each chapter begins with a section on clinical evaluation including presenting symptoms, signs, and guidelines on investigations. Considerable emphasis is placed on pretreatment planning and the preparation of patients, not only in deciding which course of treatment to take, but also what the patient should be told for the purposes of informed consent. This information is often presented in handy checklists, which stand out in the text. The authors take the reader through all the steps in planning a treatment session from the choice of laser, delivery system and lens, to the location and spot characteristics of the laser burn. For each condition, an impressive array of fundus photographs and fluorescein angiograms, both pre- and post-treatment are presented. Suggestions are made concerning the frequency and nature of post-treatment follow up and this is often illustrated with the inclusion of real clinical examples.

The chapters on diabetic retinopathy are well referenced and treatment guidelines closely follow the ETDRS and DRS protocols. An extensive reading list is provided at the end of the chapters. One possible criticism is the lack of indexing of references within the text, which could make accessing a particular reference difficult.

The authors add their own well reasoned suggestions for managing more complicated clinical situations and a section on “special cases”, where there are other coexistent ocular conditions, is included.

An superb set of stereo fundus photographs and angiograms in slide form complement the chapter on choroidal neovascularisation. A stereo viewer is provided, which is very easy to use. At the start of the chapter, the reader is guided through the interpretation of both fluorescein and indocyanine green angiography.

Advice is given on the management of recurrent choroidal neovascularisation post-treatment, and this is illustrated with clinical examples. The authors give their own guidelines for treating lesions near the fovea. There is an extensive presentation of the Macular Photocoagulation Studies' findings in summary form, with references. This is a very useful feature and will no doubt be helpful to those preparing for clinical exams.

Guidelines on the management of retinal tears and a variety of other retinal vascular and chorioretinal conditions are presented in a separate chapter. The book concludes with a number of self assessment MCQs. These are chapter based and broadly cover the information presented. Detailed explanations are provided with the answers.

In summary, the book is compact, succinct, and easy to read with the essential information readily accessible through a well designed “contents” section. The treatment guidelines that are suggested are evidence based and follow the major multicentre trial findings. Important practical points are often included in highlighted checklists for easy reference. For those wishing to read further about a particular subject the reading lists are very comprehensive. With its practical emphasis, it would be a welcome addition to any eye department library.

I think individuals preparing for clinical examinations would also find this book helpful, as would anyone wanting to learn how to perform laser treatment safely and effectively.

MARK COSTEN

Manual of Orbital and Lacrimal Surgery. 2nd ed. By Alan A McNab. Pp 142; £29.99. Oxford: Butterworth-Heinemann, 1998. ISBN 0-7506-3997-0.

From time to time, one reads a book and regrets that one did not write it oneself. This is just such a book. It is truly a manual, being manageable in size and practical. The approach is logical, opening with an adequate resume of the relevant anatomy, well illustrated with drawings and photomicrographs of CT scans. The advantages and disadvantages of the various forms of orbital imaging are well covered as are the common orbital disorders. A chapter on orbital pathology would have enhanced the text, although this is a minor criticism. The descriptions and drawings of the surgical approaches to the orbit are first rate as is the section on decompression of the orbit. The approach is balanced, describing both the advantages and disadvantages of the various techniques. Orbital trauma is well covered with a particularly useful section on the management of orbital haemorrhage and the compromised optic nerve. The orbital section concludes with a chapter on the management of orbital infection.

The five chapters on lacrimal disorders are concise and apposite as are the illustrations.

In summary, this is an excellent book, competitively priced, up to date, easy to follow, and a pleasure to handle. Every eye theatre should have a copy.

P M KYLE

Eye Examination and Refraction. 2nd ed. By R J Fletcher, D C Still. Pp 288, £29.95. Oxford: Blackwell Science, 1998. ISBN 0-632-05141-8.

This paperback book is part of a series written for optometry students preparing for their final professional qualifying examination. The ophthalmologist, in preparation for optics and refraction examinations or wishing to revise issues of refraction and spectacle prescription in clinical practice, may find it useful, however, as it raises practical problems to which answers may not be easily accessible in other texts—for example, manufacturing imperfections of trial lens sets or dealing with unfamiliar equipment.

Divided into three sections, the first concentrates on the optometric eye examination and a review of necessary equipment for setting up a practice. Basic examination techniques, courtesies, and the issues and responsibilities in the maintenance of clinical records are discussed. This material may not all be directly applicable to an ophthalmologist, but does lend insight to the perspectives of a fellow profession, from whom a large number of referrals are derived.

Section 2 is devoted to the performance of refraction, with useful tips and advice on objective and subjective refraction, including reviews of estimation of refraction from Snellen vision testing, near addition prescribing, and the use of cross cylinders. Included is a chapter on the needs of special or more challenging patients.

The final section, and probably most useful for the ophthalmologist, consists of 100 case histories of patients with proposed solutions presented for self assessment, or as a useful basis for discussion in a teaching group. These are not purely refractive cases, but include those with medical problems for whom optical correction has a role in rehabilitation.

The appendices contain practice guidelines issued by the College of Optometrists and more self assessment.

The book is written in a readable, chatty style with anecdotes and cautionary tales used to illustrate important clinical messages. The book is not a primer for the novice refractonist as it assumes basic knowledge and clinical method, nor is it a comprehensive manual of optics and refraction techniques, but rather an "experienced practitioner" offering a pragmatic companion to revision and refinement of technique "in the real world". While some techniques are expounded at length, others are mentioned only in passing or merely referenced, with some references quite historical. The ophthalmologist will find some of the references unfamiliar, but will be clearly directed to the relevant material to pursue. The text emphasises the need for flexibility of approach and the importance of familiarity with more than one method of examination or approach to achieve a desirable outcome and to satisfy the foibles of colleagues (examiners!). Thus it brings together material which might be used in viva voce examinations.

Overall, I found this an interesting read, with useful practical advice, and the case histories illuminating. I would direct the reader to peruse the introduction first so as to gauge the flavour of the text.

J A SCOTT

NOTICES

Ageing and the eye

The latest issue of *Community Eye Health* (no 29) discusses ageing and the eye. Included are papers on ageing and the eye from a global perspective; epidemiology; delivery of eye care to the elderly; and age related macular disease. For further information please contact *Community Eye Health*, International Centre for Eye Health, Institute of Ophthalmology, 11-43 Bath Street, London EC1V 9EL. (Tel: (+44) 171 608 6909/6910/6923; fax: (+44) 171 250 3207; email: eyerresource@ucl.ac.uk) Annual subscription £25. Free to workers in developing countries.

Residents' Foreign Exchange Programme

Any resident interested in spending a period of up to one month in departments of ophthalmology in the Netherlands, Finland,

Ireland, Germany, Denmark, France, Austria, or Portugal should apply to: Mr Robert Acheson, Secretary of the Foreign Exchange Committee, European Board of Ophthalmology, Institute of Ophthalmology, University College Dublin, 60 Eccles Street, Dublin 7, Ireland.

International Agency for the Prevention of Blindness

The sixth general assembly of the International Agency for the Prevention of Blindness will be held on 5-6 September 1999 at the Conference Centre, Beijing Friendship Hotel, Beijing, People's Republic of China. The theme is "The right to sight". Further details: IAPB Secretariat, LV Prasad Eye Institute, LV Prasad Marg, Banjara Hills, Hyderabad 500 034, India (tel: 091-40-215389; fax: 091-40-248271; email: IAPB@lvpeye.stph.net).

Ophthalmological Clinic, University of Creteil

An international symposium on the macula will be held on 1-2 October 1999 at the Ophthalmological Clinic, University of Creteil. Further details: Professor G Soubrane, Chef de Service, Clinique Ophtalmologique Universitaire de Creteil, Centre Hospitalier Intercommunal, 40 Avenue de Verdun, 94010 Creteil, France (fax: 01 45 17 52 27).

Jules François Prize

The 2000 Jules François Prize of \$100 000 for scientific research in ophthalmology will be awarded to a young scientist who has made an important contribution to ophthalmology. All topics in the field of fundamental and/or clinical research in ophthalmology will be considered. The application should be sent jointly with a curriculum vitae, the list of all publications, and three copies of the candidate's 10 most relevant publications to Jules François Foundation Secretary, Professor Dr M Hanssens, Dienst Oogheelkunde, de Pintelaan 185, B-9000 Gent, Belgium. Deadline for applications 31 December 1999.

Joachim Kuhlmann Fellowship for Ophthalmologists 2000

The Joachim Kuhlmann AIDS Foundation, Essen, Germany, is sponsoring two fellowships per year for ophthalmologists at a well known institute, who want to train in CMV retinitis and other HIV related ophthalmological diseases. The fellowships are valued at \$US5000 each. deadlines for applications are 31 January and 31 July. Detailed applications,

including CV and publication list, should be sent to the Joachim Kuhlmann AIDS Foundation, Bismarckstrasse 55, 45128 Essen, Germany (tel: 0201 87910-87; fax: 0201 87910-99; email: jk-stiftung@t-online.de).

XXXIV Nordic Congress of Ophthalmology

The XXXIV Nordic Congress of Ophthalmology will be held in Reykjavik, Iceland, 18-21 June 2000. This meeting celebrates the 100 year anniversary of the Nordic Ophthalmology Conference. Further details: Iceland Incentives Inc, Hamraborg 1-3, Is-Kopavogur, Iceland (tel: +354 554 1400; fax: +354 554 1472; email: incentiv@itn.is).

5th International Vitreoretinal Meeting-IIV 2000

The 5th International Vitreoretinal Meeting-IIV 2000 will be held in Parma, Italy, on 26-27 May 2000. The main topics will include "Hypotony and glaucoma in vitreoretinal surgery", "Internal limiting membrane surgery", "Macula oedema", "Open globe injuries", and "News in retinal pigment epithelium". Further details: C Cantu, MA De Giovanni, or S Tedesco, Scientific Secretariat, Institute of Ophthalmology, University of Parma, Via Gramsci 14, 43100 Parma, Italy (tel: ++39 0521 259106; fax: ++39 0521 292358; email: nuzzi@ipr.univ.cce.unipr.it).

DR-2000, International Forum on Diabetic Retinopathy

The International Forum on Diabetic Retinopathy will take place on 7-9 September 2000 at the Palazzo Reale, Naples, Italy. Further details: Francesco Bandello, Congress Secretariat, MGR Congressi, Via Servio Tullio, 4, 20123 Milano, Italy (tel: 39 02 430071; fax: 39 02 48008471; email: dr2000@mgr.it).

12th Afro-Asian Congress of Ophthalmology

The 12th Afro-Asian Congress of Ophthalmology (Official Congress for the Afro-Asian Council of Ophthalmology) will be held on 11-15 November 2000 in Guangzhou (Canton), China. The theme is "Advances of ophthalmology and the 21st century". Further details: Professor Lezheng Wu, Zhongshan Eye Center, SUMS, New Building, Room 919, 54 Xianlie Nan Road, Guangzhou 510060, PR China (tel: +86-20-8760 2402; fax: +86-20-8777 3370; email: lwuicv@gzsums.edu.cn).