

## LETTERS TO THE EDITOR

### Isolated focal melanocytes collection in the lacrimal sac

EDITOR.—Although the presence of melanocytes located within and under the epithelium of the nasal cavity and paranasal sinuses has been reported, it appears to be a rare finding.<sup>1</sup> Further, only 17 cases of malignant melanoma of the lacrimal sac have been reported.<sup>2</sup> We came across unusual, and unaccounted for, focal collections of melanocytes in the lacrimal sac of a patient and report this finding.

#### CASE REPORT

A 55 year old woman presented to the ophthalmology department of the Schieffelin Leprosy Research and Training Centre with a left sided lacrimal mucocele. Since she also had a cataract that needed surgery, a dacryocystectomy was done in January 1999. During surgery, when the lacrimal sac was being dissected, a localised small area of black pigmentation was seen on the sac. The excised sac was sent for histopathological examination to rule out melanoma. There were no associated pigmentations on the skin overlying the sac or any fistulas in the region.

Histopathological examination of the lacrimal sac showed focal and diffuse collections of cells containing blackish-brown pigments in the stroma and the epithelial cells of the sac. Inflammatory cell collections consisting of lymphocytes, histiocytes, and plasma cells were also seen in the stroma (Fig 1). The intracellular pigment gave negative results when stained with Perl's stain for haemosiderin<sup>3</sup> but gave a positive result when

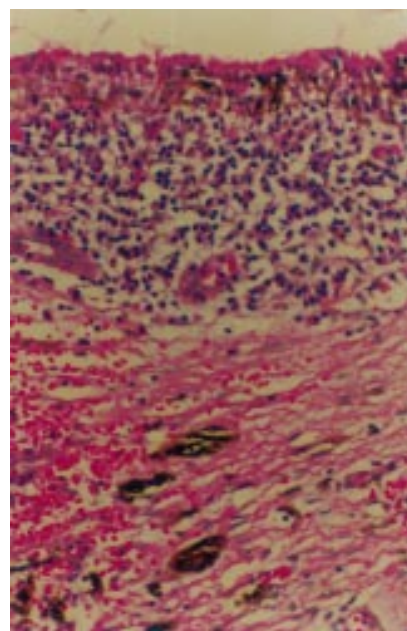


Figure 1 Photomicrograph of lacrimal sac showing blackish-brown pigments in the epithelium and stroma. Collections of lymphocytes and plasma cells are seen in the stroma adjacent to the epithelium (haematoxylin and eosin, original magnification  $\times 200$ ).

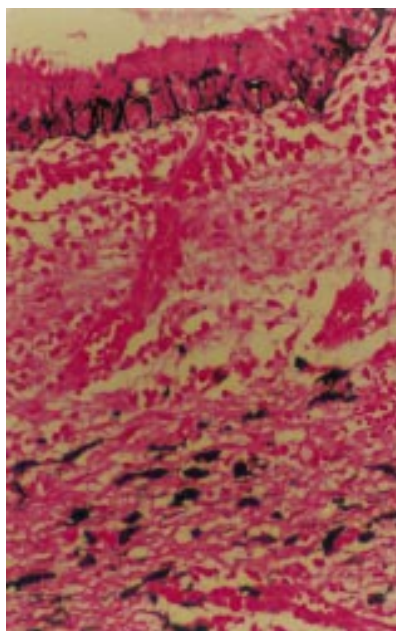


Figure 2 Photomicrograph of lacrimal sac showing blackish pigments in the epithelial cells and stroma (Fontana-Masson, original magnification  $\times 200$ ).

stained with Fontana-Masson stain for melanin (Fig 2).<sup>4</sup> The pigment was completely bleached and removed,<sup>5</sup> thus confirming that the pigment present was melanin.

#### COMMENT

The pigmentation in the lacrimal sac was a chance finding. The cells containing the pigment were confirmed to be melanocytes by the Fontana-Masson staining. The origin of malignant melanoma of the sac is uncertain.<sup>2</sup> Presumably, it can arise from nests of melanocytes located either within the epithelium of the lacrimal sac or in the underlying stroma.<sup>2</sup> This histopathological finding establishes that melanocytes can be found in isolation in the lacrimal sac. A morphologically similar histopathology can be seen in blue naevus and in the naevus of Ota but clinically the patient did not exhibit any ocular melanosis nor was the skin of the face pigmented.

EBENEZER DANIEL

Department of Ophthalmology, Schieffelin Leprosy Research and Training Centre, Karigiri, Vellore District, Tamilnadu, India - 632106

GIGI J EBENEZER

Department of Histopathology and Experimental Pathology

ELIZABETH SONU JOHN

Department of Ophthalmology

CHARLES K JOB

Emeritus scientist, Schieffelin Leprosy Research and Training Centre

Correspondence to: Dr Ebenezer Daniel  
Accepted for publication 6 September 1999

- 1 Uehara T, Matsubara O, Kasuga T. Melanocytes in the nasal cavity and paranasal sinus. Incidence and distribution in Japan. *Acta Pathol Jpn* 1987;37:1105-14.
- 2 Font RL. Eyelids and lacrimal drainage system. In: Spencer WH, ed. *Ophthalmic pathology: an atlas and textbook*. 4th ed. Vol 4. Philadelphia: Saunders, 1996:2424-6.
- 3 Cook HC. Pigments. In: *Manual of histological demonstration techniques*. London: Butterworth, 1974:71-2.
- 4 Luna LG. Methods for cytoplasmic granules. In: *Manual of staining methods of the Armed Forces Institute of Pathology*. 3rd ed. New York: McGraw-Hill, 1976:104-5.

5 Luna LG. Routine staining procedures. In: *Manual of staining methods of the Armed Forces Institute of Pathology*. 3rd ed. New York: McGraw-Hill, 1976:42.

### Pupillary distortion after contact transscleral diode laser cyclophotocoagulation

EDITOR.—In recent years, transscleral contact diode laser cyclophotocoagulation (TCDLC) has been shown to be efficient in successfully lowering the intraocular pressure in different types of glaucoma.<sup>1-5</sup> Reported success rates by various criteria ranged from 38% to 85%. Mostly, a fixed distance from the corneoscleral limbus with a specially designed contact probe without visualisation of the ciliary body is used.

Complications reported so far include phthisis, chronic hypotony, corneal graft decompensation, macular pucker, cystoid macular oedema, hyphaema, vitreous haemorrhage, loss of visual acuity, retinal detachment, conjunctival burns, uveitis, and ocular pain.<sup>1-5</sup>

However, with the increasing use of TCDLC, more complications may be observed. This report describes pupillary distortion, a previously unreported complication.

#### CASE REPORT

A 32 year old man with bilateral juvenile glaucoma since 1987 was referred to our hospital. Trabeculotomy and cyclocryotherapy had been performed in both eyes. In June 1997 visual acuity of the right eye was 20/20 and of the left eye 20/400. Intraocular pressure (IOP) of the right eye was between 12 and 45 mm Hg under maximal medical treatment. IOP of the left eye was normal. Examination of both eyes revealed focal scleral thinning due to cyclocryotherapy. Gonioscopy revealed a wide

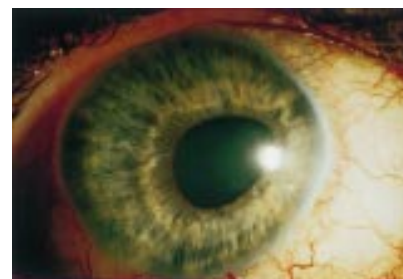

Figure 1 Distortion of pupil after transscleral diode laser cyclophotocoagulation. A "pop" effect occurred at the 2 o'clock position.

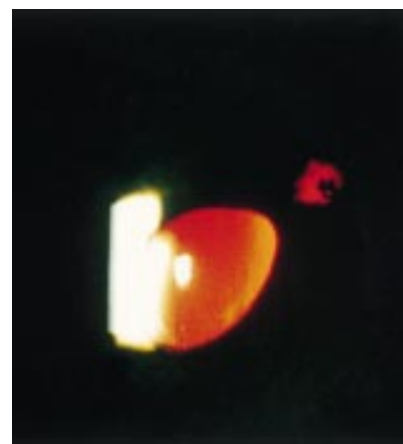

Figure 2 Transillumination showed a defect of the peripheral iris.

open angle with poor pigmentation and dysgenesis of the trabecular meshwork.

We performed TCDLC (Oculight SLx 810 nm, G-probe: 600 µm quartz fibre probe Iris Endoprobe, Iris Medical Instruments Inc, CA, USA) under local anaesthesia. The patient received 10 applications using 2 W for 2 seconds per application. Postoperatively, IOP ranged between 8 and 15 mm Hg. No medical treatment was needed during the following 8 months.

In February 1998, the IOP in the right eye increased again and could not be controlled by medication. TCDLC was repeated. Although IOP decreased postoperatively to normal values, 3 months later IOP increased to 38 mm Hg.

TCDLC was repeated a second time using the same application variables with eight spots. In the 2 o'clock position a so called "pop" effect (disruption of tissue) occurred. Postoperatively, visual acuity has not changed. IOP decreased to normal values under reduced topical medication. The patient was seen in our outpatient department 6 weeks later. Cells persisted in the anterior chamber and a pupillary distortion was observed toward the 2 o'clock position, where the "pop" effect had occurred (Fig 1). A pigment defect of the peripheral iris was seen in transillumination (Fig 2).

#### COMMENT

It appears likely that pupillary distortion in this patient was the result of a peripheral iris injury, caused by an anterior displacement of the laser spot. The "pop" effect was caused by the disruption of the iris pigment epithelium.

TCDLC using the G-probe is applied at the distance of 1.2 mm posterior to the surgical limbus, parallel to the visual axis, without visualisation of the ciliary body. At least three aspects should be taken into account in the discussion of causes for the displacement of laser spots during TCDLC. (1) Even in normal, emmetropic eyes, the anterior margin of the ciliary body varies between 1.5 and 2 mm depending on the meridian.<sup>6</sup> (2) Individual variations in the anatomical location of the pars plicata of the ciliary body may exist in normal and, especially, in eyes affected by juvenile glaucoma. (3) Bloom and Weber have demonstrated, in human necropsy eyes, that relatively small changes in probe orientation may result in peripheral iris involvement.<sup>7</sup>

Our observation supports the need for online control of the induced tissue reaction and visualisation of the ciliary body itself. In our opinion this may become an important step on the way to standardise transscleral cyclophotocoagulation and also to improve efficiency and safety. The possibility of pupillary distortion as a complication of transscleral cyclophotocoagulation should be kept in mind.

TORSTEN SCHLOTE  
MATTHIAS DERSE  
HANS-JÜRGEN THIEL  
BENEDIKT JEAN

Department of Experimental Ophthalmic Surgery,  
University Eye Hospital, Tübingen, D-72076, Germany

Correspondence to: Dr T Schlote, University Eye  
Clinic, Universitäts-Augenklinik, Schleichstrasse 12,  
Tübingen, D-72076, Germany

Accepted for publication 14 October 1999

- Bock CJ, Freedmann SF, Buckley EG, *et al*. Transscleral diode laser cyclophotocoagulation for refractory pediatric glaucomas. *J Pediatr Ophthalmol Strabismus* 1997;34:235-9.
- Schlote T, Kreutzer B, Kriegerowski M, *et al*. Diodenlaser-Zyklophotokoagulation in der Behandlung therapierefraktärer Glaukome. *Klin Monatsbl Augenheilkd* 1997;211:250-6.
- Kosoko O, Gaasterland DE, Pollak IP, the Diode Laser Ciliary Ablation Study Group. Long-term outcome of initial ciliary ablation with contact diode laser transscleral cyclophotocoagulation for severe glaucoma. *Ophthalmology* 1996;103:1294-302.
- Werner A, Vick H-P, Guthoff R. Zyklophotokoagulation mit dem Diodenlaser. Untersuchung der Langzeitergebnisse. *Ophthalmologie* 1998;95:176-80.
- Brown AJ, Tripathi RC, Tripathi BJ. *Wolff's anatomy of the eye and the orbit*. 8th ed. London: Chapman and Hall Medical, 1997:229.
- Bloom M, Weber PA. Probe orientation in contact Nd:YAG laser cyclophotocoagulation. *Ophthalmic Surg* 1992;23:364-6.

#### Urrets-Zavalía syndrome following trabeculectomy

EDITOR.—A fixed and dilated pupil is an uncommon postoperative complication first described by Urrets-Zavalía following penetrating keratoplasty for keratoconus.<sup>1</sup> We report the same problem occurring in two patients after uncomplicated trabeculectomy. To the best of our knowledge, such cases have not been previously described in the literature.

#### CASE 1

A 38 year old woman with bilateral advanced glaucoma was referred for further management of her condition. Her ophthalmic history included surgery to her left squint as a child and left amblyopia. She was otherwise fit and well and took no systemic medication.

On examination her best corrected visual acuities were 6/6 in the right eye and 6/36 in the left with a left relative afferent pupillary defect. Her anterior segments were normal and her intraocular pressure (IOP) was 19 mm Hg bilaterally on timoptol twice daily.

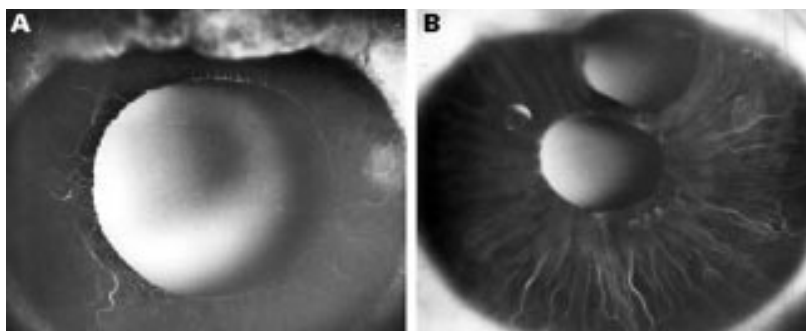


Figure 1 Case 1. Fluorescein angiogram shows delayed filling of the iris capillary plexus with large areas of non-perfusion on the right (A). The left iris is normal (B).

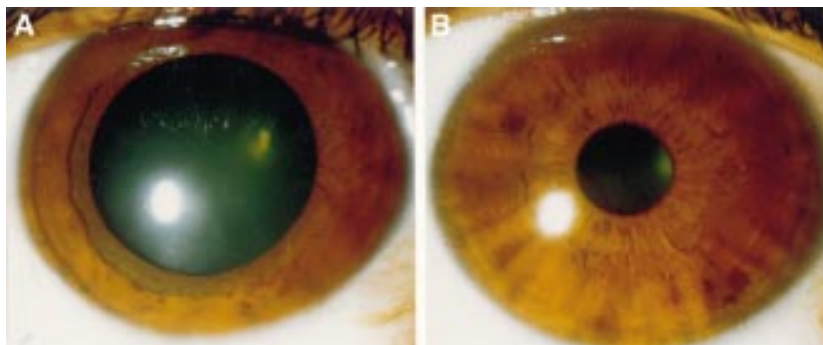


Figure 2 Case 2. Fixed and dilated right pupil (A). The left pupil is normal (B).

1 Bloom PA, Tsai JC, Sharma K, *et al*. "Cyclodiode" trans-scleral diode laser cyclophotocoagulation in the treatment of advanced glaucoma. *Ophthalmology* 1997;104:1508-20.

Gonioscopy revealed open angles and funduscopy showed end stage optic disc cupping in both eyes. Despite attempts to lower her IOPs further, they remained uncontrolled on maximal tolerated topical treatment.

A left then right uneventful trabeculectomy with perioperative 5-FU was carried out. Postoperatively, her topical medication was dexamethasone (Maxidex, Alcon) and chloramphenicol. Both IOPs were well controlled and she maintained the same preoperative visual acuity. Following surgery the patient noticed her right pupil was larger than the left.

On examination her right pupil was dilated with no direct or consensual response to light and no constriction to accommodation. There was also no reaction to either 0.125% or 4% pilocarpine drops. The left pupil had normal characteristics. Iris fluorescein angiography revealed delayed filling of the iris capillary plexus with large areas of non-perfusion on the right (Fig 1A). The left iris angiogram was normal (Fig 1B).

#### CASE 2

A 60 year old Turkish woman was referred with a high IOP in her right eye. She had no ophthalmic history of note. Her medical history was unremarkable and she took no medication.

On examination her best corrected visual acuities were 6/9 in the right eye and 6/6 in the left. Her anterior segments were normal and her IOPs were 40 mm Hg in the right eye and 15 in the left. Initial medical treatment failed to control her IOP and a right trabeculectomy was carried out 2 months after presentation. Since the operation her right IOP has been controlled but her right pupil has remained fixed and dilated (Fig 2A). On examination of her pupils, there was no right direct or consensual response to light or constriction to accommodation. There was also no reaction to either 0.125% or 4% pilocarpine drops. The left pupil was normal (Fig 2B). Iris



angiography was not possible in this case owing to her darkly pigmented irides.

## COMMENT

To our knowledge these are the first cases of Urrets-Zavalía syndrome to be reported after trabeculectomy. The clinical features of this syndrome following penetrating keratoplasty for various conditions are well established<sup>1-5</sup> but the pathophysiological mechanisms responsible for the mydriasis remain uncertain. Iris ischaemia secondary to postoperative rise in intraocular pressure has been suggested as the likely aetiology<sup>6,7</sup> with possible immunological,<sup>4</sup> neurological,<sup>8-10</sup> and structural iris<sup>6</sup> changes playing a role. We have discounted other possible causes of an internal ophthalmoplegia in our cases by ruling out Adie's pupil as there was no response to accommodation or to 0.125% pilocarpine. There was also no history of mydriatic use preoperatively or postoperatively and the pupil did not react to 4% pilocarpine. In addition, both patients had full extraocular movements with no ptosis and no other associated neurological signs suggestive of a third nerve palsy. There was no perioperative use of viscoelastic substances and both patients had minimal inflammation postoperatively. The angiography findings confirm the iris ischaemia as the most probable cause of the unilateral dilated pupil. Peripheral iridectomies performed as part of the trabeculectomy did not protect against this syndrome as is believed by some authors.<sup>6,11,12</sup> It is interesting to note that the syndrome occurred unilaterally in case 1 despite bilateral surgery. A similar finding is also reported by Sarrau *et al* following penetrating keratoplasty.<sup>4</sup>

R JAIN

A ASSI

I E MURDOCH

Moorfields Eye Hospital, City Road,  
London EC1V 2PD

Correspondence to: Mr I E Murdoch

Accepted for publication 15 September 1999

## Fluorescein angiography in altitude retinopathy

EDITOR,—High altitude retinopathy is a condition characterised by asymptomatic retinal haemorrhages that occurs in climbers at above 3000 metres. In some cases disc oedema and cotton wool spots have been described,<sup>1</sup> but in retrospect many of these cases may simply be a description of retinal changes occurring secondary to cerebral pathology or haematological changes related to altitude exposure. Little is known of altitude retinopathy because of the paucity of studies and difficulty in obtaining high quality fundal photographs and fluorescein angiography in the hostile high altitude environment.

Mountaineering is becoming increasingly popular and the commercialisation of trekking regions with good air and road links has created fast transit times between high altitudes and the office ophthalmologist. Here we document a case of altitude retinopathy in a fit normotensive subject with fluorescein angiography performed within 5 days of descent from altitude. The retinal haemorrhages appear to have occurred because of a local capillary disturbance, possibly due to the Valsalva manoeuvre, rather than to other systemic disturbances such as raised intracranial pressure as suggested in previous studies.<sup>2,3</sup>

## CASE REPORT

A 39 year old man noticed slight blurring of vision while climbing at 25 000 feet (7500 metres) on Mount Everest. On advice of the expedition medical officer, he descended almost immediately and within 5 days was reviewed at the Royal Berkshire Hospital in Reading. He was otherwise well and, apart from a mild headache, had experienced no symptoms of mountain sickness. Visual acuity was 6/5 in each eye although he still complained of "fogging areas" in his mid-peripheral vision. Anterior segments and intraocular pressures were normal, but both fundi showed widespread flame-shaped intraretinal haemorrhages radiating from the optic

discs (Fig 1) and one preretinal haemorrhage (Fig 1A). Venous filling pressure was normal on digital testing. There were no vitreal haemorrhages, disc oedema, cotton wool spots, or macular oedema. Fluorescein angiography showed masking defects corresponding to the haemorrhages, but no delay in filling of retinal veins or late disc leakage and no areas of focal leakage. Haematological investigations were normal: haemoglobin 16.6 g/dl, white cell count  $6.0 \times 10^9/l$ , platelets  $169 \times 10^9/l$ , international normalised ratio 1.0, and erythrocyte sedimentation rate 1 mm in the first hour. Two weeks later vision had returned to normal and retinal haemorrhages were reabsorbing spontaneously without further complications (Fig 1C, D). All haemorrhages had disappeared at final review 2 months after initial presentation.

## COMMENT

Altitude retinopathy was first described 30 years ago in a study of 1925 Indian soldiers overcome with mountain sickness in the Himalayas.<sup>2</sup> Many of these soldiers also had severe pulmonary and cerebral oedema and in subsequent reports it has always been difficult to isolate altitude retinopathy as a primary entity, since papilloedema, hyperviscosity, and other altitude related systemic changes can lead to the development of retinal haemorrhages and disc swelling through secondary mechanisms that also operate at sea level.<sup>3</sup> Venous filling pressure was normal and fluorescein angiography in this case report showed no delay in venous filling or evidence of leakage at the optic disc. This suggests that the observed haemorrhages are not a consequence of obstruction of venous outflow and more likely represent a primary retinal disturbance. A fluorescein angiogram of altitude retinopathy has been described only once before.<sup>4</sup> In that study there was similarly no disc leakage, but the patient had documented hyperviscosity secondary to chronic hypoxia and required haemodilution. It is therefore unclear to what extent hyperviscosity rather

- 1 Urrets-Zavalía A. A fixed, dilated pupil iritis atrophy and secondary glaucoma. A distinct clinical entity following penetrating keratoplasty in keratoconus. *Am J Ophthalmol* 1963;56:257-65.
- 2 Picetti B, Fine M. Keratoplasty in children. *Am J Ophthalmol* 1966;61:782-9.
- 3 Urrets-Zavalía A. Management of keratoplasty in the early stages. *Br J Ophthalmol* 1977;61:89-91.
- 4 Sarrau H, Offret H, Binaghi M. A propos du syndrome d'Urrets-Zavalía. *Bull Soc Ophthalmol Fr* 1978;78:579-84.
- 5 Flamment J, Schraub M, Guimaraes R, *et al*. Syndrome d'Urrets-Zavalía et cataracta glaucomatosa. *Ophthalmologica* 1984;189:186-94.
- 6 Davies PD, Ruben M. The parietic pupil: its incidence and aetiology after keratoplasty for keratoconus. *Br J Ophthalmol* 1975;59:223-8.
- 7 Tuft SJ, Buckley RJ. Iris ischaemia following penetrating keratoplasty for keratoconus. (Urrets-Zavalía syndrome). *Cornea* 1995;14:618-22.
- 8 Uribe LE. Fixed pupil following keratoplasty. Evaluation of six cases. *Am J Ophthalmol* 1967;63:1682-6.
- 9 Bonnet M, Lemarchands H, Martin J. Prophylaxie et traitement du syndrome 'mydriase irréductible-atrophie irienne progressive' succédant à une keratoplastie perforante pour keratocone. *Ann Oculist* 1969;202:1139-46.
- 10 Lagoutte F, Thienpont Ph, Comte P. Proposition de traitement du syndrome d'Urrets-Zavalía. *J Fr Ophthalmol* 1983;6:291-4.
- 11 Poulliquen Y, Cueto P. L'influence de l'iridectomie ou de l'iridotomie sur l'évolution des greffes transfixiantes. *Arch Ophthalmol* 1973;33:695-8.
- 12 Naumann GO. Iris ischaemia following penetrating keratoplasty for keratoconus. *Cornea* 1997;16:120.

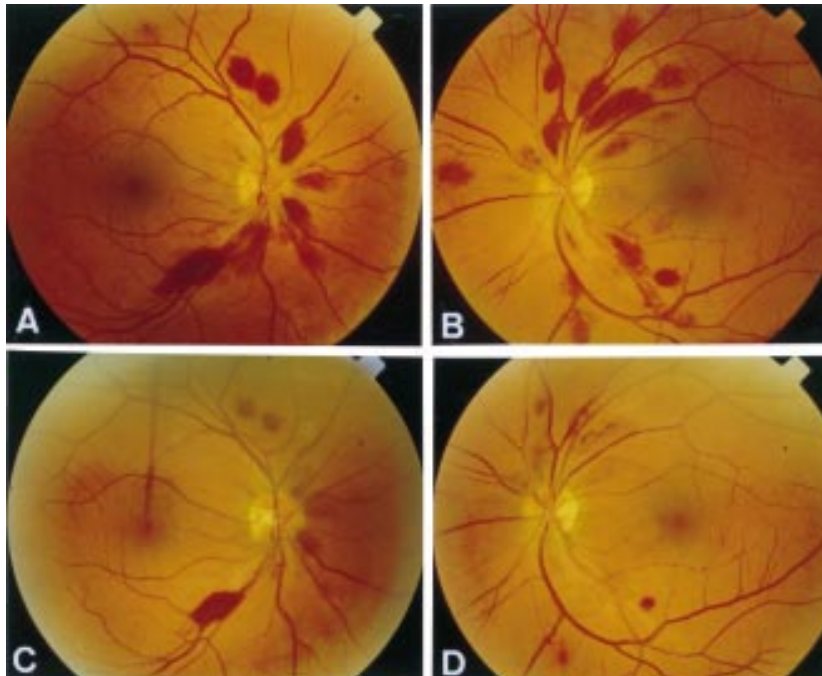


Figure 1 Fundal appearances of altitude retinopathy at presentation (A and B) and at follow up 2 weeks later (C and D).

than altitude alone had contributed to the retinal haemorrhages seen.

Two prospective studies have shown that the incidence of retinal haemorrhage is greater in subjects exercising heavily at altitude, but is not related to the number of altitude related symptoms.<sup>1-5</sup> Similar retinal changes are seen after Valsalva manoeuvres at sea level<sup>6</sup> and pathological evidence suggests that haemorrhages at altitude are similar and originate from ruptured capillaries that become grossly dilated in response to chronic hypoxia.<sup>7</sup> This case reports retinal haemorrhages occurring without disc oedema or venous stasis in an otherwise healthy subject exercising at altitude. It seems that the most likely mechanism is that of Valsalva retinopathy.

We are grateful to Professor Alan Bird for his helpful comments on the manuscript.

R E MACLAREN  
K IKRAM  
S J TALKS

Division of Ophthalmology, Royal Berkshire Hospital,  
Reading RG1 5AN

Correspondence to: Mr Robert MacLaren, Western Eye Hospital, Marylebone Road, London NW1 5YE  
Accepted for publication 25 October 1999

- 1 McFadden DM, Houston CS, Sutton JR, *et al.* High altitude retinopathy. *JAMA* 1981; 245:581-6.
- 2 Singh I, Khanna PK, Srivastava MC, *et al.* Acute mountain sickness. *N Engl J Med* 1969;280: 175-84.
- 3 Shults WT, Swan KC. High altitude retinopathy in mountain climbers. *Arch Ophthalmol* 1975; 93:404-8.
- 4 Lang GE, Kuba GB. High altitude retinopathy. *Am J Ophthalmol* 1997;123:418-20.
- 5 MacLaren RE. Retinal haemorrhage in Himalayan mountaineers. *J R Army Med Corps* 1995; 141:25-8.
- 6 Duane TD. Valsalva haemorrhagic retinopathy. *Am J Ophthalmol* 1972;75:637-42.
- 7 Lubin JR, Rennie D, Hackett P, *et al.* High altitude retinal haemorrhage: a clinical and pathological case report. *Ann Ophthalmol* 1982; 14:1071-6.

### Panuveitis as a presenting feature of giant cell arteritis

EDITOR.—It is unusual for bilateral panuveitis to be a presenting feature of giant cell arteritis. We present a patient diagnosed as having giant cell arteritis who had developed panuveitis some months previously for which the arteritis was probably responsible.

#### CASE REPORT

A 79 year old woman presented with gradual blurring and photophobia of 6 weeks' duration. There was no significant ocular history. She had had a recent history of weight loss and anorexia for which she underwent endoscopy which revealed a duodenal ulcer. Ophthalmological examination revealed a visual acuity of 6/12 in both eyes. There was no relative afferent pupillary defect. There were bilateral keratic precipitates and cells in ante-

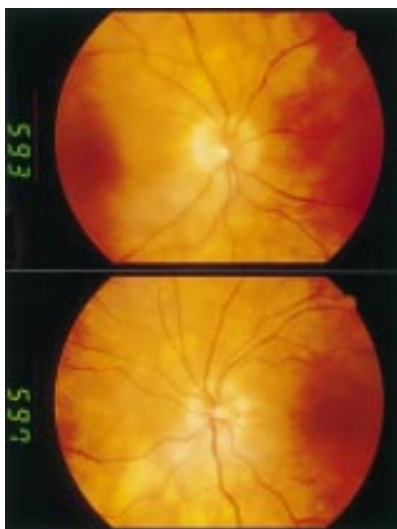


Figure 1 Bilateral disc oedema, multiple peripapillary creamy lesions, and left disc haemorrhage.

rior chamber and vitreous. The fundus examination revealed bilateral disc oedema, left disc haemorrhages, and multiple raised creamy subretinal peripapillary lesions (Fig 1). The general physical examination was essentially normal. Investigations revealed a hypochromic microcytic anaemia, an erythrocyte sedimentation rate of 87 mm in the first hour, normal angiotensin converting enzyme level, chest x ray, computed tomograph scan of head, orbits, abdomen, and pelvis, abdominal ultrasonography, and autoantibody profile. With the diagnosis of bilateral panuveitis she was started on systemic and topical steroids. The patient improved symptomatically on treatment with the visual acuity improving to 6/9 in both eyes. Ophthalmological examination revealed quiet anterior segments, slightly pale discs with flat subretinal peripapillary lesions, and there were no cells in the vitreous. Systemic steroids were gradually tapered over next few months. A year later she complained of further blurring, continuing weight loss, myalgia, and arthralgia. On examination she had visual acuities of 6/12 in the right eye and 6/18 in the left eye with quiet anterior segments, no relative afferent pupillary defect, and fundus changes similar to the previous episode with bilateral disc oedema, raised peripapillary creamy subretinal lesions with cells in the vitreous. She was also found to have non-pulsatile, non-tender temporal arteries. A temporal artery biopsy was performed which showed evidence of giant cell arteritis.

#### COMMENT

Partial or complete visual loss is the most common and the most serious ophthalmic complication of giant cell arteritis. Because

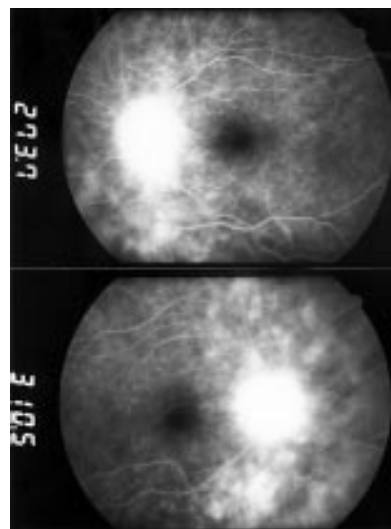


Figure 2 Fluorescein leakage from the subretinal peripapillary lesions and optic disc.

giant cell arteritis is a potentially blinding disease and its early diagnosis is the key to preventing blindness, it is important to recognise its various ocular manifestations.<sup>1</sup> Panuveitis as a presenting feature is uncommon and to the best of our knowledge this is the first report of a subacute panuveitis as a presenting feature of giant cell arteritis. There is one another case reported where the presenting feature was acute anterior and posterior uveitis.<sup>2</sup> The fluorescein angiogram showed leakage from the subretinal peripapillary lesions and the optic discs (Fig 2) and there was no wedge shaped alteration suggestive of choroidal ischaemia.<sup>3</sup> Although this patient had a history of weight loss and high erythrocyte sedimentation rate at presentation the diagnosis of giant cell arteritis was not considered because of this unusual presentation. Serum angiotensin converting enzyme levels, chest x ray, computed tomograph scans of abdomen and pelvis were done to exclude sarcoidosis and lymphoma. In conclusion we describe a case in which giant cell arteritis offers a possible explanation for the clinical picture of subacute panuveitis in the absence of an exhaustive search for an underlying cause.

C V RAJESH  
M COLE

Royal Devon and Exeter Hospital, Exeter EX1 2ED

Correspondence to: Dr Rajesh  
Accepted for publication 22 September 1999

- 1 Hayreh SS, Podhajsky PA, Zimmerman B. Ocular manifestations of giant cell arteritis. *Am J Ophthalmol* 1998;125:509-20.
- 2 Dasgupta B, Pitzalis C, Panayi GS. Inflammation of the uveal tract as a presenting feature of temporal arteritis. *Ann Rheum Dis* 1989;48:964-5.
- 3 Amalric P. Acute choroidal ischaemia. *Trans Ophthalmol Soc UK* 1971;91:305-22.