

Late onset lattice corneal dystrophy with systemic familial amyloidosis, amyloidosis V, in an English family

Helen S Stewart, Rahat Parveen, Alan E Ridgway, Richard Bonshek, Graeme C M Black

Abstract

Aims—To establish a clinical and molecular diagnosis in a family with late onset lattice corneal dystrophy.

Methods—Linkage analysis, single strand conformation polymorphism (SSCP) analysis, and direct sequencing of genomic DNA were performed. A review of the patients' clinical symptoms and signs was undertaken.

Results—Linkage to chromosome 9q34 was established and a mutation in the gelsolin gene was found in affected individuals. Numerous symptoms experienced by the patients were attributable to this mutation.

Conclusion—A diagnosis of amyloidosis type V (familial amyloidosis, Finnish type, FAF/Meretoja syndrome/gelsolin related amyloidosis) was made. This is the first case of amyloidosis type V described in the UK. This emphasises the importance of recognition of the extraocular manifestations of eye disease both in the diagnosis and management of the patient. In addition, these findings can help molecular geneticists in their search for disease-causing mutations.

(*Br J Ophthalmol* 2000;84:390-394)

Department of
Medical Genetics and
Regional Genetics
Service, St Mary's
Hospital, Manchester
M13 0JH

H S Stewart
R Parveen
G C M Black

School of Biological
Sciences and
Departments of Dental
Medicine and Surgery,
University of
Manchester,
Manchester M13 9PT
H S Stewart

Manchester Royal Eye
Hospital, Manchester
M13 9WH

A E Ridgway
R Bonshek
G C M Black

Department of
Pathological Sciences,
University of
Manchester,
Manchester M13 9PT
R Bonshek

Correspondence to:
Graeme C M Black

Accepted for publication
8 December 1999

Materials and methods

PATIENT ASCERTAINMENT

Twenty four families with corneal dystrophy were ascertained by the Manchester Royal Eye Hospital Cornea Service. One was a three generation family with atypical LCD (Fig 1A). Ethical approval was obtained from Manchester Health Commission, research ethics committee (central), reference CM/96/043. Informed consent was obtained from those participating in this study. Three symptomatic family members were reviewed clinically: symptoms and signs related to LCD and systemic amyloidosis were sought.

MOLECULAR ANALYSIS

Genomic DNA was extracted from peripheral blood lymphocytes using standard techniques.⁷

The polymerase chain reaction (PCR) was carried out under standard conditions in 20 µl reaction volumes each containing 10 pmol each of the forward and reverse primers, 50 ng of genomic DNA, 3 mM each of dATP, dCTP, dGTP, and dTTP (dNTPs), 10X Anglian PCR buffer containing 670 mM TRIS-HCl pH 8, 37 mM MgCl₂, 166 mM NH₄SO₄, 1.7 mg/ml BSA, and 0.1 units *Taq* DNA polymerase (Gibco BRL). After an initial denaturation step at 96°C for 5 minutes, the samples were processed through 32 cycles of amplification consisting of 94°C for 1 minute, primer annealing temperature for 1 minute, and extension at 72°C for 1 minute. The final extension step was lengthened to 10 minutes at 72°C.

PCR products of genomic DNA were analysed by linkage analysis, using microsatellite markers for chromosomes 5q31 and 9q34. The following forward (F) and reverse (R) primers were used: D5S399F (5'-GAGTGTATCAGTCAGGGTGC-3'), D5S399R (5'-GTCCTCAAGTTCATAA TCAA-3'), D5S363F (5'-TTCTACCTGNCCTTTCCCTCT-3'), D5S363R (5'-CATTCCCTCATTCCCTCATTCC-3'), GSN.PCR1.1 (5'-CAGCCAGCTTTGAGACAAC-3'), and GSN.PCR1.2 (5'-TCGCAAGCATA TGACTGTAA-3') (MWG Biotech).⁸ The annealing temperatures were 55°C, 58°C, and 68.5°C, respectively. Products were extracted once with phenol and resolved on an 8% polyacrylamide gel and silver stained using standard protocols.⁹

SSCP analysis of PCR products was performed using conventional methods.¹⁰ The primers (F and R) used were GSN.SSCP1 (5'-GCCAGGTCCAGGATGAA-3') and GSN.SSCP2 (5'-AAGCACGTGGTACCCAAC-3') (MWG Biotech). The annealing temperature

The corneal dystrophies are a clinically and genetically heterogeneous group of disorders. The lattice corneal dystrophies (LCD) are characterised by the accumulation of amyloid within the cornea. Different subtypes exist: type I, IIIA, and a form of late onset LCD are due to mutation of the TGFBI gene on chromosome 5q31 and type II is due to mutation of the gelsolin gene on chromosome 9q34.¹⁻⁴ Type II LCD is associated with systemic amyloidosis as amyloidosis type V/Meretoja syndrome/familial amyloidosis, Finnish type (FAF)/gelsolin related amyloidosis (OMIM No 105120).^{5,6} Amyloidosis type V was first recognised in Finland and although rare cases have been reported outside Finland, none has been described previously in the UK. We report the first case of amyloidosis type V in the UK and emphasise the importance of recognition of the extraocular manifestations of eye disease both in the diagnosis and management of the patient and as a pointer to molecular geneticists in their search for disease-causing mutations.

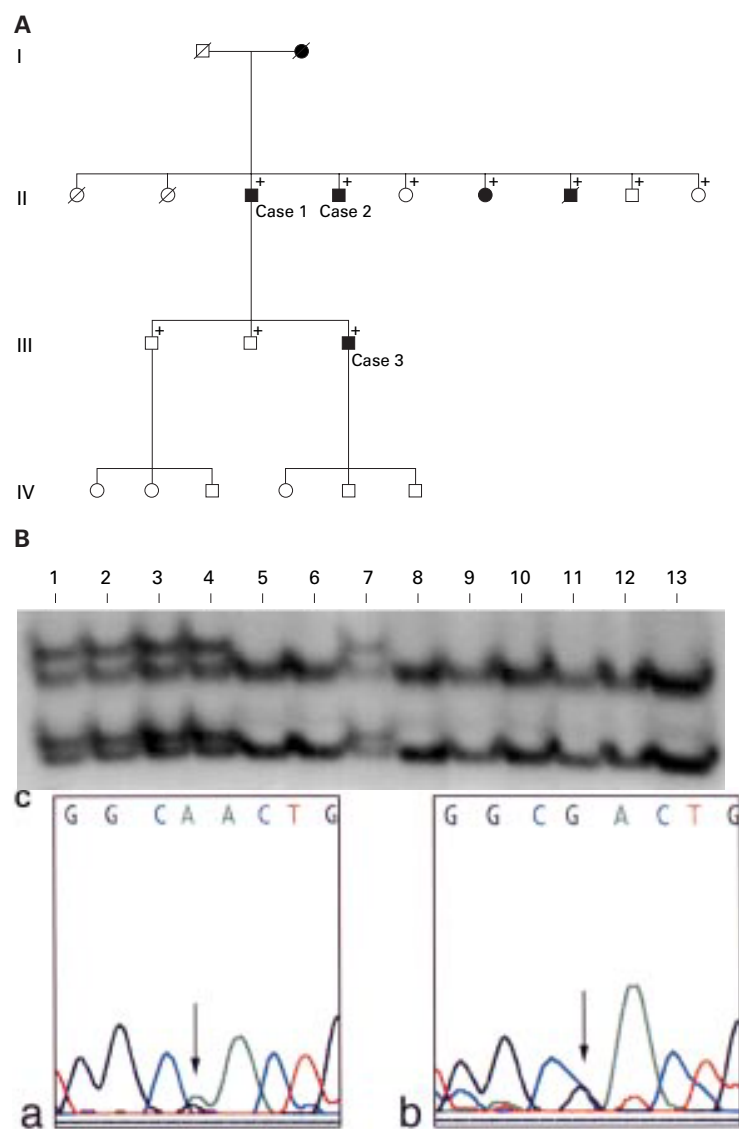


Figure 1 (A) Pedigree of family. Affected members shown in black and those contributing DNA marked with + symbol. (B) SSCP analysis of family. Lanes 1, 2, 3, 4, 7: affected. Lanes 5, 6, 8, 9, 10: unaffected family members. Lanes 11, 12, 13: unrelated control individuals. (C) Sequence analysis of the gelsolin gene (a) mutated showing a G to A transition at nucleotide 654, (b) normal.

was 64°C. PCR products were mixed with an equal volume of formamide loading dye, denatured, and loaded onto a 6% acrylamide/bisacrylamide gel. The PCR products were approximately 150 base pairs in length. They were subjected to electrophoresis at 350 V for 17 hours at 4°C and silver stained using standard protocols. In cases where an SSCP shift was observed direct sequencing of PCR products was performed using a dye terminator cycle sequencing kit (Perkin Elmer, Applied Biosystems Ltd) using a fluorescent sequencer (ABI 373), according to the manufacturers' instructions.

Results

MOLECULAR ANALYSIS

Eleven of the 24 families ascertained had LCD and were analysed for mutations within the TGFBI gene on chromosome 5q31. Mutations were defined for both early onset and late onset

LCD in 8/11 families (data not shown). In the three families in which mutations were not defined, the gelsolin locus on chromosome 9q34 was investigated. The gelsolin gene is mutated in type II LCD and is associated with systemic amyloidosis type V.⁴

Of the three families only one was large enough to undertake a limited genetic analysis (Fig 1A). Analysis of this family with the microsatellite GSN.PCR1, which lies within the gelsolin locus was consistent with linkage to the region and demonstrated no recombination between the disease phenotype and that locus.⁸ Since a single residue has been shown to be mutated in all cases described to date this region of the gene was amplified.^{4 11 12} SSCP analysis of the amplicon demonstrated a mobility shift which was present in affected members. No shift was observed in unaffected family members above the usual age of onset (Fig 1B'). Sequence analysis showed the presence of a G to A transition at nucleotide 654 of the gelsolin gene in affected individuals (Fig 1C). This causes the substitution of aspartic acid by asparagine at amino acid residue 187. The mutation was not found in unaffected family members or unrelated, unaffected controls.

CLINICAL DATA

Case 1

The proband was an 80 year old man. He had presented in middle life with bilateral corneal dystrophy not associated with recurrent erosions. He had undergone a left penetrating keratoplasty which had been complicated by two episodes of infection leading to abscess formation. He had a complicated medical history with a plethora of symptoms. He was reported to have suffered a stroke but in fact had a gradual onset of facial drooping, causing his eyebrows to fall over his eyes, necessitating surgery. He was unable to shut his eyes completely and had undergone a left tarsorrhaphy and was awaiting the same operation on the right. He wore a nasal prong to prevent collapse and occlusion of his nose. His lower lip drooped causing drooling and he ate by sucking food into his mouth. He had suffered from bilateral carpal tunnel syndrome for which he had surgery without benefit. His symptoms had been attributed to cervical arthritis causing nerve compression. He suffered cardiac arrhythmias, carotid artery stenosis, hiatus hernia, and inguinal herniae.

On examination he had bilateral corneal dystrophy, consisting of fine lattice lines maximal in the corneal peripheries without intervening stromal haze. His skin was thin, waxy, and oedematous. He had a smooth forehead, with scars from his previous surgery (Fig 2A, B). Examination of his cranial nerves revealed a full range of eye movements although he was unable to close his eyes or raise his eyebrows at all. He had normal muscles of mastication and normal facial sensation. Corneal sensation was significantly reduced (Fig 3A). He was unable to smile voluntarily or spontaneously. His hearing was good though he may have suffered from vertigo. His palate moved normally, as did

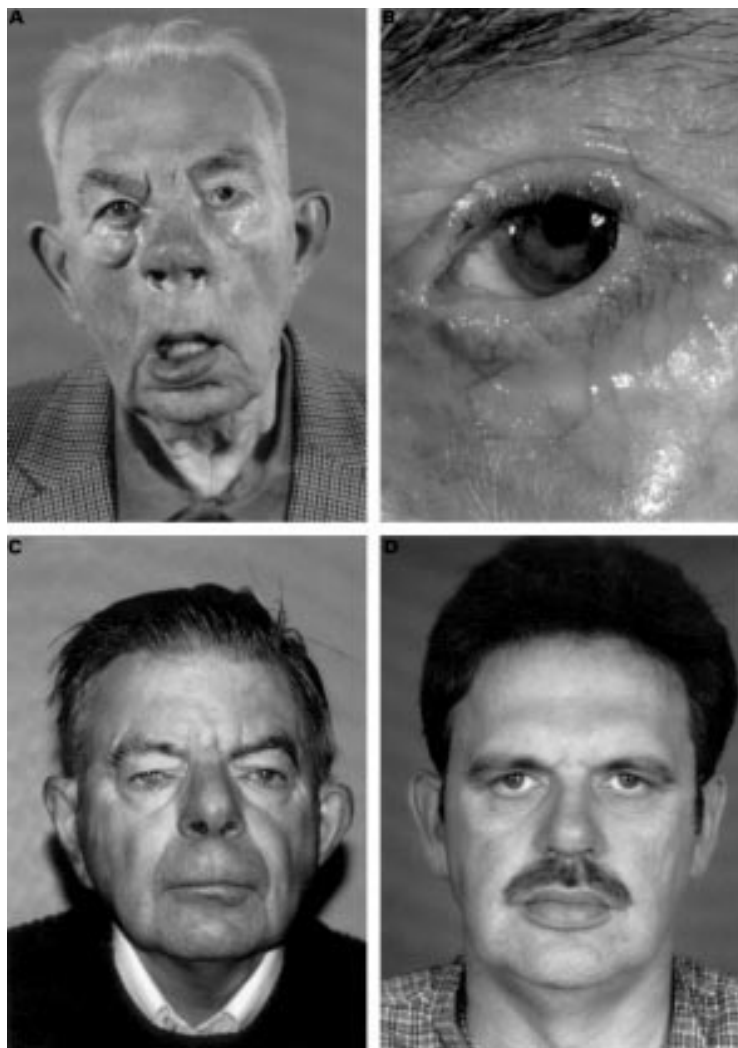


Figure 2 Clinical photographs of cases. (A) Case 1, illustrating the patient's smooth brow, drooping face and lips, nasal prong, left tarsorrhaphy, and waxy skin. (B) Left eye of patient (case 1), illustrating previous tarsorrhaphy and full thickness graft. (C) Case 2, illustrating his smooth brow, drooping upper lids, and waxy skin. There is extensive scarring of the right eye. (D) Case 3, illustrating early coarsening of the facial features and a cranial neuropathy causing a smooth brow, drooping face, and full lower lip. (Photographs reproduced with permission of patients.)

his tongue. He had bilaterally scarred wrists with good power of the small muscles in his hands and normal sensation though he complained of a poor grip. He had no proteinuria.

Light microscopy of his corneal button showed amyloid deposition (Fig 4A, B).

Case 2

The 66 year old brother of the proband had a 19 year history of glaucoma for which he had undergone a bilateral trabeculectomies. His visual acuity was 6/60 in each eye and was sufficient to allow him to be mobile. He had at least two protracted episodes of right corneal ulceration and had been noted to have bilateral lattice dystrophy. He suffered from episodes of loss of consciousness or collapse, unaccompanied by tonic, clonic movement, for which he was treated with carbamazepine. He denied symptoms of postural hypotension. He was aware of facial drooping but had not required treatment and he had no symptoms of a peripheral neuropathy. He was found to have a mildly raised plasma viscosity (1.81) and a

polyclonal increase in IgG (20.3 g/l) but full blood count, liver function tests, and autoimmune profiles were normal so serious systemic disease was excluded.

On examination he had right band keratopathy with extensive scarring and evidence of previous ulceration. Both corneas showed evidence of lattice deposits. He had bilateral corneal hypoesthesia and lagophthalmos. He had bilaterally cupped discs (last documented C/D ratio was 0.9 bilaterally) with severe glaucomatous field loss. He had weakness of muscles supplied by the VIIth cranial nerve and a drooping forehead and lower lip (Fig 2C). There was no evidence of carpal tunnel syndrome and he had no proteinuria.

Case 3

The 49 year old son of the proband was examined in view of family history of LCD and found to have lattice deposits in his corneas. He suffered from photophobia and night glare. He was aware of lid and lip drooping and twitching of his forehead. He complained of dysarthria and food falling out of his mouth when eating.

On examination multiple fine peripheral lattice lines were seen in both his corneas, the intervening stroma being clear (Fig 3B). His face twitched visibly, he had drooping lids, a full lower lip, coarse nose, but his skin was not waxy. He had no corneal or conjunctival sensation though he had normal sensation to the remainder of his face. He had reduced bulk of his muscles of mastication and weakness of eye closure (Fig 2D). He had reduced bulk and weakness of his abductor pollicis brevis but

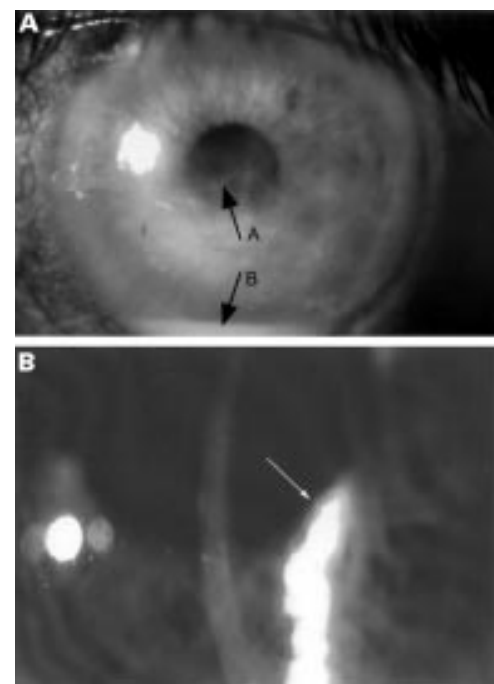


Figure 3 (A) Photograph of the anterior cornea of case 1, before first penetrating keratoplasty. Lattice lines are seen centrally (arrow A). The patient has absent corneal sensation which has led to secondary infection and hypopyon formation (arrow B). (B) Photograph of slit lamp examination of case 3 illustrating stromal lattice deposits (arrow).

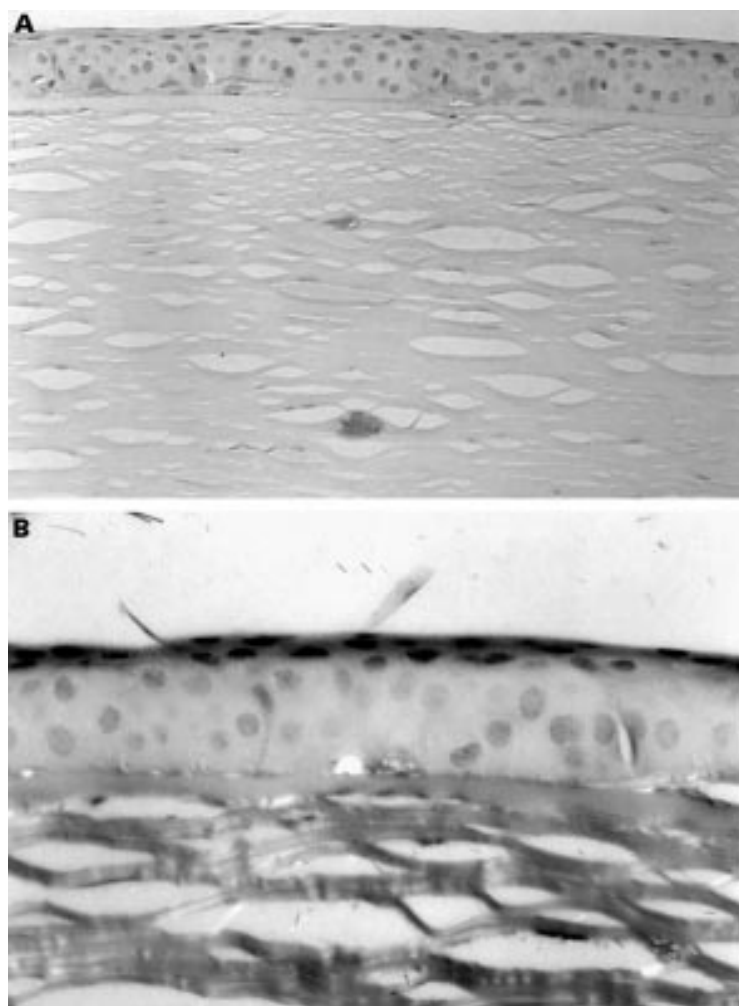


Figure 4 (A) Light microscopy of corneal button of case 1, stained with Congo red, under medium power. Small to moderate sized amyloid deposits are shown in the stroma, as well as above and below Bowman's layer. (B) Light microscopy of corneal button of case 1, stained with Congo red, under high power with cross polarisation. Typical birefringence of a subepithelial lattice dystrophy amyloid deposit is shown.

Table 1 Clinical findings in cases presented

Case	LCD type II	Glaucoma	Cranial neuropathy	Peripheral neuropathy	Autonomic neuropathy	Renal involvement
1	+	-	+	+	+	-
2	+	+	+	-	+	-
3	+	-	+	+	-	+

normal sensation in his hands. Examination of his urine revealed 30 mg/dl protein on one occasion, otherwise his renal function is normal (Table 1).

Other cases

The mother of the proband was thought to have been affected with recurrent corneal erosion and drooping lower lip. She died in her early 70s of a stroke. Another brother of the proband needed a pacemaker for cardiac arrhythmias and was noted to have a drooping face.

Discussion

The LCDs are characterised by amyloid accumulation within the cornea. Types I and IIIA have no systemic features and are distinguished by age of onset and morphology of lattice

deposits. They are inherited in an autosomal dominant manner and result from mutations in the TGFBI gene on chromosome 5q31.¹⁻³ They share a common pattern of variable recurrent erosions with the gradual development of central anterior lattice lines spreading deeper and peripherally with age but never affecting the limbal region. Type III LCD is a late onset form of autosomal recessive inheritance, the underlying molecular aetiology of which has not been defined.^{13 14} Type II LCD is accompanied by systemic amyloidosis (amyloidosis type V). The corneal features are subtly different from other LCDs: the lattice lines are fine, extend from front to back of the stroma, and are maximal peripherally in contradistinction to the findings in type I and IIIA LCD. Visual acuity is retained until the sixth decade and erosions occur less frequently than in type I LCD^{5 15} and then only later in life, possibly related to the associated lagophthalmos rather than to epithelial instability.

Amyloidosis type V was first recognised in the Finnish population where it occurs with high frequency,⁵ but rare cases have been described in Switzerland, Czechoslovakia, Holland, the USA, Denmark, and Japan.^{6 12 16-18} Similarities were shown between the amyloid deposits found in amyloidosis type V and the gelsolin protein.^{19 20} Gelsolin is an actin severing protein which prevents the toxic effects of actin in the extracellular space and allows rapid migration of cells involved in wound healing and inflammation.²¹

Two mutations in the gelsolin gene on chromosome 9q34 have been shown to cause amyloidosis type V. The first is a G to A transition at nucleotide 654 which converts aspartic acid to asparagine at residue 187.⁴ This is the common mutation found in all Finnish patients as well as in the American and Japanese families described.^{10 22} This mutation was also present in the English family we present. The second mutation is a G to T transversion, also at nucleotide 654, which converts aspartic acid to tyrosine and has been found in Dutch and Czech families.¹² Thus identical mutations within this gene have previously been shown to have arisen separately in different populations.^{11 23} The family we present has no known Finnish ancestry although haplotype analysis has not been undertaken to confirm that this is a mutation of independent origin.

The cardinal features of amyloidosis type V are a triad of ophthalmic (LCD type II, glaucoma), neurological (cranial, peripheral, and autonomic neuropathies), and dermatological (amyloid deposition in the skin) manifestations.²⁴ Renal and cardiac involvement have been described.²⁵⁻²⁷

The ophthalmic features of cases 1, 2, and 3 were typical of LCD type II. Case 1 suffered slowly progressive loss of visual acuity and underwent penetrating keratoplasty. This was complicated by recurrent infection and corneal erosion. Similar problems have been noted previously in a patient whose penetrating keratoplasty was complicated by a neurotrophic persistent epithelial defect.²⁸ The integrity of a corneal graft is dependent on an intact

nerve supply to the cornea which is absent in amyloidosis type V as a result of cranial neuropathy. Problems with grafts may be anticipated in these patients and raise the question of the value of the procedure in amyloidosis type V. In addition, glaucoma is a known complication of amyloidosis type V and was observed in case 2.¹⁵

Cranial nerve involvement has been found in all patients with amyloidosis type V particularly affecting the facial nerve.^{29,30} All three cases we describe had cranial neuropathies with involvement of cranial nerves V and VII. Each suffered progressive drooping of the face: in case 1 this was attributed to a stroke despite the gradual onset of the problem. The drooping was of such severity that surgery was required, as previously described.²⁸ Carpal tunnel syndrome has only recently been recognised³⁰ and was present in cases 1 and 3. In case 1 it was unsuccessfully treated which, since carpal tunnel syndrome in amyloidosis type V is thought to be due to axonal degeneration is perhaps unsurprising.

The major manifestations of cardiac involvement in amyloidosis type V are significant decrease in heart rate variation and orthostatic hypotension, secondary to autonomic nervous dysfunction.²⁵ Case 1 suffered cardiac arrhythmias of unknown aetiology, potentially related to amyloidosis. Case 2 was diagnosed as epileptic although the episodic loss of consciousness was atypical and the aetiology was unproved: the possibility that the cause relates to autonomic dysfunction cannot be excluded.

This is the first description of a pedigree of patients with amyloidosis type V in the UK and demonstrates the importance of recognising the ophthalmic complications for appropriate management of the condition. While affected members, who were treated in four separate centres, were known to have LCD the subtype was not defined and the significance of the plethora of symptoms remained unrecognised. We believe that establishment of the diagnosis will lead to improved multidisciplinary care. In addition, the disorder is amenable to molecular confirmation for affected and presymptomatic individuals: this further facilitates diagnosis and enhances management.

It is also important to recognise that, although historically associated with the Finnish population, the condition can occur in any population and should be considered in the differential diagnosis of LCD of relatively late onset disease. The concept of a geographically limited disorder, such as "familial amyloidosis, Finnish type, FAF", must be treated with caution since it may lead to that condition being dismissed as a possible diagnosis in other areas of the world.

GCMB is a Wellcome Trust Clinician Scientist Fellow (ref 51390/Z).

We thank Professor M J Dixon for his expert advice and Professor D L Easty for access to his patients' records.

1 Munier FL, Korvatska E, Djemai A, et al. Kerato-epithelin mutations in four 5q31-linked corneal dystrophies. *Nat Genet* 1997;15:247–51.

- 2 Yamamoto S, Okada M, Tsujikawa M, et al. A kerato-epithelin (β ig-h3) mutation in lattice corneal dystrophy type IIIA. *Am J Hum Genet* 1998; 62: 719–22.
- 3 Stewart H, Black G, Donnai, D, et al. A mutation within exon 14 of the TGFBI (BIG-H3) gene on chromosome 5q31 causes an asymmetrical, late-onset form of lattice corneal dystrophy. *Ophthalmology* (in press).
- 4 Maury CPJ, Kere J, Tolvanen R, et al. Finnish hereditary amyloidosis is caused by a single nucleotide substitution in the gelsolin gene. *FEBS Lett* 1990;276:75–7.
- 5 Meretoja J. Familial systemic amyloidosis with lattice dystrophy of the cornea, progressive cranial neuropathy, skin changes, and various internal symptoms: a previously unrecognized heritable syndrome. *Ann Clin Res* 1969;1: 314–24.
- 6 Donders PC, Blanksma LJ, Meretoja syndrome. Lattice corneal dystrophy of the cornea with hereditary generalized amyloidosis. *Ophthalmologica* 1979;178:173–80.
- 7 Sambrook J, Fritsch EF, Maniatis T. *Molecular cloning: a laboratory manual*. 2nd ed. Cold Spring Harbor, New York: Cold Spring Harbor Laboratory, 1989.
- 8 Kwiatkowski DJ, Perman S. Dinucleotide repeat polymorphism at the GSN locus (9q32–34). *Nucleic Acid Res* 1991; 19:967.
- 9 Merrill CR, Switzer RC, Van Keuren ML. Trace polypeptides in cellular extracts and human body fluids detected by two-dimensional electrophoresis and a highly sensitive silver stain. *Proc Natl Acad Sci USA* 1979;76:4335–9.
- 10 Ellis R. *Molecular diagnosis of genetic diseases*. 1st ed. London: Humana Press, 1996:Chapter 2:17–35.
- 11 Steiner RD, Paunio T, Uemichi T, et al. Asp187Asn mutation of gelsolin in an American kindred with familial amyloidosis, Finnish type (FAP IV). *Hum Genet* 1995;95: 327–30.
- 12 de la Chapelle A, Tolvanen R, Boysen G, et al. Gelsolin-derived familial amyloidosis caused by asparagine or tyrosine substitution for aspartic acid at residue 187. *Nat Genet* 1992;2:157–60.
- 13 Hida T, Tsubota K, Kigasawa K, et al. Clinical features of a newly recognized type of lattice corneal dystrophy. *Am J Ophthalmol* 1987;104:241–8.
- 14 Hida T, Proia AD, Kigasawa K, et al. Histopathologic and immunohistochemical features of lattice corneal dystrophy type III. *Am J Ophthalmol* 1987;104:249–54.
- 15 Kivela T, Tarkkanen A, Frangione B, et al. Ocular amyloid deposition in familial amyloidosis, Finnish: an analysis of native and variant gelsolin in Meretoja's syndrome. *Invest Ophthalmol Vis Sci* 1994;35:3759–69.
- 16 Sack GH Jr, Dumars KW, Gummerson KS, et al. Three forms of dominant amyloid neuropathy. *Johns Hopkins Med J* 1981;149:239–47.
- 17 Boysen G, Galassi G, Kamieniecka Z, et al. Familial amyloidosis with cranial neuropathy and lattice corneal dystrophy. *J Neurol Neurosurg Psychiatry* 1979;42:1020–30.
- 18 Tsundo I, Awano H, Kayama H, et al. Idiopathic AA amyloidosis manifested by autonomic neuropathy, vestibulo-cochleopathy and lattice corneal dystrophy. *J Neurol Neurosurg Psychiatry* 1994;5:635–7.
- 19 Maury CPJ. Isolation and characterization of cardiac amyloid in familial amyloid polyneuropathy type IV (Finnish): relation of the amyloid protein to variant gelsolin. *Biochim Biophys Acta* 1990;1096:84–6.
- 20 Haltia M, Ghiso J, Prelli F, et al. Amyloid in familial amyloidosis, Finnish type, is antigenically and structurally related to gelsolin. *Am J Pathol* 1992;136:1223–8.
- 21 Witke W, Sharpe AH, Hartwig JH, et al. Hemostatic, inflammatory and fibroblast responses are blunted in mice lacking gelsolin. *Cell* 1995;81:41–51.
- 22 Sanuda Y, Shimizu T, Nakase H, et al. Inherited amyloid polyneuropathy IV (gelsolin variant) in a Japanese family. *Ann Neurol* 1993;33:57–62.
- 23 Paunio T, Sunada Y, Kiuru S, et al. Haplotype analysis in gelsolin-related amyloidosis reveals independent origin of identical mutation (G654-A) in Finland and Japan. *Human Mutation* 1995;6:60–5.
- 24 Kiuru S. Gelsolin-related familial amyloidosis, Finnish type (FAF) and its variants found worldwide. *Amyloid—Int J Exp Clin Invest* 1998;5:55–66.
- 25 Kiuru S, Matikainen E, Kupari M, et al. Autonomic nervous system and cardiac involvement in familial amyloidosis, Finnish type (FAF). *J Neurol Sci* 1994;126:40–8.
- 26 Maury CP. Homozygous familial amyloidosis, Finnish type: demonstration of glomerular gelsolin-derived amyloid and non-amyloid tubular gelsolin. *Clin Nephrol* 1993;40:53–6.
- 27 Fernandez AL, Herreros JM, Monzonis AM, et al. Heart transplantation for Finnish type familial systemic amyloidosis. *Scand Cardiovasc J* 1997;31:357–9.
- 28 Stark T, Kenyon KR, Hanninen LA, et al. Clinical and histopathologic studies of two families with lattice corneal dystrophy and familial systemic amyloidosis (Meretoja syndrome). *Ophthalmology* 1991;98:1197–206.
- 29 Kiuru S. Familial amyloidosis of the Finnish type (FAF). A clinical study of 30 patients. *Acta Neurol Scand* 1992;86: 346–53.
- 30 Kiuru S, Seppalainen AM. Neuropathy in familial amyloidosis Finnish type (FAF): electrophysiological studies. *Muscle and Nerve* 1994;17:299–304.