

## LETTERS TO THE EDITOR

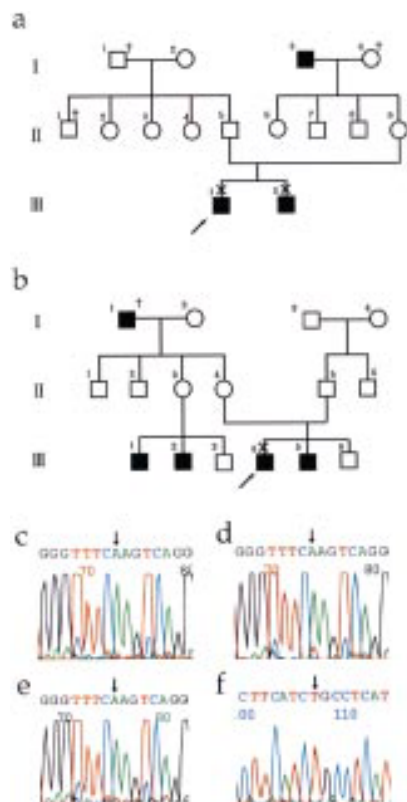
### Different mutation of the *XLRS1* gene causes juvenile retinoschisis with retinal white flecks

EDITOR.—Juvenile retinoschisis is an X linked inherited vitreoretinal degeneration that results in splitting of the superficial layers of the retina.<sup>1</sup> Retinal white flecks are rarely present in retinoschisis.<sup>2</sup> Because we have three families with retinoschisis with retinal white flecks, the clinical features and genetic analysis of both *XLRS1* and *RDH5* genes were investigated in these families to characterise this unusual fundus finding.

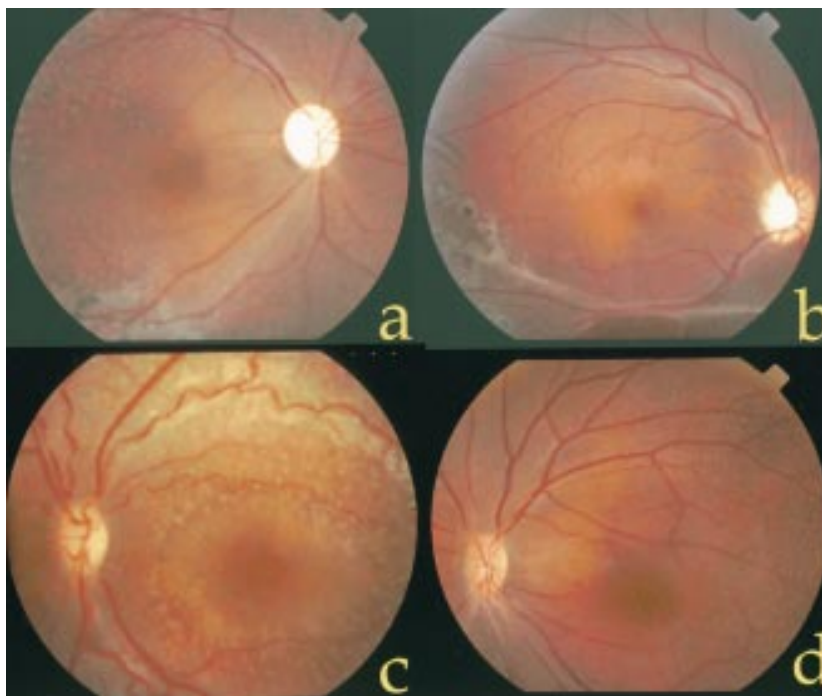
#### CASE REPORT

##### Case 1

A 17 year old young man was diagnosed as having retinoschisis at 11 months of age. We have reported some of his clinical findings at the age of 10 years.<sup>2</sup> His maternal grandfather



**Figure 1** Genotype of four cases. (a, b) Pedigrees of cases 1, 2, and 4. Solid symbols indicate retinoschisis patients; open symbols, unaffected family members. Arrows indicate proband and Xs indicate examined cases. (a) III-1 and III-2 correspond to cases 1 and 2, respectively. (b) III-4 corresponds to case 4. Both pedigrees showed X linked inheritance pattern. (c-f) Nucleotide sequences of the *XLRS1* gene using sense primer in four patients with retinoschisis. Arrows indicate the position of the mutation. (c) Case 1, hemizygous mutant (*Glu72Lys*). (d) Case 2, hemizygous mutant (*Glu72Lys*). (e) Case 3, hemizygous mutant (*Glu72Lys*). (f) Case 4, hemizygous mutant (*Arg200Cys*).



**Figure 2** Posterior pole in the four cases. (a) Right eye of case 1. (b) Right eye of case 2. (c) Left eye of case 3. (d) Left eye of case 4. All cases showed foveal schisis. Cases 1, 3, and 4 showed retinal white flecks.

and his younger brother (case 2) are also known to have this condition (Fig 1a). Both fundi showed the typical star-shaped configuration in the macula and peripheral retinoschisis inferiorly with multiple small white flecks scattered in the temporal posterior pole (Fig 2a). Full field ERG recordings showed markedly reduced scotopic response and even greater reduction in the photopic responses and a negative-type ERG with a single bright flash stimulus. Corrected visual acuity at the age of 17 years was right eye 20/200 with S+4=C-2×160°, and left eye 20/100 with S+4=C-2.5×20°.

##### Case 2

A 14 year old boy, a brother of case 1, was found to have poor visual acuity at the age of 5 years. He was diagnosed by us as having retinoschisis at the age of 13 years. Both fundi showed the typical star-shaped configuration in the macula and peripheral retinoschisis inferiorly without the multiple small white flecks (Fig 2b). The full field ERG showed a similar pattern as in case 1. During the 6 year follow up, the white flecks did not appear. Corrected visual acuity at the age of 14 years was: right eye 10/20 with S+3=C-1.5×110°, and left eye 20/100 with S+4=C-1×160°.

##### Case 3

A 9 year old boy was found to have poor visual acuity, and was referred to us. He was diagnosed as having retinoschisis at the age of 5 years. Both fundi showed the typical star-shaped configuration in the macula. Multiple small, white flecks were scattered in the posterior pole of the left eye (Fig 2c). The white flecks were not present in the right eye. The full field ERG showed a similar pattern as in case 1. Visual fields showed a large scotoma in the left eye. Corrected visual acuity at the age of 9 years was: right eye 10/20 with S+2.25=C-1×75°, and left eye 10/1000.

##### Case 4

A 22 year old man was found to have hypermetropia and was corrected by glasses at the age of 1 year. He was diagnosed as having retinoschisis and esotropia and consulted us at the age of 13 years. Pedigrees of case 4 showed an X linked inheritance pattern (Fig 1b). Although the left fundus showed the typical star-shaped configuration in the macula, the right macula showed degenerative changes. Multiple small, white flecks were scattered in his left temporal posterior pole (Fig 2d). The full field ERG showed a similar pattern to case 1. Corrected visual acuity at the age of 22 years was: right eye 30/500 with S+7, and left eye 40/200 with S+5.25=C-1.75×90°.

Informed consent was obtained from the patients after an explanation of the study. Genomic DNAs were extracted from leucocytes of peripheral blood. Exons 1-6 of the *XLRS1* gene and exons 2-5 of the *RDH5* gene were amplified by polymerase chain reaction (PCR) using primers and condition described before.<sup>3,4</sup> The PCR products were purified and directly sequenced using an automated DNA sequencer, Model 373 (Applied Biosystems, USA). The hemizygous *XLRS1* gene mutations were recognised in all four patients as shown in Figure 1. No mutation of the *RDH5* gene was detected in exons 2-5 as well as flanking intron sequences.

#### COMMENT

Retinal flecks are sometimes observed in different types of retinal dystrophies.<sup>5,6</sup> We have already reported that the retinal white flecks rarely accompany retinoschisis.<sup>2</sup> Recently, a report indicated that mutations of the *RDH5* gene, which is highly expressed in the retinal pigment epithelium, causes fundus albipunctatus.<sup>4</sup> To assess them at the genetic level, we investigate both the *XLRS1* and *RDH5* genes in four cases of retinoschisis including three patients with retinal white flecks. Although we could not detect any

mutations of the *RDH5* gene, two kinds of *XLRS1* gene mutations, including the most common mutation, were found. The mutations are presumed to be responsible for the disease because no base substitution within the codons of *XLRS1* gene was detected in over 100 alleles from normal individuals. In addition, a number of cases of retinoschisis caused by a Glu72Lys mutation and several cases of retinoschisis caused by a Arg200Cys mutation have been reported.<sup>3,7,8</sup>

The clinical features, besides the white flecks of the three patients, were very common. All three cases showed hypermetropia, poor corrected visual acuity, foveal schisis, and negative ERG configuration. We believe that the retinal white flecks in retinoschisis may be a phenotypic variation because of the intra-familial variation, unilaterality, and detection of the common *XLRS1* gene defect. We were able to follow case 1 for 17 years and no remarkable change in numbers, shape, and size of the white flecks was observed. Because the punctate lesions in his right eye were found in part of the inner layer, the flecks are probably located in the neuroretina.

This study was supported in part by grants for the research committee on chorioretinal degenerations from the Ministry of Health and Welfare of Japan, and grant in aid for scientific research (Dr Miyake, B11470363, Dr Hotta, C05807166) from Ministry of Education, Science, Sports and Culture, Japan.

YOSHIHIRO HOTTA  
 MAKOTO NAKAMURA  
 YOKO OKAMOTO  
 RYOJI NOMURA  
 HIROKO TERASAKI  
 YOZO MIYAKE

Department of Ophthalmology, Nagoya University  
 School of Medicine, Nagoya, Japan

Correspondence to: Yoshihiro Hotta, Department of Ophthalmology, Hamamatsu University School of Medicine, 3600 Handa-cho, Hamamatsu, 431-3192, Japan

hotta@hama-med.ac.jp

Accepted for publication 16 June 2000

- 1 Haas J. Über das Zusammenkommen von Veranderungen der Retina und Choroidea. *Arch Augenheilkd* 1898;37:343-8.
- 2 Van Schooneveld MJ, Miyake Y. Fundus albipunctatus-like lesions in juvenile retinoschisis. *Br J Ophthalmol* 1994;78:659-61.
- 3 Sauer CG, Gehrig A, Warnecke-Wittstock R, et al. Positional cloning of the gene associated with X-linked juvenile retinoschisis. *Nat Genet* 1997;17:164-70.
- 4 Yamamoto H, Simon A, Eriksson U, et al. Mutations in the gene encoding 11-cis retinol dehydrogenase cause delayed dark adaptation and fundus albipunctatus. *Nat Genet* 1999;22:188-91.
- 5 Krill AE, Folk MR. Retinitis punctata albescens, a functional evaluation of an unusual case. *Am J Ophthalmol* 1962;53:450-5.
- 6 Krill AE, Klien BA. Flecked retina syndrome. *Arch Ophthalmol* 1965;74:496-508.
- 7 The Retinoschisis Consortium. Functional implications of the spectrum of mutations found in 243 cases with X-linked juvenile retinoschisis (XLRS). *Hum Mol Genet* 1998;7:1185-92.
- 8 Hotta Y, Fujiki K, Hayakawa M, et al. Japanese juvenile retinoschisis is caused by mutations of the *XLRS1* gene. *Hum Genet* 1998;103:142-4.

### An Australian family with macular dystrophy linked to autosomal recessive alopecia universalis

EDITOR.—A strong linkage between autosomal recessive alopecia universalis and macular dystrophy has not been described before. Recently, the gene for this form of alopecia, the human hairless gene, has been identified at chromosome 8p12-22. There are currently no retinal or macular associated genes which have been described at this locus.

### CASE REPORT

A 28 year old landscape gardener presented to the Lions Eye Institute, Perth, with visual problems and a request for assessment. On examination, it was noted that she had marked bilateral, symmetrical, atrophic maculae (Fig 1). In addition, she had marked hair thinning and loss involving the entire head. Her best corrected visual acuity was recorded as 6/36 in both eyes, with the right eye improving to 6/12 with pinhole. She wore a spectacle correction of -4.00 sphere right and -3.50 sphere left.

Her past history noted hair loss but not symptomatic visual loss as a child. She was seen recently at the Royal Children's Hospital, Melbourne, for alopecia and fitting of wigs but not for vision loss. She complained of changing vision affecting reading and other activities in her teens. The visual loss had progressed through her teens and had become a significant disability to function. She did not complain of night blindness.

The patient also described her brother in Melbourne and a cousin in Berlin both of whom had the combination of vision loss and alopecia. The relationship between affected individuals is shown in Figure 2. None of the clinical features described in the affected children were present in the parents or the grandparents. Although neither of the parents of the affected children, nor the grandparents, were consanguineous, they all came from the same small town, Kostajnica, in a hilly region of Croatia. The presence of a likely small gene pool in the region where all the members of the pedigree were from would be consistent with a recessive disease.

Electrophysiological tests were carried out with a normal EOG and normal peak to trough ratios. The scotopic and photopic flash ERG results were reported as unreliable but the tests were not repeated. The pattern ERG was abnormal in the right eye and grossly abnormal in the left with no identifiable components. Flicker ERG responses were at the

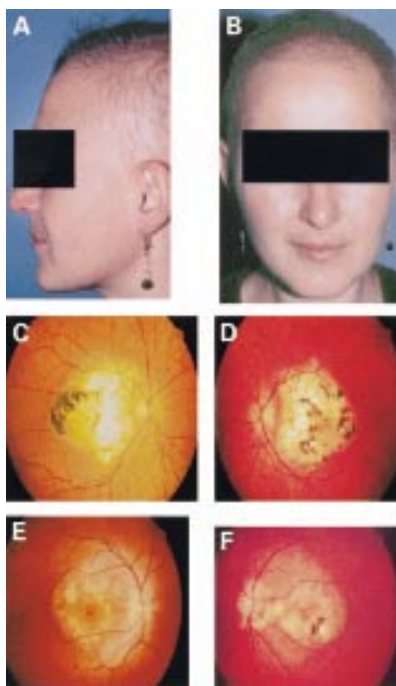


Figure 1 Clinical photograph (A) and (B) showing the patient's alopecia. Fundus photographs (C) and (D) of the patient, and (E) and (F) of the patient's brother.

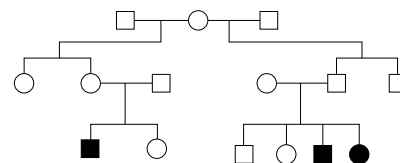


Figure 2 Pedigree. The family of the affected individual (P1) with the other affected individuals in black.

extreme lower limit of normal in the right and abnormal in the left eye with reduced b-waves.

Other tests showed a total error score on the Farnsworth 100 hue test of 136 right, and 176 left. Goldmann visual fields showed a right central scotoma of about 10 degrees to the stimulus but sparing the superonasal quadrant to the fixation point. The margin of the spared area did not respect the vertical or horizontal meridians. A central scotoma of 10 degrees to the stimulus was seen in the left with no areas spared.

### COMMENT

The identification of new, macular related, and disease related genes is sometimes helped by strong linkage to a second disease or marker trait. The strong association of alopecia and macular degeneration does not appear in the literature. Recent identification of alopecia associated genes has allowed tentative allocation of clinical disease entities to these genes.<sup>1</sup> The patient described here has the clinical diagnosis of autosomal recessive alopecia universalis. This condition has recently been identified to be associated with mutations in the human hairless gene on chromosome 8p12-22 in some families.<sup>1</sup> Expression of this gene has been shown to occur in the brain and because of the origin and nature of the retina would make this a plausible candidate.<sup>2</sup> There are currently no reported macular diseases associated genes that are present at this locus. Two chromosome-8 related retinal genes have been identified. These are a gene encoding a new oxygen regulated photoreceptor protein causing autosomal dominant retinitis pigmentosa,<sup>3</sup> linked to 8q11-13 and a "macular hypoplasia with ERG suggestion of gross abnormality of cone function" in a case of trisomy 8 mosaic syndrome.<sup>4</sup>

The primary aim of this case study is to report a family that has a strong linkage of congenital alopecia and macular degeneration. Given the recent identification of the gene responsible for autosomal recessive alopecia universalis this may suggest the site of a, currently unknown, gene associated with retinal dystrophy.

LYNDON DA CRUZ  
 I L McALLISTER

Lions Eye Institute, 2 Verdun Street,  
 Nedlands, 6009, Western Australia

Correspondence to: Dr Lyndon da Cruz, c/o Professor Bird's secretary, Medical Retina Unit, Moorfields Eye Hospital, City Road, London EC1 2PV, UK  
 Accepted for publication 16 June 2000

- 1 Cichon S, Anker M, Vogt IR, et al. Cloning, genomic organization, alternative transcripts and mutational analysis of the gene responsible for autosomal recessive universal congenital alopecia. *Hum Mol Genet* 1998;7:1671-9.
- 2 Ahmad W, Faiyaz ul Haque M, Brancolini V, et al. Alopecia universalis associated with a mutation in the human hairless gene. *Science* 279:720-4.
- 3 Pierce EA, Quinn T, Meehan T, et al. Mutations in a gene coding a new oxygen-regulated photoreceptor protein cause dominant retinitis pigmentosa. *Nat Genet* 1999;22:248-54.
- 4 Anwar S, Bradshaw K, Vivian AJ. Ophthalmic manifestations of trisomy 8 mosaic syndrome. *Ophthalmic Genet* 1998;19:81-6.



### Cystic epithelial growth after penetrating keratoplasty: successful curative treatment by block excision

EDITOR,—Most of the reported cases of epithelial growth in the anterior chamber are related to cataract surgery and injuries.<sup>1-3</sup> Epithelial invasion of the anterior chamber after perforating keratoplasty (PK) is a rare complication. Only a few authors report on epithelial cysts after PK,<sup>4,5</sup> while the majority of the presented patients in the literature suffer from diffuse epithelial downgrowth.<sup>1,6,7</sup> We present three patients with cystic epithelial growth in the anterior chamber 1–10 years after primary PK and histopathological findings after complete removal of the cyst.

#### CASE REPORTS

All three patients were referred to our department with cystic epithelial growth into the anterior chamber. Primary PK was carried out elsewhere. Block excision and corneoscleral grafting were performed by one of us (GOHN) in all three patients. Technical aspects of block excision have been described in detail earlier.<sup>2,8-10</sup>

#### Patient 1

Patient 1 is a 31 year old man. He underwent PK on his right eye because of a keratoconus. Thirteen months later cystic epithelial growth in the anterior chamber was noted with increase in size. At the time of operation the cyst size was below two clock hours on the limbal circumference. Block excision (6.0/6.1 mm) was performed in toto. Histological specimen showed a epithelial cyst formed by non-keratinising epithelium with goblet cells. During the follow up period of 48 months no recurrence of epithelial growth was observed. Preoperative visual acuity at the time of block excision was 20/20, visual acuity at the last check was 14/20; preoperatively intraocular pressure (IOP) was unremarkable, and IOP at the last check was 15 mm Hg.

#### Patient 2

A 29 year old woman underwent PK on her right eye because of lattice corneal dystrophy. After 47 months a epithelial cyst was seen for the first time. Block excision (6.0/6.1 mm) of

the cyst, which had increased in size (below three clock hours of the limbal circumference), was performed. The histological finding was a cystic epithelial growth by non-keratinising epithelium. Goblet cells were not observed in the specimen (Fig 1). Visual acuity at the time of surgery was 8/20; the last examination during the follow up period (13 months) revealed a visual acuity of 10/20, IOP was 19 mm Hg both preoperatively and postoperatively.

#### Patient 3

This was a 29 year old woman. She had undergone PK on the left eye 10 years earlier after herpes simplex keratitis. Cystic epithelial growth was noted 10 years after PK. Epithelial cyst (below three clock hours of the limbal circumference) was removed by block excision (7.5/7.6 mm) in toto. Histological examination revealed cystic epithelial growth by non-keratinising epithelium with goblet cells. Cystic epithelial ingrowth was removed in toto. Visual acuity at the time of surgery was 4/20, IOP was within normal limits. The last follow up (follow up time 7 months) revealed a visual acuity of 6/20, IOP was within normal range (18 mm Hg).

#### COMMENT

In all three patients the cyst was adjacent to the corneal surface, the iris, and the chamber angle structures.

Several other surgical methods have been described for treatment of epithelial ingrowth. Proposed methods are aspiration of the cyst, diathermy, cryocoagulation, YAG laser treatment of the cyst wall, or excision of the cyst itself. In our experience, surgical opening of the cyst tends to result in diffuse epithelial ingrowth and, consequently, the potential loss of the eye.<sup>1,2</sup> Excision of the cyst itself on the other hand is not possible, because in all histological specimens obtained by block excision (up to 60 patients) the epithelial cyst covered the corneal surface, the chamber angle structure, the anterior surface of the ciliary body, and the iris surface.

The pathway for the epithelial ingrowth is uncertain; possible pathways are sutures, forceps and other surgical instruments, prolonged postoperative hypotony, and retardation of wound healing and wound dehiscence.

The interval between primary surgery and clinical appearance of epithelial ingrowth may vary from 1 week to 38 years.<sup>1,4,6</sup> In our patients the symptom-free interval was 1–10 years. In cystic epithelial ingrowth increase in the cysts size seems to be limited by the corneal endothelial cell layer on the surface of the cyst ("Zagorski effect").<sup>3</sup>

The purpose of every treatment of cystic epithelial growth should be the complete eradication of the invaded epithelium. Surgical opening of the cyst (for example, by laser application) is contraindicated, because this intervention may transform cystic epithelial ingrowth into a diffuse epithelial ingrowth, resulting in severe secondary glaucoma and eventually the loss of the eye. Reported rate of local recurrences (up to 14–100%) and following enucleations (up to 18–33%) in reported series are relatively high.<sup>2</sup>

In conclusion, cystic epithelial ingrowth after PK without previous ocular surgery or trauma is very rare. In our experience block excision and corneoscleral grafting<sup>2,8-10</sup> are the treatment of choice if the cyst is not above five clock hours of the limbal circumference. This procedure leads to morphological and functional rehabilitation of the eye.

MICHAEL J M GROH

GOTTFRIED O H NAUMANN

Department of Ophthalmology, University  
Erlangen-Nuernberg, Schwabachanlage 6, 91054  
Erlangen, Germany

Correspondence to: Dr Groh  
michael.groh@augen.med.uni-erlangen.de  
Accepted for publication 18 June 2000

- Küchle M, Green WR. Epithelial downgrowth: a study of 207 histopathologically proven cases. *Ger J Ophthalmol* 1996;5:211–23.
- Rummelt V, Naumann GOH. Blockexzision mit tektonischer Korneoskleralplastik wegen zystischer und/oder diffuser Epithelinvasion des vorderen Augenabschnitts. *Klin Monatsbl Augenheilkd* 1997;211:312–23.
- Zagorski Z, Shrestha HG, Lang GK, et al. Sekundärglaukome durch intraokulare Epithelinvasion. *Klin Monatsbl Augenheilkd* 1988;193:16–20.
- Bennett T, D'Amico RA. Epithelial inclusion cyst of iris after keratoplasty. *Am J Ophthalmol* 1974;77:87–9.
- Clauoue C, Lewkowicz-Moss S, Easty D. Epithelial cyst in the anterior chamber after penetrating keratoplasty: a rare complication. *Br J Ophthalmol* 1988;72:36–40.
- Leibowitz HM, Elliott JH, Boruchoff SA. Epithelialization of the anterior chamber following penetrating keratoplasty. *Arch Ophthalmol* 1967;78:613–7.
- Sugar A, Meyer RF, Hood I. Epithelial downgrowth following penetrating keratoplasty in the aphake. *Arch Ophthalmol* 1977;95:464–7.
- Naumann GOH, Rummelt V. Block excision of cystic and diffuse epithelial ingrowth of the anterior chamber. Report on 32 consecutive patients. *Arch Ophthalmol* 1992;110:223–7.
- Naumann GOH, Völcker HE. Blockexzision intraokularer Prozesse. II. Epithelwachstum in das vordere Augensegment. *Klin Monatsbl Augenheilkd* 1975;166:448–57.
- Naumann GOH. Blockexzision intraokularer Prozesse. I. Tumoren der vorderen Uvea. *Klin Monatsbl Augenheilkd* 1975;166:436–48.

### Ocular scleromalacia caused by leishmaniasis: a rare cause of scleral perforation

EDITOR,—The clinical manifestations of leishmaniasis depend on complex interactions between the virulence, characteristics of the infecting *Leishmania* species, and the immune response of its host.<sup>1-3</sup> Leishmaniasis sometimes involves the eye as a result of contagious spread from the eyelid and conjunctiva, by the haematogenous route, or by inoculation of the conjunctiva by the patient's own fingers, usually caused by *L. donovani*.<sup>4,7</sup>

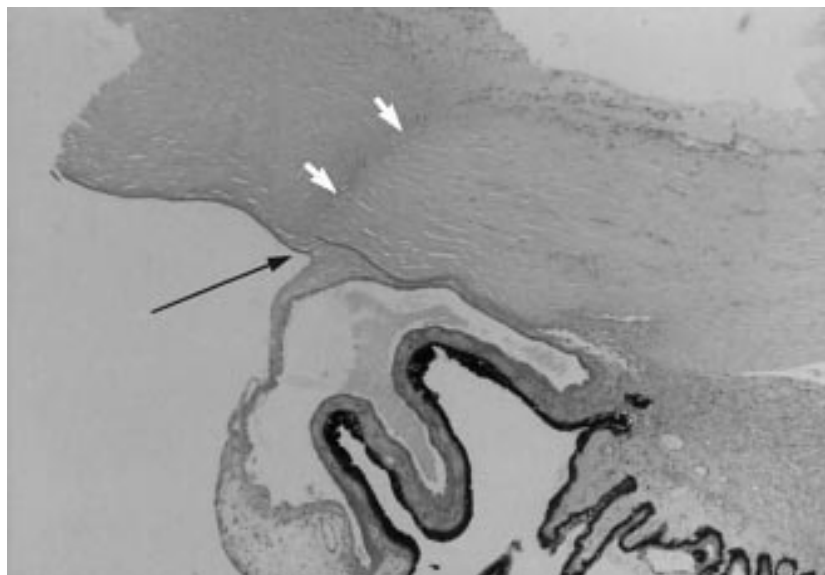
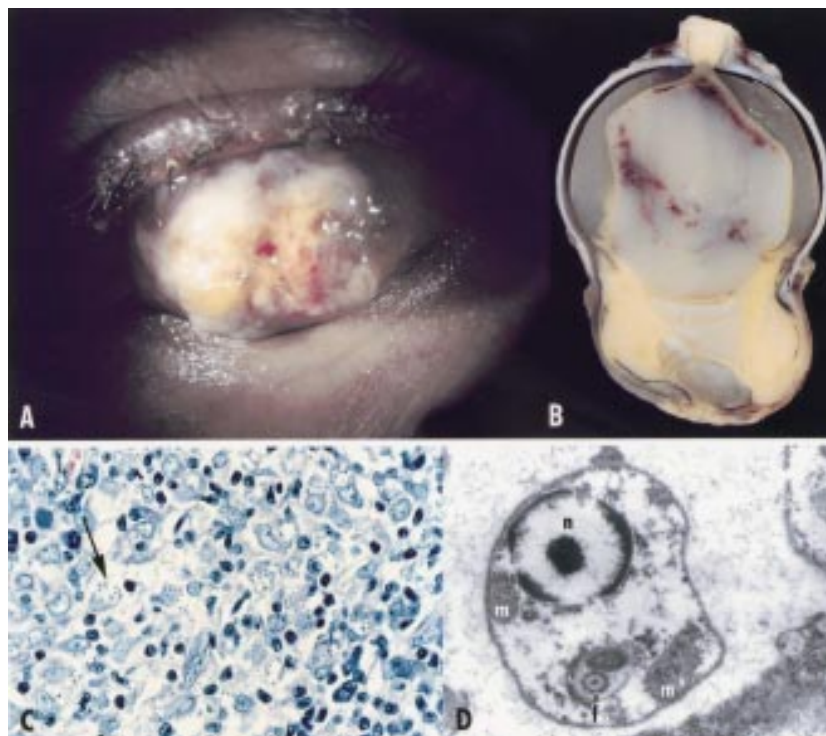


Figure 1 Histological specimen of the cyst (patient 2); periodic acid Schiff staining. Descemet's membrane defect (black arrow); cystic epithelial invasion (white arrows) by non-keratinising epithelium without goblet cells.



**Figure 1** (A) Clinical examination of the right eye. Severe scleromalacia with focal perforation. (B) Macroscopic examination. Perforated sclera, lens, parts of the iris, and vitreous body luxated into the bulge. (C) Light microscopic examination. *Leishmaniae* (arrow) within histiocytes by Giemsa staining. (D) Transmission electron microscopic examination. The protozoan consists of a nucleus (n), prominent mitochondria (m), and the flagellum (f).

We report a case of an Afghan boy suffering from general mucocutaneous leishmaniasis caused by *L. tropica* and a bilateral intraocular manifestation of this disease.

#### CASE REPORT

An 11 year old Afghan boy with known general mucocutaneous leishmaniasis caused by *L. tropica* stayed in the "Friedensdorf International", Oberhausen, Germany, for treatment of his disease. After he had undergone a systemic eradication therapy in the summer of 1995 (Institute of Tropical Medicine, University of Tuebingen, J Knobloch and the Paul Lechler Hospital for Tropical Diseases, Tuebingen, Germany), the boy was first seen in the Department of Ophthalmology, Mülheim/Ruhr, Germany, in January 1996 with binocular uveitis and secondary cataract. The right eye showed only slight inflammation, but the left eye severe inflammation of the anterior chamber. The cataract was more advanced in the right eye, visual acuity reduced to light perception in the right eye, to 0.2 in the left. Local anti-inflammatory therapy was started and cataract surgery was intended. The patient was seen again in spring 1996. Both eyes were painful, visual acuity in the left eye had also decreased to light perception, inflammation had severely increased with granulomata and vascularisation on the iris and narrowing of the anterior chamber in both eyes. After eradication therapy reinfection was thought to be very unlikely at this time but the patient deteriorated rapidly. Severe scleromalacia appeared in both eyes near the superior limbus followed by scleral perforation of the right eye. Severe pain, loss of vision, the extent of perforation, and inflammation made the enucleation of the right eye inevitable (Fig 1A).

Macroscopic examination showed the perforated sclera, with prolapse of the lens, parts

of the iris, and the vitreous body (Fig 1B). The histopathological examination showed many histiocytes filled with encapsulated leishmania 2–4  $\mu\text{m}$ ol in length (Fig 1C). The diagnosis was confirmed by transmission electron microscopy showing frequent amastigote organisms within the cytoplasm of histiocytes, with a nucleus, a kinetoplast, and an intracellular flagellum (Fig 1D). After histological examination intensive anti-infectious therapy was started again. Despite all efforts, scleral perforation also occurred in almost the entire inferior part of the sclera near the limbus of the left eye, so enucleation of the left bulbus had to be performed. Intraoperatively, both orbits were without pathological findings and the postoperative recovery was without complications.

#### COMMENT

The estimated worldwide overall prevalence of leishmaniasis is 12 million with the population at risk approaching 350 million.<sup>1</sup> Visceral leishmaniasis is typically caused by *L. donovani*.<sup>3</sup> Leishmaniasis of the eye is very rare and the few reported cases were either due to *L. donovani*<sup>4,5</sup> or the *Leishmania* subtype was not characterised.<sup>6,7</sup> *Leishmania tropica* was thought to cause cutaneous infection exclusively,<sup>1</sup> but in a small group of American military personnel who served in Operation Desert Storm, *L. tropica* was isolated from bone marrow specimens taken after the soldiers had developed chronic low fever, fatigue, and in some instances diarrhoea.<sup>8</sup> This kind of leishmaniasis was named "viscerotropic leishmaniasis" (VTL) because the clinical symptoms differed in some points from the typical visceral leishmaniasis. In this boy's case the channel of transmission could not be determined. However, as no pathological findings of the eyelids could be observed the very rare haematogenous route seems to

be the most likely mode of infection, possibly caused by the previously diagnosed *L. tropica* being the cause of the generalised mucocutaneous leishmaniasis. Identifying the species of *Leishmania* is especially important for the evaluation of treatment and their different sensitivities to anti-infectious drugs.<sup>1</sup>

P REINECKE  
H E GABBERT  
Department of Pathology, University Hospital,  
D-40225 Düsseldorf, Germany

W STRUNK  
C C LÖSCHE  
Department of Ophthalmology, Evangelisches Hospital  
D-45466 Mülheim/Ruhr, Germany

Correspondence to: Petra Reinecke, MD, Institute of Pathology, Heinrich-Heine-University, Moorenstrasse 5, D-40225 Düsseldorf, Germany  
Accepted for publication 28 June 2000

- 1 The Expert Committee: Control of the leishmaniasis. Report of a WHO Expert Committee. *WHO Tech Rep Ser* 1990;793:1–158.
- 2 Rodriguez N, Guzman B, Rodas A, et al. Diagnosis of cutaneous leishmaniasis and species discrimination of parasites by PCR and hybridization. *J Clin Microbiol* 1994;32:2246–52.
- 3 Pearson RD, de Queiroz Sousa A. Clinical spectrum of leishmaniasis. *Clin Infect Dis* 1996;22:1–13.
- 4 O'Neill DP, Deutsch J, Carmichael AJ, et al. Eye-lid leishmaniasis in a patient with neurogenic ptosis. *Br J Ophthalmol* 1991;75:506–7.
- 5 Nandy A, Addy M, Chowdhury AB. Leishmanial blepharo-conjunctivitis. *Trop Geogr Med* 1991;43:303–6.
- 6 El-Hassan AM, El-Sheikh EA, Eltoum IA, et al. Post-kala-azar anterior uveitis: demonstration of *Leishmania* parasites in the lesion. *Trans Roy Soc Trop Med Hyg* 1991;85:471–3.
- 7 Ferrari TC de Abreu, Guedes ACM, et al. Isolation of *Leishmania* sp from aqueous humor of a patient with cutaneous disseminated leishmaniasis and bilateral iridocyclitis (preliminary report). *Rev Inst Med trop Sao Paulo* 1990;32:296–8.
- 8 Magill AJ, Grogil M, Gasser RA, et al. Visceral infection caused by *Leishmania tropica* in veterans of Operation Desert Storm. *N Engl J Med* 1993;328:1383–7.

#### Clinical manifestations of protein C deficiency: a spectrum within one family

EDITOR,—Homozygous protein C deficiency is rare with an estimated incidence of one in 500 000 to one in 750 000.<sup>1</sup> It presents shortly after birth with life threatening thromboses involving the central nervous system, eyes, kidneys, and skin (purpura fulminans).<sup>2</sup> Protein C activity, in affected individuals, is usually less than 1% (normal 70–140%).<sup>3</sup> Management, in the acute phase, is with intravenous protein C concentrate (ImmunoAG, Vienna, Austria).<sup>4</sup> Untreated cases usually result in death.

We present a family exhibiting a spectrum of features caused by protein C deficiency.

#### FAMILY REPORT

The pedigree is shown in Figure 1. Individuals IV:1 and IV:2 (the parents in our family) are second cousins and both heterozygous for protein C deficiency. Protein C activity is approximately 50% in both and they are healthy. The mother (IV:1) had five miscarriages and one neonatal death; the baby had undetectable protein C levels and died at the age of 4 weeks from severe purpura fulminans and cerebral involvement. Two of her children (V:3 and V:7) were healthy with normal protein C levels. One sibling (V:5) has been described previously.<sup>5</sup> Briefly, she presented 6 days after birth with purpura fulminans on her left calf, bilateral central retinal vein occlusions, vitreous haemorrhages, and a right central retinal artery occlusion. Despite treatment



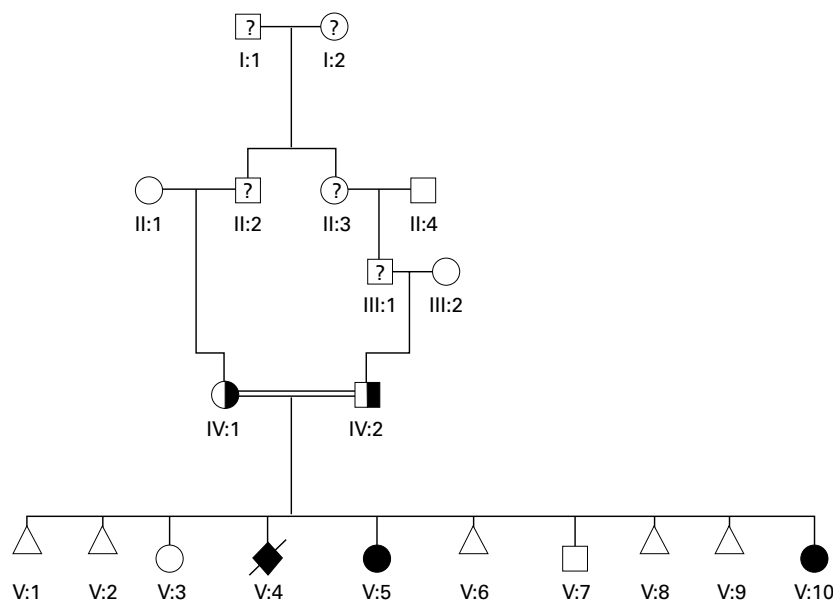


Figure 1 Pedigree of family with protein C deficiency. Key: square = male, circle = female, triangle = miscarriage, diamond = neonatal death, solid symbols = homozygous affected, half filled symbol = heterozygous affected, ? = status unknown.

with intravenous protein C concentrate she developed bilateral retinal detachments. Now, aged 7, she is bilaterally blind, has a scar corresponding to the area of purpura fulminans, but has otherwise developed normally. She receives subcutaneous protein C injections every fourth day.

The youngest child (V:10) was prenatally diagnosed as homozygous protein C deficient. She was born by emergency caesarean section at 36 weeks' gestation because of reduced fetal movements. At birth ultrasonography diagnosed an intraventricular and right intracerebral haemorrhage. Ocular examination demonstrated right leucocoria with an underlying total retinal detachment and a left macular haemorrhage. Intravenous protein C therapy (80 IU/kg) was initiated at birth and titrated relative to serum levels. Despite early intervention she developed hydrocephalus requiring a V-P shunt at 3 weeks of age. Fortunately, the left macular haemorrhage resolved leaving a relatively healthy posterior pole (Fig 2). At 3 months of age she is progressing well and showing signs of visual attention.

#### COMMENT

The clinical signs of homozygous protein C deficiency manifest from 2 hours to 2 weeks after birth.<sup>2</sup> Ocular features associated with this condition include vitreous, retinal and subretinal haemorrhage, retinal venous and arterial occlusion, microphthalmos, and leucocoria secondary to retinal detachment or

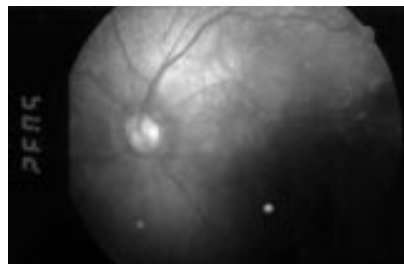


Figure 2 Photograph of the left eye of homozygous protein C deficient individual V:10 to illustrate resorption of the dense macular haemorrhage

persistent hyperplastic primary vitreous.<sup>2</sup> One or both eyes may be affected. Drefus *et al* reported blindness in 6/9 affected children.<sup>6</sup> It is possible that early treatment might result in a better visual prognosis.

This family demonstrates a spectrum of clinical manifestations ranging from no symptoms in the heterozygous state to spontaneous abortion and neonatal death in the homozygous state. Individual V:10 was delivered by emergency caesarean section and a suspected intrauterine cerebral event was confirmed. This challenges the hypothesis by Hattenbach *et al* that thrombotic events only occur postnatally.<sup>2</sup> In utero treatment is not currently possible because maternal supplements do not cross the placenta and the biological half life of protein C is short (<8 hours) so that direct fetal replacement is not practical.

In this family, the disease allele appears to be preferentially transmitted making accurate genetic counselling more difficult. Prenatal diagnosis is currently available and we would suggest that affected individuals are monitored closely in the final trimester of pregnancy. We have shown that in utero thrombotic events can occur around 36 weeks' gestation. This raises the question as to whether elective caesarean section should be considered at 34–36 weeks for homozygously affected individuals so that replacement protein C therapy can be given and avoid the complications associated with the deficiency.

AMANDA J CHURCHILL  
MICHAEL J GALLAGHER  
JOHN A BRADBURY

Department of Ophthalmology, Bradford Royal Infirmary, Bradford, West Yorkshire

ADRIAN MA MINFORD  
Department of Paediatrics, St Luke's Hospital, Bradford, West Yorkshire

Correspondence to: Dr Michael Gallagher, Department of Ophthalmology, Bradford, Royal Infirmary, Duckworth Lane, Bradford, BD9 6RJ  
mjgallagher@doctors.org.uk

Accepted for publication 3 July 2000

1 Manlar RA, Mastovich S. Hereditary protein C deficiency: a review of the genetics, clinical presentation, diagnosis and treatment. *Blood Coagul Fibrinolysis* 1990;1:319–30.

- Hattenbach L-O, Beeg T, Kreuz W, *et al*. Ophthalmic manifestations of congenital protein C deficiency. *J AAPOS* 1999;3:188–90.
- Manlar R, Montgomery R, Broekmans A and the Working Party. Diagnosis and treatment of homozygous protein C deficiency. *J Pediatr* 1989;114:528–34.
- Minford AMB, Parapia LA, Stainforth C, *et al*. Treatment of homozygous protein C deficiency with subcutaneous protein C concentrate. *Br J Haematol* 1996;93:215–16.
- Cassels-Brown A, Minford AMB, Chatfield SL, *et al*. Ophthalmic manifestations of neonatal protein C deficiency. *Br J Ophthalmol* 1994;78:486–7.
- Drefus M, Masterton M, David M, *et al*. Replacement therapy with a monoclonal antibody-purified protein C concentrate in newborns with severe congenital protein C deficiency. *Semin Thromb Hemost* 1995;21:371–81.

#### Spontaneous consecutive exotropia in children with motor fusion

EDITOR,—The development of spontaneous consecutive exotropia is not uncommon in patients with esotropia.<sup>1</sup> They characteristically have an early onset partially accommodative esotropia associated with poor binocular function including weak motor fusion, which is thought to prevent stable eye alignment. We report the findings in five patients with partially accommodative esotropia who developed spontaneous consecutive exotropia despite having adequate motor fusion.

#### CASE REPORTS

We reviewed the case records of five children with partially accommodative esotropia who attended the orthoptic clinic within the department of ophthalmology and were noted to have developed spontaneous consecutive exotropia despite having motor fusion. Each child had undergone cycloplegic refractions, with full hypermetropic correction prescribed. A full orthoptic and ophthalmic examination had also been performed. None had any significant medical history of note.

The findings are summarised in Table 1. The mean age of presentation of the esotropia was 2½ years (range 1½–3¾), with the mean size of the esodeviation being 33 prism dioptres for near (range 15–50) without spectacle correction. Accurate data were not consistently available for the distance deviation at this time owing to the young age of the children. The mean refractive error (spherical equivalent) was +6.6 dioptres for the right eye (range +4.00 to +8.75) and +6.8 dioptres for the left eye (range +4.75 to +10.75). Patients 1 and 2 had anisometropia of 2.50 DS and 2 DS respectively. The remaining patients had no significant anisometropia. At initial presentation all the children had a degree of amblyopia, which improved with appropriate occlusion therapy and spectacle wear. At subsequent visits abnormal binocular single vision was established with the Bagolini lorgnette, although none demonstrated stereopsis, with no response being elicited for either the Frisby or Titmus (housefly) stereotests. The presence of motor fusion was confirmed by the ability to overcome a 20 dioptre base out prism. This is a routinely used test for preschool visual screening,<sup>2–4</sup> with the failure to overcome the prism being interpreted as evidence of poor or absent motor fusion. At the clinic visit immediately before the onset of the exodeviation all had visual acuities of 6/12 or better, with the mean size of the esodeviation with spectacle correction being 6 prism dioptres for near (range 0–16) and 5 prism dioptres for distance (range 0–16). The mean size of the subsequent exodeviation with spectacle correction was 8 prism dioptres for near (range 2–16)

Table 1 Data from five patients who spontaneously developed consecutive exotropia

Patient	1	2	3	4	5
<i>At presentation:</i>					
Age (years)	1 1/2	3 3/4	1 3/4	2 1/2	3
Acuity					
Right	<6/60	6/12	6/18	6/12	6/18
Left	6/12	2/60	<6/60	6/60	2/60
Deviation (prism dioptres)					
Near	30 ET	15 ET	35 ET	35 ET	50 ET
Distance	NA	20 ET	NA	NA	NA
Refraction: spherical equivalent (dioptres)					
Right	8.25	8.75	4.75	4	7
Left	5.75	10.75	5.5	4.75	7.5
Stereoacuity	Negative	Negative	Negative	Negative	Negative
Motor fusion: able to overcome 20 dioptre base out prism	Yes	Yes	Yes	Yes	Yes
<i>Prior to exodeviation:</i>					
Acuity					
Right	6/12	6/6	6/12	6/6	6/9
Left	6/6	6/9	6/12	6/6	6/12
Refraction: spherical equivalent (dioptres)					
Right	7	8.75	5.75	4.5	8.5
Left	6	9.5	6	5.25	9
Deviation with glasses (prism dioptres)					
Near	16 ET	4 ET	0	4 ET	6 ET
Distance	16 ET	6 ET	0	0	4 ET
<i>Onset of exotropia:</i>					
Age (years)	4	5 1/4	3	4	6
Acuity					
Right	6/12	6/6	6/12	6/6	6/5
Left	6/6	6/9	6/12	6/6	6/9
Refraction: spherical equivalent (dioptres)					
Right	7	8.75	5.75	4.5	8.5
Left	6.25	9.5	6	5.25	9
Deviation with glasses (prism dioptres)					
Near	8 EX	2 EX	16 EX	10 EX	2 EX
Distance	4 EX	18 EX	18 EX	14 EX	20 EX
<i>Treatment:</i>					
Size of reduction in lens power (dioptres)	0.5	1	1	1.5	1.5
<i>Outcome:</i>					
	MicroEX	MicroET	MicroEX	MicroET	MicroEX

ET = esotropia; EX = exotropia; NA = no data available.

and 15 prism dioptres for distance (range 4–20). The mean interval between initial diagnosis and appearance of exotropia was 2 years (range 1½–3) with the mean age at onset of the exodeviation being 4½ years (range 3–6). Cycloplegic refraction was rechecked following the onset of the exotropia and found to be unchanged. Visual acuities were also unchanged.

The consecutive exotropia was managed in all patients by decreasing the strength of the hypermetropic prescription by a mean of 1.00 DS (range 0.50–1.50). This resulted in three children developing a microexotropia and two children developing a microesotropia during the follow up period (mean 14 months, range 3 months to 3 years).

#### COMMENT

This study demonstrates that spontaneous consecutive exotropia can develop in certain patients with accommodative esotropia despite the presence of motor fusion. Moore<sup>5</sup> reported four patients with evidence of peripheral fusional amplitudes who developed consecutive exotropia, although the actual extent of their fusional reserve was not recorded. It has been suggested that full correction of a significant hypermetropic refractive error in children with early onset esotropia predisposes to the development of spontaneous exotropia in some cases.<sup>6,7</sup> The degree of hypermetropia in our cases is similar to that of patients reported in earlier studies,<sup>5-7</sup> and it may well be that full correction of this amount of hypermetropia is the cause of the exodeviation. Just before the onset of the exodeviation all of our patients had acuities of 6/12 or better in the worse eye, with one subject seeing 6/6 with each eye. This is in keeping with the findings of Beneish *et al* and Moore,<sup>5</sup> who concluded that amblyopia was

not an important factor in the development of spontaneous consecutive exotropia. The time interval between initial diagnosis and development of exotropia in the present study is similar to that of Beneish *et al* although our patients were slightly younger (4½ as opposed to 5½). However, the children are much younger than those described by Moore<sup>5</sup> who reported an average age of onset of 9.

Why should the eyes of patients with motor fusion diverge? Although these patients had “risk factors” for developing consecutive exotropia and could be expected to show a reduction in the angle of esotropia with the passage of time, the presence of satisfactory motor fusion, as judged by the 20 dioptre base out prism test, should have prevented them diverging. Ciner and Herzberg<sup>8</sup> suggested that spontaneous consecutive exotropia is the result of poor accommodative function, while van Lammeren *et al*<sup>9</sup> proposed that it is related to anomalies of the vergence system. In addition Burian<sup>6</sup> found that a low AC:A ratio was a risk factor for the development of a consecutive exotropia but unfortunately this ratio was not formally recorded in our subjects.

Our patients were managed by reducing the strength of the hypermetropic prescription, which was effective in all cases. This might suggest that they were all overcorrected to begin with. However, repeated refraction by optometrists experienced in the assessment of paediatric patients confirmed that their initial refractions were accurate. Interestingly, previous reports document a variable response to reducing the hypermetropic prescription in the treatment of spontaneous consecutive exotropia. For example Swan<sup>10</sup> reported that it was of little benefit, with all six of his patients subsequently requiring surgery, while Beneish *et al* found that eight out of 22 patients improved significantly following a reduction in

their hypermetropic prescription. It is conceivable that such a response is only observed in patients with underlying motor fusion.

When motor fusion is present there may be a tendency not to think about the possibility of a consecutive exodeviation developing in children with esotropia but as this study illustrates this is not necessarily the case.

CLIFFORD R WEIR

Tennent Institute of Ophthalmology, Gartnavel General Hospital, Glasgow G12 0YN, UK

MARIE CLEARY

Department of Orthoptics

GORDON N DUTTON

Tennent Institute of Ophthalmology

Correspondence to: Dr Weir

Accepted for publication 2 August 2000

- 1 Van Noorden GK. *Binocular vision and ocular motility*. 5 ed. St Louis: Mosby, 1996.
- 2 Williamson TH, Andrews R, Dutton GN, *et al*. Assessment of an inner city visual screening programme for preschool children. *Br J Ophthalmol* 1995;79:1068–73.
- 3 Bowman RJ, Williamson TH, Andrews RG, *et al*. An inner city preschool visual screening programme: long-term visual results. *Br J Ophthalmol* 1998;82:543–8.
- 4 Newman DK, East MM. Preschool vision screening: negative predictive value for amblyopia. *Br J Ophthalmol* 1999;83:676–9.
- 5 Moore S. The natural course of esotropia. *Am Orthopt J* 1971;21:80–3.
- 6 Burian H. Hypermetropia and esotropia. *J Pediatr Ophthalmol* 1972;9:135–43.
- 7 Beneish R, Williams F, Polomeno RC, *et al*. Consecutive exotropia after correction of hyperopia. *Can J Ophthalmol* 1981;16:16–18.
- 8 Ciner EB, Herzberg C. Optometric management of optically induced consecutive exotropia. *J Am Optom Assoc* 1992;63:266–71.
- 9 Van Lammeren M, de Clippelair L, van Beckhoulte L, *et al*. Can spontaneous consecutive exotropia be explained by vergence anomalies? *Transactions of the 22nd Meeting of the European Strabismological Association* 1996:71–6.
- 10 Swan KC. Accommodative exotropia long range follow-up. *Ophthalmology* 1983;90:1141–5.

## Practice patterns of pneumatic retinopathy in the United Kingdom

EDITOR.—Pneumatic retinopathy (PR) has been the subject of one multicentre randomised controlled trial<sup>1,2</sup> and many uncontrolled studies with reported success rates with one procedure of 53–84%.<sup>3,4</sup> In a retrospective review of 31 cases published in 1999, we reported a primary reattachment rate of 61% with this procedure, with a relatively high incidence of secondary breaks and proliferative vitreoretinopathy.<sup>5</sup> Because of these variable success rates, PR is viewed as controversial by many surgeons. We conducted a postal survey to estimate the acceptance and prevalence of PR for the treatment of primary rhegmatogenous retinal detachment among vitreoretinal surgeons in the UK.

Questionnaires were posted in July 1999 to 80 members of the British and Eire Association of Vitreoretinal Surgeons (BEAVRS). We questioned the number of PR procedures they performed per month, their reasons for selecting it as a first procedure, and their estimated primary success rates. The data were collected anonymously.

### RESULTS

A total of 69 questionnaires were returned (86%). Thirty (43%) of the 69 vitreoretinal surgeons indicated that they never perform PR, 28 (41%) use it occasionally (less than once a month), and only 11 (16%) surgeons use it frequently (one to four times a month).

*Surgeons who don't perform pneumatic retinopathy*  
A third of the surgeons who don't perform PR said that they had tried it in the past and abandoned it. Ninety per cent of these surgeons believe that pneumatic retinopathy has a lower reattachment rate than other techniques and a third associate it with a high rate of complications.

*Surgeons who perform pneumatic retinopathy occasionally*

The mean success rate of the 41% surgeons who perform PR occasionally is estimated at 73% (SD 20.2). Their main indications for using this procedure are patient unfit for more invasive surgery (70%), simplicity and ease of the technique (53%), and the lack of theatre time or anaesthetic cover (32%).

*Surgeons who perform pneumatic retinopathy frequently*

The 16% of surgeons who said that they perform PR frequently estimate their success rate at 80% (SD 8.8). The simplicity and ease of the procedure is their main reason for using it (82%). Other reasons include its high success rate for primary reattachment (64%) and patients unfit for more invasive surgery (55%).

### COMMENT

This study demonstrates that pneumatic retinopathy is not popular as a first procedure in the treatment of primary rhegmatogenous retinal detachment among most vitreoretinal surgeons in the UK. A survey conducted in North America and published in 1993<sup>6</sup> revealed the selective use of this technique among American vitreoretinal surgeons with geographic pockets of increased use in California and Florida. A more recent survey confirmed these regional differences

and demonstrated an increase in the popularity of PR among younger retinal specialists.<sup>7</sup>

A C ASSI  
D G CHARTERIS  
Z J GREGOR  
*Moorfields Eye Hospital, City Road, London  
EC1V 2PD, UK*

Correspondence to: Mr A Assi  
Accepted for publication 11 August 2000

- 1 Tornambe PE, Hilton GF. The Retinal Detachment Study Group. Pneumatic retinopathy: a multicenter randomized controlled clinical trial comparing pneumatic retinopathy with scleral buckling. *Ophthalmology* 1989;**96**:772–84
- 2 Tornambe PE, Hilton GF. The Retinal Detachment Study Group. Pneumatic retinopathy: a two year follow-up study of the multicenter trial comparing pneumatic retinopathy with scleral buckling. *Ophthalmology* 1991;**98**:1115–23
- 3 Liggett PE. Clinical experience: Doheny Eye Institute, Los Angeles, California. In: Tornambe PE, Grizzard WS, eds. *Pneumatic retinopathy: a clinical symposium*, 1988. Chicago: Greenwood, 1989:155–6.
- 4 Hilton GF, Kelly NE, Salzano TC, et al. Pneumatic retinopathy: a collaborative report of the first 100 cases. *Ophthalmology* 1987;**94**:307–14
- 5 Assi AC, Charteris DG, Pearson RV, et al. Pneumatic retinopathy in the treatment of primary rhegmatogenous retinal detachment. *Eye* 1999;**13**:725–8
- 6 Ai E, Gardner TW. Current patterns of intraocular gas use in North America. *Arch Ophthalmol* 1993;**111**:331–2.
- 7 Benson WE, Chan P, Sharma S, et al. Current popularity of pneumatic retinopathy. *Retina* 1999;**19**:238–41.

### Does instilling proxymetacaine before cyclopentolate significantly reduce stinging? The implications for paediatric cycloplegia

EDITOR.—Cyclopentolate 1% is the drug most commonly used to obtain paediatric pupil dilatation and cycloplegia. It is widely disliked by children and ophthalmic staff because of the severe stinging instillation may produce. As a result many children develop a negative association with the clinic, and become distressed and uncooperative before drop instillation and during subsequent examinations. To try to reduce this discomfort, previous instillation of the local anaesthetic proxymetacaine has been advocated in a single study,<sup>1</sup> which reported significant benefit. However, this was a retrospective study, with the particular limitation of using parental recall of their child's distress a year previously, as the measure of the pain experienced with the use of cyclopentolate alone. We therefore considered that more data were required before the use of proxymetacaine is included in routine cycloplegia.

Because cyclopentolate is unstable at neutral pH, preparations are acidified with dilute hydrochloric acid to around pH 4 so that stinging on instillation might be expected.

However, although proxymetacaine has been shown to sting less than other local anaesthetic drops, it is also acidified with hydrochloric acid to a similar pH and can cause discomfort

It could be that stinging is not the sole reason for children's unhappy memories of their clinic visit. Factors not yet evaluated include lack of understanding, a dislike of eye examination, and a recollection of the prolonged blurring produced by the cycloplegia in hypermetropes.

We designed a study to quantify the pain experienced by patients specifically attributable to cyclopentolate minims 1%, with and

Table 1 Results ranked in order of increasing pain score

	Mean pain score	SD
Saline	0.16	0.27
Cyclopentolate with prior proxymetacaine	0.36	0.60
Proxymetacaine	0.79	0.86
Cyclopentolate with prior saline	4.19	2.43

Table 2 Combined pain score

Total pain score	Mean pain score	SD
Saline plus cyclopentolate	4.29	2.54
Proxymetacaine plus cyclopentolate	1.16	1.10

without previous instillation of proxymetacaine minims.

We enrolled only adult subjects to allow for accurate numerical pain scoring and to exclude the confounding factors mentioned above. Subjects were adult patients attending the ophthalmology clinic for the first time. Exclusions were pre-existing corneal disease, eye surgery, eye drop use, or an inability to understand the pain scoring system. Informed consent was obtained including the use of an information sheet approved by Tayside ethics committee.

Participating subjects had either proxymetacaine 0.5% or saline instilled in their first eye (either left or right was chosen randomly). Using a standard numerical pain scoring system of 0 to 10, the subjects were asked to record the pain score after all stinging pain has stopped. They were encouraged to record the score of the stinging at its peak. The score was re-recorded after instilling the second, remaining drop in the fellow eye. The process was repeated with the instillation of cyclopentolate 1%, sequentially, in each eye approximately 45 seconds later.

We used a standard numerical pain scoring system 0 to 10. The saline and proxymetacaine labels were covered so that the tests were double blind. All the tests were carried out by one investigator (MS).

In all, 29 subjects completed the study. The age range was 29–84 years, with an average age of 66 years. The mean pain score for proxymetacaine was 0.79 (SD 0.86). This compares with a mean pain score of 0.16 (SD 0.27) with saline. The difference between these is statistically significant ( $p < 0.001$ ). The mean pain score for cyclopentolate instilled after proxymetacaine was 0.36 (SD 0.60). This compares with a mean pain score of 4.19 in the patients who received cyclopentolate after the placebo saline (SD 2.43). This result was highly significant ( $p < 0.001$ ). Taking the total pain scores for each eye and using a parametric test the difference between the total pain scores was found to be highly significant ( $p < 0.001$ ) (Whitney U test). These results are summarised in Tables 1 and 2.

### COMMENT

In this study we found a highly statistically significant reduction in total discomfort with cyclopentolate instilled after premedication with proxymetacaine compared with the use of cyclopentolate instilled after a placebo. We also demonstrated that proxymetacaine does cause some discomfort although this is minor compared with cyclopentolate alone. Most of the pain from the combined medication came from the initial proxymetacaine drop. It has



been demonstrated elsewhere that diluting proxymetacaine 0.5% can reduce this stinging substantially without compromising efficacy.<sup>2</sup> In practice, however, only the 0.5% preparation is currently commercially available.

This study provides support for the hypothesis that previous instillation of local anaesthetic should reduce discomfort in paediatric cycloplegia. However, as other factors may contribute to the discomfort experienced by children, further studies are required to determine if this benefit is realised in practice. Even if pretreatment with proxymetacaine does prove to be advantageous, it remains an unsatisfactory compromise. Ultimately the best solution to this important issue will be the development of a short acting, non-stinging cycloplegic which is stable at a neutral pH and iso-osmolar with tears.

The authors would like to thank Dr Ruoling Chen for his help preparing the statistics in this study

M S M SUTHERLAND  
J D H YOUNG

Department of Ophthalmology, Ninewells Hospital and Medical School, Dundee DD1 9SY, UK

Correspondence to: Dr Shona Sutherland  
Accepted for publication 28 August 2000

- Shah P, Jacks AS, Adams GG. Paediatric cycloplegia: a new approach. *Eye* 1997;11(Pt 3):845-6.
- Brady MD, Husted RR, Robinson RH, et al. Dilution of proparacaine in balanced salt solution reduces pain of anaesthetic instillation in the eye. *Reg Anesth* 199;19:196-8.

### Delayed quinine toxicity mimicking open angle glaucoma

EDITOR.—Ocular quinine toxicity from acute overdose is much more rare than in the past. It manifests as severe peripheral vision loss associated with severe retinal arteriole constriction. Although the optic nerve head does not develop characteristic cupping, the extensive field loss can be misinterpreted as glaucoma-

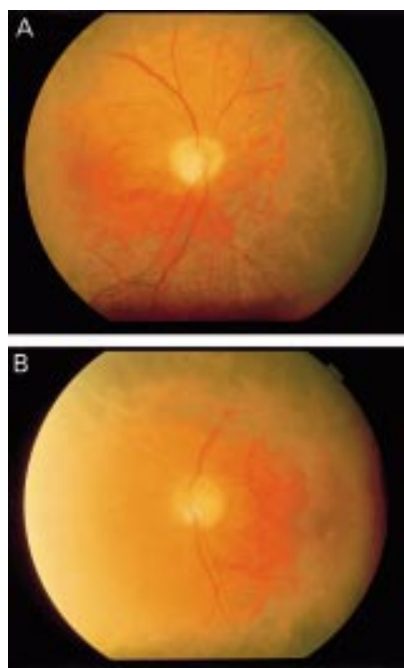


Figure 1 Fundus photos (A) right eye, (B) left eye. Severe attenuation of retinal vasculature. Drusen evident in mid-periphery. A small central cup is present in both optic nerves.

tous in nature. Severe retinal arteriolar constriction and extensive electrophysiological abnormalities can provide help in differentiating these two conditions.

### CASE REPORT

This 79 year old non-English speaking, Greek woman was referred for evaluation and management of advanced glaucoma. According to the referring physician, the patient had a history of glaucoma diagnosed approximately 2 years earlier. Intraocular pressures had been in the high teens to low 20s range on a regimen of Xalatan QHS in both eyes. Humphrey visual fields had been obtained revealing severe peripheral loss.

On presentation the patient complained of poor vision for the past few years, the right eye worse than the left and discomfort in the right eye. She had been seen by ophthalmologists in Brazil, Greece, and the United States. She had undergone laser procedures twice in the right eye and once in the left, for glaucoma. Her past medical history was only significant for falls resulting in an ankle and hip fracture approximately 3 months ago. Review of systems was non-contributory. The patient was on no systemic medications except for pain medications for a painful hip. She was also taking Xalatan 0.005% QHS in both eyes. According to the referring physician's note, the patient had not tolerated Timoptic, Alphagan, and Trusopt.

Visual acuity was 20/60-2 right eye and 20/80-1 left eye. Manifest refraction improved visual acuity to 20/30 right eye with +4.00-

1.50 × 90° and to 20/40 left eye with -3.00-1.00 × 90°. Goldmann visual fields demonstrated severe constriction in both eyes.

External examination revealed bilateral ptosis in both eyes. The pupils were equal and reactive to light without afferent pupillary defect. Ocular motility was intact.

Slit lamp examination revealed dry eyes, clear corneas, and deep and quiet anterior chambers in both eyes. Patent peripheral iridotomies were present superiorly in both eyes. Intraocular pressures by Goldmann applanation tonometry were 20 mm Hg right eye and 21 mm Hg left eye. Zeiss gonioscopy revealed grade 3 to 4 open angles in both eyes.

Dilated slit lamp examination revealed 2+ nuclear sclerotic changes in the right eye and 3+ nuclear sclerotic changes in the left. Dilated fundus examination revealed drusen in the mid-periphery. The retina appeared to be slightly hazy. Thin threadlike arteries and veins were noted in both eyes (Fig 1). Dilated stereobiomicroscopic examination of the optic nerve heads revealed pale nerves in both eyes and areas of peripapillary atrophy. Central cups with approximate dimensions of 0.4 vertically by 0.3 horizontally (c/d ratio) were present in both eyes (Fig 1).

The patient then volunteered one additional piece of information that she had withheld from her past ocular history. She revealed that 49 years earlier she had attempted suicide with an overdose of quinine. She apparently ingested 120 tablets of quinine (unable to determine the actual amount of quinine that she had consumed). She was hospitalised for

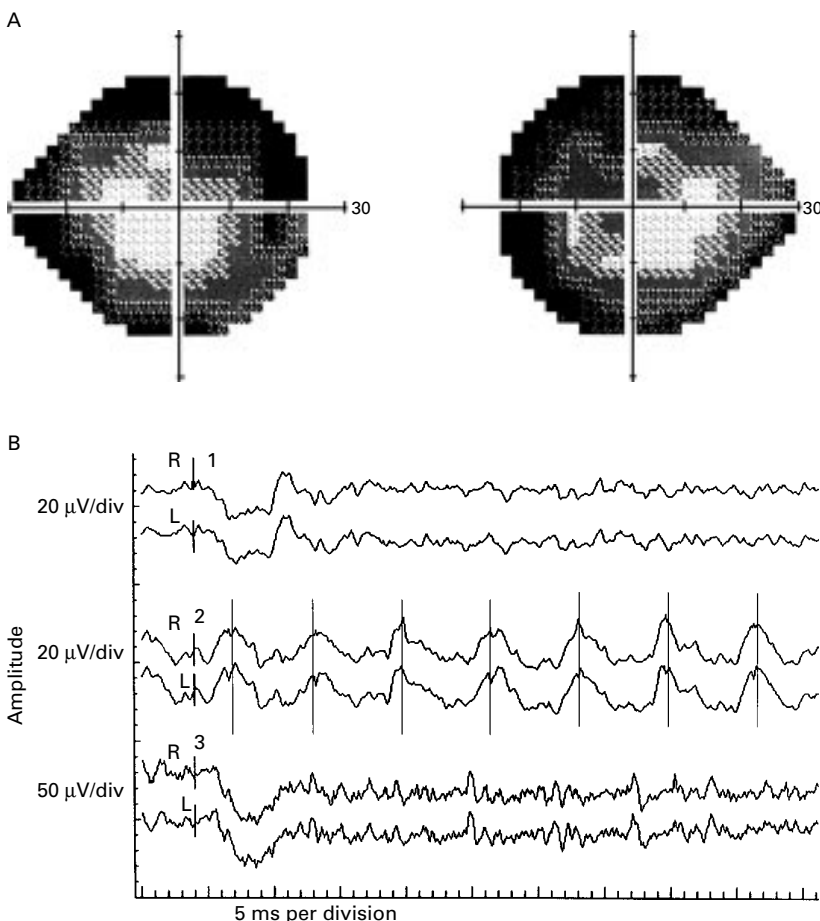


Figure 2 (A) Full threshold Humphrey visual fields indicating severe constriction of peripheral vision in both eyes. (B). ERG recordings under photopic (1), photopic flicker (2) and scotopic (3) conditions. Significant increase in b-wave implicit time and attenuation of b-wave amplitude.



more than 10 days and she had apparently lost her vision for approximately 1 week following this attempted suicide. Vision had slowly recovered after this period of total blindness.

An ERG was obtained on a separate visit (Fig 2). ERG recordings were obtained from the two eyes simultaneously. Under photopic conditions, there was an unusual scooped out photopic a-wave with b-wave amplitudes of only 60  $\mu$ V. B-wave implicit times were prolonged. Responses to photopic flicker were similarly reduced in amplitude and prolonged in latency. Following dark adaptation, scotopic wave forms showed an electronegative wave form with a-wave amplitudes of about 160  $\mu$ V.

#### COMMENT

This is a case of quinine toxicity which has been extremely rare in recent years. Quinine is an alkaloid obtained from cinchona bark and has been used principally as an antimalarial agent. Although it has been one of the oldest antimalarials it is now indicated in the treatment of chloroquine resistant malaria caused by *Plasmodium falciparum*.<sup>1</sup> Quinine has also been used for the prophylaxis and treatment of nocturnal leg muscle cramps<sup>1</sup> as well as in the treatment of severe babesiosis caused by *Babesia microti*.<sup>1</sup> In the past quinine has been used as an abortifacient.<sup>2</sup>

It has been known for approximately 150 years that quinine can disturb vision and hearing, especially in people who have taken an overdose.<sup>3</sup> More than 250 articles have been published during the past 80 years concerning the toxic effect of quinine on the eyes. Mild effects include clouding of vision and flickering while more severe intoxication has led to sudden complete blindness often realised after the patient emerges from deep coma with circulatory collapse.<sup>4</sup> As a rule, the central vision has recovered even in these cases, at least partially, but quite characteristically, peripheral visual fields remain constricted.<sup>4</sup>

Ophthalmoscopic appearance in the acute phase of quinine toxicity varies with reports of early oedema, constriction of the retinal blood vessels, or a completely normal appearance.<sup>4</sup> In the late stages, optic nerves have been found to be pale and vessels narrowed, almost uniformly.<sup>4</sup> Electroretinographic and electro-oculographic measurements have shown practically normal ERGs in the acute phase. However, severe disturbances of the ERGs were noted later on. In particular, disappearance of the b-wave has been noted.<sup>5,6</sup>

Histological examination of the retina from patients who have developed quinine toxicity has been rare. In the few instances where the eyes have been examined histologically retinal ganglion cells and the nerve fibre layer were found to be degenerated and rods and cones atrophic.<sup>7</sup>

The ERG data, fundus appearance, and the few cases of histological examination of affected retinas have raised the question of whether the damage to retinal ganglion cells and the outer retina is the primary event or secondary phenomenon related to arteriolar constriction which is evident after the acute phase. Experimental administration of quinine intravenously or intravitreally in rabbits causes a reversible inversion of the c-wave.<sup>8</sup> This has been interpreted as a direct toxic effect on the retinal pigment epithelium. In excised pieces of rabbit retina high dose quinine was found to reversibly delete the b-wave of the ERG.<sup>9,10</sup> Other animal experiments have shown vacuolisation of the retinal ganglion cells as the most common histologi-

cal response to quinine intoxication. Endarteritis and periarteritis have been reported but the degree of damage appears greater than that caused by interruption of blood supply. In addition, no changes in oxygen metabolism or glucose uptake in retinas of acutely poisoned animals have been detected. At later stages, when the degeneration is evident, the metabolism becomes affected. It appears now that the majority of experimental data support the view of a direct toxic effect of quinine on retinal ganglion cells.

JOHN DANIAS  
SCOTT BRODIE

Department of Ophthalmology, Mt Sinai School of Medicine, New York, USA

Correspondence to: John Danias, MD, PhD, Department of Ophthalmology, Box 1183, Mt Sinai School of Medicine, 1 Gustave L Levy Place, New York, NY 10029, USA

danias@msvax.mssm.edu

Accepted for publication 19 September 2000

- 1 Quinine. In: *Drug information for the health care professional*. Rockville, MD: The United States Pharmacopoeia Convention Inc, USP DI, 1998:571-4.
- 2 Benowitz NL. Quinine. In: Olson KR, ed. *Poisoning and drug overdose*. New York: Prentice Hall International, 1990.
- 3 Berggren L, Rendahl I. Quinine amblyopia. *Acta Ophthalmol* 1995;33:217-28.
- 4 Grant MW. Quinine. In: *Toxicology of the eye*. 2nd ed. Springfield, IL: Charles C Thomas, 1974.
- 5 Behrman J, Mushin A. Electrodiagnostic findings in quinine amblyopia. *Br J Ophthalmol* 1968;52:925-8.
- 6 Vaino-Mattila B, Zewi M. Quinine amblyopia and the electroretinogram. *Acta Ophthalmol* 1954;32:451-61.
- 7 Casini F. Il metabolismo respiratorio della retina nell'intossicazione sperimentale da chinino. *Arch Ottalmol* 1939;46:263-79.
- 8 Junemann G, Schulze J. Elektretinographische Untersuchungen zur Entesehung der Chinin- bzw. Resochin-Retinopathie. *Klin Monatsbl Augenheilkd* 1968;152:562-6.
- 9 Hommer J. The effects of quinine, chloroquine, iodacetate and chlordiazepoxide on the ERG of the isolated rabbit retina. *Graefes Arch Klin Exp Ophthalmol* 1968;175:111-20.
- 10 Hommer K, Ulrich WD, Wundsck L. The effects of antimalarial compounds on the ERG recorded in situ. *Graefes Arch Klin Exp Ophthalmol* 1968;175:121-30.

#### Progressive assessment of age related macular degeneration using an artificial neural network approach

EDITOR.—The key to successful age related macular degeneration (ARMD) screening is the efficient production of accurate classified images with minimum patient inconvenience.<sup>1</sup> The technologies of digital image analysis and artificial neural networks (ANN) are not new and have been used in the past to provide a more objective basis for a range of medical applications.<sup>2-9</sup> They have, however, not been used for operational classification of macu-

lopathies such as ARMD. Research has shown that ANN computer programs are capable of discriminating normal fundus from those with diabetic retinopathy, potentially reducing the numbers of images requiring expert examination by 70% or more.<sup>10</sup>

Digital fundus images from a Topcon Imagenet camera were modified by in-house computer imaging techniques (ERDAS Imagine Software) within a geographical information system (GIS) (Fig 1). The ANN used was a standard back propagation multilayer perceptron, running within the Stuttgart neural network system (SNNS) program.

The validating criteria for the study came from a small group of ophthalmologists carrying out masked assessment of a series of fundus images (stereo 35 mm slides and digital fundus images) which either contained ARMD at different confidence levels of judgment or which did not contain ARMD.

#### CASE REPORT

A total of 87 sample images of the drusen features under analysis were extracted from the postprocessed fundus images, of which 30 were used as test samples for operational accuracy assessments. Each extracted image represented a square sample of  $11 \times 11$  (121) pixels of intensity information (the intensity information was the relative "brightness" of the feature within the range, 1-255 black to white). The feature types assessed constituted three subcategories within the grading system hierarchy; these were hard drusen (HD), large soft distinct drusen (LSD), and serogranular drusen (SGD). All other features indicative of ARMD such as haemorrhages, blood vessels, etc, were grouped into the background fundus class (FB) actively excluding them from further assessment. The choice of kernel size at  $11 \times 11$  pixels was chosen because the main focus at this stage of the research was to differentiate the drusen subtypes using hard distinct drusen as the main discriminator and generally all sample features fit well within this window size. The ANN required approximately 10 000 iterations in order to categorise the training samples to within the accepted error margin of 0.01 and, after being analysed by both the expert assessor and the ANN model, the sample outputs were finally compared as shown in Table 1 to assess the accuracy of the computer based analysis system with the clinical standard.

The ANN, compared with the reference assessment across all test feature classes, yielded an overall accuracy of 69.21%, with sensitivity to drusen classes (HD/SGD) being 95%/99% respectively and specificity 55% and 75%.

The overall accuracy of the ANN test method across the two test feature classes was

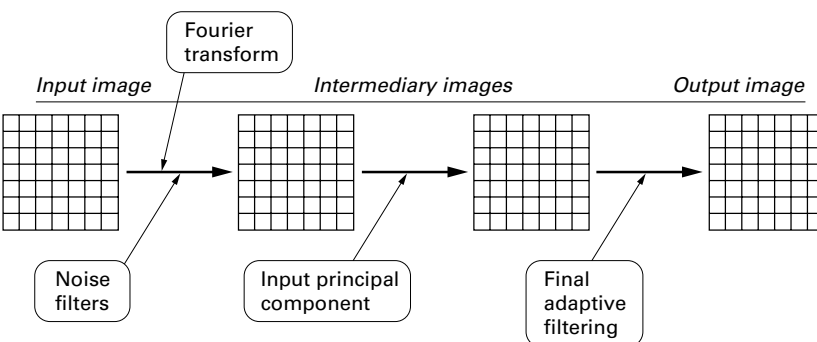


Figure 1 Flow diagram of image analysis methodology.

Table 1 Error matrix of ANN assessment against reference (clinical) assessment

ANN classification	Clinical assessment					Operational accuracy
	FB	HD	SGD	LSD	Total	
Fundus background	—	—	—	—	—	—
Hard drusen	62.9	373.1	10.9	230.6	677.5	55.07%
Serogranular drusen	393.5	15.9	1279.2	15.5	1704.1	75.07%
Large soft distinct drusen	0.03	3.32	2.5	0.31	6.16	5.03%
Total	456.43	392.32	1292.6	246.41	→	2387.76
System accuracy	—	95.1%	98.96%	0.13%	2387.76	1652.61

Note: The tabular data above are raw output values of likelihood weightings produced from the ANN analysis.

found to be 66%, with 72% and 90% sensitivity (HD/SGD) and 72% and 63% Specificity respectively. Current published literature on ANN pattern recognition tasks suggests that results of ~70% overall accuracy indicate a good result for first stage ANN analyses. The results obtained in this study with values of (95%+ sensitivity, 75% specificity) indicate that both types of drusen are being clearly differentiated by the ANN

The neural network was trained to an accuracy of within 0.01 for each drusen subtype (hard, serogranular, and large soft distinct drusen) before the validation set was classified. Results indicate that the neural network performed better with more numerous feature classes available; the system sensitivity overall being found to be 95% with 75% specificity.

#### COMMENT

A simple methodology for using computer based image processing and feature detection techniques to accurately quantify drusen has been presented and results are comparable with clinical trials. This approach could be applied to operational assessment of fundus diseases providing benefits both in time management and associated cost.

Thanks are due to the Gift of Thomas Pocklington and the Royal College of Surgeons for funded support towards this study.

J MORGAN-DAVIES  
N K TAYLOR  
A M ARMBRECHT  
P ASPINALL  
B DHILLON

Medical Imaging RG, Geomatics Unit, Faculty of Environmental Studies, ECA/Heriot Watt, 79 Grassmarket, Edinburgh EH1 2HJ, UK

Correspondence to: Mr Morgan-Davies

justin@eca.ac.uk

Accepted for publication 9 October 2000

- Williamson TH, Keating D. Telemedicine and computers in diabetic retinopathy screening. *Br J Ophthalmol* 1998;82:5-7.
- Shin DS, Javornik NB, Berger JW. Computer-assisted, interactive fundus image processing for macular drusen quantitation. *Ophthalmology* 1999;106:1119-25.
- Brigatti L, Hoffman D, Caprioli J. Neural networks to identify glaucoma with structural and functional measurements. *Am J Ophthalmol* 1996;121:511-21.
- De Roach JN. Neural networks B an artificial intelligence approach to the analysis of clinical data. *Aust Phys Eng Sci Med* 1989;12:100-6.
- Gardner GG, Keating D, Williamson TH, et al. Detection of diabetic retinopathy using neural network analysis of fundus images. *Proceedings of International Conference on Neural Networks and Expert Systems in Medicine and Health Care*. University of Plymouth, 1996:28-35.
- Kerr JP, Bartlett EB. Medical image processing utilising neural networks trained on a massively parallel computer. *Comput Biol Med* 1995;25:393-403.
- Kirkpatrick JNP, Spencer T, Manivannan A, et al. Quantitative image analysis of macular drusen from fundus photographs and scanning laser ophthalmoscope images. *Eye* 1995;9:48-55.
- Peli E, Lahav M. Drusen measurement from fundus photographs using computer image analysis. *Ophthalmology* 1986;93:1575-80.

9 Sebag M, Peli E, Lahav M. Image analysis of changes in drusen area. *Acta Ophthalmol* 1991;69:603-10.

10 Gardner GG, Keating D, Williamson TH, et al. Automatic detection of diabetic retinopathy using an artificial neural network: a screening tool. *Br J Ophthalmol* 1996;80:940-4.

#### Iatrogenic keratectasia after phototherapeutic keratectomy

EDITOR.—Several cases of iatrogenic keratectasia have been reported after laser in situ keratomileusis (LASIK).<sup>1-4</sup> Until now, there has been no report of keratectasia after phototherapeutic keratectomy (PTK), presumably because PTK employs less laser ablation of the corneal stroma than LASIK. Previous studies demonstrated that thickness of the residual stromal bed is critical in the development of this complication.<sup>1-4</sup>

We describe a case of progressive corneal ectasia following PTK for the treatment of band keratopathy. Even though the residual corneal thickness was greater than 500 µm, the patient developed steepening of the cornea, irregular astigmatism, and progressive myopia.

#### CASE REPORT

A 76 year old woman was referred to Miyata Eye Hospital for the treatment of bilateral band keratopathy. She had no apparent systemic or ocular disorders related to the development of band keratopathy, such as uveitis, long term use of miotics, hypercalcaemia, chronic renal disease, tuberculosis, or connective tissue diseases. The best spectacle corrected visual acuity (BSCVA) was 6/20 in the right eye with a refraction of cyl -1.5 dioptres (D) and 8/20 in the left eye with +1.5 D cyl +1.0 D. The central corneal thickness measured with the ultrasound pachymeter (UP-2000, Nidek Co, Ltd, Aichi, Japan) was 541 µm and 540 µm in the right and left eyes, respectively. PTK was performed on the right eye with Star excimer laser system version 2.50 (Visx, Inc, Santa Clara, CA, USA). Using the transepithelial technique, 200 pulses were applied to ablate 48 µm of the cornea. The treatment zone was 6 mm in diameter with a 0.7 mm transition zone. A soft contact lens was worn for 3 days following the procedure. The re-epithelialisation was complete within the first postoperative week. One month after surgery, BSCVA was 20/20 with -3.5 D and corneal thickness was 517 µm. By the third month after surgery, BSCVA deteriorated to 10/20 with a spectacle lens of -10.0 D. At 6 months after surgery, BSCVA was 10/20 with -10.0 D and the central corneal thickness was 513 µm. The colour coded maps of the videokeratography (TMS-2, Computed Anatomy Inc, New York, NY, USA) obtained serially after surgery showed progressive keratectasia in the central area (Fig 1). The scanning slit corneal topography (Orbscan, Orbtex, Inc, Salt Lake City, UT, USA) taken 6 months after surgery revealed a marked elevation of the posterior surface in the central area,

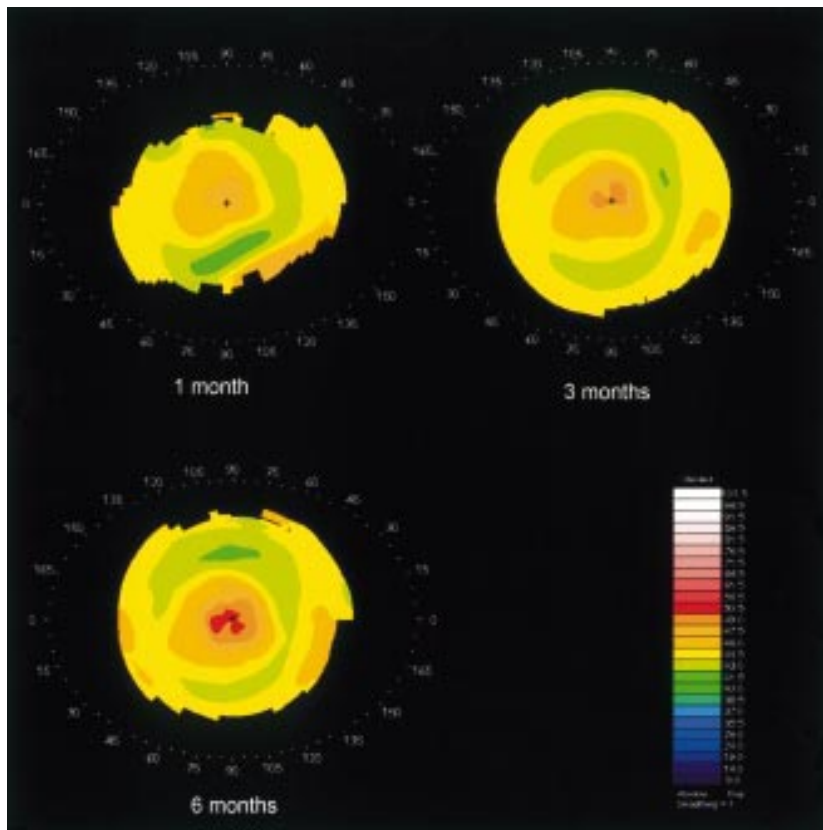


Figure 1 Colour coded maps taken 1, 3, and 6 months after phototherapeutic keratectomy for band keratopathy, demonstrating marked and progressive steepening of the central cornea.



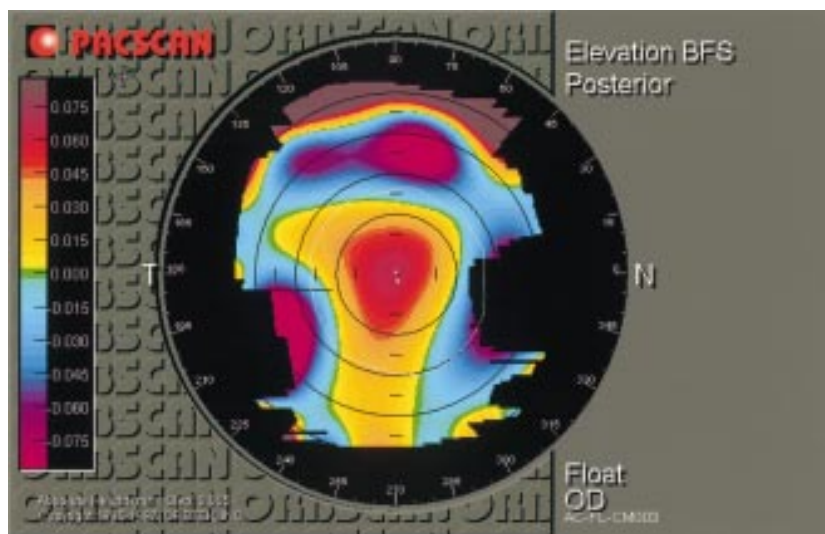


Figure 2 An elevation map of the posterior corneal surface obtained 6 months after surgery. There is an evident elevation of the central area, indicating forward protrusion of the cornea.

indicating anterior protrusion of the central cornea (Fig 2). Since then, the anterior and posterior topographies did not show apparent progression during the observation period up to 1 year after PTK.

#### COMMENT

This is the first documentation of iatrogenic keratectasia after PTK. In LASIK, the minimum thickness of the residual stromal bed to avoid corneal ectasia has been claimed to be 250–300  $\mu\text{m}$ ,<sup>1,3,4</sup> approximately corresponding to the postoperative total corneal thickness of 400–450  $\mu\text{m}$ . The postoperative corneal thick-

ness in the current patient was greater than 500  $\mu\text{m}$ . Moreover, it has been postulated that the risk of keratectasia following surface excimer laser surgery might be lower than that following LASIK because of the relatively thicker effective stress bearing corneal stroma after surgery.<sup>4,5</sup> Nevertheless, this patient demonstrated keratectasia as evidenced by steepening of the cornea, irregular astigmatism, and progressive myopia. It seems that the histopathological changes due to band keratopathy had already compromised the tensile strength of the cornea<sup>6</sup> and the laser ablation further weakened the tissue to the degree that

progressive ectasia ensued. The age of patient might have played a part. It was suggested that the safety limit of residual corneal thickness in normal eyes may not directly apply to diseased corneas.

None of the authors has a proprietary interest in any material or method mentioned here.

KAZUNORI MIYATA

TETSUYA TAKAHASHI

Miyata Eye Hospital, 6-3, Kuraharacho,  
Miyakonojo-shi, Miyazaki, Japan

ATSUO TOMIDOKORO

Department of Ophthalmology, Omiya Red Cross  
Hospital, 8-3-33 Yono-shi, Saitama, Japan

KYOKO ONO

TETSURO OSHIKA

Department of Ophthalmology, University of Tokyo  
School of Medicine, 7-3-1, Hongo, Bunkyo-ku,  
Tokyo, Japan

Correspondence to: Kazunori Miyata, MD, Miyata  
Eye Hospital, 6-3, Kuraharacho, Miyakonojo-shi,  
Miyazaki, 885-0051, Japan  
miyata@miyata-med.ne.jp

Accepted for publication 7 September 2000

- 1 Seiler T, Koufala K, Richter G. Iatrogenic keratectasia after laser in situ keratomileusis. *J Refract Surg* 1998;14:312–17.
- 2 Seiler T, Quirke AW. Iatrogenic keratectasia after LASIK in a case of forme fruste keratoconus. *J Cataract Refract Surg* 1998;24:1007–9.
- 3 Geggel HS, Talley AR. Delayed onset keratectasia following laser in situ keratomileusis. *J Cataract Refract Surg* 1999;25:582–6.
- 4 McLeod SD, Kislak TA, Caro NC, et al. Iatrogenic keratoconus: corneal ectasia following laser in situ keratomileusis for myopia. *Arch Ophthalmol* 2000;118:282–4.
- 5 Andreassen TT, Simonsen AH, Oxlund H. Biomechanical properties of keratoconus and normal corneas. *Exp Eye Res* 1980;31:435–41.
- 6 Binder PS, Anderson JA, Rock ME, et al. Human excimer laser keratectomy. Clinical and histopathologic correlations. *Ophthalmology* 1994; 101:979–89.