

## LETTERS TO THE EDITOR

### Primary sebaceous carcinoma of the lacrimal gland

EDITOR.—Sebaceous carcinoma is a rare primary neoplasm of the lacrimal gland and to the best of our knowledge only five cases have previously been reported.<sup>1-5</sup> Sebaceous carcinoma of the orbit more commonly occurs as secondary invasion from the eyelid but may occur as metastatic spread from elsewhere in the body. We report a case of primary sebaceous carcinoma of the lacrimal gland and discuss the histological diagnosis and management of the disease.

#### CASE REPORT

A 35 year old woman was referred with a 6 month history of a gradually enlarging palpable mass arising in the left superotemporal orbit and causing painless, and progressive diplopia. On examination she had a palpable, hard, fixed, left superotemporal orbital mass, a non-axial proptosis, and hypoglobus. The eyelids were normal. Examination of ocular motility revealed a restriction of left elevation. In addition, she was found to have an enlarged, painless ipsilateral preauricular lymph node. Computed tomograph (CT) and magnetic resonance imaging (MRI) scans showed the mass was arising from the lacrimal gland (Fig 1).

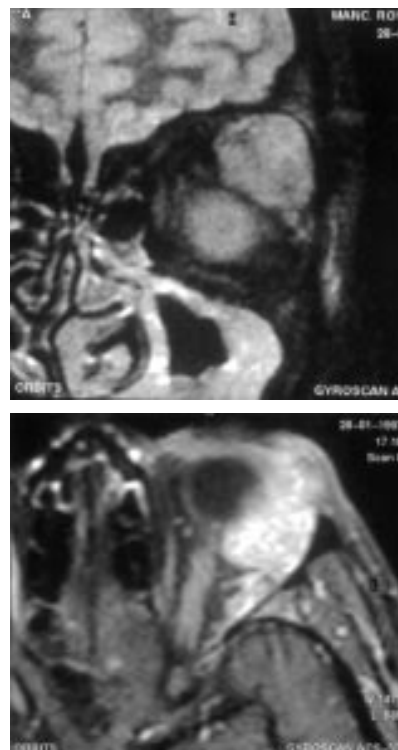


Figure 1 (Top) Coronal fluid attenuated inversion recovery (FLAIR) image showing a large lacrimal gland mass. The tumour is well delineated and shows minimal heterogeneity. (Bottom) Axial post-contrast T1 weighted image with fat suppression. The tumour is again seen to be well demarcated and shows marked homogeneous enhancement.

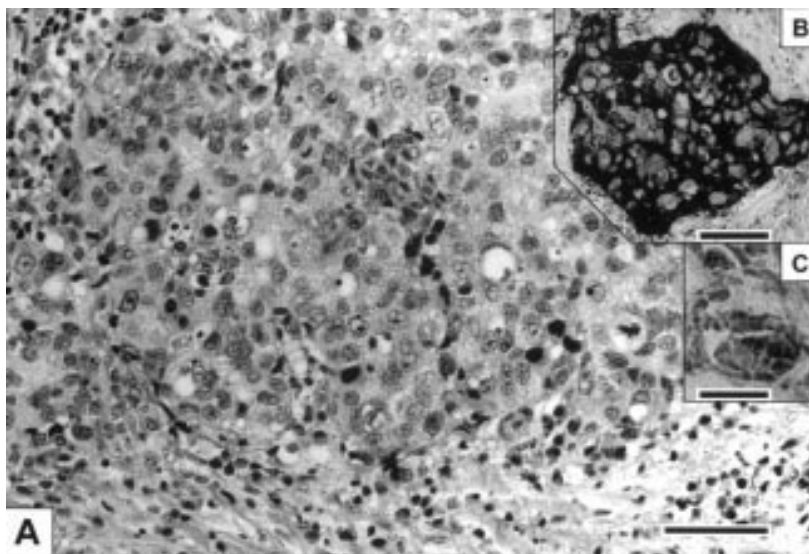


Figure 2 (A) (Haematoxylin and eosin, scale bar = 70  $\mu$ m). The neoplasm is composed of lobulated masses of large cells with large nuclei and a prominent nucleolus. Many cells contain vacuolated cytoplasm. Mitotic figures and apoptotic bodies are present. There is a desmoplastic connective tissue response in which there are many lymphocytes. Neoplastic cells were negative with mucin stains, but contained PAS positive glycogen. No melanin was demonstrated. Tumour cells are positive with epithelial membrane antigen (EMA) (inset B, scale bar = 100  $\mu$ m) and contain lipid (inset C, oil red O, scale bar = 50  $\mu$ m).

A transseptal biopsy of the mass was performed and histological examination showed tissue infiltrated by carcinoma in which the neoplastic cells were large and contained prominent nucleoli. Many cells were vacuolated and contained lipid as confirmed by fat stains on unprocessed, fixed material. Immunohistochemistry revealed strongly positive staining for epithelial membrane antigen (EMA) but negative staining with anti-cytokeratin, indicating the carcinoma to be of sebaceous origin (Fig 2). Metastatic spread from another primary site was excluded by general physical examination, chest x ray, mammography, and isotopic bone scan undertaken by an oncologist.

A left orbital exenteration with left superficial parotidectomy and excision of left cervical lymph nodes was performed. Histological examination of the exenteration specimen showed a 35  $\times$  30  $\times$  18 mm tumour arising in the region of the lacrimal gland, which had been entirely replaced by sebaceous carcinoma, with only a small focus of ductal tissue being present at the margin of the tumour at one point. There was no involvement of the overlying periorbital skin, eyelid, or conjunctiva. The preauricular lymph node contained metastatic deposits, although her cervical lymph nodes were free from metastatic disease.

Postoperatively she underwent radiotherapy to the involved area and the orbit was allowed to granulate and re-epithelialise. Nine months after the surgery an isolated soft, mobile node was noted in the neck. This increased in size over 2 months and was found to be recurrent metastatic carcinoma on fine needle aspiration biopsy. Radical dissection of nodes in the neck confirmed involvement of 30-40 nodes and the patient received further radiotherapy. Six months after this, a swelling in the parotid region without lymphadenopathy again showed recurrent tumour. This lesion responded well to radiotherapy alone. Since then she has achieved good cosmesis with an orbital prosthesis and at the time of writing 3 years after original diagnosis she remains well with no signs of residual tumour.

#### COMMENT

Primary sebaceous carcinoma of the lacrimal gland possibly arising from heterotopic sebaceous tissue is extremely rare and must be differentiated from secondary invasion of the orbit by a primary eyelid tumour or metastatic spread from other areas of the body. The tumour is highly malignant and metastases to the preauricular and deep cervical lymph nodes occur early in the disease. Orbital exenteration is required and in addition parotidectomy and cervical lymphadenectomy combined with postoperative radiotherapy should be considered as part of the management. The prognosis in previously reported patients was poor with local recurrences and metastases leading to death within 1 year. One previous patient survived to 22 months postoperatively.<sup>2</sup> At the time of writing our patient is the first to show 3 year survival without evidence of further recurrence.

D BRISCOE

Department of Ophthalmology, Meir Hospital, Kfar Saba, Israel

S MAHMOOD

R BONSHK

Manchester Royal Eye Hospital, Oxford Road, Manchester M13 9WH, UK

A JACKSON

Manchester Royal Infirmary

B LEATHERBARROW

Manchester Royal Eye Hospital

Correspondence to: Mr B Leatherbarrow, Royal Eye Hospital, Manchester M13 9WH, UK  
bollin@mighty-micro.co.uk

Accepted for publication 20 December 2000

- Jakobiec FA. Sebaceous tumours of the ocular adnexa. In: Albert DM, Jakobiec FA, eds. *Principles and practice of ophthalmology*. Philadelphia: WB Saunders, 1994;3:1768-70.
- Rodgers IR, Jakobiec FA, Gingold MP, et al. Anaplastic carcinoma of the lacrimal gland presenting with recurrent subconjunctival hemorrhages and displaying incipient sebaceous differentiation. *Ophthalmic Plast Reconstr Surg* 1991;7:229-37.

- 3 Witchel H, Zimmermann LE: Malignant mixed tumour of the lacrimal gland: a clinicopathological report of two unusual cases. *Graefes Arch Clin Exp Ophthalmol* 1981;216:327-37.
- 4 Konrad EA, Thiel HJ: Adenocarcinoma of the lacrimal gland with sebaceous differentiation: a clinical study using light and electron microscopy. *Graefes Arch Clin Exp Ophthalmol* 1983; 221:81-5.
- 5 Harvey P A, Parsons A, Rennie I: Primary sebaceous carcinoma of lacrimal gland: a previously unreported primary neoplasm. *Eye* 1994;8: 592-5.

### Congenital circumscribed choroidal haemangioma associated with infantile hepatic haemangioendotheliomatosis

EDITOR,—Choroidal haemangiomas are vascular hamartomas that occur in two distinct forms, circumscribed and isolated, or diffuse, as seen in the Sturge-Weber syndrome.<sup>1</sup> Likewise, hepatic haemangioendotheliomas are benign hamartomatous tumours composed of anastomosing vascular channels lined with endothelial cells. Infantile haemangioendotheliomas (IHE) of the liver are congenital lesions noted at birth or during the first 6 months of life. Hepatomegaly, congestive heart failure, and haemangiomas of the skin combine to form the classic symptomatic triad.<sup>2</sup> To our knowledge, this is the first report of a congenital circumscribed choroidal haemangioma and the first noted association of a circumscribed choroidal haemangioma with a visceral neoplasm.

#### CASE REPORT

A 3.75 kg male with an uncomplicated prenatal history was born at full term by normal spontaneous vaginal delivery. At birth, the patient was noted to have a single 1 cm diameter cutaneous haemangioendothelioma of his left upper extremity. There was no family history of ocular diseases or any haemangioma-tous syndromes. The patient's early postnatal course was complicated by hepatic and congestive heart failure. During this time, his cutaneous haemangioendotheliomas had increased in number ranging from 2 mm to 1 cm in diameter involving his right upper extremity, occiput, and chest wall. An ophthalmological examination was requested to exclude a diagnosis of LCHAD (long chain 3-hydroxyacyl coenzyme A dehydrogenase) deficiency, a disorder of mitochondrial fatty acid  $\beta$  oxidation, which is associated with chorioretinal abnormalities. Funduscopic examination revealed pigmentary mottling of his macula and a dulled foveal reflex bilaterally. The optic discs and vasculature were within normal limits. A diagnosis of LCHAD deficiency was not supported by further serological testing. Diagnostic imaging revealed multiple hepatic lesions associated with hepatomegaly. Subsequently, at 7 weeks of age a liver biopsy was performed which confirmed the diagnosis of multiple benign haemangioendotheliomas of the liver. Owing to progressive hepatic and congestive heart failure the patient underwent a living related liver transplantation at 6 months of age. His postoperative course was otherwise unremarkable with normal growth and development and resolution of his cutaneous haemangioendotheliomas.

On follow up ophthalmological examination at 7 months of age the patient was able to fix and follow objects bilaterally without evidence of amblyopia. Funduscopic examination, however, revealed bilateral macular pigment epithelial granularity and mottling, greater in his left eye. Re-examination at 10

months of age demonstrated persistent macular pigmentary changes in the left eye with elevation of the macula. Examination under anaesthesia was subsequently performed at 11 months of age which revealed normal anterior segment and clear crystalline lenses bilaterally. Funduscopic examination showed normal discs, vessels, and retinal periphery in both eyes. The right macula was normal without pigmentary abnormalities but the left macula revealed a raised choroidal lesion with an orange coloration and reactive pigmentary changes without retinal, detachment or subretinal fluid. On A and B-scan ultrasonography the maximum height of the lesion was 2.1 mm and the reflectivity of the lesion was high. The clinical and ultrasonographic appearance was most consistent with the diagnosis of a circumscribed choroidal haemangioma. Given the patient's normal visual acuity and absence of subretinal fluid, observation was recommended in lieu of laser or radiation therapy. Follow up examination at 15 months of age revealed normal visual acuities without progression of the lesion.

#### COMMENT

The pathogenesis of haemangiomas remains largely unknown. Histologically, the hepatic and cutaneous haemangioendotheliomas are composed of vascular channels lined by endothelial cells as well as cells suggestive of pericytes.<sup>3</sup> Similar histological characteristics are shared by circumscribed choroidal haemangiomas which consist of a mixture of small (capillary) or large (cavernous) vascular channels lined by flat endothelial cells separated by connective tissue septae.<sup>1</sup> It has been proposed that persistent arteriovenous shunts, which normally occur in great numbers during the embryogenesis of the choroidal vasculature and then regress, may play a part in the development of choroidal haemangiomas.<sup>4</sup> Whether a similar model may apply in the development of hepatic and cutaneous haemangioendotheliomas remains speculative.

Infantile hepatic and cutaneous haemangioendotheliomas show a high incidence of spontaneous regression and therapeutic measures are recommended only when associated conditions lead to morbidity.<sup>5,6</sup> Although our patient's hepatic lesion eventually required surgical intervention the natural history of these lesions combined with the patient's normal vision and lack of associated vision threatening complications justified observation. Should the choroidal lesion eventually give rise to subretinal fluid, macular detachment, and/or decreased visual acuity the patient may benefit from photocoagulation or radiation therapy. Thus, albeit rare and usually diagnosed in adulthood, circumscribed choroidal haemangiomas may present in a congenital fashion and may also be associated with visceral abnormalities of vasculogenesis.

SAAD SHAIKH  
STEVEN SANISLO

Department of Ophthalmology,  
Stanford University Medical Center

JOAN M O'BRIEN

Department of Ophthalmology,  
University of California, San Francisco

DEBORAH ALCORN  
Department of Ophthalmology and Pediatrics,  
Stanford University Medical Center,  
Lucille Packard Children's Hospital

Correspondence to: Saad Shaikh, MD, Department of Ophthalmology, Stanford University Medical Center, Boswell A157, Stanford, CA 94305, USA  
saads@earthlink.net

Accepted for publication 27 November 2000

- 1 Witschel H, Font RL: Hemangioma of the choroid. A clinicopathologic study of 71 cases and a review of the literature. *Surv Ophthalmol* 1976;20:415-31.
- 2 Zurcher B, Caffisch U, Hofer B, et al: Hemangioendothelioma of the liver. *Z Kinderchir* 1982; 35:26-31.
- 3 Cerar A, Dolenc-Strazar ZD, Bartenjev D: Infantile hemangioendothelioma of the liver in a neonate. Immunohistochemical observations. *Am J Surg Pathol* 1996;20:871-6.
- 4 Heimann K: The development of the choroid in man. *Ophthalmol Res* 1972;3:257-73.
- 5 Pardes JG, Bryan PJ, Gauderer MW: Spontaneous regression of infantile hemangioendotheliomatosis of the liver: demonstration by ultrasound. *J Ultrasound Med* 1982;1:349-53.
- 6 Keslar PJ, Buck JL, Selby DM: From the archives of the AFIP. Infantile hemangioendothelioma of the liver revisited. *Radiographics* 1993;13:657-70.

### Echographic localisation of corticosteroid after retrobulbar injection

EDITOR,—Long acting periocular corticosteroids are commonly used to treat cystoid macular oedema (CMO) resulting from ocular inflammation or cataract surgery that does not respond to topical therapy. Drug localisation to the macular area is considered important for optimal therapeutic effect. In post-cataract CMO refractory to topical therapy, corticosteroids delivered by retrobulbar and posterior sub-Tenon's injections are equally effective.<sup>1</sup> Steroids given by sub-Tenon's injection have previously been shown to localise to the macular area.<sup>2</sup> Retrobulbar anaesthetic injections have been shown to localise in the intraconal space, but not precisely to the macular area.<sup>3,4</sup> We performed ultrasonography after retrobulbar steroid injection to confirm drug localisation in the macular area.

#### CASE REPORT

Sixteen patients with chronic CMO secondary to sarcoid, idiopathic uveitis, or cataract surgery (Irvine-Gass syndrome) were included in the study. The main inclusion criteria were presence of a visually significant form of CMO that had either failed topical anti-inflammatory treatment, or was deemed clinically severe enough to warrant systemic or periocular injections of corticosteroids primarily, and willingness to sign informed consent. The main exclusion criteria was refusal to consent to the procedure.

Each eye was injected with 1-2 ml of 40 mg/ml tramcinolone acetone mixed with 0.5 ml of 2% lignocaine (lidocaine) without adrenaline (epinephrine) using a sharp 1½ inch 25 gauge needle. The needle was inserted at the inferotemporal aspect of the lower lid aiming in the direction of the orbital apex. The patient was asked to look straight ahead while the globe was balloted towards the superior orbit with the index finger of the non-injecting hand. Once the needle was positioned in the muscle cone near the posterior pole, the solution was slowly injected.

B-mode ultrasound was performed within 30 minutes of the retrobulbar injection. After topical proxymetacaine (proparacaine) was given, a methylcellulose coupling agent was placed on the ultrasound probe, which then was directly applied to the ocular surface. Standard longitudinal, vertical transverse, and axial planes were imaged (Figs 1 and 2).

In 15 of 16 (94%) eyes the steroid was localised to the macular area defined as the portion of the posterior pole bounded by the optic nerve, major temporal arcades, and 3 mm temporal to the fovea. In eyes where the bolus localised to the macular area, the mean distance between the most anterior aspect of



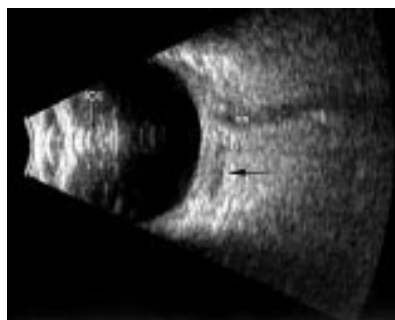


Figure 1 Horizontal axial view. An echolucent area is present (arrow) representing the depot corticosteroid. The macula is located just below the optic nerve in the echogram.

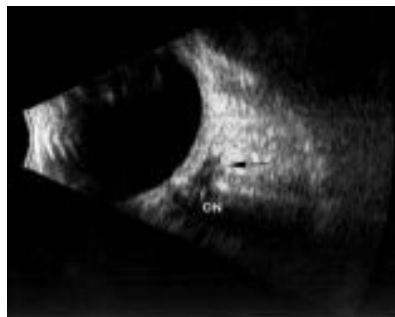


Figure 2 Vertical transverse view. A large lucency (arrow) is present just posterior to the macula.

the bolus and the retina was 2 mm with a range of 1–3 mm. In one eye, the steroid bolus was not visualised by ultrasonography. The injections were well tolerated, and no complications occurred.

#### COMMENT

Depot steroids are an important therapy for treating CMO which is unresponsive to topical therapy. Drug localisation to the macula is considered to be important in maximising therapeutic effect. Steroid therapy delivered by sub-Tenon's and retrobulbar injections is equally effective, and steroids given by sub-Tenon's injection have been localised to the macula previously. The localisation of retrobulbar injections to the macular area may explain the similar efficacy of retrobulbar and sub-Tenon's injection in the treatment of CMO.<sup>1</sup> Retrobulbar injection is a procedure familiar to most ophthalmologists, and the decision to perform either a sub-Tenon's or a retrobulbar injection should take into consideration the degree of comfort the administering physician has with the technique.

Financial support: Heed Fellowship (MJT).

MICHAEL J TOLENTINO  
JONATHAN L PRENNER  
E KYM GENDRON  
ALBERT M MAGUIRE  
Retina Service, Scheie Eye Institute,  
Philadelphia, PA, USA

Correspondence to: Albert M Maguire, MD, Retina Service, Scheie Eye Institute, Myrin Circle, 51 North 39th Street, Philadelphia, PA 19104, USA  
Amaguire@mail.med.upenn.edu

Accepted for publication 15 December 2000

1 Thach AB, Dugel PU, Flindall RJ, *et al.* A comparison of retrobulbar versus sub-Tenon's corticosteroid therapy for cystoid macular edema refractory to topical medications [see comments]. *Ophthalmology* 1997;104:2003–8.

- Freeman W, Green R, Smith R. Echographic localization of corticosteroid after periocular injection. *Am J Ophthalmol* 1987;103:281–8.
- Winder S, Walker SB, Atta HR. Ultrasonic localization of anesthetic fluid in sub-Tenon's, peribulbar, and retrobulbar techniques. *J Cataract Refract Surg* 1999;25:56–9.
- Hyndiuk RA, Reagan MG. Radioactive depot-corticosteroid penetration into monkey ocular tissue. I. Retrobulbar and systemic administration. *Arch Ophthalmol* 1968;80:499–503.

#### Early wound dehiscence with use of hydroxyapatite orbital implant covered with calf pericardium

EDITOR,—Enucleation techniques continue to evolve.<sup>1</sup> While sclera covered hydroxyapatite orbital implants have been quite effective, two major limitations have led us to study other covering materials. One, while there has been no documented human immunodeficiency virus transmission, several patients have expressed concerns about the use of allogeneic sclera because of that issue.<sup>2</sup> Two, in some settings obtaining cadaver donor tissue in a timely manner can be vexing.

Processed calf pericardium has been used in a number of clinical settings as diverse as vascular grafts and neurological surgical patches.<sup>3</sup> Animal ophthalmic data with these materials have shown little untoward effect. While theoretic concerns about prion disease can be raised no evidence of this problem has been reported from over 90 000 human implantations.<sup>4</sup> While this material is a xenograft that is stored in glutaraldehyde, we are unaware of significant ophthalmic reactions on the basis of either parameter.

I performed a phase I-II trial with commercially available calf pericardium in 14 patients who underwent enucleations for large intraocular tumours. I compared the results with 126 previous enucleations in similar patients by the same author with placement of allogeneic scleral wrapped HA implants. When two of these 14 cases developed early, apparently non-infective suture line breakdown (compared with none previously) I stopped the use of this approach.

#### CASE REPORT

In a phase I-II trial 14 eyes of 14 patients, with large intraocular tumours that were not amenable to eye salvage techniques, underwent enucleation. Three patients had large, unilateral retinoblastomas and 11 had uveal melanomas. In the latter group, eight had primary enucleations and three had their eye removed at relatively long intervals after either brachytherapy<sup>2</sup> or proton radiation.<sup>1</sup> The mean age was 49 years old with a range of 1.3–81 years.

Enucleations were performed in a standard manner, as described elsewhere, using double armed 5-0 polyglycolic and polylactic acids (Vicryl) sutures to imbricate each of the recti muscles.<sup>1</sup> An 18–22 mm HA implant was soaked in a combination of antibiotic-bupivacaine (Marcaine) solution for 5 minutes then covered with a preshaped Oculoguard calf pericardium (Bio-vascular, Inc, St Paul, MN, USA). The open end of the preformed, bag-shaped material was placed posteriorly and was partially closed with interrupted 4-0 polyglycolic and polylactic acids (Vicryl) sutures. A scalpel was used to create four windows, each approximately 3 × 5 mm located at the equator. After haemostasis was achieved the recti muscles were each attached to the anterior edge of their respective 3 × 5 mm window. Tenon's layer was then closed

with a running 4-0 polyglycolic and polylactic acids (Vicryl) circle suture, and overlying interpreted 4-0 polyglycolic and polylactic acids (Vicryl) sutures. The conjunctiva was closed with a running 6-0 plain gut. The retrospective control group was operated on in an identical manner except alcohol preserved allogeneic sclera was used instead of calf pericardium.

Patients who received calf pericardium covered implants have been followed for 7–20 months following surgery. None of the sockets has been drilled for placement of an integrated implant. In two adults we noted breakdown and retraction of the anterior suture line within 1 month of surgery. In neither of the two cases in which breakdown of the suture line in the first month postoperatively was there ocular radiation, pre-existing conditions, or untoward events noted at surgery. In both cases cultures were negative. In the first case, since I had never had this complication in the first month after an enucleation, I assumed that the suture material had broken and took the patient back to the operating room to close the defect. A culture was negative, and I easily resutured the conjunctival edges, but it again broke down 1 week later. In that patient and the second case that presented with a slightly larger defect 2 weeks after enucleation, we removed the anterior face of the calf pericardium that covered the HA implant, and the overlying conjunctival defect was closed with a dermal graft. The first patient has done well. The second case had recurrent breakdown anteriorly so that we removed the implant. No pathogenic organisms were seen.

In the historic control group (126 cases), who had scleral covered HA implants, I had no cases with this type of complication in the first 6 months after surgery.

#### COMMENT

A large variation in the incidence of post-enucleation complications have been reported.<sup>5</sup> Using the technique outlined above, I have not had an early (<6 months) wound dehiscence or anterior surface breakdown. It is uncertain why we have developed this complication in 14% of cases operated on with bovine pericardium. It is likely that either these patients had a reaction to the xenograft or to the preservative material (although the pericardium is carefully washed in balanced saline solution, bupivacaine (Marcaine) and antibiotics before insertion). In some clinical investigations a higher incidence of early complications with scleral covered hydroxyapatite implants has been reported; these series report wound dehiscence between 5–30%.<sup>5</sup> While that higher incidence has been noted by others, it has not been my experience with a surgical technique that has been basically unchanged for several years.

The mechanism responsible for this early wound dehiscence is uncertain. In an animal study that compared bovine pericardium with homologous sclera there was significantly greater inflammation with the former material; all rabbits that received bovine pericardium wrapped implants had diffuse inflammation in the outer 20% of the material.<sup>3</sup>

It is unlikely that our patients had a subclinical infection (cultures were negative and histological studies showed no organisms) although we cannot completely rule out that possibility.

While there are a number of theoretical advantages with the use of calf pericardium instead of allogeneic sclera, the 14% incidence

of a significant complication has truncated my experience with this material.

Supported in part by a grant from the Tumori Foundation.

DEVRON H CHAR  
The Tumori Eye Foundation, 45 Castro Street,  
Suite 309, San Francisco, CA 94114, USA  
devron@tumori.org

Accepted for publication 14 December 2000

- 1 Char DH. *Ophthalmic oncology*. Toronto: BC Decker, 2000:461–90.
- 2 Beaver HA, Patrinely JR, Holds JB, et al. Periocular autografts in socket reconstruction. *Ophthalmology* 1996;103:495–502.
- 3 DeBacker CM, Dutton JJ, Proia AD, et al. Bovine pericardium versus homologous sclera as wrapping materials for hydroxyapatite ocular implants: an animal study. *Ophthalmic Plast Reconstruct Surg* 1999;15:312–16.
- 4 Holt TA, Phillips J. Bovine spongiform encephalopathy. *BMJ* 1988;296:1581–2.
- 5 Moshfeghi DM, Moshfeghi AA, Finger PT. Enucleation. *Surv Ophthalmol* 2000;44:277–301.

### Wegener's granulomatosis as a cause of cicatrising conjunctivitis

EDITOR.—Wegener's granulomatosis is a multisystem disorder characterised by the classic triad of necrotising granulomas in the upper respiratory tract and the lung, a variable degree of systemic small vessel vasculitis, and a focal necrotising glomerulonephritis.<sup>1</sup> A limited form of Wegener's granulomatosis, with absence of glomerulonephritis, has been described.<sup>2</sup>

Ophthalmic complications occur in about 30% of patients with biopsy proved disease.<sup>3</sup> Among these orbital pseudotumours ulcerations of the sclera and the cornea are observed most frequently and the histopathological findings have been described.<sup>3</sup> Involvement of the conjunctiva and eyelids has also been observed,<sup>4</sup> but progressive scarring of the conjunctiva and its sequelae has not been reported.

#### CASE REPORT

A 72 year old man was first seen at our department in November 1997 with bilateral conjunctivitis. His medical history had been unrevealing until early 1987, when he developed systemic illness with upper respiratory complaints and renal insufficiency. Wegener's granulomatosis was diagnosed by biopsy of the nasal mucosa and kidney. In 1993 he developed necrotising anterior scleritis and peripheral corneal melting in the left eye. There was complete remission on systemic immunosuppressive therapy.

Since January 1997 the patient has suffered from recurrent bilateral conjunctivitis. He complained about persistent epiphora in the left eye and irritation in both eyes. He was then on local treatment with fusidic acid gel and prednisolone 1% eye drops for 2 weeks. On examination lid margin disease with obstruction of the meibomian glands and obliteration of the left canaliculi was noted. The left upper lid showed inflammatory thickening with haemorrhagic and mild cicatricial changes of the tarsal conjunctiva (Fig 1A). In the right eye similar changes were noted; they were, however, much less prominent. Bulbar conjunctiva was unremarkable and there were no other signs of active inflammation in the globe. As there was at that time no evidence of systemically active Wegener's granulomatosis and as cANCA levels were near normal, systemic immunosuppressive treatment was not started again and therapy was restricted to

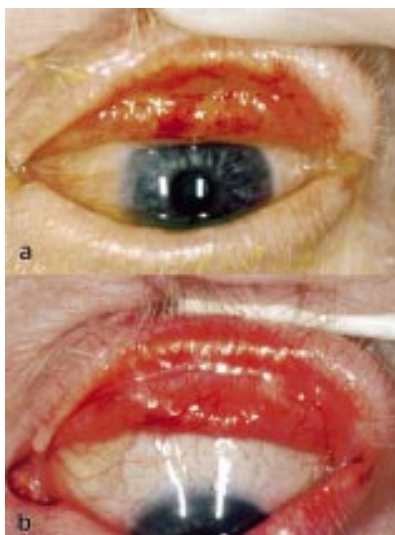


Figure 1 (a) Active granulomatous, haemorrhagic inflammation of the left upper tarsus in 1997. (b) Same area 2 years later. Note advanced scarring of the left upper tarsus causing entropion and trichiasis.

the usual blepharitis regimen (oral tetracycline, lubricating agents, local antibiotics, and steroids).

The patient was referred again in March 1999 after he had suffered several episodes of superficial corneal ulceration in the left eye. On examination the left upper lid was less inflamed than 2 years earlier, but progressive scarring of the tarsus with cicatricial entropion and trichiasis had occurred (Fig 1B). The right upper eyelid showed marked inflammatory thickening, clinically imposing as multiple chalazia. A biopsy from the lateral right upper tarsus disclosed a chronic infiltration with lymphocytes, plasma cells, and occasional histiocytes. Numerous eosinophils but no giant cells were noted. Perivascular inflammation (Fig 2) and areas of active necrosis were only seen in few areas while disorganisation of the tarsus by fibrous tissue was obvious. Together with the analysis of extraocular tissue and the clinical background, the conjunctival biopsy was regarded as diagnostic.

#### COMMENT

The current state of knowledge has not recognised Wegener's granulomatosis as a disorder causing cicatrising conjunctivitis.<sup>5</sup> The diagnosis of granulomatous conjunctivitis in Wegener's granulomatosis can easily be established in the presence of a history of systemic disease. Conjunctival and eyelid findings, however, may be the presenting symptoms<sup>4</sup>

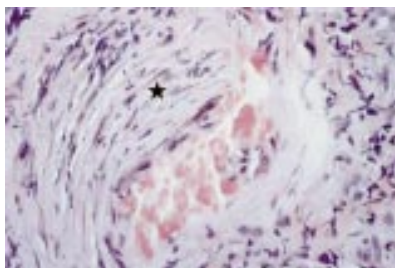


Figure 2 Asterisk indicates fibrous hyperplasia in the wall of a small artery as consequence of vasculitis (haematoxylin and eosin,  $\times 40$ ).

and correct diagnosis is difficult. cANCA levels, a chest x ray film, and an urinary sediment may be helpful in such situations.

Owing to the small number of cases, the experience in treating conjunctival Wegener's disease is limited. In the absence of detectable cANCA levels or extraocular disease activity, we did initially not recommend systemic treatment with steroids and/or immunosuppressive agents. Considering the progressive course with severe lid complications this approach has to be redefined. Further reports will help in this decision.

FABIO M MEIER  
ELMAR P MESSMER  
WOLFGANG BERNAUER  
Department of Ophthalmology, University Hospital  
Zurich, 8091 Zurich, Switzerland

Correspondence to: Wolfgang Bernauer, MD, OMMA Eye Center, Theaterstrasse 2, 8001 Zurich, Switzerland

Accepted for publication 15 November 2000

- 1 Fauci AS, Wolff SM. Wegener's granulomatosis: studies in eighteen patients and review of the literature. *Medicine (Baltimore)* 1973;52:535–61.
- 2 Carrington CB, Liebow AA. Limited forms of angitis and granulomatosis of Wegener's type. *Am J Med* 1966;41:497–527.
- 3 Bullen CL, Liesegang TJ, McDonald TJ, et al. Ocular complications of Wegener's granulomatosis. *Ophthalmology* 1983;90:279–90.
- 4 Jordan DR, Addison DJ. Wegener's granulomatosis. Eyelid and conjunctival manifestations as the presenting feature in two individuals. *Ophthalmology* 1994;101:602–7.
- 5 Bernauer W, Dart JKG, Elder MJ, eds. Cicatrising conjunctivitis. *Developments in Ophthalmology*. Vol 28. Basle: Karger, 1997.

### An unusual presentation of diabetic neuropathy

EDITOR.—Diabetic neuropathy can present in numerous forms; as symmetrical sensory polyneuropathy, mononeuropathy, or as an autonomic neuropathy. The earliest functional change in diabetic nerves is delayed conduction velocity, the earliest histological change is segmental demyelination due to damage of Schwann cells. We report an uncommon but important presentation, which can easily be overlooked on clinical examination.

#### CASE REPORT

A 27 year old woman was referred to Moorfields Eye Hospital complaining of bilaterally red and irritable eyes accompanied by a gradual reduction in vision over the previous 18 months. This had not responded to a wide range of different topical medications. She had been an insulin dependent diabetic since the age of 11. History of control of her diabetes was good, on a regimen of subcutaneous Monotard and Actrapid. She had no other significant medical history.

On examination she was noted to have bilateral corneal erosions. She had a reduced blink rate and peripheral corneal thinning. Her visual acuity was recorded at 6/60 right, 6/24 left unaided. It was also noted that she had complete corneal anaesthesia in both eyes. Basic neurological examination was otherwise normal.

The patient had the typical appearances of a neurotrophic epithelium. She was started on hypromellose 1% eye drops and chloramphenicol 1% eye drops four times daily, both preservative free to stabilise her epithelium, and this improved her symptoms and vision. Further progress was obtained with therapeutic contact lenses, and her visual acuity improved to 6/18 in both eyes. Because of her



corneal anaesthesia she was referred for full neurological investigation.

Autonomic function tests were performed which revealed postural hypotension, blunted pressor tests, and a blocked valsalva test. There was much reduced heart rate variability and responses for her age were thought to be consistent with sympathetic and parasympathetic impairment. Her EMG and nerve conduction studies showed a mild sensory motor neuropathy. A sural nerve biopsy was offered but refused by the patient.

She is currently well maintained with scleral contact lenses and no other symptomatic manifestations of diabetic neuropathy.

#### COMMENT

Corneal anaesthesia can be physiological or pathological. Corneal sensation decreases with age, and is lower in females, especially premenstrually. Contact lens wear, and infection by herpes zoster and simplex, oedema and surgery will also reduce sensation. Congenital causes of corneal anaesthesia include corneal dystrophy and Riley-Day syndrome, and congenital corneal anaesthesia without an associated syndrome, which is presumed to be due to hypoplasia of the ophthalmic division of the trigeminal nerve. Systemic disease such as diabetes, myotonic dystrophy, scleroderma, and vitamin deficiencies are important causes of corneal anaesthesia, which can often be overlooked. Forty five per cent of diabetic patients had a degree of corneal hypoaesthesia when examined in a study of 130 patients published by Osman *et al.*<sup>1</sup> There is little or no relation between the age of a diabetic patient and the observed decrease in corneal sensitivity. However, corneal sensitivity thresholds do rise with increased duration of diabetes.<sup>2</sup>

It has been suggested that diabetic peripheral neuropathy was due to occlusive vascular disease and nerve infarctions.<sup>3</sup> More recent evidence suggests that common symmetrical distal polyneuropathy is due to segmental demyelination with associated or secondary axonal degeneration.<sup>4</sup>

Recent studies show that there may be a potential to use topical neurotrophic growth factors as a treatment for neurotrophic corneal ulceration.<sup>5</sup> In a study of 14 eyes Lambiase *et al* treated neurotrophic corneal ulcers with topical nerve growth factor for 2 weeks. Corneal healing began within 2–14 days and all patients had complete healing of their ulcers after 10 days to 6 weeks.

Corneal anaesthesia may often be overlooked unless it is profound. It can be tested with cotton wisps or an anaesthesiometer. It is important to test the corneal sensation subjectively and objectively and also to test all four quadrants of the cornea.

This case raises three important points:

- Chronically red irritable eyes should have their corneal sensation tested. Corneal anaesthesia is easily overlooked by non-ophthalmologists and ophthalmologists alike, and the anaesthetic cornea represents a real risk of profound visual loss from trauma and infection.
- Reduced corneal sensation can be a presenting feature of diabetic neuropathy. This woman had no other symptoms or signs of neuropathy apart from her corneal anaesthesia. If a diabetic develops a red or irritable eye, corneal sensation should be tested.
- There is some promise for the future in that neurotrophic corneal ulceration may potentially be treated by the use of topical neurotrophic growth factors.<sup>5</sup> The research

into this project continues and is currently not in clinical practice.

C S DANIEL  
S G FRASER  
J K G DART  
Moorfields Eye Hospital, City Road,  
London EC1V 2PD, UK

Correspondence to: Miss Claire Daniel  
Accepted for publication 15 January 2001

- 1 Ben Osman N, Jeddi A, Sedai L, *et al*. La cornee du diabetique. *J Fr Ophthalmol* 1995;18:120–3.
- 2 Schwartz DE. Corneal sensitivity in diabetics. *Arch Ophthalmol* 1974;91:174–8.
- 3 Fagerberg SE. Studies on the pathogenesis of diabetic neuropathy: III. Diabetic neuropathy in relation to diabetic vessel complications. *Acta Med Scand* 1957;157:401–6.
- 4 Thomas PK, Lascelles RG. The pathology of diabetic neuropathy. *Q J Med* 1966;35:489–509.
- 5 Lambiase A, Rama P, Bonini S, *et al*. Topical treatment with nerve growth factor for corneal neurotrophic ulcers. *N Engl J Med* 1998;338:1174–80.

#### Bilateral acute retinal necrosis and herpes simplex type 2 encephalitis in a neonate

EDITOR,—Acute retinal necrosis (ARN) is a rapidly progressing, sometimes devastating, retinitis associated with the herpes virus family. First described in 1971,<sup>1</sup> it is diagnosed by the clinical triad of progressive peripheral retinal necrosis, occlusive vasculopathy, and vitreous inflammation.<sup>2</sup> The association of herpetic encephalitis with ARN has been described in adults.<sup>3–4</sup> Herpes simplex virus type 2 (HSV-2) has also been recognised as one of the causative agents of the ARN syndrome, particularly in Japan.<sup>5</sup> It has been suggested that ARN in patients less than 25 years of age is likely to be caused by HSV-2.<sup>6</sup> We present a case of bilateral ARN (BARN) in a neonate with HSV-2 encephalitis.

#### CASE REPORT

A 25 day old infant presented with a 4 day history of lethargy, poor feeding, and coughing. Examination revealed an injected, blistered pharynx and a solitary red skin lesion on the left upper arm accompanied by a cluster of blisters. A clinical diagnosis of possible viral encephalitis was made, and intravenous aciclovir and cefotaxime were commenced. Computed tomography of the brain showed an area of necrosis in the right thalamus. A scrape from the skin lesion and a sample of cerebrospinal fluid (CSF), obtained by lumbar puncture, were sent for polymerase chain reaction (PCR) analysis. Both specimens were positive for HSV-2. HSV-2 was also isolated in tissue culture from a throat swab. Two days later a bilateral retinitis affecting the superior retina in the right eye and the superonasal retina in the left was identified. A small area of retinal detachment subsequently developed outside the vascular arcades superiorly in the right eye. While in the left eye, an extensive superior retinal detachment occurred, threatening the macula; in the right eye indirect argon laser photocoagulation was used to demarcate the interface between necrotic and healthy retina (Fig 1). In the left, laser was not applied because of the proximity of subretinal fluid to the macula. After 4 days the retinitis was inactive in both eyes; however, a week later the right retina became necrotic posterior to the original laser treatment and further indirect laser was applied. In the left eye massive subretinal haemorrhage involving the macula developed and the child underwent

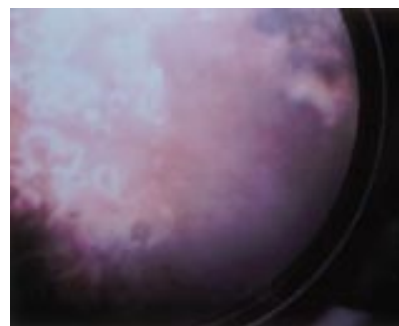


Figure 1 Photograph showing where indirect argon laser photocoagulation was used to demarcate the interface between necrotic and healthy retina.

left pars plana vitrectomy, vitreous and retinal biopsy, posterior hyaloid peel, endolaser, air/fluid exchange, and silicone oil tamponade. Analysis of the vitreous sample revealed a non-diagnostic band on PCR. Histology, including electron microscopy, of the retinal biopsy showed only necrotic tissue.

The fundal appearance stabilised and oral aciclovir was commenced which has been maintained to date. A maternal blood sample taken during the second trimester of pregnancy was retrospectively analysed and found to be negative for HSV-2. A sample obtained 2 months post partum was positive for HSV-2.

#### COMMENT

Neonatal HSV infection is usually symptomatic and has a high mortality. Three quarters of cases are due to HSV-2 and this is most commonly acquired from the maternal genital tract lesion during delivery.<sup>7</sup> The maternal HSV titres in this case suggest that the mother acquired a primary infection during the third trimester. A diagnosis of encephalitis was confirmed by the CT scan appearance and a PCR positive for HVS-2 in the CSF. The retinitis was first observed only 6 days after the onset of the systemic symptoms and progressed significantly despite intravenous administration of aciclovir. This treatment was continued for several weeks and was then followed by oral therapy. The fact that HSV was not identified from the vitreous or retinal biopsy may be attributable to the prolonged antiviral treatment.<sup>8</sup>

HSV encephalitis is a severe infection, especially in the neonate, that carries a potential risk of significant ocular involvement. This case highlights the importance of early diagnosis and active management. Like ARN in adults, this may include the need for prophylactic laser retinal photocoagulation to prevent retinal detachment<sup>9</sup> and, should this fail, pars plana vitrectomy with silicone oil tamponade.<sup>10</sup>

ANDRÉS KYCHENTHAL  
Moorfields Eye Hospital, London, UK

ANDREW COOMBES  
JOHN GREENWOOD  
St George's Hospital, Department of Ophthalmology,  
London, UK

CARLOS PAVESIO  
GEORGE W AYLWARD  
Moorfields Eye Hospital, London, UK

Correspondence to: George W Aylward, Vitreo-retinal Service, Moorfields Eye Hospital, London EC1V 2PD, UK

Accepted for publication 8 January 2001

- 1 Urayama A, Yamada N, Sasaki T, *et al*. Unilateral acute uveitis with periarteritis and detachment. *Jpn J Clin Ophthalmol* 1971;25:607–19.

- Holland GN. Standard diagnostic criteria for the acute retinal necrosis syndrome. Executive Committee of the American Uveitis Society. *Am J Ophthalmol* 1994;117:663-7.
- Ahmadi H, Sajjadi SH, Azarmina M, et al. Association of herpetic encephalitis with acute retinal necrosis syndrome. *Ann Ophthalmol* 1991;23:215-9.
- Pavésio CE, Conrad DK, McCluskey PJ, et al. Delayed acute retinal necrosis after herpetic encephalitis. *Br J Ophthalmol* 1997;81:415-16.
- Itoh N, Matsumura N, Olgi A, et al. High prevalence of herpes simplex virus type 2 in acute retinal necrosis syndrome associated with herpes simplex virus in Japan. *Am J Ophthalmol* 2000;129:404-5.
- Ganatra JB, Chandler D, Kuppermann B, et al. Viral causes of the acute retinal necrosis syndrome. *Am J Ophthalmol* 2000;129:166-72.
- The newborn. In: *Forfar and Arneil's textbook of pediatrics*. 5th ed. Edinburgh: Churchill Livingstone, 1998:287.
- Knox CM, Chandler D, Short GA, et al. Polymerase chain reaction-based assays of vitreous samples for the diagnosis of viral retinitis. Use in diagnostic dilemmas. *Ophthalmology* 1998;105:37-44.
- Han DP, Lewis H, Williams GA, et al. Laser photocoagulation in the acute retinal necrosis syndrome. *Arch Ophthalmol* 1987;105:1051-4.
- Stoffels B, Pfeiffer N. Acute retinal necrosis: silicone oil tamponade in retinal detachment. *Ophthalmologie* 1997;94:568-72.

### Surgical excision, autolimbial transplantation, and mitomycin C in the treatment of conjunctival and corneal intraepithelial neoplasia

EDITOR.—Conjunctival and corneal intraepithelial neoplasia (CIN) are uncommon lesions of low malignant potential.<sup>1</sup> Surgical excision is the standard treatment for this condition. However, owing to the poorly defined borders of these lesions, recurrence rates following surgical excision can be as high as 53%.<sup>2</sup> Adjunctive therapy including cryotherapy,<sup>3</sup> radiotherapy,<sup>4</sup> immunotherapy,<sup>5</sup> and topical alcohol and urea have been used to treat the condition. Many of these procedures induce limbal stem cell failure with consequent corneal epithelial problems, requiring (auto) stem cell transplantation. Topical cytotoxic agents like 5-fluorouracil and mitomycin C

have been used successfully in the treatment of CIN.<sup>6</sup> However, inhibition of limbal stem cell division with mitomycin C is thought to notably impair physiological corneal epithelial replacement.<sup>7</sup> We report the successful use of prolonged mitomycin C after autolimbial transplantation in the treatment of recurrent CIN.

#### CASE REPORT

A 37 year old white woman presented in February 1995 with a 6 month history of a fleshy white lesion in the corner of her right eye. In the past she had experienced intermittent episodes of bilateral sore, red eyes. Her visual acuities were 6/18 with pinhole in the right eye and 6/5 in the left eye. Ocular examination revealed a whitish elevated lesion on the right limbal conjunctiva from 7 to 11 o'clock extending almost to the central cornea (Fig 1A).

The patient underwent excision biopsy of the lesion. Intraoperatively the exposed bed of the lesion was treated with absolute alcohol and the conjunctival edge with two cycles of cryotherapy. Postoperatively, a bandage contact lens was inserted and she was treated with topical preservative-free antibiotics and steroids. One month later the corneal and conjunctival epithelium had healed completely and vision improved to 6/12. Histology confirmed the lesion to be conjunctival and corneal intraepithelial neoplasia (Fig 1B).

Two months postoperatively, she developed a recurrence in the form of two central, abnormal areas of corneal epithelium. These were treated by scraping and application of absolute alcohol to the bed of the lesion. Histology identified these lesions to be severely dysplastic corneal epithelial cells. Subsequently she developed right limbal stem cell failure resulting in recurrent episodes of filamentary and punctate keratitis and a reduction of visual acuity to 6/18. Histology of corneal scrapes showed epithelial cells and goblet cells. In

February 1998 she underwent a right autologous limbal transplant and vision improved to 6/9.

Two months later she had a recurrence of CIN involving one third of the cornea (Fig 1C). This was treated with four cycles of 0.04% mitomycin C applied four times a day, for 10 days at a time. The tumour regressed completely in 3 months. Twenty months later she remains asymptomatic with a clear cornea (Fig 1D).

#### COMMENT

Mitomycin C is a cytotoxic alkylating agent which inhibits DNA synthesis and is, therefore, most effective against rapidly dividing cells. While it has been used to treat recurrences of CIN, there have been concerns about the effects of mitomycin C on the limbal stem cells and the integrity of the corneal epithelium.<sup>7</sup> In our patient the grafted limbal stem cells and corneal epithelium remained healthy in spite of the significant dose of mitomycin C required to treat her recurrent CIN. To the best of our knowledge this is the first reported case of topical mitomycin C used successfully against CIN after autolimbial transplant, despite the prolonged duration of application (40 days).

The authors would like to thank Miss April Powell-Richards and Professor J Lowe for their help with the illustrations.

ANNIE JOSEPH  
KOURESH SABRI  
HARMINDER S DUA

Department of Ophthalmology, University Hospital,  
Queen's Medical Centre, Nottingham NG7 2UH, UK

Correspondence to: Professor H S Dua, Department of Ophthalmology, B Floor, Eye, Ear, Nose and Throat Centre, University Hospital, Nottingham NG7 2UH, UK

harminder.dua@nottingham.ac.uk

Accepted for publication 24 January 2001

- Arffa RC. Conjunctival and corneal tumours. In: Craven L, Cox KJ, Loonstyn SM, eds. *Grayson's diseases of the cornea*. 4th ed. St Louis: Mosby-Year Book, 1997:717-22.
- Erie J, Campbell R, Liesegang T. Conjunctival and corneal intraepithelial and invasive neoplasia. *Ophthalmology* 1986;93:176-83.
- Peksayer G, Soyurk M, Demiryont M. Long term results of cryotherapy on malignant epithelial tumours of the conjunctiva. *Am J Ophthalmol* 1989;107:337-40.
- Cezero L, Otero J, Aragon G, et al. Conjunctival intraepithelial neoplasia and invasive squamous cell carcinoma treated with strontium-90. *Radiation Oncol* 1990;17:191-7.
- Vann R, Karp C. Perilesional and topical interferon alfa for conjunctival and corneal epithelial neoplasia. *Ophthalmology* 1999;106:91-7.
- Wilson W, Hungerford J, George S, et al. Topical mitomycin C for the treatment of conjunctival and corneal epithelial dysplasia and neoplasia. *Am J Ophthalmol* 1997;124:303-11.
- Heigle T, Doyle Stulting R, et al. Treatment of recurrent conjunctival epithelial neoplasia with topical mitomycin C. *Am J Ophthalmol* 1997;124:397-9.

### Bilateral granulomatous uveitis in association with common variable immunodeficiency

EDITOR.—We report a case of bilateral granulomatous uveitis, which prompted extensive diagnostic review in a 20 year old woman with a long history of recurrent infection and idiopathic thrombocytopenia. Investigations allowed the definitive diagnosis of common variable immunodeficiency with granulomas (granulomatous antibody deficiency syndrome.) To our knowledge this is the first reported case of granulomatous uveitis in

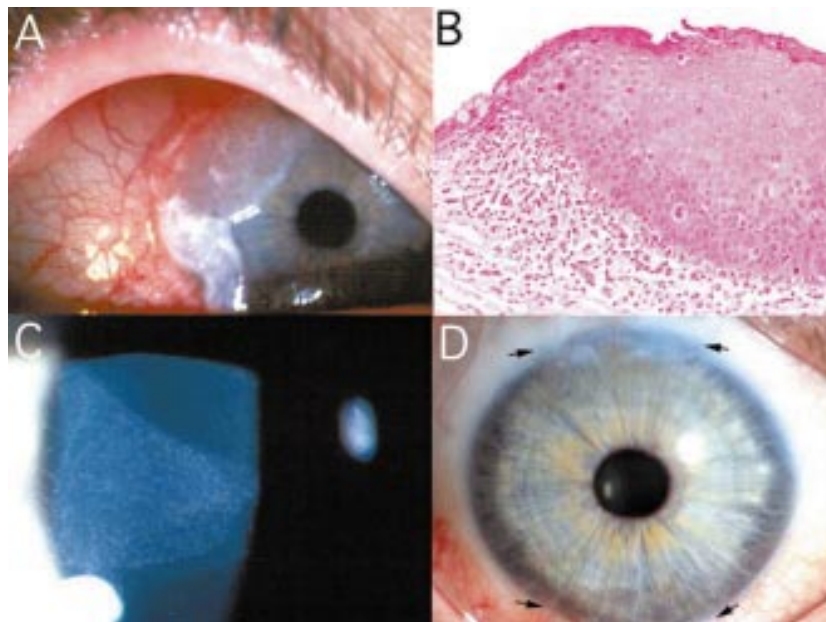


Figure 1 (A) Pretreatment view of right eye showing conjunctival/corneal intraepithelial neoplasia (CIN). (B) Photomicrograph of the initial biopsy specimen showing the features of CIN (stain haematoxylin and eosin; original magnification,  $\times 100$ ). (C) Recurrence of CIN after autologous limbal transplantation. (D) The lesion has not recurred 20 months after mitomycin C therapy. Arrows show the two areas of autologous limbal transplantation.



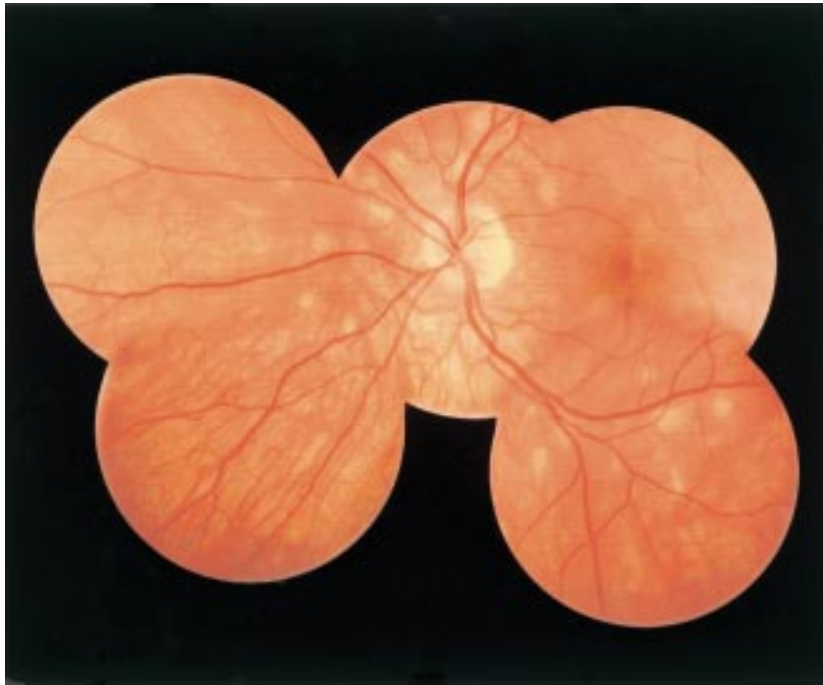


Figure 1 Composite fundal photograph showing optic disc swelling and multifocal areas of choroidal pallor, representing granulomas.

association with granulomatous antibody deficiency (GAD). We discuss the features of GAD, and how it may be distinguished from sarcoidosis.

#### CASE REPORT

A 20 year old woman presented with sudden onset blurred vision. Examination revealed a bilateral granulomatous uveitis with mutton-fat keratic precipitates and anterior chamber cells. Two weeks later she developed bilateral optic disc swelling with multifocal areas of choroidal pallor in her left eye (Fig 1). There was no vitritis or evidence of retinal vascular changes. Her uveitis settled on topical steroids and she maintained vision of 6/6 in the right eye and 6/9 in the left. The working diagnosis was sarcoidosis.

However, serum angiotensin converting enzyme (ACE) was not elevated and magnetic resonance imaging (MRI) showed no evidence of neurosarcoid. Plain chest films and high resolution computed tomography of the thorax revealed bilateral hilar and paratracheal lymphadenopathy, with air space shadowing and ill defined nodular opacities in both lower zones. Bronchial biopsies, obtained at fibre-optic bronchoscopy, showed inflammation of the bronchial epithelium consistent with bronchial pneumonia. No granulomata were seen.

As a child she had suffered from recurrent chest infections, with severe neutropenia and thrombocytopenia. By 6 years of age she had developed splenomegaly and widespread lymph node enlargement. Kveim and Mantoux test were both negative. Investigations for lymphoma over several years were negative. At 13 she underwent splenectomy for idiopathic thrombocytopenia. No definitive diagnosis was established for her in childhood.

She suffered an episode of parotitis and then, at 18, infective discitis of the lumbar spine requiring intravenous antibiotics. This precipitated a drug induced hepatitis with ascites, which became infected, resulting in a chronic, low grade peritonitis. Epstein-Barr

virus, cytomegalovirus, and parvovirus serology was normal. Histological review showed that the spleen had little white pulp and few germinal centres (Fig 2), while lymph nodes showed multiple, small, non-caseating granulomas and few germinal centres (Fig 2). Immunological investigation showed all immunoglobulin levels were reduced, with IgG 0.1 g/l (normal 5.4–16.1 g/l), IgA <0.1 g/l (normal 0.8–2.8 g/l), and IgM 1.0 g/l (normal 0.5–1.9 g/l). Lymphocyte subclasses and bone marrow biopsy were normal.

The diagnosis of common variable immunodeficiency syndrome (CVIS) with granulomas was made. Her exacerbations of idiopathic thrombocytopenia responded to immunoglobulin therapy.

#### COMMENT

CVIS is a primary immunodeficiency characterised by decreased or absent levels of immunoglobulins. Patients suffer from recurrent bacterial infections and respiratory failure is the principal cause of death.<sup>1</sup> Autoimmune disease is seen in approximately 10% of cases, especially thrombocytopenia, haemolytic anaemia, and rheumatoid arthritis; 25% have splenomegaly and approximately one third have non-caseating granulomata in sites such

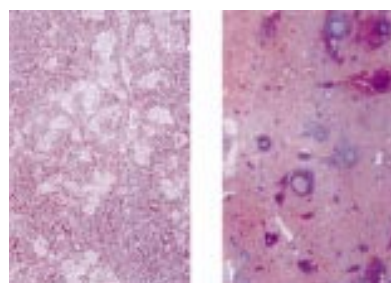


Figure 2 (Left) Lymph node showing multiple, small, non-caseating granulomas (haematoxylin and eosin,  $\times 125$ ). (Right) Spleen showing little white pulp and few germinal centres (haematoxylin and eosin,  $\times 125$ ).

as the liver, lungs, spleen, and lymph nodes.<sup>2</sup> This variant is called granulomatous antibody deficiency (GAD). A sarcoid-like syndrome may be seen in 7.5% of patients.<sup>3</sup>

To our knowledge this is the first reported case of bilateral granulomatous uveitis in association with GAD. As in sarcoidosis, serum ACE may be elevated if the granuloma burden is high<sup>4</sup> and a Kveim test may be positive. The diagnosis of GAD hinges on the presence of hypogammaglobulinaemia, while in sarcoidosis immunoglobulin levels are normal or raised.<sup>5</sup>

Granulomatous uveitis is often an indicator of systemic disease. When there is a history of recurrent infection or of autoimmune disease, immunoglobulin levels should be measured to exclude the possibility of a treatable immunodeficiency.

VICTORIA M L COHEN

Department of Ophthalmology, Royal Hallamshire Hospital, Sheffield S10 2JF, UK

JOHN A LEE

Department of Pathology

WILLIAM EGNER

Department of Clinical Immunology, Northern General Hospital, Sheffield S5 7YT, UK

MOIRA K B WHYTE

Department of Medicine, Royal Hallamshire Hospital, Sheffield S10 2JF, UK

IAN G RENNIE

Department of Ophthalmology, Royal Hallamshire Hospital, Sheffield S10 2JF, UK

Correspondence to: Miss Victoria Cohen, Department of Ophthalmology, Box 41, Addenbrooke's Hospital, Hills Road, Cambridge CB2 2QQ, UK  
victoria-cohen@supanet.com

Accepted for publication 13 December 2000

- 1 Waldmann TA. Immunodeficiency diseases: primary and acquired. In: Samter M, Talmage DW, eds. *Immunological diseases*. 4th ed. Boston: Little, Brown, 1988:411–65.
- 2 Hermaszewski RA, Webster AD. Primary hypogammaglobulinaemia: a survey of clinical manifestations and complications. *Q J Med* 1993;**86**:31–42.
- 3 Asherson GL, Webster AD. *Diagnosis and treatment of immunodeficiency diseases*. Oxford: Blackwell Scientific, 1980:41–60.
- 4 Gilbert S, Steinbrech DS, Landas SK, et al. Amounts of angiotensin-converting enzyme mRNA reflect the burden of granulomas in granulomatous lung disease. *Am Rev Respir Dis* 1993;**148**:483–6.
- 5 Mechanic LJ, Dikman S, Cunningham-Rundles C. Granulomatous disease in common variable immunodeficiency. *Ann Intern Med* 1997;**127**: 613–17.

#### A postoperative complication far worse than endophthalmitis: the coexistence of orbital cellulitis

EDITOR,—The coexistence of endophthalmitis and orbital cellulitis in one individual is often a result of endogenous complications, such as metastatic septicæmia or infiltration from a neighbouring orbital infection.<sup>1–3</sup> However, the coexistence of both these diseases as complications following intraocular or extraocular surgery is very rarely recognised and has only been reported previously in two patients who underwent radial keratotomy and penetrating keratoplasty.<sup>3,4</sup> We report a patient who underwent uncomplicated phacoemulsification surgery under sub-Tenon anaesthesia and presented with an acute endophthalmitis and orbital cellulitis, leading to phthisis bulbi despite a good response to prompt treatment.

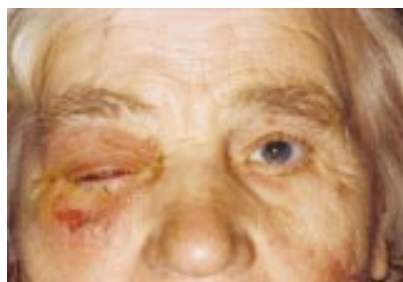

Figure 1 Patient presented with acute endophthalmitis following uncomplicated phacoemulsification surgery of the right eye, and was noted to have coexisting orbital cellulitis.

#### CASE REPORT

A 77 year old woman with high myopia and left aphakia underwent uncomplicated elective phacoemulsification surgery of the right eye under sub-Tenon anaesthesia, without intraocular lens implantation. Postoperative ocular examination was satisfactory but on the second day after surgery, she developed headache, vomiting, and ocular pain, with decreased vision in the operated eye to hand movements.

Examination revealed a proptotic right eye with erythematous lid swelling, purulent discharge, and some restriction in all extraocular movements. There were generalised corneal oedema, severe fibrinous uveitis, and vitritis. Postoperative endophthalmitis with orbital cellulitis was diagnosed (Fig 1). The patient was admitted for emergency aqueous and vitreous biopsy with intravitreal antibiotic injection. Oral prednisolone 40 mg once daily and standard intensive topical antibiotics were commenced and changed accordingly when bacteriology cultures confirmed the growth of *Streptococcus pneumoniae*.

She suffered from bronchial asthma with a productive cough. She was febrile since her second admission, but both sputum and urinary cultures were negative. Diabetes and dacryocystitis were also excluded. Computed tomography (CT) orbital scan had revealed no retrobulbar or orbital abscess. As the isolated pathogen was *Strep pneumoniae*, endogenous spread from her chronic respiratory disease to the eye was still a possibility. Her ocular infections had eventually resolved into phthisis bulbi with no perception of light 2 months after the surgery.

#### COMMENT

The cause of postoperative endophthalmitis is often a result of inoculation of pathogens directly into the ocular cavity during surgery or indirectly into periocular tissues with subsequent access gained via an open wound. However, the precise mechanism leading to orbital cellulitis from endophthalmitis is less clear.

In our patient, sub-Tenon anaesthesia was applied and this could potentially have served as an access for the pathogen into the orbital cavity. One of two reported cases of postoperative endophthalmitis and orbital cellulitis received only topical anaesthesia at the primary procedure<sup>2</sup>; orbital cellulitis developed following vitreous biopsy and intravitreal antibiotic injection, and the type of anaesthesia was not mentioned. Sub-Tenon anaesthesia is an increasingly popular procedure for intraocular surgery, and when performed by the anaesthetist, skin preparation is usually undertaken using Betadine (Seton), but conjunctival lavage with antiseptic is not usually

practised and periocular tissues are not draped. We recommend fastidious preparation of the lids and conjunctiva with 5% povidone iodine before sub-Tenon anaesthesia together with appropriate draping in addition to the standard procedure before intraocular surgery which has been shown to reduce the incidence of postoperative infection.<sup>5</sup>

There is a general assumption that orbital cellulitis is an infective consequence of endophthalmitis, where the orbit was infected with the causative pathogen. On the other hand, orbital cellulitis could simply be an inflammatory response to the severe infection of the globe. The patient we describe presented with coexisting orbital cellulitis and endophthalmitis, probably resulting from simultaneous inoculation of the infecting organism into orbital tissues and the eye from the conjunctiva. This is supported by the findings of peri-orbital soft tissue swelling on the CT scan. In addition, the degree of orbital involvement could simply reflect the virulence of the particular organism.<sup>3</sup> Phthisis bulbi within 2 months of the initial infection was also the result of the reported case of post-radial keratotomy, even though the causative pathogen differed from the present case. As the prognosis of both coexisting diseases is far worse than endophthalmitis or orbital cellulitis alone, early recognition and the initiation of aggressive treatment are vital.

PECK-LIN LIP  
MARIA MOUTSOU  
MARK HERO

Department of Ophthalmology, Coventry and Warwickshire Hospital, Coventry, UK

Correspondence to: P L Lip, The Birmingham and Midland Eye Centre, City Hospital, Dudley Road, Birmingham B15 2LS, UK  
g.y.h.lip@bham.ac.uk

Accepted for publication 31 January 2001

- Hornblat ATK, Coden DJ, Ahn-Lee S. Endogenous orbital cellulitis and endogenous endophthalmitis in subacute bacterial endocarditis. *Am J Ophthalmol* 1989;108:196-7.
- Li S, Perlman JI, Edwaed DP, et al. Unilateral blastomyces dermatitidis endophthalmitis and orbital cellulitis. A case report and literature review. *Ophthalmology* 1998;105:1466-70.
- Pavan PR, Oteiza EE, Hughes BA, et al. Exogenous endophthalmitis initially treated without systemic antibiotics. *Ophthalmology* 1994;101:1289-96.
- McLeod SD, Flowers CW, Lopez PF, et al. Endophthalmitis and orbital cellulitis after radial keratotomy. *Ophthalmology* 1995;102:1902-7.
- Speaker MG, Menikoff JA. Prophylaxis of endophthalmitis with topical povidone-iodine. *Ophthalmology* 1991;98:1769-75.

## NOTICES

#### National prevention of blindness programmes and Vision 2020

The latest issue of *Community Eye Health* (36) discusses national prevention of blindness programmes. For further information please contact *Community Eye Health*, International Centre for Eye Health, Institute of Ophthalmology, 11-43 Bath Street, London EC1V 9EL. (Tel: (+44) (0) 20-7608 6909/6910/6923; fax: (+44) (0) 7250 3207; email: eyesource@ucl.ac.uk) Annual subscription £25. Free to workers in developing countries.

#### Second Sight

Second Sight, a UK based charity whose aims are to eliminate the backlog of cataract blind in India by the year 2020 and to establish strong links between Indian and British ophthalmologists, will be sending volunteer surgeons to India early in 2001. Details can be found at the charity website at [www.second-sight.org.uk](http://www.second-sight.org.uk) or by contacting Dr Lucy Mathen (email address [lucymathen@yahoo.com](mailto:lucymathen@yahoo.com)).

#### 14th Annual Meeting of German Ophthalmic Surgeons

The 14th Annual Meeting of German Ophthalmic Surgeons will be held in the Meistersingerhalle, Nuremberg, Germany on 17-20 May 2001. Further details: MCN Medizinische Congress-organisation Nuremberg AG, Zerzabelhofstrasse 29, 90478 Nuremberg, Germany (tel: ++49-911-3931621; fax: ++49-911-3931620; email: [doerflinger@mcn-nuernberg.de](mailto:doerflinger@mcn-nuernberg.de)).

#### European Association for the Study of Diabetic Eye Complications (EASDEC)

The next meeting of the European Association for the Study of Diabetic Eye Complications (EASDEC) will be held in Paris, France, on 19-20 May 2001. Further details: Colloquium, 12 Rue de la Croix Faubin, 75 557 Paris Cedex 11, France (tel: +33-1-44 64 15 15; fax +33-1-44 64 15 10; email: [s.mundler@colloquium.fr](mailto:s.mundler@colloquium.fr)).

#### 2nd Interdisciplinary Symposium on the Treatment of Autoimmune Disorders 2001

The 2nd Interdisciplinary Symposium on the Treatment of Autoimmune Disorders 2001 will take place on 7-9 June 2001 at the University Hospital, University of Kiel, Kiel, Germany. Further details: Prof Dr Med Michael Sticherling, Department of Dermatology, University of Kiel, Schittenhelmstrasse 7, D-24105 Kiel, Germany (tel: +49-431 597 1512; fax: +49-431 597 1611; email: [msticherling@dermatology.uni-kiel.de](mailto:msticherling@dermatology.uni-kiel.de)).

#### European Intensive Program of Disease and Imaging of the Fundus

The European Intensive Program of Disease and Imaging of the Fundus under the auspices of the European Program Socrates will be held 2-12 July 2001 at the Clinique Ophtalmologique Universitaire, 40 avenue de Verdun, 94010 Créteil, France. Further details: Béatrice Rousseau (tel: (33 1) 45 17 52 22; fax: (33 1) 45 17 52 66).

#### American Institute of Ultrasound in Medicine—Millennium Ultrasound Course Series

A course entitled "Obstetrical and Gynecological Ultrasound" will be held in New York City, NY, on 24-26 August 2001. Further details: Stacey Bessling, Public Relations Coordinator, AIUM, 14750 Sweitzer Lane, Suite 100, Laurel, MD 20707-5906, USA (tel: 301-498-4100; email: [sbessling@aium.org](mailto:sbessling@aium.org)).

#### 14th World Congress of the International Society for Laser Surgery and Medicine

The 14th World Congress of the International Society for Laser Surgery and Medicine is to be held on the 27-30 August 2001 at Sri Ramachandra Medical College and University Hospital, Chennai, India. The American Society of Lasers in Medicine and Surgery has



indicated that it will designate the 14th World Congress of ISLSM as its society's co-sponsoring meeting. A pre-conference course and separate sessions in ophthalmology will be held as a part of this international meeting. Further details: Dr B Krishna Rau, President, 14th World Congress of the International Society for Laser Surgery and Medicine, Department of Surgery, D2 Ward, Sri Ramachandra Medical College and Research Institute, Porur, Chennai - 600 116, India (tel: 91-44-4765856, 4768027-28, 8527776, 8594804; fax: 91-44-8594578, 4767008; email: krishnar@giasmd01.vsnl.net.in and website: www.medindia.net/islsm2001).

### **31st Cambridge Ophthalmological Symposium**

The 31st Cambridge Ophthalmological Symposium will be held 3–5 September 2001 at St John's College Cambridge. The subject is Retinal Detachment. Further details: COS Secretariat, Cambridge Conferences, The Lawn, 33 Church Street, Great Shelford, Cambridge CB2 5EL, UK (tel: 01223 847464; fax: 01223 847465; email: b.ashworth@easynet.co.uk).

### **1st Asia Pacific Forum on Quality Improvement in Health Care**

The 1st Asia Pacific Forum on Quality Improvement in Health Care will be held from 19–21 September 2001 in Sydney, Australia.

Presented by the BMJ Publishing Group (London, UK) and Institute for Healthcare Improvement (Boston, USA), with the support of the Commonwealth Department of Health and Aged Care (Australia), Safety and Quality Council (Australia), NSW Health (Australia) and Ministry of Health (New Zealand). Further details: quality@bma.org.uk; fax +44 (0) 7383 6869.

### **41st St Andrew's Day Festival Symposium on Therapeutics**

The 41st St Andrew's Day Festival Symposium on Therapeutics will be held on 6–7 December 2001 at the Royal College of Physicians of Edinburgh. Further details: Ms Eileen Strawn, Symposium Co-ordinator (tel: 0131 225 7324; fax: 0131 220 4393; email: e.strawn@rcpe.ac.uk; website: www.rcpe.ac.uk).

### **4th International Conference on the Adjuvant Therapy of Malignant Melanoma**

The 4th International Conference on the adjuvant therapy of malignant melanoma will be held at The Royal College of Physicians, London on 15–16 March 2002. Further details: Conference Secretariat, CCI Ltd, 2 Palmerston Court, Palmerston Way,

London SW8 4AJ, UK (tel: + 44 (0) 20 7720 0600; fax: + 44 (0) 20 7720 7177; email: melanoma@confcomm.co.uk; website: www.confcomm.co.uk/Melanoma).

### **XXIXth International Congress of Ophthalmology**

The XXIXth International Congress of Ophthalmology will be held on 21–25 April 2002 in Sydney, Australia. Further details: Congress Secretariat, C/- ICMS Australia Pty Ltd, GPO Box 2609, Sydney, NSW 2001, Australia (tel: +61 2 9241 1478; fax: +61 2 9251 3552; email: ophthal@icmsaust.com.au; website: www.ophthalmology.aust.com).

### **International Society for Behçet's Disease**

The International Society for Behçet's Disease was inaugurated at the 9th International Congress on Behçet's Disease. Professor Shigeaki Ohno represents the ophthalmology division (Department of Ophthalmology and Visual Sciences, Hokkaido University Graduate School of Medicine, Sapporo, Japan: tel: +81-11-716-1161 (ext 5944); fax +81-11-736-0952; email: sohno@med.hokudai.ac.jp). The 10th International Congress on Behçet's Disease will be held in Berlin 27–29 June 2002. Further details: Professor Ch Zouboulis (email: zoubbere@zedat.fu-berlin.de).