

# Deep lamellar keratoplasty with lyophilised tissue in the management of keratoconus

Andrew G A Coombes, James F Kirwan, Chad K Rostron

## Abstract

**Aims**—Data are presented on the use of deep lamellar keratoplasty (DLK) using lyophilised donor corneal tissue, in the management of patients with keratoconus (KC).

**Method**—The results of DLK on 44 eyes (42 patients) are reported. The mean patient age was 29.8 years (range 10–56). Mean follow up was 25 months (range 6–100). In seven patients with mental handicap or severe mental illness, the collection of acuity and refractive data was limited.

**Results**—Perforation of Descemet's membrane (DM) occurred in nine cases (20%). A double anterior chamber formed in five cases, which resolved spontaneously in three patients. Persistent epithelial defects occurred in two cases, one of which necessitated replacement of the graft. The median postoperative uncorrected visual acuity was 6/36. The median corrected postoperative acuity was 6/9. Those with more than 1 year of follow up (n=25) had a significantly better acuity (p=0.015). This group achieved 6/12 or better in 80% (n=20) and 6/6 or better in 40% (n=10). The mean postoperative spherical error was +0.28 (SD 3.49) dioptres (D). The mean refractive cylinder was 3.85 (1.87) D.

**Conclusion**—This detailed retrospective study of DLK for the treatment of patients with KC, with an average follow up of 2 years, highlights the advantages and disadvantages of this technique.

(Br J Ophthalmol 2001;85:788-791)

Keratoconus (KC) is a progressive ectatic stromal dystrophy and one of the commonest indications for corneal grafting.<sup>1,2</sup> The visual results following lamellar corneal grafts, without the removal of all stromal tissue, reportedly deliver poor optical results.<sup>3</sup> Since the visual outcome following penetrating keratoplasty (PK) is often excellent,<sup>4</sup> this technique has become the accepted standard surgical treatment. However, patients suffering from KC are generally young, and significant risks are associated with PK, in particular endothelial failure, graft rejection, and side effects from topical steroids. It has been shown that the optical results of lamellar keratoplasty can be improved by deep lamellar keratoplasty (DLK), where a deep dissection approaching or at the level of DM is achieved.<sup>5-7</sup> DLK has no risk of endothelial rejection and the endothelial cell count is minimally reduced.<sup>8</sup> In 1985, Archila first described the use of air injected into the corneal stroma to facilitate a

deep dissection,<sup>9</sup> and the use of lyophilised tissue in conjunction with DLK was reported by us in 1992.<sup>5</sup> Most previously published DLK case series contain a heterogeneous group of corneal pathologies.<sup>5-7 10 11</sup> We present the detailed data and follow up on a group of KC patients treated with DLK, using air injection and lyophilised donor material.

## Methods

### PATIENTS (SEE TABLE 1)

Fifty patients with KC underwent DLK between January 1991 and March 1999. A retrospective review of case notes revealed that adequate data, with at least 6 months follow up, were available on 44 first graft operations (42 patients).

The primary indication for surgery was contact lens intolerance. If appropriate, patients underwent repeated contact lens fitting before surgery and, where measured, preoperative keratometry was extremely steep (<5.5 mm radius). In seven patients with mental handicap or severe mental illness the collection of acuity and refractive data was limited. Two patients suffered severe allergic or atopic conjunctivitis and one had giant papillary conjunctivitis. Other relevant ocular conditions included one patient with advanced glaucoma and two with cataracts.

### SURGICAL TECHNIQUE

All surgery was performed by a single surgeon (CKR). Although modified during the 8 years of the study, the current technique is as follows: using a 30 gauge needle, air is injected into the corneal stroma, expanding its normal thickness 2–3-fold. The recipient area is marked with a trephine and a vertical incision made with a diamond blade. Hydrodissection, with injection of balanced salt solution into the air expanded central stromal island, is followed by lamellar dissection close to DM. Once the bulk of stroma has been removed, if a pre-DM plane has been defined by the air/hydrodissection, it is filled with viscoelastic through a small puncture. This allows the central posterior stromal fibres to be excised with scissors. If no pre-DM cleavage plane is created, lamellar dissection is performed as deeply as possible without perforation. If perforation occurs, because further lamellar resection is difficult, donor tissue is then applied to the bed.

Table 1 Age and follow up (n=44)

	Age (years)	Follow up (months)	Follow up interval (months)	% (n)
Mean	29.8	25	6–12	32 (14)
SD	9.9	21	12–24	32 (14)
Range	10 to 56	6 to 100	>24	36 (16)

Department of Ophthalmology, St George's Hospital, London, UK  
A G A Coombes  
J F Kirwan  
C K Rostron

Correspondence to:  
Mr C K Rostron,  
Department of Ophthalmology, St George's Hospital, Blackshaw Road, London SW17 0QT, UK  
rostron@sghms.ac.uk

Accepted for publication  
27 February 2001

The rehydrated donor button is sutured in place with interrupted monofilament sutures (11/0 polyester or 10/0 nylon). Finally, the eyelids are closed with a temporary tarsorrhaphy suture, until epithelialisation is complete. In mentally ill or handicapped patients we use either a botulinum toxin ptosis or a bandage contact lens instead. Topical antibiotic ointment is used until epithelialisation, and topical corticosteroid (betamethasone) is tapered over 2–3 months.

#### STATISTICS

Parametric data are presented using mean (SD) values. Non-parametric data are presented with median values. Visual acuity data was analysed by coding and then compared using the Mann-Whitney test.

#### Results

##### VISUAL ACUITIES AND REFRACTIVE OUTCOME (SEE TABLES 2 AND 3)

Those with more than 1 year follow up had a significantly better visual outcome ( $p=0.015$ ). The final corrected visual acuity was independent of DM rupture or the presence of a double anterior chamber immediately after surgery ( $p=0.846$ ). Six patients wore contact lenses after surgery and their median corrected acuity was 6/6. The remainder wore glasses or remained uncorrected.

The mean refractive cylinder of 3.85 (SD 1.87) D ( $n=37$ ), contrasted with the mean keratometric cylinder of 4.65 (2.78)D ( $n=28$ ). In most cases the keratometric values were simulated from topographic maps (Tomey TMS). One patient had required astigmatic keratotomy (AK) and a second underwent laser in situ keratomileusis (LASIK) to correct postoperative ametropia.

#### SURGERY

Lyophilised tissue was supplied by the Keratec Eye Bank at St George's Hospital and, for one patient, Allergan Medical Optics. Host and donor trephine diameters were the same size in all procedures. The average graft diameter was 8.51 (0.43) mm, the majority having 100% stromal thickness. Initially, a small number of

Table 2 Visual acuity (VA) outcome

	All patients ( $n=37$ )	>1 year follow up ( $n=25$ )
Median UCVA	6/36	6/36
Median BCVA	6/9	6/9
% BCVA 6/12 or better	76% ( $n=28$ )	80% ( $n=20$ )
% BCVA 6/9 or better	51% ( $n=19$ )	64% ( $n=16$ )
% BCVA 6/6 or better	27% ( $n=10$ )	40% ( $n=10$ )

UCVA = uncorrected visual acuity, BCVA = best corrected visual acuity.

Table 3 Refractive outcome ( $n=37$ )

	Spherical equivalent	Sphere	Cylinder
Average	-1.65D	+0.28D	-3.85D
SD	3.43D	3.49D	1.87D
Range	-10.25 to +7.00D	-8.50 to +10.00D	0.00 to -8.00D
% $\pm 1$ D	30% ( $n=11$ )	32% ( $n=12$ )	11% ( $n=4$ )
% $\pm 2$ D	49% ( $n=18$ )	57% ( $n=21$ )	22% ( $n=8$ )
% $\pm 3$ D	68% ( $n=25$ )	76% ( $n=28$ )	35% ( $n=13$ )
% >3D	32% ( $n=12$ )	24% ( $n=9$ )	65% ( $n=24$ )

D=dioptr.

Table 4 Intraoperative and postoperative complications ( $n=44$ )

	%
Descemet's membrane rupture	20% ( $n=9$ )
Double anterior chamber	11% ( $n=5$ )
Persistent epithelial defect	5% ( $n=2$ )
Graft rejection	0% ( $n=0$ )
Recurrent uveitis	2% ( $n=1$ )
Permanent mydriasis	2% ( $n=1$ )

donor buttons were prelathed to 75–98% of normal thickness. One patient had DLK accompanying cataract extraction and lens implantation. The mean time to full epithelialisation was 3.8 (1.4) days. Removal of graft sutures was performed at 6–12 months.

#### COMPLICATIONS (SEE TABLE 4)

Of the five patients who developed a double anterior chamber, one had had an episode of resolved hydrops and one did not have an obvious perforation. In two patients, the double anterior chamber did not resolve spontaneously and these were treated with fibrinogen glue (Tisseel) at 6 and 7 weeks respectively after surgery. In the cases excluded from this study owing to lack of follow up, there was one further intraoperative DM rupture that also had suffered a previous hydrops. The presence of previous hydrops was a significant factor in the development of a DM rupture ( $p=0.015$ ; Fisher's exact test).

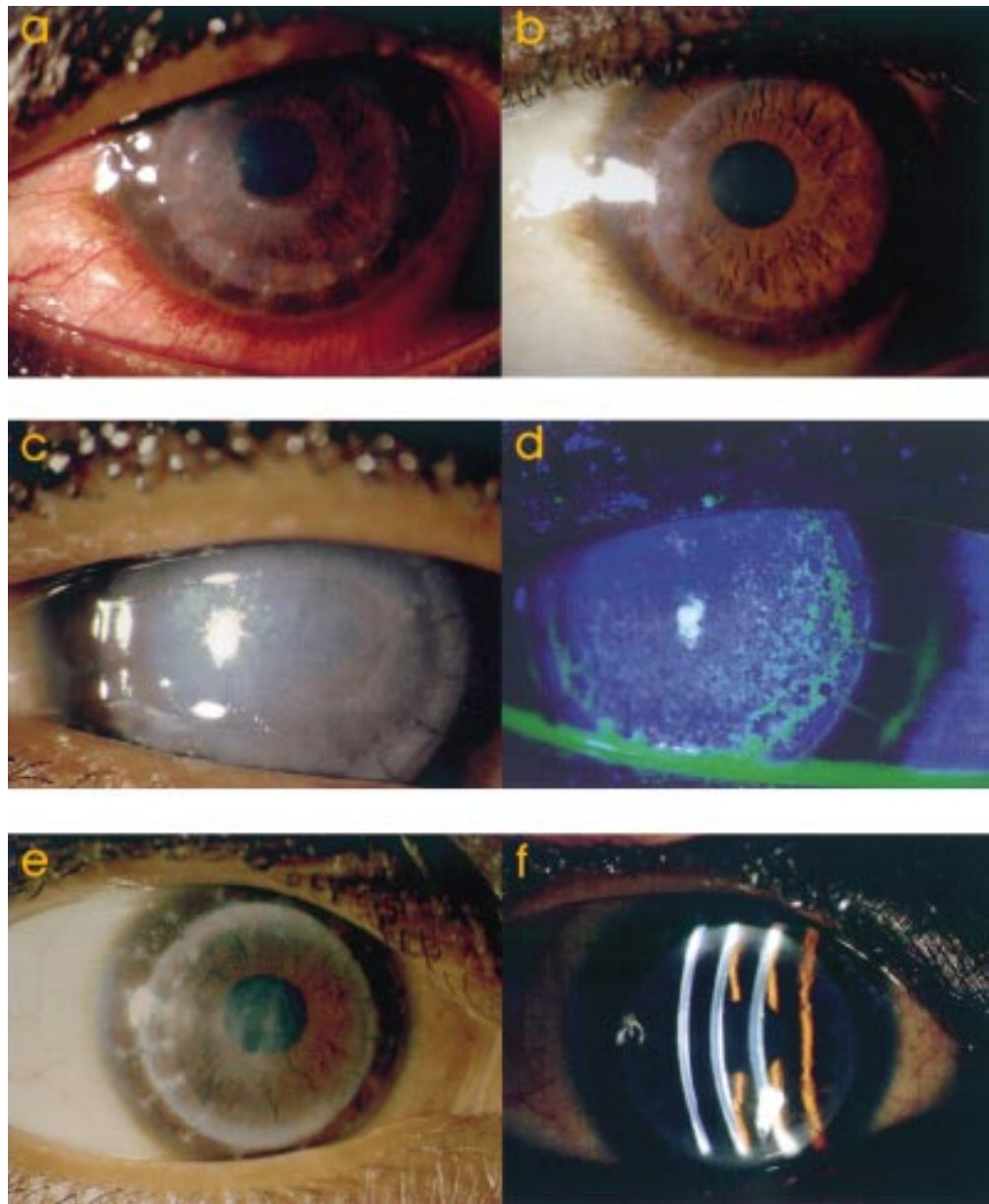
Persistent epithelial defects occurred in two patients, one of which resulted in a corneal melt that necessitated replacement of the graft 60 days after initial surgery. Because of mental illness, neither patient had received a tarsorrhaphy.

#### SECONDARY SURGICAL PROCEDURES

One patient with Down's syndrome, suspected of eye rubbing, required resuturing soon after surgery. Another patient underwent uneventful cataract surgery and lens implantation 7 years after DLK. A further patient, with a poor visual outcome 1 year after DLK, had a successful PK performed by trephining within the lamellar graft.

#### Discussion

The visual acuities in this study are similar to those previously reported following DLK. Our median overall corrected acuity was 6/9, and 76% achieved better or equal to 6/12. The significant improvement in acuity after a year of follow up has been noted in previous studies.<sup>6–7,12</sup> In a study of 113 eyes (none with KC) Sugita and Kondo recorded a mean postoperative corrected acuity of between 6/9 and 6/12, and 62.8% achieved 6/12 or better.<sup>6</sup> A separate study of 24 eyes with KC reported excellent visual results with DLK using fluid injection to achieve deep dissection.<sup>12</sup> The mean follow up in this study, which excluded patients with an intraoperative DM rupture or a previous episode of hydrops, was 13 months. At this stage, all but one patient (95.8%) achieved 6/9 or better and 24% achieved 6/6. In contrast, after 1 year, our group achieved 6/9 or better in 64% of patients, and 40% achieved 6/6.



*Figure 1 (a) At 1 week postoperatively the central area of full thickness stromal resection is outlined by some haze in the residual deep host stroma. (b) At 4 months the graft/host interface is clear. (c and d) This case was complicated by tearing of Descemet's membrane. At 1 week the graft is oedematous with bullous keratopathy and punctate epitheliopathy. (e and f) The same eye at 4 months postoperatively with spontaneous reattachment of Descemet's membrane, and clearing of the graft oedema. Final best corrected acuity was 6/9.*

The mean astigmatism we observed was 3.9D of refractive cylinder and 4.7D of keratometric cylinder. A study of DLK in 17 eyes reported mean keratometric astigmatism of 3.2D with an in situ adjusted running suture.<sup>7</sup> Suture removal usually increases astigmatism<sup>13</sup> and since we had removed the interrupted sutures in most cases, our results appear broadly comparable. Studies addressing post-PK astigmatism demonstrate a variable outcome, possibly dependent on the technique employed.<sup>13, 14</sup> Overall, the level of astigmatism after DLK compares favourably with the best results following PK. One of our patients was treated with LASIK to correct postgraft ametropia. The high intraocular pressure produced by cutting the LASIK flap carries a danger of wound dehiscence. This is of

particular concern following PK, even many years after surgery. In contrast, DLK may present the opportunity for earlier treatment with LASIK. Another advantage of DLK is that it does not suffer rejection, a complication of PK that has been reported following excimer laser treatment.<sup>15</sup>

To reduce myopia following PK for KC, the diameter of host and donor trephine should be the same.<sup>16</sup> We used the same size trephines, although all donor tissue was pre-cut in the eye bank from the epithelial surface, with the donor corneoscleral segment mounted on an artificial anterior chamber. Our postoperative spherical equivalent averaged approximately -2D. The use of lyophilised donor material necessitates the protection of the cornea during epithelialisation, usually with a tarsorrhaphy. This is

underlined by two cases with persistent epithelial defects, one of which suffered a graft melt that required replacement. Where a tarsorrhaphy cannot be performed, a botulinum toxin induced protective ptosis is usually successful in promoting epithelialisation. This takes time to develop and, in the interim, a bandage contact lens may help.

The principal complication during DLK is DM rupture. This occurred in 20% of our series. The rate of this complication in previous reports varies between 0% and 39.2%.<sup>5-6</sup> In our study, no intraoperative DM tear necessitated conversion to a PK. In contrast, the only other study that has focused on DLK in the treatment of KC managed DM perforations by changing to a penetrating technique.<sup>12</sup> We believe it is unnecessary to convert to a PK (Fig 1) and confirmed the finding by Sugita and Kondo that the visual results of patients with or without a DM rupture do not differ significantly.<sup>6</sup> Sugita and Kondo also found that, at 1 year post-surgery, the endothelial cell density was the same irrespective of this complication. In our study, one patient who had suffered an episode of hydrops before surgery, had an intraoperative DM rupture. This is not unexpected since a break in DM, albeit healed, would already exist. Surgery in these cases may be considered as contraindicated and would proceed with the expectation of DM rupture. Five patients developed a double anterior chamber following surgery and in two cases this persisted. These two were treated with fibrinogen glue placed between DM and the donor cornea. The glue slowly absorbed, successfully eliminating the double anterior chamber.

One of the patients from early in our series underwent successful PK 1 year after DLK to improve the visual outcome. Performing the PK within the lamellar graft is simple, since the tissue thickness is likely to be normal compared with peripheral host cornea. As lyophilised tissue may not sensitise the recipient to donor antigens,<sup>17</sup> not only are lyophilised grafts free from rejection, but they should not increase subsequent PK rejection.

Our postoperative topical corticosteroid regimen is of a short duration compared with our post-PK treatment. The higher corticosteroid requirement following PK is an important consideration in patients with glaucoma (one patient in this study). It is also of relevance in the formation of cataract or where there is a history of herpes simplex keratitis. One of our patients had a persistent postoperative mydriasis. This patient had a double anterior chamber that was treated with fibrinogen glue, combined with air injected into the anterior chamber. This may have caused iris sphincter ischaemia and Urrets-Zavalía syndrome.<sup>18</sup> Mydriatic agents have been previously implicated as a cause, and all our patients were treated with cyclopentolate 1% for 1–2 weeks after surgery.

In our study, seven patients had either severe mental illness or handicap. Although relatively successful outcomes have been reported using PK in such patients,<sup>19</sup> DLK offers the advantage of more rapid wound healing. A number

of our patients also suffered atopic or allergic conjunctivitis. Such ocular surface disease increases the risk of PK rejection<sup>20,21</sup> and this highlights a further group of KC patients in whom the use of DLK is advantageous.

## Conclusion

Despite its technical difficulty and time consuming nature, DLK is a promising technique. Importantly, its complications do not necessarily compromise outcome. In patients with KC, the optical results of DLK approach those of PK, but it offers the advantage of no graft rejection, and long term graft survival. There is increasing interest in DLK but debate exists over which graft technique is preferable.<sup>22</sup> This study has shown that the spectrum of risk and benefit differs between DLK and PK. However, with a mean follow up of only 2 years, the long term advantages of the technique remain to be seen.

This work was supported in part by Keratec, registered charity No 803386.

- Vail A, Gore SM, Bradley BA, *et al.* Corneal transplantation in the United Kingdom and Republic of Ireland. *Br J Ophthalmol* 1993;77:650–69.
- Maeno A, Naor J, Lee HM, *et al.* Three decades of corneal transplantation: indications and patient characteristics. *Cornea* 2000;19:7–11.
- Soong HK, Katz DG, Farjo AA, *et al.* Central lamellar keratoplasty for optical indications. *Cornea* 1999;18:249–56.
- Silbiger JS, Cohen EJ, Laibson PR. The rate of visual recovery after penetrating keratoplasty for keratoconus. *CLAO* 1996;22:266–9.
- Chau GK, Dilly SA, Sheard CE, *et al.* Deep lamellar keratoplasty on air with lyophilised tissue. *Br J Ophthalmol* 1992;76:646–50.
- Sugita J, Kondo J. Deep lamellar keratoplasty with complete removal of pathological stroma for vision improvement. *Br J Ophthalmol* 1997;81:184–8.
- Tsubota K, Kaido M, Monden Y, *et al.* A new surgical technique for deep lamellar keratoplasty with single running suture adjustment. *Am J Ophthalmol* 1998;126:1–8.
- Morris E, Kirwan JF, Sujatha S, *et al.* Corneal endothelial specular microscopy following deep lamellar keratoplasty with lyophilised tissue. *Eye* 1998;12:619–22.
- Archila EA. Deep lamellar keratoplasty dissection of host tissue with intrastromal air injection. *Cornea* 1984;5(3):217–18.
- Panda A, Bageshwar LM, Ray M, *et al.* Deep lamellar keratoplasty versus penetrating keratoplasty for corneal lesions. *Cornea* 1999;18:172–5.
- Price FW. Air lamellar keratoplasty. *Refract Corneal Surg* 1989;5:240–3.
- Amayem AF, Anwar M. Fluid lamellar keratoplasty in keratoconus. *Ophthalmology* 2000;107:76–9.
- Mader TH, Yuan R, Lynn MJ, *et al.* Changes in keratometric astigmatism after suture removal more than one year after surgery. *Ophthalmology* 1993;100:119–26.
- Ruhschworm, Scholz U, Pfeiffer T, *et al.* Three-year clinical outcome after penetrating keratoplasty for keratoconus with the guided trephine system. *Am J Ophthalmol* 1999;127:666–73.
- Hersh PS, Jordan AJ, Mayers M. Corneal graft rejection episode after excimer laser phototherapeutic keratectomy. *Arch Ophthalmol* 1993;111:735–6.
- Goble RR, Hardman Lea SJ, Falcon MG. The use of the same size host and donor trephine in penetrating keratoplasty for keratoconus. *Eye* 1994;8:311–14.
- Moore MB, Gebhardt BM, Verity SM, *et al.* Fate of lyophilized xenogenic corneal lentilles in intrastromal implantation and epikeratophakia. *Invest Ophthalmol Vis Sci* 1987;28:555–9.
- Tuft SJ, Buckley RJ. Iris ischaemia following penetrating keratoplasty for keratoconus (Urrets-Zavalía syndrome). *Cornea* 1995;16:618–22.
- McElvanney AM, Adhikary HP. Penetrating keratoplasty in the mentally retarded. *Eye* 1997;11:786–9.
- Ghoriishi M, Akova YA, Tugal-Tutkun I, *et al.* Penetrating keratoplasty in atopic keratoconjunctivitis. *Cornea* 1995;14:610–13.
- Tuft SJ, Gregory WM, Davison CR. Bilateral penetrating keratoplasty for keratoconus. *Ophthalmology* 1995;102:462–8.
- Aggarwal RK. Deep lamellar keratoplasty—an alternative to penetrating keratoplasty. *Br J Ophthalmol* 1997;81:178–9.