

PostScript

LETTERS

Dense Kayser-Fleischer ring in asymptomatic Wilson's disease (hepatolenticular degeneration)

The Kayser-Fleischer ring is the single most important diagnostic sign in Wilson's disease; it is found in 95% of patients. Virtually all patients with Kayser-Fleischer rings have neurological manifestations.¹ Pseudo rings have been described in other conditions.¹ The density of a Kayser-Fleischer ring correlates with the severity of Wilson's disease.² We describe a rare case of a dense Kayser-Fleischer ring in an asymptomatic patient with an extremely high liver copper content. The recent significant genetic advances, and the clinical implications are discussed.

Case report

At the age of 14 this 23 year old white woman had an evisceration of her left eye for painful rubrotic glaucoma following chronic retinal detachment, resulting from ANA positive iridocyclitis. Her optician referred her because over the past few years, her left prosthetic eye had repeatedly needed an increasingly dense brown ring painted onto it, to match her remaining eye. On examination the visual acuity in the right eye was 6/6 with a heavily pigmented red brown Kayser-Fleischer ring (Fig 1). Her systemic and neurological examinations were normal.

Baseline biochemistry, liver function, haematology, and cerebral magnetic resonance image (MRI) were normal. She was ANA positive 1 in 20, serum copper 11.6 µmol/l (normal 11–22), and ceruloplasmin 0.15 g/l (normal 0.15–0.45). Twenty four hour urinary copper 9.2 µmol/24 h (normal 0.9 µmol/24 h). Haematoxylin and eosin stained liver biopsy showed normal architecture. Orcein and rhodanine stains showed patchy excessive copper binding protein, and copper within the hepatocytes. The quantified copper content of the sample was hugely elevated at 3000 µg/g (normal 20–50 µg/g).

She was treated with trientine dihydrochloride.³ The Kayser-Fleischer ring initially became denser but has faded considerably over the past 5 years; a thin rim still persists (Fig 2).

If you have a burning desire to respond to a paper published in the *BJO*, why not make use of our "rapid response" option? Log on to our website (www.bjophthalmol.com), find the paper that interests you, and send your response via email by clicking on the "eLetters" option in the box at the top right hand corner.

Providing it isn't libellous or obscene, it will be posted within seven days. You can retrieve it by clicking on "read eLetters" on our homepage.

The editors will decide as before whether to also publish it in a future paper issue.

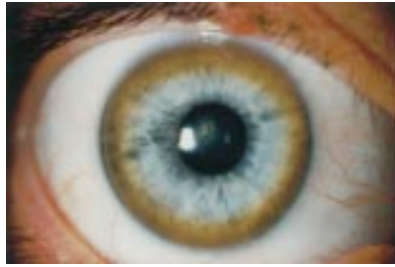

Figure 1 The right eye showing a heavily pigmented red brown Kayser-Fleischer ring.

The patient remains well with no hepatic or neurological manifestations.

Comment

This patient had an extremely elevated liver copper level, 60 times the normal level. She had to our knowledge the highest ever published liver copper content level over twice the highest level recorded in other publications.⁴ She had a very dense Kayser-Fleischer ring, but no neurological or hepatic abnormalities. Despite the severity of her condition she remained neurologically asymptomatic with normal liver architecture.

Wilson's disease is inherited as an autosomal recessive trait. The defect has been mapped and sequenced to the long arm of chromosome 13 (13q14.3). The Wilson's gene is responsible for a defective membrane bound P-type ATPase copper transport molecule, ATP7B. This is located in the *trans* golgi network; the ATPase delivers copper to copper binding ceruloplasmin. During elevated copper levels vesicles containing the ATPase and copper are released by exocytosis into bile. In patients with a defective gene there is an abnormal accumulation and, in comparison, low excretion of stored liver copper.⁵ These findings contrast with previous theories that Wilson's disease was caused by a defect of apo-ceruloplasmin post-translational modification, and abnormal binding to ceruloplasmin.⁴

There are a large number of copper binding ATP7B mutations.⁶ The clinical heterogeneity and overlap of clinical manifestations suggest that locus heterogeneity alone is unlikely to be responsible. It has been hypothesised that there is a subset of pedigrees in which an additional gene is affected other than that for ATP7B.⁵ Genes encode proteins for detoxification of stored copper—for example, metallothionein, and neutralisation of free radicals

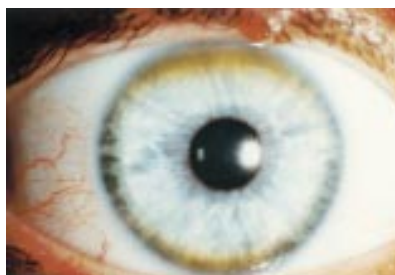

Figure 2 A thin rim still persists 5 years later.

such as super oxide dismutase.^{4,5} This could be a plausible explanation as to why such an extraordinarily high level of copper was bound safely in this patient's liver.

Untreated Wilson's disease has progressive, irreversible consequences, and ultimately causes death.⁴ The identification of a Kayser-Fleischer ring remains the most important clinical sign for the diagnosis of Wilson's disease.

Charlotte Anne Sullivan

Department of Ophthalmology, Birmingham and Midlands Eye Hospital, City Hospital, Western Road, Birmingham B18 7QU, UK

A Chopdar

Department of Ophthalmology, East Surrey Hospital, Surrey, UK

G A Shun-Shin

Department of Ophthalmology, Wolverhampton Eye Infirmary, Wolverhampton, West Midlands, UK

Correspondence to: Miss C A Sullivan, Birmingham and Midlands Eye Hospital, City Hospital, Western Road, Birmingham B18 7QU, UK
Accepted for publication 6 June 2001

References

- 1 **Finelli PF**, Kayser-Fleischer ring: hepatolenticular degeneration (Wilson's disease). *Neurology* 1995;**45**:1261–2.
- 2 **Rodman R**, Burnstine M, Esmali B, *et al*. Wilson's disease: presymptomatic patients and Kayser-Fleischer rings. *Ophthalmic Genet* 1997;**18**:79–85.
- 3 **Tankanow RM**. Pathophysiology and treatment of Wilson's disease. *Clin Pharm* 1991;**10**:839–49.
- 4 **Brewer GJ**, Yuzbasiyan-Gurkan V, Wilson's disease. *Medicine* 1992;**71**:139–64.
- 5 **Camakaris J**, Voskoboinik I, Mercer JF. Molecular mechanisms of copper homeostasis. *Biochem Biophys Res Commun* 1999;**261**:225–32.
- 6 **Thomas GR**, Forbes JR, Roberts EA, *et al*. The Wilson disease gene: spectrum of mutations and their consequences. *Nat Genet* 1995;**9**:210–17.

Rapidly developing intimal fibrosis mimicking giant cell arteritis

Temporal headache associated with a tender superficial temporal artery and decreased pulse on palpation are characteristics of giant cell arteritis. We report the clinical and biopsy findings in a patient in whom these symptoms were caused by a rapid developing intimal fibrosis.

Case report

A 51 year old woman presented with a 2 month history of a tender and painful left superficial temporal artery (STA). First she noticed a "thickened cord" on the left temple which felt pulsatile on palpation. Within 6 weeks the throbbing pulse disappeared and was followed by tenderness and pain. She also reported arthritic pain in the limbs and a morning cough over a 2 year period. She has smoked 40 cigarettes per day for 30 years. On examination the left STA felt hardened, knotted, non-pulsatile, and was slightly tender over a 2 cm distance (Fig 1, cross). There were no bruits on auscultation of major arteries. The facial and maxillary arteries were soft and

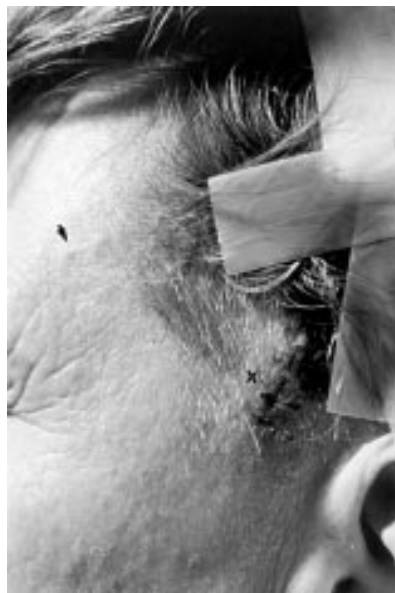

Figure 1 Thickened, tender, and painful superficial temporal artery in a 51 year old woman. At the site of biopsy the artery was pulselessness (cross). A knotted appearance is also present distally and rostrally (arrow).

pulsatile on both sides. The C reactive protein (CRP) was normal and the erythrocyte sedimentation rate (ESR) was 4 mm in the first hour. Blood pressure was 135/75.

It was considered necessary to exclude an inflammatory cause, given the similarity of the presentation to giant cell arteritis. The biopsy was taken at the site where the STA was pulseless and most prominent (Fig 1). The tissue was examined using the serial block, serial section technique in order to minimise the chance of a false negative result. The histological appearances were those of a severely fibrosed artery devoid of any inflammatory changes and consistent with arteriosclerosis. The intima was considerably thickened, the internal elastic lamina was preserved, and the media had some degree of fibrosis (Fig 2). The thickened intima, which had led to tightening of the lumen consisted of collagen and concentrically arranged layers of elastic fibres. No thrombotic material could be observed.

The patient remained stable over a 3 year follow up period and subsequent ESR and

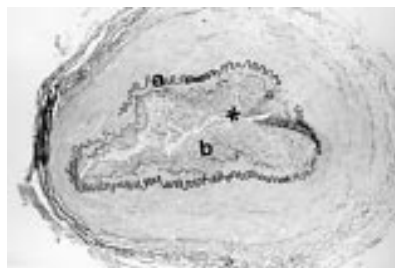


Figure 2 Photomicrograph showing a segment of the superficial temporal artery with severely narrowed lumen (asterisk). The internal elastic lamina (a) is well preserved (elastica stain). The intima is considerably thickened (b) and shows tissue proliferation. There are no signs of necrosis, inflammation, or thrombus.

CRP were normal. She continued having diffuse body pain.

Comment

GCA is a neurological emergency which, when left unrecognised and untreated frequently leads to permanent blindness.¹ ESR can be normal in 5–30% of patients,^{2,3} but this is an exceptionally rare diagnosis in middle aged patients.

In summary, our patient presented with a clinical picture suspicious of vasculitic occlusion of the superficial temporal artery, polymyalgia, and cough. We present this case as an illustration that this clinical picture can result from rapidly developing intimal fibrosis without any evidence of inflammation.

A Petzold, G T Plant

Moorfields Eye Hospital, City Road, London EC1 2PD, UK

F Scaravilli

Department of Neuropathology, Institute of Neurology, Queen's Square, London WC1N 3BG, UK

Correspondence to: Dr Petzold
Accepted for publication 9 July 2001

References

- 1 Font C, Cid MC, Coll-Vinent B, *et al.* Clinical features in patients with permanent visual loss due to biopsy-proven giant cell arteritis. *Br J Rheumatol* 1997;**36**:251–4.
- 2 Zweegman S, Makkink B, Stehouwer CD. Giant-cell arteritis with normal erythrocyte sedimentation rate: case report and review of the literature. *Neth J Med* 1993;**42**:128–31.
- 3 Ellis ME, Ralston S. ESR in the diagnosis and management of polymyalgia rheumatica/giant cell arteritis syndrome. *Ann Rheum Dis* 1983;**42**:168.

Fixed dilated pupil following deep lamellar keratoplasty (Urrets-Zavalía syndrome)

A fixed dilated pupil following penetrating keratoplasty is a well recognised if rare postoperative complication. We report a case of Urrets-Zavalía syndrome following a deep lamellar keratoplasty (DLK). To our knowledge this association has not been previously described.

The mydriasis following penetrating keratoplasty was first described by Castroviejo (Castroviejo R, personal communication) but it was Urrets-Zavalía who first published his observations on a series of six cases and suggested an association of fixed dilated pupil, iris atrophy, and secondary glaucoma.¹

The incidence of this syndrome is estimated at 5.8%, from pooled data on 445 eyes undergoing penetrating keratoplasty for keratoconus, of which 24 eyes developed a fixed dilated pupil.² Davies and Ruben also found a similar incidence.³ However, other more recent studies find no cases,^{4,6} and some even question its continued existence. This may in part reflect improved surgical technique and differing diagnostic criteria.

The pupil can become abnormally dilated following penetrating keratoplasty for keratoconus, particularly if dilating drops are used. There are three main groups of pupillary dilatation.²

(1) A pupil with normal light and near reaction which is at least 1.5 mm larger than its fellow unoperated eye. It fully constricts with topical miotics. An incidence of approximately 90% has been reported for this type of abnormality.³

(2) An unreactive parietic pupil that returns slowly to normal.

(3) Irreversible pupil dilatation with iris atrophy.

This syndrome has also been reported when no dilating drops were used.²

In addition to the pupil and iris abnormalities, Urrets-Zavalía also described other features—iris ectropion, pigment dispersion, anterior subcapsular cataract and posterior synechiae. No early postoperative pressure rises were documented, although some had peripheral anterior synechiae and secondary glaucoma. Gasset also describes the glaucoma as a secondary phenomenon, commenting that it is not integral to the syndrome.² In the series presented by Pouliquen *et al.*, severe anterior uveitis, fibrinous exudate, and broad posterior synechiae are described.⁷ An early postoperative intraocular pressure rise is documented in two of the three cases presented by Tuft and Buckley.⁸

We describe the case of a patient undergoing deep lamellar keratoplasty for keratoconus who developed a permanently dilated pupil with iris atrophy. In addition she had marked anterior uveitis and posterior synechiae similar to the cases presented by Pouliquen *et al.*⁷ Dilating drops were not used.

Case report

A woman with keratoconus underwent a left deep lamellar keratoplasty at the age of 28 because of unstable contact lens fit and central corneal scarring. A 7.75 mm graft into a 7.5 mm diameter recipient DLK was performed under peribulbar anaesthesia with sedation. Disposable Baron Hessburg suction trephines were used and the deep lamellar dissection performed after air injection, as described by Tuft and Buckley.⁹ A paracentesis was performed and no viscoelastic or air was injected into the anterior chamber. The procedure was uncomplicated.

In her medical history of note was atopic eczema and hay fever.

The eye became painful during the first postoperative evening. At the first dressing the next morning she was comfortable again but the pupil was noted to be semidilated with an intraocular pressure of 10 mm Hg. The anterior chamber was deep and quiet.

Three weeks postoperatively, despite using her topical steroids, she developed a marked anterior uveitis with posterior synechiae to the lens. This responded well to an increase in her topical steroids. However, the iris has remained fixed, dilated, and non-reactive.

The visual acuity at 1 month postoperatively was 6/9+ with $-1.75/-1.50 \times 125$. Unfortunately 11 weeks postoperatively she developed an inferior retinal detachment. No breaks were identified but she underwent a cryobuckle procedure with an encircling band. Six months after her initial surgery she sees 6/12 wearing a contact lens correction of $-2.25/-3.50 \times 65$. She is still troubled by glare and is somewhat unhappy with the cosmetic appearance of the eye.

Comment

The precise aetiology of this syndrome is unknown; it has been suggested that iris ischaemia can develop if it is compressed between the lens and cornea during surgery.³ This cannot be the explanation in patients undergoing deep lamellar keratoplasty. Urrets-Zavalía syndrome has also been described after penetrating keratoplasty for other indications³ and after cataract surgery.

Urrets-Zavalía suggested that the strong mydriasis produced by atropine at the time of

surgery brought the iris into contact with the peripheral cornea to produce peripheral anterior synechiae and glaucoma.¹ Davis and Ruben noted the condition was more common in the absence of a peripheral iridotomy and proposed a mechanism of relative pupil block.³ Naumann comments that in over 1000 cases of penetrating keratoplasty he has never seen this condition and suggests that performing a peripheral iridotomy in phakic patients is protective.⁴ Interestingly he always uses dilating drops.

It has been suggested that the iris is in some way abnormal in keratoconus, supported by the observation that these pupils remain dilated for longer periods following mydriasis than in normal eyes.² Keratoconic eyes seem to hyperreact to application of mydriatics as far as speed of dilation and duration of effect, this observation is also seen the eyes of patients with Down's syndrome.²

An abnormality of the sympathetic nervous system in the keratoconic eye remains unproven.

Davies and Ruben also suggest that direct iris trauma during surgery could result in strangulation of iris vessels in the mid-periphery and ischaemic paralysis of the sphincter pupillae.³

Tuft and Buckley suggest in the presence of raised intraocular pressure, the low ocular rigidity of the keratoconic eye permits occlusion of the vessels at the root of iris within the sclera, which results in iris ischaemia while preserving ciliary body function.⁹

This case, the first to our knowledge, describes the Urrets-Zavalía syndrome following a lamellar keratoplasty. The compressive theory cannot play a part in this instance and it may lend support to the theory of an intrinsic iris abnormality in keratoconus. Equally, the pain she experienced on the first postoperative evening may have been secondary to raised intraocular pressure and perhaps supports the ischaemic theory.⁹ In either case, this syndrome is still poorly understood.

Meg Minasian, William Ayliffe

Croydon Eye Unit, Mayday University Hospital
NHS Trust, London Rd, Thornton Heath, Surrey
CR7 7YE, UK

Correspondence to: Meg Minasian, Adnexal Unit,
Moorfields Eye Hospital, City Road, London
EC1V 2PD, UK; megminasian@hotmail.com
Accepted for publication 11 July 2001

References

- 1 **Urrets-Zavalía A.** Fixed dilated pupil, iris atrophy and secondary glaucoma: a distinct clinical entity following penetrating keratoplasty for keratoconus. *Am J Ophthalmol* 1963;**56**:257–65.
- 2 **Gasset AR.** Fixed dilated pupil following penetrating keratoplasty in keratoconus (Castroviejo syndrome). *Ann Ophthalmol* 1977;**9**:623–8.
- 3 **Davies PD,** Ruben M. The parietic pupil: its incidence and aetiology after keratoplasty for keratoconus. *Br J Ophthalmol* 1975;**59**:223–8.
- 4 **Naumann GO.** Iris ischaemia following penetrating keratoplasty for keratoconus (Urrets-Zavalía syndrome). *Cornea* 1997;**16**:120.
- 5 **Krachmer JH,** Feder RS, Belin MW. Keratoconus and related non-inflammatory corneal thinning disorders. *Surv Ophthalmol* 1984;**28**:293–322.
- 6 **Kirkness CM,** Ficker LA, Steele ADMcG, et al. The success of penetrating keratoplasty for keratoconus. *Eye* 1990;**4**:673–88.
- 7 **Pouliquen Y,** Ginmraes R, Petroustos G, et al. Le syndrome d'Urrets-Zavalía: existe-t-il encore? *J Fr Ophthalmol* 1983;**6**:325–6.
- 8 **Pouliquen Y,** Bernard J, Mezarik B. A propos de 4 cas de mydriase aiguë irido-atrophique

après kératoplastie pour kératocone. *Arch Ophthalmol (Paris)* 1970;**30**:219–26.

- 9 **Tuft SJ,** Buckley RJ. Iris ischaemia following penetrating keratoplasty for keratoconus (Urrets-Zavalía syndrome). *Cornea* 1995;**14**:618–22.

Asymptomatic oculopalatal myoclonus: an unusual case

Oculopalatal myoclonus is characterised by rhythmic pendular vertical eye movements associated with synchronous contraction of the soft palate.¹ It produces intractable oscillopsia,² and is normally the result of brainstem haemorrhage.² However, it is does not usually become manifest until several months or even years later, with the longest recorded interval being 49 months.³ We present an unusual case of a patient who sustained a brainstem haemorrhage following trauma. Eight years later he was incidentally noted to have oculopalatal myoclonus, and surprisingly was asymptomatic.

Case report

A 61 year old man was admitted to the neurosurgery department following head trauma. A computed tomography (CT) scan showed subarachnoid bleeding. An magnetic resonance image (MRI) revealed left frontal and posterior parietal contusions and a small brainstem haemorrhage. Following the head injury he complained of double vision on downgaze. Examination revealed bilateral fourth cranial nerve palsies, which resolved spontaneously.

Nine months later the patient developed acute angle closure glaucoma in his right eye, which was unresponsive to medical therapy. He subsequently underwent a right trabeculectomy. Thereafter, his visual acuities were 6/18 in the right eye and 6/6 in the left eye, and he was reviewed annually at a glaucoma clinic.

While attending 8 years after his head injury, an audible click was heard emanating from the patient. He was unaware of this because of longstanding sensorineural deafness. However, on further questioning his wife stated that she had been aware of the clicking for several months. Examination of the soft palate revealed rhythmic contractions that were synchronised with the auditory clicking. There was a right unilateral vertical pendular nystagmus, although no nystagmus was noted in the left eye. A diagnosis of oculopalatal myoclonus secondary to the brainstem haemorrhage 8 years previously was made. An MRI scan (T2 weighted images with contrast) was performed and found to be normal. The patient was unaware of oscillopsia, presumably as a consequence of his reduced visual acuity secondary to the previous episode of angle closure glaucoma. As he was asymptomatic no treatment was indicated.

Comment

Oculopalatal myoclonus is a rare condition normally resulting in intractable oscillopsia, thought to be caused by a lesion in the myoclonic triangle, which consists of the red nucleus, the ipsilateral inferior olive, and the contralateral dentate nucleus.⁴ To our knowledge, this is the first reported case of asymptomatic oculopalatal myoclonus. It also illustrates that the latency period may be longer than that previously described.

Peter Cackett, Clifford R Weir, Zaw Minn-Din

Tennent Institute of Ophthalmology, Gartnavel General Hospital, Great Western Road, Glasgow G12 0YN, UK

Correspondence to: Dr Cackett
Accepted for publication 12 July 2001

References

- 1 **Leigh RJ,** Zee DS. *The neurology of eye movements.* 3rd ed. New York: Oxford University Press, 1999.
- 2 **Talks SJ,** Elston JS. Oculopalatal myoclonus: eye movement studies, MRI findings and the difficulty of treatment. *Eye* 1997;**11**:19–24.
- 3 **Matsuo F,** Ajax ET. Palatal myoclonus and denervation supersensitivity in the central nervous system. *Ann Neurol* 1979;**5**:72–8.
- 4 **Koeppe AH,** Barron KD, Dentinger MP. Olivary hypertrophy: histochemical demonstration of hydrolytic enzymes. *Neurology* 1980;**30**:471–80.

Bilateral exudative retinopathy as the initial manifestation of retinitis pigmentosa

A Coats'-like retinopathy affects approximately 1–4% of cases of longstanding retinitis pigmentosa (RP).^{1,2} As a presenting sign of RP, however, Coats'-like retinopathy is extremely rare.³ We present a case of bilateral exudative retinopathy suggestive of Coats' disease in a 12 year old boy in whom investigation revealed previously undiagnosed RP.

Case report

A 12 year old male presented with a 3 week history of blurred vision in both eyes. There was no significant medical or family history. Visual acuities were 6/120 in the right eye and 6/15 in the left eye. Anterior segment examination was normal. The posterior segment of

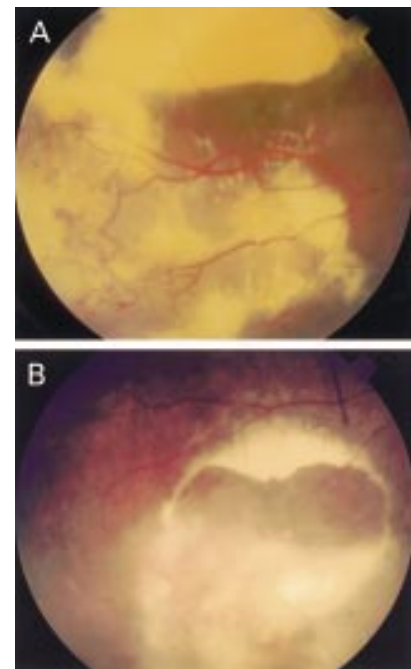


Figure 1 (A) Fundus photograph of the right eye showing subretinal exudation, serous retinal detachment, and telangiectatic retinal vessels. (B) Fundus photograph of the left eye showing mottled granularity of the retinal pigment epithelium.

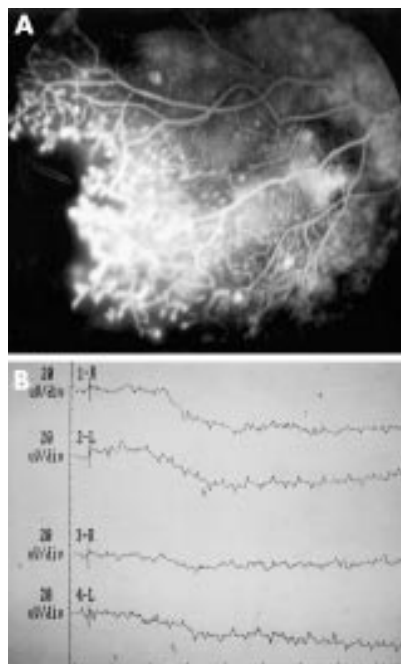


Figure 2 (A) Fluorescein angiogram of the right eye showing retinal ischaemia with adjacent telangiectasia. (B) Scotopic electroretinogram showing isoelectric response in both eyes.

both eyes showed extensive subretinal exudation, serous retinal detachment, and overlying retinal telangiectasia (Fig 1A). There was cystoid macular oedema with a lamellar macular hole in the left eye. The optic discs appeared normal. Additionally, mottled granularity of the retinal pigment epithelium (RPE) was noted in the mid-periphery of both retinas (Fig 1B). Upon further questioning, he admitted to night blindness.

A fluorescein angiogram confirmed retinal telangiectasia, serous retinal detachment, and macular oedema (Fig 2A). An electroretinogram (ERG) showed an isoelectric response under both scotopic and photopic conditions (Fig 2B). Visual field testing revealed marked constriction in both eyes.

A diagnosis of retinal telangiectasia, exudative retinopathy, and retinitis pigmentosa was made and the areas of most severe telangiectasia were treated with retinal cryotherapy. One year later the retinal telangiectasia had mostly resolved, the exudation was slightly less extensive and the visual acuity was unchanged.

Comment

The association between retinitis pigmentosa and exudative retinopathy was first described in 1956⁴ and has been termed a "Coats'-like RP".⁵ Various studies have suggested that 1–4% of RP cases will show such a response.^{1,2} This entity differs from true Coats' disease in that Coats'-like RP often occurs bilaterally, has no sex predisposition, and shows diffuse pigmented alterations in both fundi.^{5,6} The cause is unknown but it may represent a vasodilatory response to toxic products of photoreceptor/RPE degeneration.² Our case is unusual in that almost all previous reported cases have occurred in the setting of long-standing RP.^{2,3} Our patient had never consulted an ophthalmologist despite being night blind and having markedly constricted visual fields. We recommend that ophthalmologists

consider an underlying diagnosis of retinitis pigmentosa in any patient presenting a picture of bilateral exudative retinopathy.

Acknowledgments

Support provided by the International Award of Merit in Retina Research, Houston, Texas (JA Shields); Macula Foundation (CL Shields), and Eye Tumor Research Foundation, Philadelphia, PA, USA.

**Arun D Singh, Carol L Shields,
Jerry A Shields**

Oncology Service, Wills Eye Hospital, USA

Alan Goldfeder

Thomas Jefferson University, Philadelphia and Ophthalmic Physicians, Union, New Jersey, USA

Correspondence to: Arun D Singh, MD, Oncology Service, Wills Eye Hospital, 900 Walnut Street, Philadelphia, PA 19107, USA; arunsingh@eyetumors.com
Accepted for publication 16 July 2001

References

- 1 **Kajiwaru Y.** Ocular complications of retinitis pigmentosa. Association with Coats' syndrome. *Jpn J Clin Ophthalmol* 1980;**34**:947–55.
- 2 **Pruett RC.** Retinitis pigmentosa: clinical observations and correlations. *Trans Am Ophthalmol Soc* 1983; **81**:693–735.
- 3 **Kim RY, Kearney JJ.** Coats-type retinitis pigmentosa in a 4-year-old child. *Am J Ophthalmol* 1997;**114**:846–8.
- 4 **Zamorani G.** Una rara associazione di retinite di Coats con retinite pigmentosa. *Gior Ital Oftalmol* 1956;**9**:429–43.
- 5 **Khan JA, Ide CH, Strickland MP.** Coats'-type retinitis pigmentosa. *Surv Ophthalmol* 1988;**32**:317–32.
- 6 **Witschel H.** Retinopathia pigmentosa and "morbus Coats". *Klin Monatsbl Augenheilkd* 1974;**164**:405–11.

Resolution of proliferative venous stasis retinopathy after carotid endarterectomy

Ocular ischaemic syndrome (OIS) may present as an asymmetric retinopathy in

diabetic patients. We report a case of asymmetric diabetic retinopathy with posterior segment neovascularisation due to OIS associated with critical ipsilateral carotid stenosis where the neovascularisation resolved after carotid endarterectomy.

Case report

A 50 year old woman presented in May 1996 with left sided weakness. She had hypercholesterolaemia, hypertension, a family history of vascular disease, and was a smoker. She was found to be diabetic with peripheral retinal ischaemia and disc neovascularisation in the right eye, and minimal retinal ischaemia in the left eye (Fig 1). Her visual acuities were 6/12 in the right eye and 6/9 on the left. There was no anterior segment neovascularisation in either eye. Carotid Doppler and carotid angiography showed critical stenosis at the origin of the right internal carotid artery. The right middle cerebral artery branches were visualised as a result of retrograde flow through the ophthalmic artery. The left internal carotid artery was narrowed by 50% and there were no collaterals to the right hemisphere (Fig 2). Fluorescein angiography revealed a prolonged transit time with slow filling of choroidal and retinal vasculature, peripheral retinal capillary closure, and leakage from the disc neovascularisation.

One year later the optic disc neovascularisation and retinal ischaemia were unchanged with no iris neovascularisation. In April 1997 she underwent an uneventful right carotid endarterectomy. Two months later she developed clinically significant macular oedema in the right eye that was treated with focal argon laser photocoagulation.

Six months later the maculopathy had resolved and 14 months after surgery there was complete resolution of the optic disc neovascularisation. Three years after surgery the right eye had a visual acuity of 6/9, a near normal fluorescein angiogram transit time, minimal peripheral retinal ischaemia, and no posterior segment neovascularisation.

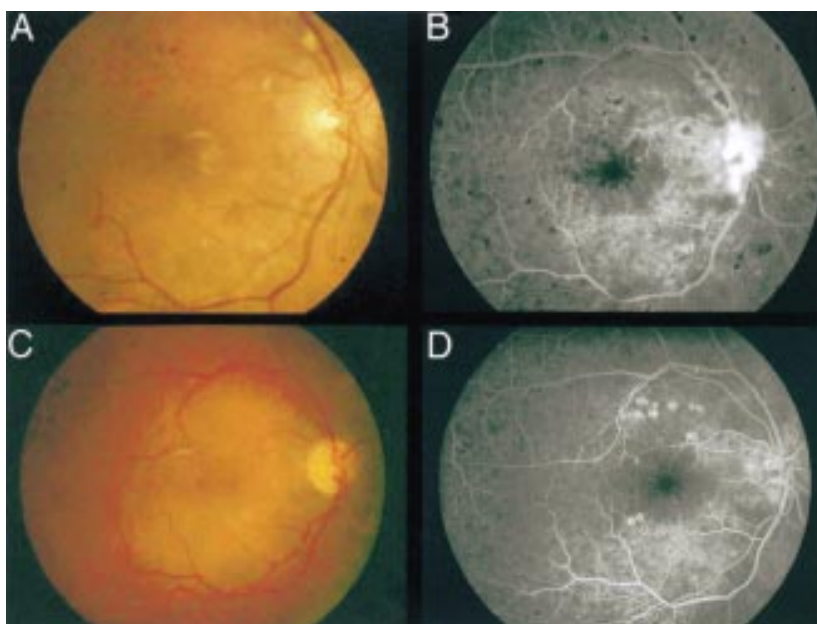


Figure 1 Presenting fundus photograph showing disc neovascularisation (A) with corresponding fluorescein angiogram showing leakage from these vessels (B). The neovascularisation has resolved 14 months after surgery (C) and is confirmed on fluorescein angiogram (D).

Comment

Ocular ischaemic syndrome (OIS) is characterised in the anterior segment by flare and initial hypotony, with later iris neovascularisation. Retinopathy with neovascular proliferation occurs in the fundus because of chronic hypoperfusion. The development of neovascular glaucoma can lead to permanent blindness.^{1,2} In the diabetic patient OIS is superimposed on any pre-existing diabetic retinopathy, and markedly asymmetric retinopathy should prompt a search for underlying ischaemia from carotid occlusive disease. Diabetic patients with marked proliferative changes require treatment with panretinal photocoagulation (PRP), which has been shown to reduce the risk of severe visual loss and neovascular glaucoma. However, there is no clear evidence for the benefit of PRP in patients with OIS. In one study only 36% of OIS patients with iris neovascularisation responded to PRP, which may be due to uveal rather than retinal ischaemia.^{3,4} In the case presented the patient was not treated with immediate PRP but reviewed regularly. The disc new vessels did not progress in the year before carotid endarterectomy and there was no immediate threat to vision.

Carotid stenosis can result in changes in the ophthalmic artery blood flow ranging from reduced antegrade to reversal of flow. If there is inadequate crossflow in the circle of Willis from the contralateral internal carotid, reversal of flow occurs in the ophthalmic artery as a consequence of a collateral circulation from branches of the external carotid artery.⁵ Although some series show no correlation between direction of flow and the severity of OIS Kerty *et al* in a study of 45 patients found that only reversal of flow was associated with structural changes of OIS.⁶

One similar case exists in the literature where neovascularisation resolved within several days of carotid endarterectomy (CEA).⁷ Other case reports also show that the retinopathy without neovascularisation can improve following surgery. However, the benefit of carotid endarterectomy in patients with ocular ischaemic syndrome is not quantified and it has never been shown to reverse

neovascular glaucoma.⁸⁻¹⁰ The European Carotid Surgery Trial showed that the risk of ischaemic stroke in symptomatic patients with 70-99% carotid stenosis with medical treatment was only 20% over 3 years and CEA lowered this by 50%. Based on the results of this a risk factor score suggested that a cerebral rather than an ocular event had a greater risk for stroke on medical treatment and would therefore derive greater benefit from surgery.²

In the absence of iris neovascularisation and severe peripheral retinal ischaemia the ocular changes in patients with OIS can be monitored closely for the development of iris neovascularisation but the retinal vascularisation may not require early treatment with PRP.

Christina A Rennie, Declan W Flanagan
Department of Ophthalmology, Addenbrooke's Hospital, Cambridge, UK

Correspondence to: Dr C Rennie, Department of Ophthalmology, Princess Margaret Hospital, Okus Road, Swindon, Wilts, SN1 4JU, UK
Accepted for publication 23 July 2001

References

- 1 Brown G, Magargal L. The ocular ischaemic syndrome. Clinical, fluorescein angiographic and carotid angiographic features. *Int Ophthalmol* 1988;**11**:239-51.
- 2 Malhotra R, Gregory-Evans K. Management of ocular ischaemic syndrome. *Br J Ophthalmol* 2000;**84**:1428-31.
- 3 Mizener JB, Podhajsky P, Hayreh SS. Ocular ischaemic syndrome. *Ophthalmology* 1997;**104**:859-64.
- 4 Sivalingam A, Brown GC, Magargal LE. The ocular ischemic syndrome. III. Visual prognosis and the effect of treatment. *Int Ophthalmol* 1991;**15**:15-20.
- 5 Riordan-Eva P, Restori M, Hamilton AMP, *et al*. Orbital ultrasound in the ocular ischaemic syndrome. *Eye* 1994;**8**:93-6.
- 6 Kerty E, Eide N, Horven I. Ocular hemodynamic changes in patients with high-grade carotid occlusive disease and development of chronic ocular ischaemia II. Clinical findings. *Acta Ophthalmol Scand* 1995;**73**:72-6.
- 7 Neupert JR, Brubaker RF, Kearns TP, *et al*. Rapid resolution of venous stasis retinopathy

after carotid endarterectomy. *Am J Ophthalmol* 1976;**81**:600-2.

- 8 Kearns TP, Younge BR, Piepgras DG. Resolution of venous stasis retinopathy after carotid endarterectomy. *Mayo Clin Proc* 1980;**55**:342-6.
- 9 Inoue M, Azumi A, Kajijura-Tsukahara Y, *et al*. Ocular ischemic syndrome in diabetic patients. *Jpn J Ophthalmol* 1999;**43**:31-5.
- 10 Geroulakos G, Bothchway L, Pai V, *et al*. Effect of carotid endarterectomy on the ocular circulation and on ocular symptoms unrelated to emboli. *Eur J Vasc Endovasc Surg* 1996;**11**:359-63.

Identifying the proportion of age related macular degeneration patients who would benefit from photodynamic therapy with verteporfin (Visudyne)

Verteporfin has recently been licensed for the treatment of subfoveal exudative cases of age related macular degeneration (AMD); however, it is not clear how many patients would actually benefit from this treatment.^{1,2} This question has far reaching implications in terms of verteporfin's introduction into the National Health Service in the United Kingdom.

Case report

We have recently looked at a cohort of 1418 new referrals (out of a possible 1481 (95.7%)) seen in the 166 consultant outpatient clinics at Southampton Eye Unit, between 1 December 2000 and 31 January 2001. Diagnoses were obtained from the consultant's letter to the referring doctor following the clinic visit to obtain the spectrum of diagnoses made. When two eyes were similarly affected this was recorded as a single diagnostic event.

Cataract related diagnoses³ were found to be most frequent, accounting for 28.8% (597) of the total. This was followed by retinal disease³ at 23.4% (485).

Within the retinal disease group AMD was the single most frequent diagnosis even though it may not have been the primary reason for referral, accounting for 22.3% (108) of the 485 retinal disease cases recorded. Of the 108 AMD patients identified, 62% (67) were female and 38% (41) male, the majority being above the age of 75 (90.7%). Approximately 78% (84) of the total number of patients had AMD affecting both eyes with unilateral involvement in the remaining 22% (24).

Of the 108, most were not felt to need further investigation, having either established and untreatable disease or mild changes. Only 13% (14) underwent further investigation with fluorescein angiography. Of these, four were thought to be possibly suitable for verteporfin treatment with only one fully meeting the criteria for treatment, having a predominantly classical subfoveal membrane.^{1,2}

Co-existing ocular diseases such as cataract and glaucoma were treated in 49% (53) of the 108 patients, cataract extraction predominating (70% (37)).

The majority of the 107 patients (77) who did not receive verteporfin therapy did not require or were not suitable for any further assistance for their AMD. The remainder (30) were assessed for low vision aids and/or registered as partially sighted/blind.

Comment

Photodynamic therapy with verteporfin has caused much excitement, as it is heralded as a breakthrough in the treatment of exudative AMD.^{4,5} A recent editorial in the *BMJ* suggested

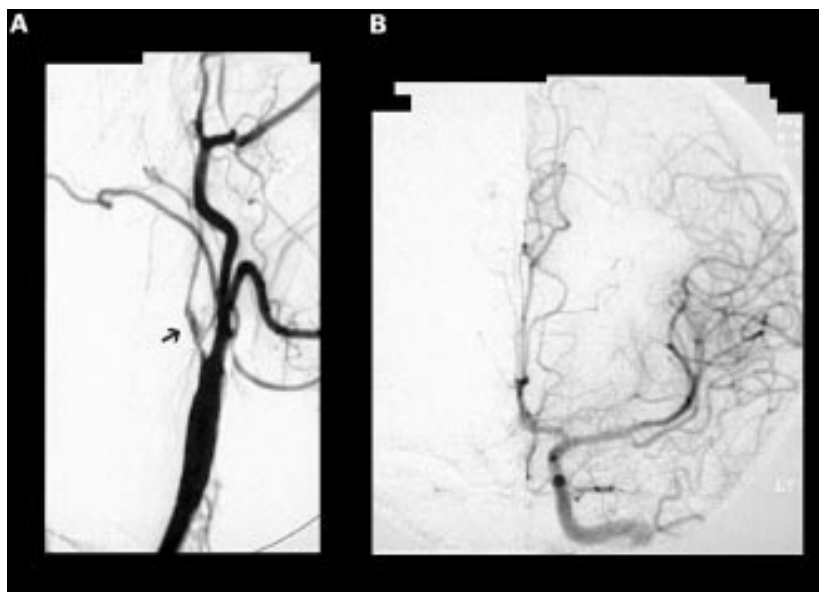

Figure 2 Angiography showing narrowing of the right internal carotid artery (A, arrow) and angiogram of the left side (B) revealing lack of crossflow to the right cerebral hemisphere allowing the development of collateral circulation via the ophthalmic artery.

that 20–30% of the 200 000 cases of exudative AMD that present to ophthalmologists each year in the United States would benefit from such photodynamic therapy.⁶ Southampton Eye Unit serves approximately 570 000 people as part of its main catchment area, corresponding to approximately 1% of the UK population, and produced only one person over the 2 month study period suitable for treatment with verteporfin by the strict criteria for its use.^{1,2} The period studied was before the awareness of photodynamic therapy was fully developed and represents an unselected group of patients having some degree of AMD. Subsequent studies might show a higher proportion of suitable patients once their referral is with a view for verteporfin treatment. Between August 2000 and April 2001 a total of 24 patients were assessed for verteporfin therapy resulting in seven receiving treatment, in keeping with the 4:1 ratio of those assessed and treated in the 2 month study. While it is difficult to extrapolate from such a small number it would seem that the number likely to benefit from verteporfin treatment may well be smaller than suggested even if the treatment criteria was extended to include occult, myopic, and idiopathic lesions.^{7,8}

Even with the addition of verteporfin therapy to the ranks of the treatment modalities available, the vast majority of AMD patients are still considered untreatable if the treatment criteria are observed.^{1,2} Rehabilitation in the form of low vision aids, registration as partially sighted or blind, and the treatment of co-existing ocular disease remains the mainstay of help that the ophthalmologist can offer.⁹ However, the interest created and accepted value of verteporfin should not be underestimated as it represents a new and non-destructive approach to the problem (in contrast with laser photocoagulation) and the first of a novel treatment option likely to be joined by others in the not too distant future.

N Mandal, I H Chisholm
Southampton Eye Unit

Correspondence to: Nakul Mandal, c/o Sheila Davies, Southampton Eye Unit, Southampton SO16 6YD, UK; nm397@soton.ac.uk
Accepted for publication 25 July 2001

References

- 1 Treatment of Age-related Macular Degeneration with Photodynamic Therapy (TAP) Study Group.** Verteporfin (Visudyne) therapy of subfoveal choroidal neovascularization in AMD: one-year results of two randomised clinical trials-TAP Report 1. *Arch Ophthalmol* 1999;**117**:1329–45.
- 2 Treatment of Age-related Macular Degeneration with Photodynamic Therapy (TAP) Study Group.** Verteporfin (Visudyne) therapy of subfoveal choroidal neovascularization in AMD: two-year results of two randomised clinical trials-TAP Report 2. *Arch Ophthalmol* 2001;**119**:198–207.
- 3 Ellwein LB, Friedlin V, McBean AM, et al.** Use of eye care services among the 1991 Medicare population. *Ophthalmology* 1996;**103**:1732–43.
- 4 Stokkermans TJW.** Treatment of age-related macular degeneration. *Clin Eye Vis Care* 2000;**12**:15–35.
- 5 Margherio RR, Margherio AR, DeSantis ME.** Laser treatment with verteporfin therapy and its potential impact on retinal practices. *Retina* 2000;**20**:325–30.
- 6 Bressler NM, Gills JP.** Age-related macular degeneration: new hope for a common problem comes from photodynamic therapy. *BMJ* 2000;**321**:1425–7.
- 7 Sickenberg M, Schmidt-Erfuth U, et al.** A preliminary study of photodynamic therapy using verteporfin for choroidal

neovascularisation in pathologic myopia, ocular histoplasmosis syndrome, angioid streaks, and idiopathic causes. *Arch Ophthalmol* 2000;**118**:327–36.

- 8 Mones J, for the Verteporfin in Photodynamic Therapy (VIP) Study Group.** Photodynamic therapy with verteporfin of the subfoveal choroidal neovascularisation in age-related macular degeneration: study design and baseline characteristics in the VIP randomized clinical trials. *Invest Ophthalmol Vis Sci* 1999;**40**:S321.
- 9 Chisholm IH, Bird AC, Grey RHB, et al.** Age-related macular degeneration best clinical practice guidelines. *Trans Roy Coll Ophthalmol* 2000;3–19.

A new technique for delivering sub-Tenon's anaesthesia in ophthalmic surgery

Sub-Tenon's local anaesthesia has become an accepted technique for anterior and posterior segment eye surgery.^{1–3} It is a safe, quick, and effective method of local anaesthesia. However, it requires a certain amount of skill for dissection into the sub-Tenon's space. This dissection can lead to bleeding and chemosis.

We describe a modification of the current technique of sub-Tenon's anaesthesia which aims to simplify the method of local anaesthetic delivery, avoid bleeding, and chemosis while maintaining effective anaesthesia.

Case report

Fifty consecutive patients undergoing anterior segment surgery scheduled for local anaesthesia were recruited for this study.

For this procedure, a 22 gauge Venflon standard intravenous cannula was used. The conjunctiva was anaesthetised with topical amethocaine 1%. A Barraquet speculum was inserted. The conjunctiva was grasped 5 mm from the limbus using toothed forceps. Under direct visualisation the tip of a 22 gauge Venflon was used to introduce the plastic cannula under the conjunctiva and Tenon's fascia (keeping the needle tip visible at all times) (Fig 1A). The plastic cannula was advanced over the needle, which was drawn back and removed (Fig 1B). Four millilitres of lignocaine 2% with 30 international units (IU)/ml of hyalase was then injected through the plastic cannula (Fig 1C).

All 50 patients had anterior segment surgery. Forty six were cataract operations with posterior chamber lens implant, and four were phacotrabeculectomies. None experienced excessive discomfort on delivery of the block. All local anaesthetic blocks were performed by one operator and no complication which prevented surgery occurred. No patient who was scheduled for local anaesthesia was considered unsuitable for this technique.

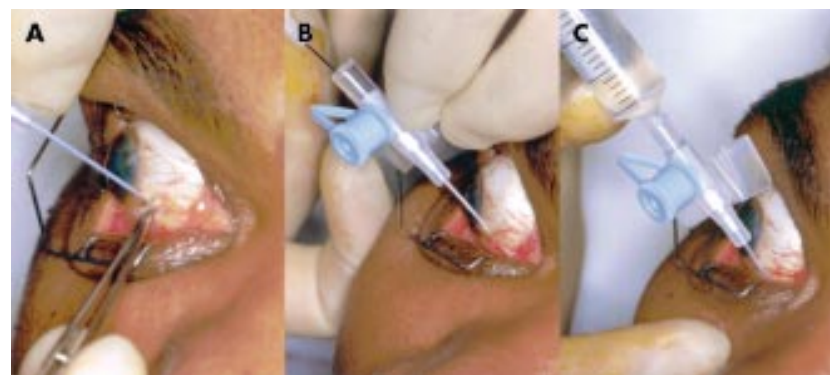


Figure 1 New technique for delivering sub-Tenon's anaesthesia injection.

All patients had effective anaesthesia and akinesia for the surgical procedure. None complained of pain. Top up of anaesthesia was not required in any case. Twenty eight patients had complete or partial ptosis.

Subconjunctival haemorrhage extending more than one quadrant occurred in one patient, but this did not interfere with surgery. None had chemosis.

Comment

Sub-Tenon's local anaesthesia is a well established technique for ophthalmic surgery. Although the Venflon cannula does have a sharp needle, it is used simply as an introducer to place the blunt plastic cannula in the correct tissue plane. The needle tip is kept under direct visualisation at all times. Thus there is minimal risk of ocular perforation with this technique.

Venflon cannulas are used for intravenous delivery of drugs and fluid so are readily available, inexpensive, and disposable. Sub-Tenon's cannulas in current use are specialised cannulas and therefore more costly than intravenous cannulas.

We describe a modification of the current technique of sub-Tenon's anaesthesia which simplifies the method using an intravenous cannula. We predict that this method is easier to learn and that it maintains the efficacy of this type of anaesthesia without compromising safety.

Sandip Amin

Department of Anaesthesia, Moorfields Eye Hospital, City Road, London EC1V 2PD, UK

Miriam Minihan

Department of Ophthalmology, St Thomas's Hospital, Lambeth Palace Road, London SE1 7EH, UK

Sarit Lesnik-Oberstein

Department of Ophthalmology, Moorfields Eye Hospital, City Road, London EC1V 2PD, UK

Caroline Carr

Department of Anaesthesia, Moorfields Eye Hospital, City Road, London EC1V 2PD, UK

Correspondence to: Sandip Amin; Samin@talk21.com

Accepted for publication 13 August 2001

References

- 1 Stevens JD.** A new local anaesthesia technique for cataract extraction by one quadrant sub-Tenon's infiltration. *Br J Ophthalmol* 1992;**76**:670–4.
- 2 Mein CE, Woodcock MG.** Local anaesthesia for vitreoretinal surgery. *Retina* 1990;**10**:47–9.
- 3 Hansen EA, Mein CE, Mazzoli R.** Ocular anaesthesia for cataract surgery: a direct sub-Tenon's approach. *Ophthalmic Surg* 1990;**21**:696–9.

- 4 Li HK, Abouleish A, Grady J, *et al.* Sub-Tenon's injection for local anaesthesia in posterior segment surgery. *Ophthalmology* 2000;**107**:41–7.
- 5 Roman SJ, Chong Sit DA, Boureau CM, *et al.* Sub-Tenon's anaesthesia: an efficient and safe technique. *Br J Ophthalmol* 1997;**81**:673–6.

MAILBOX

IOP measurement and central corneal thickness

In the recent paper by Feltgen and colleagues,¹ the intraocular pressure (IOP) was measured by Goldmann applanation tonometry and by using a cannula inserted into the anterior chamber connected with a pressure transducer. Thus, the measurement took place omitting a possible influence of the cornea on the result. Marx *et al*² believed that by intracameral measurement the “true” intraocular pressure may be measured. Feltgen *et al* share his opinion. They believe, therefore, that they have compared the intraocular pressure measured with and without the possible influence of the cornea.

Feltgen *et al* write in their conclusion: “There is no systematic error of applanation tonometry with increasing central corneal thickness (CCT). Therefore it is inadequate to recalculate IOP based on regression formula of applanatory IOP versus CCT.” They base their conclusion on their results. In our opinion their paper shows the following methodological deficits: (1) Both methods used for measuring IOP are not up to the demands of the scientific technique of measurement; (2) their intracamerally measured IOP values do not reflect the true IOP because of bias; (3) a non-significant regression coefficient does not prove that the slope is actually 0 and, therefore, by a non-significant regression coefficient it is not proved that applanatory readings are not influenced by CCT; (4) the goodness of fit of the linear regression model is insufficient; and (5) an important covariate (true IOP value) was omitted in the linear regression. We would like to discuss these points in detail.

In the study of Feltgen *et al* the only criterion for the quality of measurement is the stability of the readings on the monitor. However, it is not sufficient to conclude from the presence of stability that the scale readings

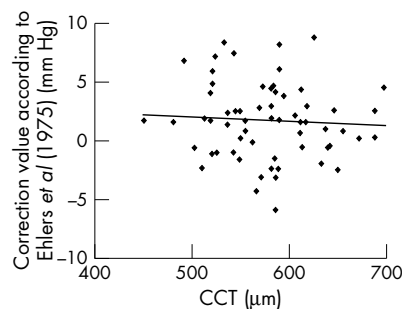


Figure 1 Dependence of differences in IOP measurements from CCT. Data of figure 2 of Feltgen *et al* obtained by digitisation; 68 of the 73 data points could be identified. The four outliers shown by Feltgen *et al* as open circles are omitted. These outliers would have made the use of the same scale in both diagrams more difficult. Thus n = 64. Same scale as in Figure 2.

represent the “true” pressure value that is at the tip of the cannula. If there were a barrier inside the cannula the reading on the monitor would also be stable but would not represent the pressure at the tip. There are many pitfalls in pressure measurements by thin tubes that we know from our own studies.^{3,4} Minute air bubbles or tiny particles influence the result a great deal. If we want to know that a display reading represents the quantity in question then we have to guarantee that the measurement system has the opportunity to react freely to changes in the quantity. This guarantee can be obtained by feeding a known signal to the input of the system and by observing the output. If the output reacts in the expected way then the guarantee is given. Ehlers *et al*⁵ realised this in their rabbit experiments and we in electrophysiology.^{6–9} As long as this demand is not met the results are not definitive, giving cause for criticism and leading to misinterpretations.

Feltgen *et al* write in their paper (p 86): “. . . however, we believe intracamerally measured IOP values reflect the ‘true’ IOP more accurately.” Scientific facts should not be a matter of belief. The belief of the authors in the values they measured is not justified. In the study under discussion their figure 2 shows the scatter plot of the pressure differences versus central corneal thickness. From this diagram and from their statistical calculations the authors draw their conclusions. Their results are quite different from those of Ehlers *et al*⁵ shown in figure 4 of their paper. Thus we must compare these two data sets. To facilitate this task, we have digitised the data presented in the figures of Feltgen *et al* and of Ehlers *et al*. They are shown here in Figures 1 and 2 on the same scale. The difference is striking.

Let's first consider a possible reason from the physical point of view. Ehlers *et al*⁵ reduced the pressure measurement to a basic physical quantity, here to the length of a water column. We can, therefore, trust the results of Ehlers *et al* more than the results of Feltgen *et al* who used a pressure transducer which has a zero point fluctuation up to 4.5 mm Hg (Abbott GmbH, data file). It is recommended also by the manufacturer that the zero point of the measurement system has to be determined for each patient by comparison with a water column (Dr Beer, Abbott GmbH, Wiesbaden, personal communication). This procedure is not described by Feltgen *et al*.

Therefore, none of the methods used in the article by Feltgen *et al* may be called a reference method and all methods may be prone to error and bias. Hence, analysis of differences in IOP between these models is inap-

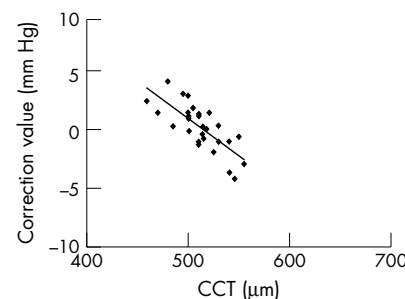


Figure 2 Dependence of differences in IOP measurements from CCT. Data of figure 4 of Ehlers *et al*⁵ obtained by digitisation. All data points could be identified. Thus n = 29. Same scale as in Figure 1.

propriate in order to decide on the necessity of a conversion formula.

Further, the variability of differences is large, which is probably the result of errors in the intracameral measurement of IOP. Regression lines with a small non-significant slope (0.38 mm Hg IOP difference per 0.1 mm cornea thickness in the article by Feltgen *et al*) may occur in both situations where variability is both high and low. Only, in the latter case, when—as a consequence of the small variability—the confidence interval for the slope is narrow, may this be interpreted in the way that the covariate included in the model (that is, CCT) has no effect. If the variability is high and the slope is approximately 0, this may lead to the conclusion that IOP measurement is inappropriate because of too large an error. This conclusion is allowed if no other essential covariates were overlooked. If variability is high and the slope of the regression line is near 0, a large p value may not be interpreted as a proof of no effect of the covariate considered in the regression model. For better interpretation of the results a confidence interval for the estimated slope would have been much more appropriate than a p value.

As a consequence, the differences between measurements from applanation tonometry and a reference method, like the intraocular hydrostatic pressure done by Ehlers *et al*, should be evaluated first. If measurements by applanatory IOP are highly correlated with measurements by the reference method a conversion formula may be derived from linear regression. Under the assumption of small variability of residuals (difference between observed value and regression line)—that is, a satisfactory goodness of fit (for example, $r^2 \geq 60\%$), results may lead to the recommendation of the use of a conversion formula. In contrast, Feltgen *et al* report an r^2 of 0.2%. Only for small residuals, a slope approximately 0, and a confidence interval with limits near to 0, may the recommendation that a conversion formula is not necessary be given.

Moreover, the large variability in IOP differences may occur because Feltgen *et al* did not adjust for “true” intraocular hydrostatic pressure as Ehlers *et al* did. Since Ehlers *et al* calculated separate linear regression models for 10 mm Hg and 30 mm Hg which resulted in different intercepts and slope parameters, this might be another source of variation in the IOP differences from Feltgen *et al* which were unadjusted.

We hope our arguments are convincing and ask that you bring them to the attention of your readers.

Richard Stodtmeister

St Elisabeth Hospital Rodalben (Palatinate),
Turnstrasse 24, D-66953 Pirmasens, Germany

Martina Kron, Wilhelm Gaus

University of Ulm, Department of Biometry and
Medical Documentation, Schwabstrasse 13,
D-89075 Ulm, Germany

Correspondence to: Professor Dr med Richard
Stodtmeister; Stodtmeister@online.de

References

- 1 Feltgen N, Leifert D, Funk J. Correlation between central corneal thickness, applanation tonometry, and direct intracameral IOP readings. *Br J Ophthalmol* 2001;**85**:85–7.
- 2 Marx W, Madjlessi F, Reinhard T, *et al.* [More than four years' experience with electronic intraocular needle tonometry] Mehr als vier Jahre Erfahrung mit der elektronischen intraokularen Nadel-Druckmessung bei

- irregularen Hornhauten. *Ophthalmologie* 1999;**96**:498–502.
- 3 **Stodtmeister R**, Kästner R, Pillunat LE. Saignapfmethoden. In: Straub W, Kroll P, Küchle HJ, eds. *Augenärztliche Untersuchungsmethoden*. 1st ed. Stuttgart: Ferdinand Enke, 1995:436–61.
 - 4 **Stodtmeister R**, Hornberger M, Hofer M, et al. Okulo-Oszillo-Dynamographie nach Ulrich und Ulrich: Ergebnisse bei Augengesunden. *Klin Monatsbl Augenheilkd* 1988;**192**:219–33.
 - 5 **Ehlers N**, Bramson T, Sperling S. Applanation tonometry and central corneal thickness. *Acta Ophthalmol (Copenh)* 1975;**53**:34–43.
 - 6 **Stodtmeister R**, Wilmanns I. Bandpass measurements in the electroretinographic electrode circuit. *Albrecht Von Graefes Arch Klin Exp Ophthalmol* 1978;**208**:263–7.
 - 7 **Stodtmeister R**, Wilmanns I. Changes of the current pathways in the eye due to coating agents during electroretinography. *Albrecht Von Graefes Arch Klin Exp Ophthalmol* 1978;**208**:255–60.
 - 8 **Stodtmeister R**, Wilmanns I, Koenig A, et al. EEG-Registrierung beim Hirntod. *Prakt Anaesth* 1978;**13**:446–9.
 - 9 **Wilmanns I**, Stodtmeister R. Ein neues Verfahren zur Kalibrierung elektrophysiologischer Untersuchungseinheiten. *Albrecht Von Graefes Arch Klin Exp Ophthalmol* 1977;**205**:33–9.

Authors' reply

In reply to the comments of Stodtmeister and colleagues on our recent paper,¹ we won't argue about the correlation between central corneal thickness (CCT) and intraocular pressure (IOP), but we mistrust the clinical application of correcting factors. Stodtmeister *et al* compare our study to that of Ehlers *et al*² which is often cited to prove an influence of corneal thickness on applanatory measurement.

In our paper simultaneous IOP measurement by applanation and intracameral tonometry was performed. Assuming a normal CCT of 520 µm, an IOP correction for every 10 µm change in corneal thickness is recommended. But in the Ehlers paper, there are some confusing arguments.

Ehlers *et al*² describe a very good correlation between direct and intracameral IOP measurement (correlation coefficient approximated 1). Unfortunately, they didn't give the measured IOP values. In figure 2, the slopes of correlation lines at different CCT are presented for rabbits (not for human eyes!). The increase of the slopes are less than 45°. With the paper of Bland and Altman³ in mind, a minor methodological agreement is very likely. It is therefore not allowed to recalculate the values P10 and P30 (applanatory versus intracamerally IOP, measured at an adjusted IOP of 10 and 30 mm Hg) for a relevant IOP level of 20 mm Hg (P20). It is indeed very interesting that the group didn't measure at an IOP level of 20 mm Hg.

The equipment for intracameral measurement is comparable to our device. We also calibrated the transducer before each measurement. When we tested our device on enucleated human eyes in a preclinical study, a very sensitive change of IOP values was noted when touching the eyeball. We therefore decided not to measure the IOP simultaneously. We also confirmed these findings *in vivo*. For these reasons, we expected an unpredictable increase of applanatory measurement during intracamerally IOP in the study of Ehlers.² Unfortunately, there is no comment about this problem.

Stodtmeister and colleagues pointed out the "pitfalls in pressure measurement" (bubbles or tiny particles) without mentioning that Ehlers had not solved these problems in

his trial on human eyes. We are also missing any information about the cannula size. Additionally, the device used resembles an "open system" where fluid could circulate through the anterior chamber and trabecular meshwork. This can generate a noticeable change in intraocular pressure.

Ehlers *et al*² measured IOP in patients with an acute eye disease (glaucoma patients requiring surgery) and cataract patients. He changed the IOP to 10 and 30 mm Hg. This method is questionable especially in glaucoma patients, because an acute IOP change could also entail endothelial alterations which could alter CCT. Unfortunately, he didn't measure the CCT after IOP change. We have no information about the influence of IOP alterations on CCT.

In summary, the above mentioned study gives a hint on the influence of CCT on IOP measurement, but does not prove this assumption. It is amazing that within the last 25 years nearly 50 published papers refer to the Ehlers study² without checking the results by intracameral measurement themselves.

All papers measuring CCT and applanatory IOP renouncing intracameral measurement described an increasing IOP with increasing CCT. We could also confirm this finding in our study ($y = 14.5 + 8.4 \times \text{CCT}$, where y is applanatory IOP in mm Hg). Of course, it would be easiest to claim the cornea for this correlation. But it is also conceivable that eyes with thick corneas (for example, OHT) have a reduced ocular outflow facility and consequently elevated IOP—for instance, because of a "thick" trabecular meshwork.

With the present study¹ we tried to find out if the above recommended correcting factors are clinically applicable or not. According to our findings they are not. We found quite variable and unpredictable differences between intraocular pressure and applanatory measurement in an individual patient. Interestingly, the same results can be found in the Ehlers study.² Therefore, we renew our warning to recalculate the IOP depending on central corneal thickness.

Nicolas Feltgen, Jens Funk

Department of Ophthalmology,
Albert-Ludwigs-University Freiburg, Germany;
feltgen@aug.ukl.uni-freiburg.de

References

- 1 **Feltgen N**, Leifert D, Funk J. Correlation between central corneal thickness, applanation tonometry, and direct intracameral IOP readings. *Br J Ophthalmol* 2001;**85**:85–7.
- 2 **Ehlers N**, Bramson T, Sperling S. Applanation tonometry and central corneal thickness. *Acta Ophthalmol (Copenh)* 1975;**53**:34–43.
- 3 **Bland JM**, Altman DG. Statistical methods for assessing agreement between two methods of clinical measurement. *Lancet* 1986;**1**:307–10.

NOTICES

Onchocerciasis

The latest issue of *Community Eye Health* (No 38) discusses onchocerciasis and the impact of interventions, with an editorial by Bjorn Thylefors, former director of the Programme for the Prevention of Blindness and Deafness, WHO. For further information please contact *Community Eye Health*, International Centre for Eye Health, Institute of Ophthalmology, 11–43 Bath Street, London EC1V 9EL. (tel: +44 (0) 20 7608 6909/6910/6923; fax: +44 (0) 7250 3207; email: eyesource@ucl.ac.uk).

Annual subscription £25. Free to workers in developing countries.

International Centre for Eye Health

The International Centre for Eye Health has published a new edition of the *Standard List of Medicines, Equipment, Instruments and Optical Supplies* (2001) for eye care services in developing countries. It is compiled by the Task Force of the International Agency for the Prevention of Blindness. Further details: Sue Stevens, International Centre for Eye Health, 11–43 Bath Street, London EC1V 9EL, UK (tel: +44 (0) 20 7608 6910; email: eyesource@ucl.ac.uk).

Leonhard Klein Award 2002

To promote ophthalmic surgery the Leonhard Klein Foundation bestows the Leonhard Klein Award 2002 for innovative, scientific works in the field of development and application of microsurgical instruments, as well as for microsurgical operating techniques.

The award is endowed with 15.000€ and can be conferred to an individual person as well as to a group of researchers. The prize sum must be spent for research in the field of ophthalmic surgery.

Individual and third party applications are accepted. Five copies of the works must be submitted in either English or German. The deadline for applications is 31 March 2002. Applications should be sent to: Stifterverband für die Deutsche Wissenschaft e.V., Frau Dr Marilen Macher, Postfach 164460, D-45224 Essen, Germany.

Second Sight

Second Sight, a UK based charity whose aims are to eliminate the backlog of cataract blind in India by the year 2020 and to establish strong links between Indian and British ophthalmologists, is regularly sending volunteer surgeons to India. Details can be found at the charity website (www.secondsight.org.uk) or by contacting Dr Lucy Mathen (lucymathen@yahoo.com).

Specific Eye Conditions (SPECS)

Specific Eye ConditionS (SPECS) is a not for profit organisation which acts as an umbrella organisation for support groups of any conditions or syndrome with an integral eye disorder. SPECS represents over fifty different organisations related to eye disorders ranging from conditions that are relatively common to very rare syndromes. We also include groups who offer support of a more general nature to visually impaired and blind people. Support groups meet regularly in the Boardroom at Moorfields Eye Hospital to offer support to each other, share experiences and explore new ways of working together. The web site www.eyecconditions.org.uk acts as a portal giving direct access to support groups own sites. The SPECS web page is a valuable resource for professionals and may also be of interest to people with a visual impairment or who are blind. For further details about SPECS contact: Kay Parkinson, SPECS Development Officer (tel: +44 (0)1803 524238; email: k@eyecconditions.org.uk; www.eyecconditions.org.uk).

4th International Conference on the Adjuvant Therapy of Malignant Melanoma

The 4th International Conference on the adjuvant therapy of malignant melanoma will

be held at The Royal College of Physicians, London on 15–16 March 2002. Further details: Conference Secretariat, CCI Ltd, 2 Palmerston Court, Palmerston Way, London SW8 4AJ, UK (tel: + 44 (0) 20 7720 0600; fax: + 44 (0) 20 7720 7177; email: melanoma@confcomm.co.uk; website: www.confcomm.co.uk/Melanoma).

EUPO 2002 Course Retina

A course on retina will be held on 15–17 March 2002 at Erlangen, Germany, where European professors will teach European residents. Further details: Priv Doz Dr Ulrich Schonherr, Friedrich-Alexander-University of Erlangen-Nuemberg, Department of Ophthalmology, Schwabachanlage 6 (Kopfkl. Klinikum), D-91054 Erlangen, Germany (tel: +49 9131 853 4379; fax: +49 9131 853 4332; email: ulrich-schoenherr@augen.imed.uni-erlangen.de).

XXIXth International Congress of Ophthalmology

The XXIXth International Congress of Ophthalmology will be held on 21–25 April 2002 in Sydney, Australia. Further details: Congress

Secretariat, C/- ICMS Australia Pty Ltd, GPO Box 2609, Sydney, NSW 2001, Australia (tel: +61 2 9241 1478; fax: +61 2 9251 3552; email: ophthal@icmsaust.com.au; website: www.ophthalmology.aust.com).

12th Meeting of the European Association for the Study of Diabetic Eye Complications (EASDEC)

The 12th meeting of the EASDEC will be held on 24–26 May 2002 in Udine, Italy. The deadline for abstracts is 15 February 2002. Three travel grants for young members (less than 35 years of age at the time of the meeting) are available. For information on the travel grants, please contact Pr CD Agardh, President of EASDEC, Malmö University Hospital, SE-205 02 Malmö, Sweden (tel +46 40 33 10 16; fax: +46 40 33 73 66; email: carl-david.agardh@endo.mas.lu.se). Further details: NORD EST CONGRESSI, Via Aquilea, 21.-33100 Udine, Italy (tel: +30 0432 21391; fax: +39 0432 50687; email: nordest.congressi@ud.nettuno.it)

International Society for Behçet's Disease

The 10th International Congress on Behçet's Disease will be held in Berlin 27–29 June 2002. Further details: Professor Ch Zouboulis (email: zoubbere@zedat.fu-berlin.de).

Singapore National Eye Centre 5th International Meeting

The Singapore National Eye Centre 5th International Meeting will be held on 3–5 August 2002 in Singapore. Further details: Ms Amy Lim, Organising Secretariat, Singapore National Eye Centre, 11 Third Hospital Avenue, Singapore 168751 (tel: (65) 322 8374; fax: (65) 227 7290; email: Amy_Lim@snecc.com.sg).

CORRECTION

We regret that an error occurred in the mailbox letter published by Kenawy *et al* in the November 2001 issue of *BJO* (2001;85:1394–5). The name of one of the authors was incorrect and should have been Omar M Ayoub.



Is your paper being cited?

CiteTrack service

CiteTrack will alert you by email whenever new content in the *British Journal of Ophthalmology* or a participating journal is published that matches criteria you want to track

Topics: Tell CiteTrack which words or subjects to watch for in new content

Authors: Be alerted whenever key authors you are following publish a new paper

Articles: Know whenever a paper of interest to you is referenced by another paper

www.bjophthalmol.com