

PostScript

LETTERS

If you have a burning desire to respond to a paper published in the *BJO*, why not make use of our "rapid response" option?

Log on to our website (www.bjophthalmol.com), find the paper that interests you, and send your response via email by clicking on the "eletters" option in the box at the top right hand corner.

Providing it isn't libellous or obscene, it will be posted within seven days. You can retrieve it by clicking on "read eletters" on our homepage.

The editors will decide as before whether to also publish it in a future paper issue.

The ocular surface toxicity of paraquat

We describe the clinical appearance and progress of bilateral ocular chemical injury caused by paraquat, a herbicide. Paraquat is used more commonly in developing countries and it has been associated with severe and prolonged ocular surface abnormalities due to the nature of the chemical.¹ The current concepts in managing such an injury are reviewed.

Case report

A 69 year old fruit farmer splashed a 20% solution of paraquat into both his eyes. The exposure of the right eye to the solution was more marked. The eyes were irrigated for less than 5 minutes at the time of the injury, and a formal irrigation, using Ringer's solution for each eye, was not performed until presentation 5 hours later.

General medical history revealed that apart from controlled hypertension he was otherwise well and he had no previous history of ocular problems.

On arrival uncorrected visual acuity was 6/9 on the right and 6/12 on the left. The intraocular pressure was 14 mm Hg on the right and 19 mm Hg on the left. There was a circular 90% epithelial defect centred over the right cornea. The remaining corneal epithelium was opaque, leathery and oedematous (Fig 1). The left cornea was epithelialised although the surface was irregular and hazy in appearance (Fig 2). The conjunctiva was hyperaemic and chemotic, particularly on the right. The limbal vasculature initially appeared congested, but there was no evidence of episcleral ischaemia. The corneal stroma was clear. Examination did not reveal any abnormality of the anterior chamber, lens, or posterior pole in either eye.

The patient was commenced on our chemical burns protocol.² This comprises topical citrate 10% drops every 2 hours, ascorbate 10% drops every 2 hours, chloramphenicol ointment four times daily, atropine 1% drops three times a day, fluorometholone acetate 1% drops every 2 hours, oral ascorbate 500 mg four times daily, and 4 g of a urinary alkaliniser

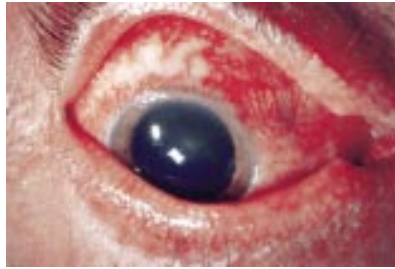


Figure 1 Right eye at presentation.

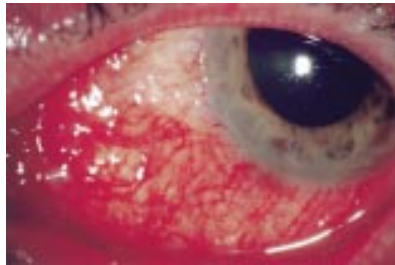


Figure 2 Left eye at presentation.

(Ural, Abbot Pharmaceutical, IL, USA) containing 750 mg citric acid anhydrous and 630 mg sodium citrate anhydrous three times daily.

On the first day after presentation there was complete loss of the corneal epithelium in the right eye. The bulbar and tarsal conjunctival epithelium had also sloughed off. The conjunctiva in this eye was diffusely chemotic. There was extensive thrombosis of superficial and deep conjunctival vessels over the entire bulbar conjunctiva; however, the episcleral vessels remained intact and patent.

The left cornea had punctate epithelial erosions over most of its surface and an epithelial defect involving the inferomedial conjunctiva had just encroached onto the adjacent cornea. The conjunctiva in the left eye was also oedematous and had thrombosed vessels around the epithelial defect. Over the next few days the epithelial defect in the left eye enlarged to involve the inferonasal quadrant of the cornea although the conjunctival defect only enlarged slightly.

A severe pseudomembranous conjunctivitis developed in the right eye by the third day with fibrinous adhesions developing in the inferior fornix. Periodic glass rodding was commenced to break early symblepharon

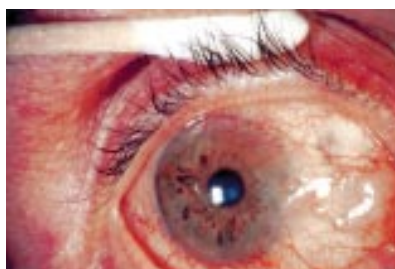

Figure 3 Right eye 6 months after injury.

formation and the steroid was changed to non-preserved dexamethasone 1% hourly by day.

At 6 days post-injury there was evidence of epithelial healing from the margin of the epithelial defect in the inferior fornix of the right eye. Topical citrate and ascorbate were stopped and treatment was altered to non-preserved topical medication only: topical dexamethasone 1% every 2 hours, chloramphenicol four times daily, and hypromellose every 2 hours. Autologous serum tears (diluted to 20% in sterile saline solution) were also commenced 2 hourly.

Two weeks after the injury there were persistent epithelial defects in both eyes but the healing edge of conjunctival epithelium had reached the nasal limbus in the right eye. Best corrected visual acuity was 6/24 right and 6/6 left. At this stage there was no pseudomembrane present although the conjunctiva remained inflamed.

By 4 weeks after injury the ocular surface in both eyes had re-epithelialised. The cornea of the right eye at this stage was clear with no vascularisation. Visual acuity remained 6/24 on the right.

Impression cytology of both central corneas was undertaken at this point. The right cornea showed conjunctival-type epithelium with scattered goblet cells, polymorphonuclear leucocytes, and numerous apoptotic bodies. The left cornea demonstrated a corneal phenotype epithelium.

The last review was at 6 months post-injury. Uncorrected visual acuity was 6/9 in both eyes. The conjunctiva of both eyes remained minimally inflamed with mild erythema, chemosis, and subepithelial fibrosis now evident. These changes were more marked in the right eye (Fig 3). There was superficial pannus encroaching onto the right cornea predominantly superonasally. The affected area in the left eye shows subconjunctival fibrosis with vascular disorganisation and localised scleral translucency (Fig 4). Current treatment was dexamethasone 1% twice daily in both eyes.

Comment

Paraquat is a dipyrilidium quaternary ammonium salt that acts as an indiscriminate killer of all plant life. Preparations made commercially commonly contain the related compound diquat as well as surfactants to increase distribution over the leaf and aid penetration. Toxicity in humans is thought to relate to paraquat recycling in the redox reaction (Fig 5). This depletes NADPH and interrupts cell metabolism. The reduced

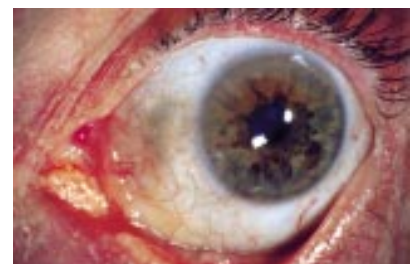

Figure 4 Left eye 6 months after injury.

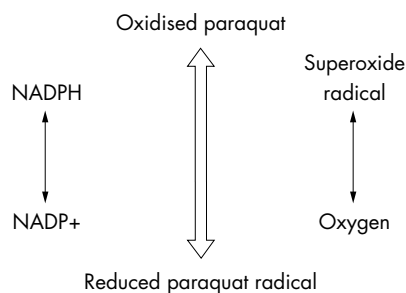


Figure 5 Redox cycling reaction with paraquat.

paraquat then reoxidises using oxygen to generate a superoxide radical.

The oxygen free radicals generated bind macromolecules and damage membrane lipids. Intracellular processes involving calcium are also affected. Paraquat may not be effectively cleared from the cell, resulting in persistent cell damage. Prolonged clinical effects lasting up to a year have been reported.

Documented cases of paraquat toxicity, although few, have noted a relatively mild initial appearance with a poor visual outcome in the long term. This has been the result of the development of a conjunctivalised corneal surface and chronic inflammation.^{1,3}

Paraquat ingestion can result in early fatality due to multiorgan failure. In less severe cases acute renal and hepatic toxicity is common. Pulmonary fibrosis may result in death. Pulsed methylprednisolone and cyclophosphamide during the inflammatory stages may have a profound effect on reducing the mortality.⁴ It is unclear whether a similar regimen would circumvent the long term sequelae of ocular paraquat injury.

The patient in this case had significant exposure to a commercial preparation with minimal first aid measures being implemented at the time of injury. He developed a severe surface injury over the first 48 hours with marked epithelial loss over one eye. This implied there were few, if any, viable limbal stem cells remaining. A severe pseudomembranous conjunctivitis then developed.

Previous reports of this extensive type of surface injury show that eventually conjunctivalisation of the cornea with vascular pannus is to be expected. Severe injury may result in a disordered ocular surface with dryness, symblepharon, ankyloblepharon, fornical shortening, entropion, and trichiasis.

Patients with total limbal stem cell loss invariably develop superficial pannus and conjunctivalisation of the cornea. Evidence that previously conjunctival phenotypic epithelium can transdifferentiate into corneal type epithelium is derived from animal experiments with a debrided cornea and limbus where corneal epithelium healed the resultant defect.⁵ Viable limbal stem cells may thus have remained in the perilimbal crypts of Vogt. The right eye of this patient healed from conjunctival epithelium, confirmed by impression cytology, although most of the cornea remains clear without pannus. It has been reported that transdifferentiation is inhibited once neovascularisation occurs.⁵ In the left eye, which only had a small zone of limbal stem cell loss if any, the epithelium over the cornea was confirmed as corneal phenotype on impression cytology and there was no vascularisation.

A suitable microenvironment for healing should be encouraged through the use of

medical therapy. Topical corticosteroids in the first week after injury promote successful healing of epithelial defects by controlling inflammation. Adequate lubrication is also important. Autologous serum tears have been reported to relieve the symptoms of dry eye⁶ and improve the ocular surface disease more successfully than conventional tear substitutes in dry eye states. These drops have also been instrumental in the healing of persistent epithelial defects.⁷ Essential components of the tear film present in serum tears include epidermal growth factor, vitamin A, and transforming growth factor β , which are important for the proliferation, differentiation, and maturation of the surface epithelium.⁷

We present a case of severe paraquat chemical injury to both eyes that had a good outcome from treatment. This case demonstrates a very good result from a usually devastating injury.

Preventing conjunctivalisation of the corneal surface after total loss of the limbal stem cell population remains a challenge. Therapeutic intervention may help restore a more functional surface visually. The use of intensive early antioxidant therapy followed by autologous serum tears and non-preserved ocular lubricants may have improved the outcome.

D McKeag

Corneal Unit, Royal Victorian Eye and Ear Hospital, Melbourne, Australia

R Maini, H R Taylor

Centre for Eye Research Australia, Melbourne, Australia

Correspondence to: Dr D McKeag, Royal Victorian Eye and Ear Hospital, 32 Gisborne Street, East Melbourne 3002, Melbourne, Australia

Accepted for publication 23 July 2001

References

- 1 Vlahos K, Coggin M, Coster D. Paraquat causes chronic ocular toxicity. *Aus NZ J Ophthalmol* 1993;**21**:187-90.
- 2 Brodovsky SC, McCarty CA, Snibson GS, et al. Management of alkali burns. An 11-year retrospective review. *Ophthalmology* 2000;**107**:1829-35.
- 3 Joyce M. Ocular damage caused by paraquat. *Br J Ophthalmol* 1969;**53**:688-90.
- 4 Lin JL, Leu ML, Liu YC, et al. A prospective clinical trial of pulse therapy with glucocorticoid and cyclophosphamide in moderate to severe paraquat-poisoned patients. *Am J Respir Crit Care Med* 1998;**159**:357-60.
- 5 Tseng SCG, Hirst LW, Farazdaghi M, et al. Goblet cell density and vascularisation during conjunctival transdifferentiation. *Invest Ophthalmol Vis Sci* 1984;**25**:1168-76.
- 6 Tsubota K, Goto E, Fujita H, et al. Treatment of dry eye by autologous serum application in Sjogren's syndrome. *Br J Ophthalmol* 1999;**83**:390-5.
- 7 Tsubota K, Goto E, Shimmura S, et al. Treatment of persistent corneal epithelial defects by autologous serum application. *Ophthalmology* 1999;**106**:1984-9.

Henoch-Schonlein purpura with bilateral central retinal artery occlusion

Henoch-Schonlein (H-S) purpura is an acute leucocytoclastic vasculitis that primarily affects children and mainly involves skin, joints, gastrointestinal tract, and kidney.¹ Reported ophthalmic manifestations of Henoch-Schonlein purpura include episcleritis, scleritis, keratitis, anterior uveitis, and central reti-

nal vein occlusion.²⁻⁴ However, central retinal artery occlusion, to the best of our knowledge, have not been reported. We report on a girl with H-S purpura complicated with bilateral central retinal artery occlusion.

Case report

A 6 year old girl visited our paediatric department with the chief complaint of multiple erythematous rashes over the lower extremities and buttock for 2 weeks. Under a presumptive diagnosis of H-S purpura, oral prednisolone was prescribed. Nevertheless, arthralgia, haematuria, and moderate hypertension developed 3 weeks later. The histopathological findings of renal biopsy were compatible with H-S purpura nephritis. Unfortunately, acute renal failure occurred despite aggressive systemic treatment and haemodialysis was started.

Two days before haemodialysis, the patient noticed sudden visual loss. Visual acuity was hand movement in both eyes. Anterior segment and intraocular pressure were normal. Fundus examination revealed a cherry red spot with severe retinal oedema at the macular and peripapillary area in both eyes. Disc oedema and venous engorgement were also noted in both eyes (Figs 1 and 2). The retinal manifestations were compatible with bilateral central retinal artery occlusion. Fundus fluorescein angiography was not performed because of her poor general condition.

Three days after haemodialysis, her systemic condition deteriorated with drowsiness that was proved to be cerebral vasculitis by brain computed tomography.

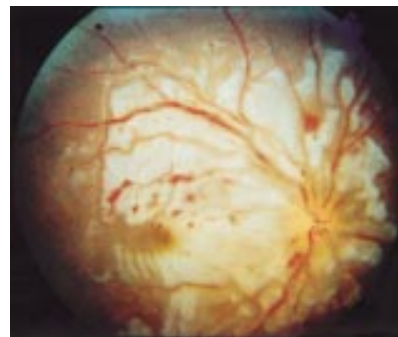


Figure 1 Fundus photograph of the right eye demonstrating cherry red spot with severe retinal oedema at macular and peripapillary area, disc oedema, and venous engorgement.

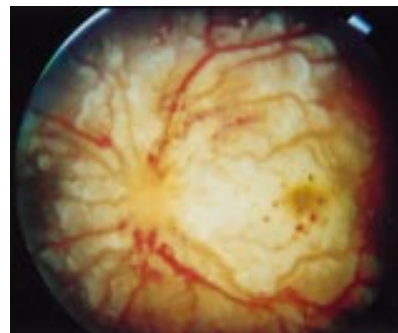


Figure 2 Fundus photograph of the left eye demonstrating cherry red spot with severe retinal oedema at macular and peripapillary area, disc oedema, and venous engorgement.

One month later, her visual acuity was counting finger in both eyes. Fundus examination revealed a pale disc, arterial sheathing, and drusen-like RPE change at foveal area in both eyes. Six months later, her best correction visual acuity was 6/30 in the right eye, and 6/60 in the left.

Comment

The dominant clinical manifestations of H-S purpura are cutaneous purpura (100%), abdominal pain (63%), gastrointestinal bleeding (33%), and nephritis (40%).² In general, H-S purpura is an acute, self limiting illness though one third of patients will have one or more recurrences of symptoms. H-S purpura was the cause of renal failure in 2% and 5% of groups of children undergoing haemodialysis in California and France, respectively.⁵ Although the aetiology of H-S purpura remains unknown, it is clear that IgA has a critical role in the immunopathogenesis. The clinical features of H-S purpura are a consequence of widespread leucocytoclastic vasculitis due to IgA deposition in vessel walls.⁶ Treatment is limited to symptomatic and supportive care. Corticosteroids are often used depending on the severity of the disease.

According to the previous reports, the ocular manifestations of H-S purpura are rare, including episcleritis, scleritis, keratitis, anterior uveitis, and central retinal vein occlusion.²⁻⁴ In this case, H-S purpura vasculitis may have an important role in the pathogenesis of bilateral central retinal artery occlusion. To our knowledge this might be the first case of H-S purpura complicated with bilateral central retinal artery occlusion in the literature.

T-T Wu, S-J Sheu, L-C Chou

Department of Ophthalmology, Kaohsiung Veterans General Hospital, Kaohsiung, Taiwan

T-T Wu, S-J Sheu

School of Medicine, National Ying-Min University, Taipei, Taiwan

S-J Sheu

Chung-Hwa Institute of Technology, Tainan, Taiwan

Correspondence to: Tsung-Tien Wu, MD, Department of Ophthalmology, Kaohsiung Veterans General Hospital, 386 Ta-chung 1st Road, Kaohsiung, Taiwan 813; ttwu@isca.vghks.gov.tw

Accepted for publication 23 July 2001

References

- 1 **Saulsbury FT.** Henoch-Schonlein purpura. *Pediatric Dermatol* 1984;1:195-201.
- 2 **Saulsbury FT.** Henoch-Schonlein purpura in children. Report of 100 patients and review of the literature. *Medicine* 1999;78:395-409.
- 3 **Yamabe H, Ozawa K, Fukushi K.** IgA nephropathy and Henoch-Schonlein purpura nephritis with anterior uveitis. *Nephron* 1988;50:368-70.
- 4 **Barton CH, Vaziri ND.** Central retinal vein occlusion associated with hemodialysis. *Am J Med Sci* 1979;277:39-47.
- 5 **Farley TA, Gillespie S, Rasoulpour M.** Epidemiology of a cluster of Henoch-Schonlein purpura. *Am J Dis Child* 1989;143:798-803.
- 6 **Allen AC, Willis FR, Beattie TJ.** Abnormal IgA glycosylation in Henoch-Schonlein purpura restricted to patients with clinical nephritis. *Nephrol Dial Transplant* 1998;13:903-4.

Primary iris pigment epithelial hyperplasia and glaucoma

Primary iris pigment epithelial hyperplasia (PIPH) is a rare condition characterised by the presence of iris pigment epithelium on the anterior surface of the iris stroma. There are

few reports that are available in the literature¹⁻¹¹ and they generally refer to it as congenital ectropion uveae (CEU). CEU, however, is a misnomer, since the iris pigment layer is known to be separate from the uvea.⁷ Yet, the term CEU persists in clinical use.

Primary iris pigment epithelial hyperplasia is a congenital non-progressive condition that is easily differentiated from acquired progressive ectropion uveae, the latter resulting from tractional eversion of posterior pigment layer and sphincter muscle, secondary to glaucoma and/or uveitis.

The most common association is neurofibromatosis^{8,9,12} though other ocular^{7,10} and systemic associations^{8,9} have been described, including a chromosomal abnormality.⁶

This report describes two cases of primary iris pigment epithelial hyperplasia with glaucoma and reviews the available literature on this rare abnormality. In one case the presentation of glaucoma was in adolescence and in infancy in the other. Associated ocular features are described. In these two patients there were no systemic features of diagnostic significance.

Case 1

A 15 year boy presented with occasional watering in the left eye for 4 years. There was no history of any visual disturbance.

On examination his left eye was apparently proptosed and Hertel exophthalmometry readings were 19 mm in the left eye and 13 mm in the right with bar reading of 105. He had a ptosis of 2 mm (Fig 1, top right) with good levator function. The appearance of the left upper lid was suggestive of plexiform neurofibroma but no mass was palpable. The patient's vision was 20/20 right eye (emmetropic) and 20/25 left eye (cylinder of -1.50 D at 110°, keratometry left eye -42.00 × 15°, 45.5 × 105°).

The left eye had extensive hyperplasia of the iris pigment epithelium which overlay the stroma of the iris in an irregular manner but did not reach the angle (Fig 1, top left). The normal iris architecture was lost, but no nodules were seen. There was pigment on the anterior surface of the lens but the iris did not transilluminate. There was anisocoria of 1.5 mm, the left pupil being larger but round, regular and reacting to light. Indirect gonioscopy (Fig 1, bottom left) demonstrated an open angle with iridotrabeculodysgenesis in the form of an anterior insertion of the iris into the trabecular meshwork with excessive pigment deposition and a prominent Schwalbe's line, this being very marked in some areas. The right eye had a fully open angle with all structures clearly seen. Intraocular pressure (IOP) on the first examination was 52 mm Hg in the left eye and 12 mm Hg in the right. On fundus examination there was an oblique insertion of the disc, with inferonasal crescent and an oval oblique cup involving 0.8:1 × 0.6:1 part of the disc (Fig 1, bottom right). A B-scan ultrasound of orbit did not reveal any abnormality and the A-scan biometry confirmed that the apparent proptosis of the left eye was due to a longer axial length (24.36 mm compared with 22.60 mm in the right eye). There were two café au lait spots on the trunk but there was no other systemic abnormality. None of the family members had similar ocular findings or any evidence of neurofibromatosis.

The IOP responded poorly to topical medication and a trabeculectomy was performed which controlled the IOP.

Case 2

A 5½ year old girl presented with gradual enlargement of the right eye since the age of 6 months. There was a history of mild photophobia but none of lacrimation or deterioration of vision.

On examination the patient's Snellen acuity was 20/240 in the right eye (-1.5D sph, -4.0D

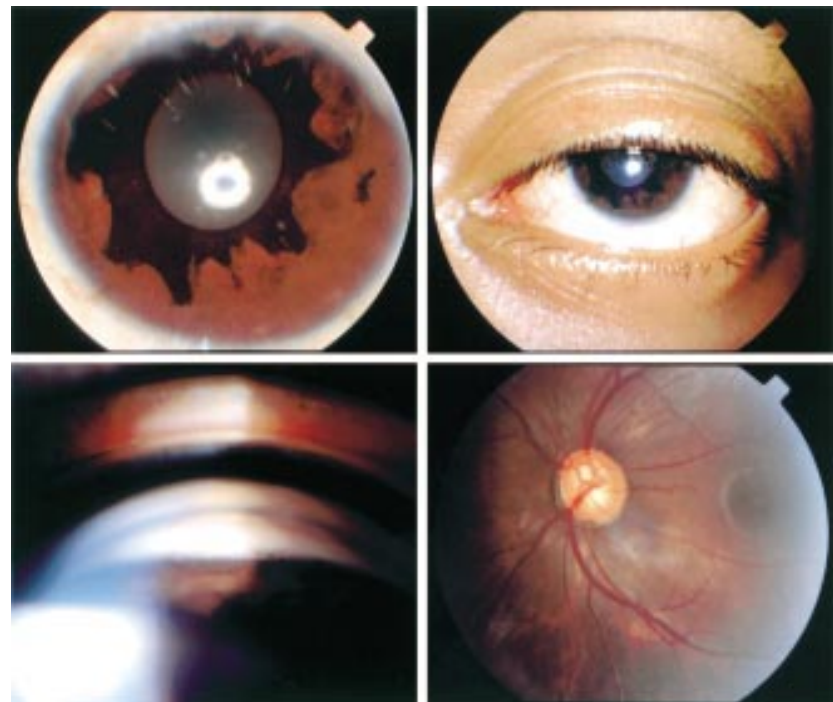


Figure 1 Case 1 with PIPH and associated abnormalities. Top left: Extensive hyperplasia of iris pigment epithelium overlying the stroma; top right: associated ptosis; bottom left: indirect gonioscopy demonstrated anterior insertion of iris with excessive pigment deposition; bottom right: oblique insertion of disc with an inferonasal crescent and an oval cup.

cyl × 90°) and 20/20 in the left eye (−0.25D cyl × 90°). The right eye was buphthalmic with a corneal diameter of 13.0 × 14.0 mm (10.5 × 11.5 mm, left eye). The right eye had extensive hyperplasia of the iris pigment epithelium overlying the stroma of the iris in an irregular manner, but this did not reach the angle. The normal architecture of the iris was lost but there were no iris nodules. The angle was examined with a direct gonioscope and the findings were similar to that of case 1. The right pupil was 6 mm in diameter and did not react to light and was less responsive to miotics and mydriatics.

Intraocular pressure was 27 mm Hg in the right eye (on oral acetazolamide and topical timolol and propine) and 14 mm Hg in the left eye. Fundus examination of the right eye revealed a 0.9:1 cupping of the optic disc with a significant pallor of the neuroretinal rim and bayonetting of the vessels. A-scan biometry demonstrated an axial length of 26.0 mm in the right eye and 22.07 mm in the left.

No systemic abnormality was detected. No sibling, parent, or near relative was similarly affected.

A combined trabeculotomy and trabeculectomy without any pharmacological modulation was performed on the right eye and a diffuse bleb and a well formed anterior chamber was seen on fourth postoperative day but intraocular pressure was unrecordably low. The patient's vision at 4 weeks postoperatively was 20/200.

Comment

In the normal iris the pigment epithelium forms a double layer that includes itself into the pupillary margins as the pigmented ruff. A congenital exaggeration of this process occurs where the pigmented layer advances over the anterior surface of the iris to a varying degree.¹⁰ The extent to which the pupillary circumference is involved in PIPH is variable,^{9,11} but characteristically ends short of the angle.⁹ The pupil may be normal in size in some cases and larger than its counterpart in others.⁷ It may be round and reactive to light but may be oval⁹ and less reactive to light.⁷ The iris stroma is generally hypoplastic to a variable degree,⁹ with a smooth anterior surface with absence of circular concentric furrows and radial folds.⁷ The condition is usually unilateral^{7,9–11} but a bilateral case has been reported.⁸

Both the cases in this report had extensive PIPH, loss of normal iris architecture, and pupillary abnormalities.

The aetiology of the condition remains unknown but is probably due to imbalance of growth between the ectoderm and the mesoderm, usually a hyperplasia of the former.¹¹ It may represent a clinical manifestation of a pathological process related to abnormal neural crest cell migration.⁷

Histological studies have shown that the eversion is the result of hyperplasia of the pigment epithelial layer.⁷ There is no evidence that the condition is hereditary in uncomplicated cases, however, those which are associated with conditions such as Rieger's dysgenesis may be transmitted in the same way as the major deformity.¹¹

A variety of systemic disorders have been reported in association with PIPH. Neurofibromatosis is the disorder most commonly associated with PIPH.^{8,9,12} In one report⁹ three out of eight were associated with neurofibromatosis. In addition, Ritch *et al*⁹ reported neurofibromatosis, a case of associated diabetes mellitus and left facial hemiatrophy, and one each of Prader-Willi syndrome and

right facial hemiatrophy. Hetzbert⁸ reported a case with associated asthma and a dental anomaly.

Not all cases have systemic associations. None of the nine patients reported by Dowling *et al*⁷ had any systemic associations. None of the two cases in this report had any identifiable systemic association.

Besides the iris and pupillary abnormalities discussed above, PIPH is frequently associated with significant ocular abnormalities. Ipsilateral mild ptosis with good levator function was presented in six of nine cases reported by Dowling *et al*⁷ and in one case each by Ritch *et al*⁹ and Herzberg.⁸ The eye may be slightly proptotic in some cases.⁹ The appearance of the upper lid may suggest plexiform neuroma even though no mass may be palpable.⁹ All these features were present in the first case in this report.

Angle anomalies appear to be universal in most of the cases demonstrating anterior insertion of the iris,^{7,9} a prominent Schwalbe's line, prominent iris processes and/or increased pigment,⁹ and a similar iridotrabeulodysgenesis was present in both the cases in this present report.

Glaucoma was present in most of the cases reported. Ritch *et al*⁹ found glaucoma in seven out of eight cases of PIPH, Dowling *et al*⁷ in eight of nine cases, and it was also noted and in other reported cases of PIPH.^{2,3,5,6,8,10,12} It is usually of onset in childhood or early adolescence as was seen in cases in this report but cases with late onset also has been reported.^{1,7,10} The intraocular pressure shows an initial decrease when the medication is instituted but rises again quickly and filtering surgery was required in most cases.⁷

Surgical intervention was necessary in both the cases in this report.

The features of PIPH detailed in this report are in concordance with those previously published. There may be other associated ocular abnormalities, ptosis being the commonest. Neurofibromatosis is the most frequently associated systemic disorder.

Glaucoma may develop at any stage, therefore these cases should be recognised early by healthcare professionals and followed for development of glaucoma.

A Bansal, J Luck

Department of Ophthalmology, Royal United Hospital, Bath BA1 3NG, UK

Correspondence to: Atul Bansal; bansalatul@yahoo.com

Accepted for publication 6 August 2001

References

- 1 Mandai AK. Late-onset unilateral primary developmental glaucoma associated with iridotrabeulodysgenesis, congenital ectropion uveae and thickened corneal nerves: a new neural crest syndrome? *Ophthalmic Surg Lasers* 1999;**30**:567–70.
- 2 Dietlein TS, Jacobi PC, Krieglstein GK. Primary congenital ectropion uveae associated with vitreoretinal degeneration. *Ophthalmologica* 1998;**212**:63–5.
- 3 Candaele C, Lefevre A, Meire F, *et al*. Congenital ectropion uveae with glaucoma. *Bull Soc Belge Ophthalmol* 1993;**249**:131–7.
- 4 Futterweit W, Ritch R, Teekhasaene C, *et al*. Coexistence of Prader-Willi syndrome, congenital ectropion uveae with glaucoma, and factor XI deficiency. *JAMA* 1986;**255**:3280–2.
- 5 Levin H, Ritch R, Barathur R, *et al*. Aniridia, congenital glaucoma, and hydrocephalus in a male infant with ring chromosome 6. *Am J Med Genet* 1986;**25**:281–7.
- 6 Bechettille A, Ebran JM, Bigorgne. Congenital ectropion of the iris epithelium and glaucoma. *J Fr Ophthalmol* 1985;**8**:529–34.

- 7 Dowling JL Jr, Albert DM, Nelson LB, *et al*. Primary glaucoma associated with iridotrabeulodysgenesis and ectropion uveae. *Ophthalmology* 1985;**92**:912–21.
- 8 Hertzberg R. Congenital ectropion uveae and glaucoma. *Aust NZ J Ophthalmol* 1985;**13**:45–8.
- 9 Ritch R, Forbes M, Hetherington J Jr, *et al*. Congenital ectropion uveae with glaucoma. *Ophthalmology* 1984;**91**:326–31.
- 10 Quigley HA, Stanish FS. Unilateral congenital iris pigment epithelial hyperplasia associated with late-onset glaucoma. *Am J Ophthalmol* 1978;**86**:182–4.
- 11 Duke-Elder S. Normal and abnormal development. Congenital deformities. In: *System of ophthalmology*. Vol 3, Pt 2. St Louis: CV Mosby, 1964:599–600.
- 12 Wolter JR, Butler RG. Pigment spots of the iris and ectropion uveae with glaucoma in neurofibromatosis. *Am J Ophthalmol* 1963;**56**:964–73.

Unilateral vitreous haemorrhage secondary to caudal epidural injection: a variant of Terson's syndrome

Terson's syndrome is characterised by vitreous haemorrhage accompanying subarachnoid or any other form of intracranial haemorrhage. Although Litten reported vitreous haemorrhage in association with subarachnoid haemorrhage in 1881, it was Terson who described the syndrome in 1900. Haemorrhage in Terson's syndrome may be contained between the internal limiting membrane and retina or extend into the vitreous cavity. Other findings include multiple preretinal, intraretinal, subretinal haemorrhages, as well as macular rings¹ and epiretinal membranes.²

Case report

A 47 year old man with chronic back pain due to epidural adhesions (confirmed in magnetic resonance imaging (MRI)) was referred to the anaesthetic department for caudal epidural injection of steroids and saline to break up the epidural adhesions for pain relief. He received the injection through the sacral hiatus between the spinal dura and spinal canal in the caudal epidural space under general anaesthesia. Following recovery from general anaesthesia, he stated that he had lost the sight in his left eye. Ophthalmic examination at that time confirmed vision of 6/6 right eye and 6/60 left eye with no afferent pupillary defect, normal anterior segments, and the presence of a dense left vitreous haemorrhage with a normal right eye. There were no other predisposing factors for vitreous haemorrhage. Post-epidural MRI scan of brain and spinal cord was performed. There was no intracranial haemorrhage but the epidural adhesions were still noted to be present. The patient's vision gradually improved to 6/12 over a 3 year period but because of residual severe symptomatic floaters he underwent left pars plana vitrectomy, which allowed his vision to improve to 6/6 unaided.

Comment

Terson³ proposed that intraocular haemorrhage occurred secondary to intracranial hypertension, which resulted in elevated peripapillary capillary pressure. The most commonly cited mechanism is that elevated intracranial pressure⁴ resulting from subarachnoid haemorrhage is transmitted within the optic nerve sheath and obstructs intraocular venous drainage causing distension and rupture of peripapillary and retinal capillaries resulting in significant haemorrhage in the subhyaloid space or vitreous cavity.

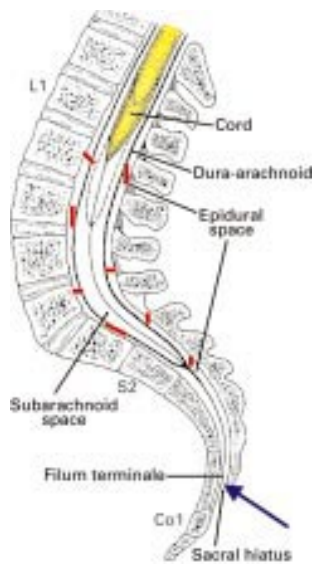


Figure 1 Site of injection is shown by blue arrow, compartments formed by the adhesions shown by red markings.

In our patient during the caudal epidural injection the fluid wave of injection did not spread uniformly in the epidural space and break the adhesions but, instead, got trapped in tiny compartments formed by the adhesions and caused lateral pressure on the spinal cord, thus increasing subarachnoid space pressure, resulting in vitreous haemorrhage in the left eye (Fig 1).

Therefore, we feel the cases with pathogenesis of intraocular haemorrhage, secondary to a sudden rise of intracranial pressure, should be considered as the variant of Terson's syndrome.

The clinical course of Terson's syndrome is typically one of gradual resolution of the vitreous haemorrhage and return of normal vision. Haemorrhages that do not resolve may require vitrectomy, but several studies have proposed that early vitrectomy also may improve visual outcome.⁵

Indications for early pars plana vitrectomy⁶ include vitreous haemorrhage in infants (prevent amblyopia) and in adults with bilateral vitreous haemorrhage. Indications for conservative management include rapidly clearing vitreous haemorrhage, mild haemorrhage, unilateral cases with normal vision in the fellow eye, and pre-existing ocular damage precluding a favourable visual outcome.

S Gibran, K Mirza, F Kinsella
Eye Clinic, University College Hospital, Galway, Ireland

Correspondence to: Dr Gibran; syedgibran@yahoo.com
Accepted for publication 15 August 2001

References

- 1 Sadeh AD, Lazar M, Loewenstein A. Macular ring in a patient with Terson's syndrome. *Acta Ophthalmol Scand* 1999;**77**:599-600.
- 2 Weingeist TA, Goldman EJ, Folk JC, et al: Terson's syndrome: clinicopathologic correlations. *Ophthalmology* 1986;**93**:1435.
- 3 Terson A. De l'hémorragie dans le corps vitre au corps de l'hémorragie cérébrale. *Clin Ophthalmol* 1900;**6**:309.
- 4 Medele RJ, Stummer W, Mueller A, et al. Terson's syndrome in subarachnoid hemorrhage and severe brain injury accompanied by acutely raised intracranial pressure. *J Neurosurg* 1998;**88**:851-4.
- 5 Augsten R, Konigsdorffer E, Strobel J. Surgical approach in Terson syndrome: vitreous and retinal findings. *Eur J Ophthalmol* 2000;**10**:293-6.
- 6 Schultz PN, Sobol WM, Weingeist TAL. Long-term visual outcome in Terson's syndrome. *Ophthalmology* 1991;**98**:1814.

Severe macular pucker after retinal detachment surgery in an infant

The appearance and clinical course of rhegmatogenous retinal detachments in children are more complicated than those of adults, because the retinal detachments are generally associated with trauma or congenital anomalies.^{1,2} In an infant, especially, an unexpected course may develop; however, the incidence of these detachments is so low that treatment and complications have scarcely been described in the literature. We report an infant who developed severe macular pucker after retinal detachment surgery.

Case report

A 2 week old male infant was referred with a diagnosis of bilateral congenital cataracts. The pregnancy and delivery had been uncomplicated. His mother also had had congenital cataracts. Both eyes of the infant had dense zonular cataracts. The patient had no associated ocular problems on slit lamp biomicroscopy or gonioscopy and no abnormalities on physical examination. He underwent bilateral lensectomy and anterior vitrectomy by limbal approach at 3 weeks of age; both fundi were unremarkable. Although his right eye underwent sufficient anterior vitrectomy, retropupillary membrane developed on the residual

vitreous surface and the pupil closed 3 months postoperatively. During the second surgery, pupilloplasty was performed and we found a tear in the ciliary epithelium of the pars plana resulting from traction of the retropupillary membrane tissue, and also discovered a localised detachment of the retina and ciliary epithelium (Fig 1A). We performed cryopexy with encircling scleral buckle, vitrectomy, and fluid-air exchange, and the retina was reattached. One month later, macular pucker rapidly developed and enfolded the entire posterior retina (Fig 1B). The original tear was completely sealed, and signs of the recurrent rhegmatogenous retinal detachment with proliferative vitreoretinopathy, including vitreous haze and wrinkling of retina in the other location, were not identified. After additional vitrectomy to remove residual cortex and to perform membrane peeling, the retina was finally reattached with a residue of degeneration near the fovea (Fig 1C).

Haematoxylin and eosin and Azan stains and transmission electron microscopy of the surgically removed membrane showed pigmented cells, fibroblast-like cells, vessels, and collagen fibres (Fig 2A). The membrane was immunostained with antibodies for cytokeratin and α -smooth muscle actin (Fig 2B, C), while there was slight immunoreactivity for vimentin and no immunoreactivity for glial fibrillary acidic protein or desmin. The membrane also contained vessels, which was confirmed by positive immunoreactivity for Von Willebrand factor (Fig 2D).

Comment

Macular pucker in this infant is significantly different from that in adults. The severe posterior retinal folds may be formed by strong contraction of the epiretinal membrane, a firm vitreoretinal juncture, and an extensible retina. A previous histopathological report on recurrent proliferation after vitrectomy in two children with tractional retinal detachments showed that retinal glial cells were the main reactive cells.³ However, in our case, the major component of the pucker was retinal pigment epithelium (RPE) cells, the same as in adults with rhegmatogenous retinal detachment.^{4,5} Cytoplasmic actin within the membrane, rather residual vitreous cortex on the retinal surface, may be involved in forming strong contractile elements, which also may underlie idiopathic cases in children.⁶ Vessels in the pucker may have originated from the adherent retina, because no residual hyaloid vessels were identified during surgery.

Because excessive cryopexy tends to disperse and activate RPE cells, minimal cryopexy is recommended; laser may be preferable

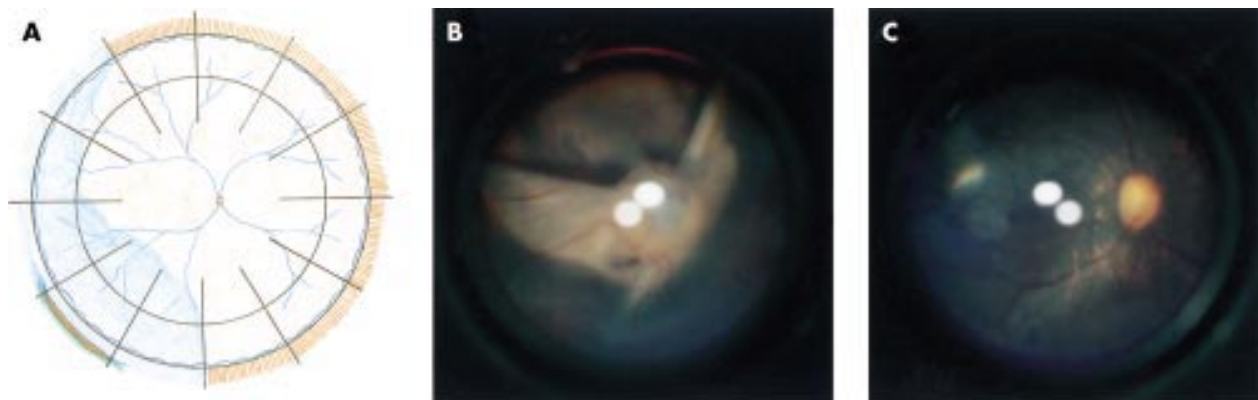


Figure 1 (A) Schema of retinal detachment in the right eye. Ciliary epithelial tear is observed between the 7 and 8 o'clock positions. (B) Macular pucker enfolded the entire posterior retina and covers the optic disc. (C) Postoperative fundus with residual retinal degeneration.

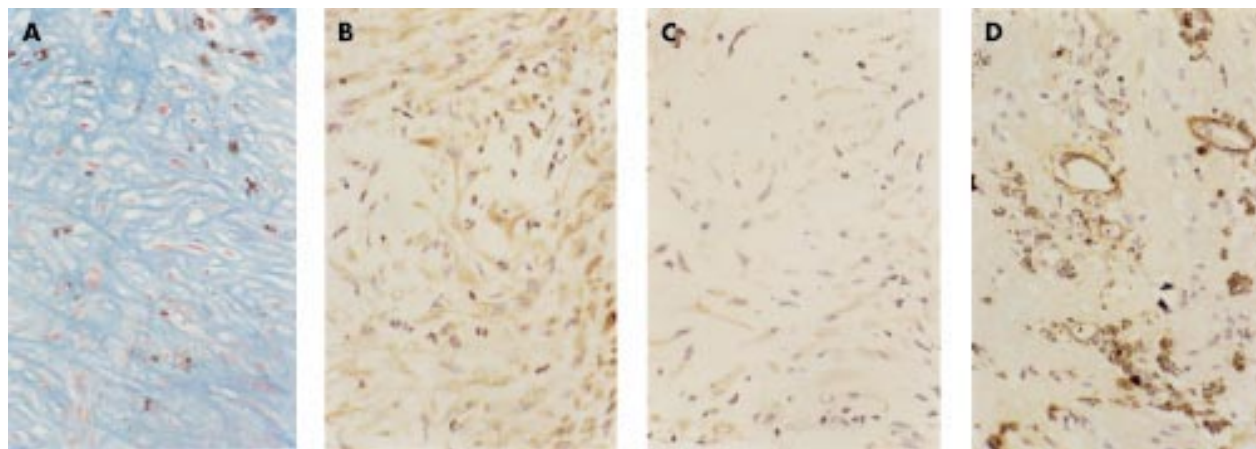


Figure 2 (A) Light micrograph shows pigmented cells, fibroblast-like cells, and collagen (Azan, original magnification $\times 100$). Positive immunostaining for cytokeratin (B) and α -smooth muscle actin (C) is seen prominently in the membrane. (D) Positive staining for Von Willebrand factor shows the vessels (peroxidase-antiperoxidase, original magnification $\times 100$).

to treat rhegmatogenous retinal detachment in infants. Enzyme assisted vitrectomy to separate the firm vitreoretinal juncture may prevent the development of subsequent macular pucker. Frequent examinations and careful management are required even after successful reattachment surgery.

S Nishina, N Azuma

Department of Ophthalmology, National Children's Hospital, Tokyo, Japan

Correspondence to: Noriyuki Azuma, MD, Department of Ophthalmology, National Children's Hospital, 3-35-31 Taishido, Setagaya-ku, Tokyo, 154-8509, Japan; nazuma@nch.go.jp
Accepted for publication 16 August 2001

References

- 1 Winslow RL, Tasman W. Juvenile rhegmatogenous retinal detachment. *Ophthalmology* 1978;**85**:607-18.
- 2 Lemrini F, Dafallah L, Kabbaj A. Retinal detachment surgery in children. *J Fr Ophthalmol* 1993;**16**:159-64.
- 3 De Juan E Jr, Lambert HM, Machemer R. Recurrent proliferations in macular pucker, diabetic retinopathy, and retrolental fibroplasia-like disease after vitrectomy. *Graefes Arch Clin Exp Ophthalmol* 1985;**23**:174-83.
- 4 Clarkson JG, Green WR, Massof D. A histopathologic review of 168 cases of preretinal membrane. *Am J Ophthalmol* 1977;**84**:1-17.
- 5 Kampik A, Kenyon KR, Michels RG, et al. Epiretinal and vitreous membranes. Comparative study of 56 cases. *Arch Ophthalmol* 1981;**99**:1445-54.
- 6 Smiddy WE, Michels RG, Gilbert HD, et al. Clinicopathologic study of idiopathic macular pucker in children and young adults. *Retina* 1992;**12**:232-6.

Microbial keratitis associated with extended wear of silicone hydrogel contact lenses

Traditional hydrogel soft contact lenses (SCL) have limited oxygen permeability.^{1,2} Recently introduced silicone hydrogel SCL have much higher oxygen transmissibility (Dk/t O₂), allowing near normal oxygen supply to the cornea during extended lid closure, and are hoped by some to address most of the problems related to corneal hypoxia encountered with previous extended wear soft contact lenses.^{1,3} They have therefore been approved for up to 30 days of continuous wear in both Europe and Australia.

Four cases of microbial keratitis in patients who were using silicone hydrogel SCL (either CibaVision Focus Night and Day lenses (Lotrafilcon A, fluorosiloxane hydrogel) or Bausch & Lomb PureVision lenses (Balafilcon A, silicone hydrogel)) on an extended wear basis are presented. The minimum amount of continuous wear was 24 hours. All cases were treated either in private or at the corneal clinic of the Royal Victorian Eye and Ear Hospital from December 2000 to February 2001. All the patients underwent a complete ophthalmic examination by a corneal specialist. Microbiological specimens were taken from all patients via cornea scrapings and were submitted for Gram and Blankophor staining, and bacterial and fungal cultures via direct inoculation onto sheep blood agar, chocolate agar, and Sabouraud agar. Bacterial sensitivities of cultured organisms were also obtained. Where possible, the contact lenses themselves were also sent for microbial cultures.

Each case is described in brief, and a summary presented in Table 1.

Case 1

This 22 year old man presented with a 2 day history of left ocular injection, pain, photophobia, and blurred vision. He was wearing CibaVision Focus Night and Day SCL continuously for 10 days at a time, discarding the lenses after a month of use. He had swum in the sea while wearing the same lenses 2 weeks before, after which he removed the lenses and disinfected them in "Complete Comfort Plus" multipurpose solution (poly-hexamethyl biguanide, poloxamer, hypromellose, edetate disodium, sodium phosphate dibasic and monobasic, sodium chloride, potassium chloride, purified water, manufactured and distributed by Allergan Australia, Sydney). Continuous wear was recommenced the next morning.

Examination revealed a visual acuity with his spectacle correction of 6/4-2 right eye and 6/9 left eye. The left eye had a central, 1 mm corneal epithelial defect with an underlying dense infiltrate. Marked ciliary injection and anterior chamber activity were present with 3+ cells and multiple inferior keratic precipitates (KP).

Serratia marcescens grew on the sheep blood agar plate from the corneal scrapings and the contact lens. It was sensitive to ciprofloxacin, tobramycin, and chloramphenicol.

Hourly topical ciprofloxacin 0.3% (Ciloxan, Alcon, Fort Worth, TX, USA) was commenced,

with marked symptomatic improvement and resolution of the anterior chamber inflammation after 48 hours. Treatment was tapered and unpreserved prednisolone phosphate 0.5% drops were added four times daily. Review 2 weeks later revealed a best corrected visual acuity of 6/6-1 in both eyes, and a central subepithelial scar

Case 2

A 16 year old boy presented with a 24 hour history of left eye grittiness, marked photophobia, and hazy vision. He was wearing PureVision SCL on a monthly continuous wear basis. He gave a history of swimming in a river in these lenses 1 week earlier, after which he removed the lenses and disinfected them with "Renu" multipurpose solution (boric acid, edetate disodium, poloxamine, sodium borate, sodium chloride, and polyaminopropyl biguanide, manufactured and distributed by Bausch & Lomb, Greenville, SC, USA). Continuous wear was recommenced within a few hours.

Examination revealed an uncorrected visual acuity of 3/60 in both eyes, improving to 6/12 in both eyes with pinhole. A paracentral 1 mm epithelial defect with underlying dense infiltrate was noted in the left eye with anterior chamber inflammation of 1+ cells and multiple scattered KP (Fig 1).

Corneal scrapings revealed fungal elements on Gram and Blankophor staining. Cultures grew *Acinetobacter* species in the enrichment broth, sensitive to ciprofloxacin, chloramphenicol, and tobramycin. *Penicillium* was later grown on the Sabouraud agar slope. A yeast (not *Candida albicans*) was grown on Sabouraud agar from the left contact lens, with *Penicillium* species grown from the right.

Topical ciprofloxacin 0.3% was commenced hourly, after which his symptoms and signs markedly improved. The ciprofloxacin was tapered and changed to topical chloramphenicol 0.5% (Chlorsig, Sigma) 8 days after presentation.

Two weeks later, the epithelial defect had resolved but significant subepithelial scarring remained. His best corrected visual acuity was 6/6 right eye and 6/7.5 left eye.

Case 3

A 21 year old man was referred to MSL with a 2 day history of right eye injection, pain, photophobia, and decreased vision. He was wearing PureVision lenses on a daily wear basis, but changed to continuous wear 24 hours before the onset of his symptoms.

Table 1 Summary of case details

	Patient details			
	Case 1	Case 2	Case 3	Case 4
Sex	Male	Male	Male	Male
Age	22	16	21	17
Eye	Left	Left	Right	Left
Refraction	-1.75/-0.25x50	-4.50	-3.50	-5.00/-1.50x5
Lens brand	CibaVision Focus Night and Day	Bausch & Lomb Pure Vision	Bausch & Lomb PureVision	CibaVision Focus Night and Day
Duration of EWSCL use	12 months	12 months	6 weeks	12 months
Pattern of wear	Monthly continuous wear	Monthly continuous wear	Daily wear, changing to 24 hours' continuous wear just before presentation	Monthly continuous wear
Duration of wear	10 days	7 days	24 hours	2 days
Microscopy	Insufficient specimen, no PMN or organisms seen	Fungal elements on Blankophor preparation. No organisms on Gram stain	PMN +, no organisms seen	No PMN, no organisms seen
Culture	<i>Serratia marcescens</i> (sheep blood agar plate)	<i>Acinetobacter</i> (enrichment broth) <i>Penicillium</i> (Sabouraud agar)	Heavy growth of <i>Corynebacterium</i> (sheep blood agar plate)	α Haemolytic streptococcus, in enrichment broth
Contact lens culture	<i>Serratia marcescens</i>	Yeast from left lens; <i>Penicillium</i> from right lens	Not available	No growth
Other risk factors	Swam in lenses 2 weeks earlier	Swam in lenses 1 week earlier		Swam in a different pair of lenses 3 days earlier
Last corrected VA (time)	VAR=6/6-1 (2 weeks)	VAL=6/7.5 (8 days)	Unavailable	VAL=6/7.5 (1 week)

Examination revealed a visual acuity of 6/6 right eye and 6/5 left eye with his spectacle correction. Marked right eye ciliary injection and anterior chamber activity were noted with cells, flare, multiple scattered KPs, and a small paracentral epithelial defect with underlying infiltrate.

Corneal scrapings revealed polymorphs on Gram stain (no organisms seen), and a heavy growth of *Corynebacterium* species on the sheep blood agar plate, sensitive to penicillin, ciprofloxacin, and chloramphenicol. Culture of the contact lenses was impossible as they had been discarded.

Treatment consisted of hourly topical ciprofloxacin 0.3%. Topical fluoromethalone acetate 0.1% (Flarex, Alcon, Fort Worth, TX, USA) was added four times daily after clinical improvement 24 hours later. All treatment was tapered and ceased after 2 weeks.

The patient failed to attend for any further follow up appointments but on contact by telephone stated his vision had returned to normal.

Case 4

A 17 year old presented with a 5 day history of left eye redness, irritation, photophobia, and blurred vision. He was wearing CibaVision Focus Night and Day SCL on a monthly continuous wear basis and gave a history of swimming in a river with a previous pair of lenses 3 days before the onset of symptoms.



Figure 1 Case 2, left eye 1 day after presentation.

These lenses were discarded and replaced with his current lenses the next day.

Initial treatment by the general practitioner consisted of topical chloramphenicol (0.5%) drops 2 hourly by day and chloramphenicol (1%) ointment (Chlorsig, Sigma) at night.

Examination revealed a visual acuity of 6/6 right eye (with SCL) and 3/36 left eye unaided, improving to 6/18 with pinhole. Conjunctival injection was noted in the left eye, with a 3 x 4 mm paracentral area of stromal haze and an associated area of subepithelial infiltrate. The overlying epithelium was intact.

Corneal scrapings revealed no polymorphs or organisms on Gram stain, but grew α haemolytic streptococcus from the enrichment broth sensitive to penicillin, chloramphenicol, ciprofloxacin, and neomycin.

Treatment was with hourly topical ciprofloxacin 0.3%, with tapering after 48 hours. Review 1 week later revealed a persisting subepithelial scar and a best corrected spectacle acuity of 6/7.5.

Comment

Extended wear of soft contact lenses for up to 6 days has been advocated in various forms since the 1980s with traditional hydrogel lenses. However, owing to the relatively high rates of associated microbial keratitis,^{4,5} extended wear of soft contact lenses has not had widespread use.

The advent of high oxygen permeability silicone hydrogel soft contact lenses has again made extended wear a viable option, as the increased oxygen permeability is thought to reduce the risk of development of a hypoxic epithelial defect, which can serve as a portal of infection.² Pre-release extended wear studies did not reveal any cases of microbial keratitis but these studies were relatively small. Lenses with a Dk/t O₂ greater than 50 x 10⁷ have also been shown to have a lesser affinity for *P aeruginosa* binding during extended wear,⁶ further decreasing the risk of microbial keratitis.⁷

Our experience suggests that extended wear with even these newer SCL is still a risk factor in the development of microbial keratitis. All four patients had central or paracentral

infiltrates, with three patients presenting with an associated epithelial defect. All four patients also had a positive culture or Gram/Blankophor stain from the corneal scrape and had residual scarring after resolution of the acute episode. Although *Corynebacterium* species are considered by some to be a non-pathogenic organism, it has been described as the causative organism in several cases of microbial keratitis.^{8,9} We therefore feel that it is very unlikely that any of these cases represent a more benign non-infectious contact lens complication such as CLPU (contact lens induced peripheral ulcer), CLARE (contact lens induced acute red eye), or IK (infiltrative keratitis), which are all described as being conditions that resolve after cessation of contact lens wear alone, without the development of residual corneal scarring.¹⁰

Previous studies have shown that the most important risk factor for the development of microbial keratitis in soft contact lens wearers is the duration of contact lens wear, where overnight wear in particular aggravates the relative hypoxia of the cornea.^{3,6} However, there are other risk factors such as hypercapnia, trauma, biofilm alterations/contamination, altered corneal sensation, altered tear volume, and composition.¹¹⁻¹³ Only hypoxia and hypercapnia should be improved by increased contact lens gas permeability.

Three of the four patients described had swum in their lenses within weeks of their presentation. This might be an important risk factor in the development of their microbial keratitis in association with their silicon hydrogel SCL (as it is with other SCL), although the organisms involved were not those typically associated with microbial keratitis from contaminated water exposure. All four of the patients were also males between the ages of 16 and 22 years. These two demographic factors have been linked to an increased risk of microbial keratitis in contact lens wearers.⁷

Recent studies have shown that bacterial populations grown from silicone hydrogel SCL in asymptomatic wear were not statistically different in comparison with those grown from standard HEMA based SCL.³ This

suggests that a silicone hydrogel SCL can still be a means of contamination in the pathogenesis of SCL microbial keratitis. Certainly, some of the lenses in this small series did grow the same organisms as the corneal lesions themselves.

Our experience supports a multifactorial causality for the development of microbial keratitis in extended SCL wearers, rather than just corneal epithelial hypoxia, particularly in high risk groups such as the four patients described where high risk behaviour is also undertaken. Further investigation needs to be done on the effects these lenses have in extended wear with regard to the development of microbial keratitis before their long term safety can be assured.

L Lim, M S Loughnan, L J Sullivan

Corneal Clinic, Royal Victorian Eye and Ear Hospital, Locked Bag 8, East Melbourne, 8002, Australia

Correspondence to: L J Sullivan;
lsullivan@optushome.com.au

Accepted for publication 16 August 2001

References

- 1 **Dart JKG**. Extended wear contact lenses, microbial keratitis, and the public health. *Lancet* 1991;**354**:174–5.
- 2 **Fatt I**. Comparative study of some physiologically important properties of six brands of disposable hydrogel contact lenses. *CLAO J* 1997;**23**:49–54.
- 3 **Keay L**, Willcox MDP, Sweeney DF, et al. Bacterial populations on 30-night extended wear silicone hydrogel lenses. *CLAO J* 2001;**27**:30–4.
- 4 **Stapleton F**, Dart JKG, Minassian D. Risk factors with contact lens related suppurative keratitis. *CLAO J* 1993;**19**:204–10.
- 5 **Cheng KH**, Leung SL, Hoekman HW, et al. Incidence of contact-lens-associated microbial keratitis and its related morbidity. *Lancet* 1999;**354**:181–5.
- 6 **Bausch & Lomb product information**, <http://www.bausch.com/us/resource/visioncare/soft/purestory.jsp#AERGE>
- 7 **Imayasu M**, Petroll M, Jester J, et al. The relation between contact lens oxygen transmissibility and binding of *Pseudomonas aeruginosa* to the cornea after overnight wear. *Ophthalmology* 1994;**101**:371–88.
- 8 **Rubinfeld RS**, Cohen EJ, Arentsen JJ, et al. Diphtheroids as ocular pathogens. *Am J Ophthalmol* 1989;**108**:251–4.
- 9 **Heidemann DG**, Dunn SP, Diskin JA, et al. *Corynebacterium striatum* keratitis. *Cornea* 1991;**10**:81–2.
- 10 **Sankaridurg PR**, Sweeney DF, Sharma S, et al. Adverse events with extended wear of disposable hydrogels. *Ophthalmology* 1999;**106**:1671–80.
- 11 **Stapleton F**, Willcox MD, Fleming CM, et al. Changes to the ocular biota with time in extended- and daily-wear disposable contact lens use. *Infect Immun* 1995;**63**:4501–5.
- 12 **Connor CG**, Campbell JB, Steel SA, et al. The effects of daily wear contact lenses on goblet cell density. *J Am Optom Assoc* 1994;**65**:792–4.
- 13 **Millodot M**. Effect of soft lenses on corneal sensitivity. *Acta Ophthalmol* 1974;**52**:603–8.

Serious corneoscleral complications after pterygium excision with mitomycin C

The use of topical mitomycin C (MMC) to prevent recurrence after pterygium surgery is increasing since its introduction by Kunitomo and Mori in Japan, and its subsequent popularisation in the United States by Singh and associates.¹ Low dose MMC (0.02%) twice daily for 5 days after the operation has been prospectively studied with long term follow

up, and few serious side effects have been noted.^{2,3} Intraoperative MMC appeared to be an effective and safe adjunctive treatment of primary pterygium excision.⁴

Case reports

We retrospectively analysed three patients who presented at the Haemek Medical Central, Afula, Israel with scleral melting which developed after pterygium excision between October and November 2000, with intraoperative application of MMC (0.02% for 3 minutes). The MMC was washed out immediately with an abundant amount of balanced salt solution for at least 3 minutes. During the past 10 years we performed over 300 pterygium excisions with intraoperative use of MMC in Haemek Medical Center with three cases having serious complications.

Case 1 (Fig 1)

A previously healthy 50 year old man underwent recurrent pterygium excision of the right eye using a bare sclera technique with intraoperative application of MMC 0.02% for 3 minutes, having undergone pterygium excision with MMC 10 months earlier in his right eye. Visual acuity was 6/9+ SC. Preoperative ophthalmological examination revealed a nasal fleshy wide lesion 4.5 mm over the limbus and inferior symblepharon, with the remainder of the examination being normal. He was released on the same day, following surgery at which time there were no complications. On the first (postoperative day 1) and second (postoperative day 7) follow ups no complaints or complications were noted. However, on postoperative day 30, corneal limbal perforation and iris incarceration in the wound was noted. Immediately, he underwent right eye corneal tectonic graft surgery. At his last follow up (12 weeks after the pterygium excision with MMC), the best corrected visual acuity was 6/24 CPH, the graft has good adaptation, no gap and no rejection signs.

Case 2 (Fig 2)

A previously healthy 37 year old man underwent pterygium excision of the left eye using

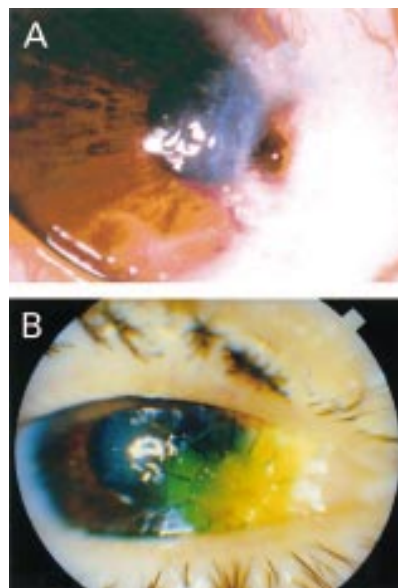


Figure 1

a bare sclera technique with intraoperative application of MMC 0.02% for 3 minutes. His presenting symptoms were cosmetic only. Visual acuity was 6/6 partial SC. Preoperative ophthalmological examination revealed nasal fleshy wide lesion 2.8 mm over the limbus with the remainder of the examination being normal. Two years previously he had undergone pterygium excision of the right eye using a bare sclera technique with intraoperative application of MMC 0.02% for 3 minutes. The right eye procedure had been successful and was performed in the same institute. Three weeks after the surgery, on routine follow up scleral melting and necrosis were noted. The scleral defect was unresponsive to ocular lubricants, topical antibiotics, topical steroids, and patching. Ten weeks after the left eye pterygium excision and MMC application, he underwent autologous conjunctival graft surgery to repair the defect. Follow up 2 weeks later showed that the graft has good adaptation and re-epithelialisation was noted.

Case 3

A previously healthy 70 year old man underwent pterygium excision of the right eye using a bare sclera technique with intraoperative application of MMC 0.02% for 3 minutes. On preoperative examination: visual acuity 6/24 partial SC in the right eye and 6/60 SC in the left, anterior segment was quiet except fleshy temporal pterygium 7 mm over the limbus partially covering the pupil axis in the right eye. The procedure of the right eye pterygium excision with MMC was successful and performed in the same institute. No complaints or complications were noted at the first two follow ups; however, 3 weeks postoperatively right eye temporal scleral melting and ectasia was seen (3 mm × 3 mm in size). Conservative topical treatment with antibiotics, topical anti-inflammatory agents, and steroids failed to resolve the situation. Consequently, 8 weeks after the initial right eye surgery he underwent right eye conjunctival flap grafting over the area of scleral melting. At his last examination best corrected visual acuity was 6/36 partial, blood vessel growth was noted towards the bare sclera and re-epithelialisation with minimal staining. He is still being treated with topical antibiotics with some improvement.

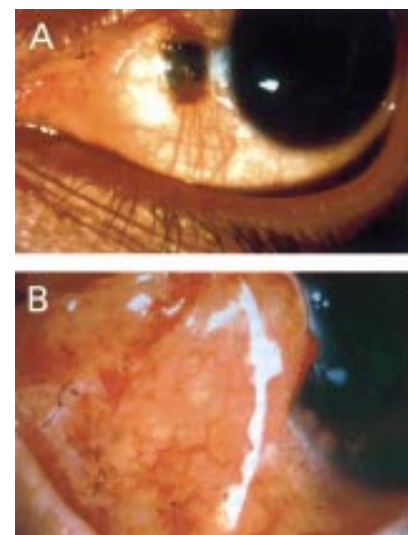


Figure 2

Table 1

No	Age/sex/race	Presenting symptom	Clinical finding	Treatment	Preop VA v postop	Outcome
1	50/M/white	Blurred vision, dust sensation	Limbal perforation with iris incarceration in the wound	Tectonic corneal graft	6/9+ SC 6/24 CPH	Good graft adaptation. No recurrence of pterygium after 12 weeks
2	37/M/white	Cosmetic disturbance	Scleral nasal melting (3 mm × 2 mm)	Trial at conservative topical treatment failed. Autologous conjunctival graft	6/9+ SC 6/12+ SC	Good graft adaptation at last follow up
3	70/M/white	Pterygium covering the pupil visual axis	Scleral temporal melting (3 mm × 3 mm)	Trial at conservative topical treatment failed. Conjunctival flap	6/24 pt CC 6/36 pt CC	Blood vessels growth towards the bare sclera with re-epithelisation. No recurrence of pterygium after 12 weeks

Comment

Mitomycin C is an antineoplastic antibiotic agent isolated from the fermentation filtrate of *Streptomyces caespitosus*. Its action is similar to alkylating agents; it alkylates and crosslinks DNA and, in addition, may generate superoxide and hydroxyl radicals in solution. It also inhibits DNA, RNA, and protein synthesis.⁵

These combined effects may result in a long term influence on cellular proliferation.

Scleral melting occurring after pterygium surgery with adjunctive treatment has been well reported.^{6,7} However, no serious complications were noted in the study by Frucht-Pery and Ilsaar⁸ with postoperative use of 0.1 mg/ml MMC twice daily for 5 days (with a mean follow up period of 15.3 months) or in intraoperative MMC treated eyes.⁴ A common element in toxicity with MMC is a relatively large cumulative dose.⁷ Therefore, most ophthalmologists believe that a single intraoperative exposure to MMC would reduce the complication rate of MMC eye drop regimen.⁴

In the current series, all patients underwent pterygium excision in the bare sclera technique with the low concentration of 0.02% of MMC and a short application of 3 minutes. Among our patients one had corneal perforation that was treated by tectonic keratoplasty and other two had severe deep scleral melting that required conjunctival flaps or autologous graft. Our patients were all healthy, without conditions predisposing to ulceration or poor wound healing such as Sjögren syndrome, severe keratoconjunctivitis sicca, acne rosacea, atopic keratoconjunctivitis, or herpes keratitis (Table 1). We suspected that the MMC concentration was not appropriate during that period. We checked the concentration and it was difficult to obtain precise results after a waiting period, owing to the degradation of the material.

This report raises serious questions regarding routine use of MMC. Recently, some investigators have evaluated the safety and efficacy of low dose MMC (0.02%) for an even shorter time (30 seconds).⁹ All ophthalmologists should be aware of the possibility of vision threatening complications and avoid routine and broad use of mitomycin in all fields.

B Safianik, I Ben-Zion, H J Garzozi

Department of Ophthalmology, Haemek Medical Center, Afula, Israel

Correspondence to: Dr Boris Safianik, Department of Ophthalmology, Ha'emek Medical Center, Afula, Israel

Accepted for publication 22 August 2001

References

- 1 Singh G, Wilson MR, Foster CS. Mitomycin eye drops as treatment for pterygium. *Ophthalmology* 1988;**95**:813-21

- 2 Hayasaka S, Noda S, Yamamoto Y, et al. Postoperative instillation of low dose mitomycin-c in the treatment of primary pterygium. *Am J Ophthalmol* 1988;**106**:715-8.
- 3 Rachmiel R, Leibe H, Levartovsky S. Results of treatment with topical mitomycin C 0.02% following excision of primary pterygium. *Br J Ophthalmol* 1995;**79**:233-6.
- 4 Cano-Para J, Diaz-Llopis M, Maldonado MJ, et al. Prospective trial of intraoperative mitomycin C in the treatment of primary pterygium. *Br J Ophthalmol* 1995;**79**:439-41.
- 5 Glaubiger D, Ramu A. Antitumor antibiotics. In: Chabner BA, ed. *Pharmacologic principles of cancer treatment*. Philadelphia: WB Saunders, 1982:407-10.
- 6 Mackenzie FD, Hirst LW, Kynaston B. Recurrence rate and complications after beta-irradiation for pterygium. *Ophthalmology* 1991;**98**:1776-80.
- 7 Rubinfeld RS, Pfister RS, Stern RM, et al. Serious complications of topical mitomycin-c after pterygium surgery. *Ophthalmology* 1992;**99**:1647-54.
- 8 Frucht-Pery J, Ilsaar M. The use of low dose mitomycin-c for prevention of recurrent pterygium. *Ophthalmology* 1994;**101**:759-62.
- 9 Cheng HC, Sung-Huel T, Ping-Lin K, et al. Low-dose intraoperative mitomycin C as chemoadjuvant for pterygium surgery. *Cornea* 2001;**20**:24-9.

Extrascleral extension of a choroidal melanoma after argon photocoagulation and transpupillary thermotherapy

The optimal management of small posterior choroidal melanomas remains controversial, especially for tumours located near the optic disc and fovea. Although with increasing rarity, argon laser photocoagulation continues to be used in the primary treatment of small tumours, despite data suggesting that other therapeutic methods may be more successful.¹⁻⁴ More recently, transpupillary thermotherapy (TTT) has emerged as a therapeutic option for the primary treatment of small choroidal melanomas.^{5,6} Initial results are promising, but like any new treatments, more widespread use and longer follow up are needed for a thorough assessment of its efficacy. As a cautionary reminder that additional study is required to define the potential complications of these treatments, we present a case of choroidal melanoma in which treatment with primary argon photocoagulation followed by TTT was associated with extrascleral extension of the tumour.

Case report

A 38 year old woman presented with decreased visual acuity in her right eye. An ophthalmologist noted a pigmented choroidal

lesion with associated subretinal fluid. The lesion was initially treated with argon laser photocoagulation, but within a month the decision was made to re-treat the lesion with TTT. Over the next 7 months, visual acuity deteriorated to 20/200. The lesion exhibited persistent elevation and subretinal fluid. By ultrasound, a change in the retrolscleral echogenicity was observed, precipitating referral to an ophthalmic oncologist whereupon a diagnosis of choroidal melanoma with extrascleral extension was made. The patient was then referred to UCSF for consideration of proton beam therapy.

On examination, all abnormal findings were confined to the right eye. The patient's visual acuity was counting fingers at 2 feet. Funduscopic examination revealed a raised pigmented tumour centred on the fovea, measuring 7 mm vertically by 10 mm horizontally, extending to within 2.3 mm of the disc. Subretinal fluid was present and extended over the nasal aspect of the tumour (Fig 1A). A flat

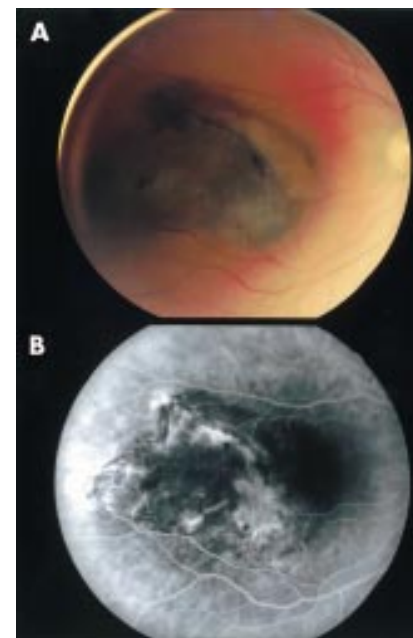


Figure 1 (A) Fundus photograph of the right eye demonstrating a pigmented choroidal tumour in the macular region with an area nasally exhibiting orange pigment on its surface. There is associated subretinal fluid extending nasally. (B) Fluorescein angiography demonstrates irregular choroidal vessels within the tumour that are bright in the early arterial phase and show late leakage with punctate hot spots.

naevus 2 mm in diameter was also noted inferonasally (not shown). Fluorescein angiography was remarkable for an irregular plexus of choroidal vessels within the tumour noted in the early arterial phase, mid-phase leakage from retinal veins overlying the tumour, and late leakage with punctate hot spots at the tumour margin (Fig 1B). B-scan ultrasound revealed choroidal excavation, an acoustic quiet zone, and orbital shadowing (Fig 2A). A-scan demonstrated spontaneous pulsation, low to medium internal reflectivity, and a sharp posterior spike (Fig 2B). The intraocular thickness was 3.0 mm, with 7.7 mm of extraocular extension. These findings are consistent with choroidal melanoma with posterior extrascleral extension. Systemic evaluation revealed no signs of metastasis. The potential for orbital contamination by tumour made focal therapy by proton beam a less desirable alternative. Therefore, enucleation with en bloc resection of the extrascleral tumour was recommended and subsequently performed. Pathological examination confirmed the diagnosis of malignant choroidal melanoma, mixed cell type, with extensive extrascleral extension and focal vascular invasion. The patient elected to undergo adjuvant post-surgical external beam irradiation to reduce the rate of orbital recurrence, with the understanding that this treatment, while not definitively harmful, is of unproved benefit.⁷ She was also referred to the medical oncology service for systemic therapy and has begun an experimental treatment protocol using interferon alfa. Systemic chemotherapy is currently under consideration.

Comment

Options for the management of choroidal melanoma include observation, laser photocoagulation, transpupillary thermotherapy, charged particle radiotherapy, brachytherapy, local resection, and enucleation. Argon laser

photocoagulation is typically used as an adjunct to other treatments,² but in select cases has been used as primary therapy for choroidal melanoma.¹⁻³ Typically, photocoagulation is reserved for small tumours (less than 3–4 mm in thickness and less than 10 mm in diameter) that are located close to the fovea and/or the optic disc in eyes with good vision. Because the level of tumour necrosis with laser photocoagulation is shallow (0.2–0.8 mm),⁸ multiple sessions are often necessary.^{2,3} Therefore, the greatest challenge to successful photocoagulative therapy in choroidal melanomas is determining when the tumour has been fully ablated.⁹

TTT shares the advantages that photocoagulation has over radiotherapy, including the more rapid visible reduction of tumour size, the relative sparing of adjacent normal tissue, and the convenience and economy of an outpatient procedure. In contrast with the shallow penetration of the argon laser, however, TTT employs near infrared light to produce up to a 3.9 mm depth of tumour necrosis.¹⁰ The promise of this treatment has spurred investigation into its use as a primary treatment for small posterior choroidal melanomas with encouraging early results.^{5,6}

It has been suggested that recurrences occur following apparently successful photocoagulation or TTT because invisible nests of malignant cells can infiltrate the sclera, a histologically documented phenomenon.^{11,12} The presented case serves as a reminder that this possibility is not trivial. Extrascleral extension, presumably from tumour out of reach of initial argon phototherapy and subsequent TTT, resulted in a requirement for aggressive local surgical therapy, radiation therapy, and adjuvant systemic therapy to reduce the risk of metastatic disease. The unusual degree of extrascleral extension for a small melanoma also raises the possibility that either photocoagulation or, more likely, TTT produced some reduction in scleral integrity allowing focal egress of tumour cells. Reports of complications following argon laser are likely to become rarer because advances in modern radiotherapy have made primary photocoagulation an uncommon treatment.⁴ The use and investigation of TTT, however, continue to increase and the risks for extrascleral extension remain undefined.

T Tsai, J M O'Brien

Ocular Oncology Unit, Department of Ophthalmology, University of California, San Francisco, California, USA

R Engstrom, B R Straatsma

Jules Stein Eye Institute, University of California, Los Angeles, California, USA

Correspondence to: Joan O'Brien, MD, Ocular Oncology Unit, UCSF Department of Ophthalmology, 10 Kirkham Street, Box 0730, San Francisco, CA 94143, USA; aleja@itsa.ucsf.edu

Accepted for publication 29 August 2001

References

- 1 Eide N. Primary laser photocoagulation of "small" choroidal melanomas. *Acta Ophthalmol Scand* 1999;**77**:351–4.
- 2 Shields JA. The expanding role of laser photocoagulation for intraocular tumors. The 1993 H Christian Zweng Memorial Lecture. *Retina* 1994;**14**:310–22.
- 3 Shields JA, Glazer LC, Mieler WF, et al. Comparison of xenon arc and argon laser photocoagulation in the treatment of choroidal melanomas. *Am J Ophthalmol* 1990;**109**:647–55.
- 4 Shields JA, Shields CL, Donoso LA. Management of posterior uveal melanoma. *Surv Ophthalmol* 1991;**36**:161–95.

- 5 Shields CL, Shields JA, Cater J, et al. Transpupillary thermotherapy for choroidal melanoma: tumor control and visual results in 100 consecutive cases. *Ophthalmology* 1998;**105**:581–90.
- 6 Oosterhuis JA, Journée-de Korver HG, Kakebeke-Kemme HM, et al. Transpupillary thermotherapy in choroidal melanomas. *Arch Ophthalmol* 1995;**113**:315–21.
- 7 The Collaborative Ocular Melanoma Study (COMS) randomized trial of pre-enucleation radiation of large choroidal melanoma. III: local complications and observations following enucleation COMS report no 11. *Am J Ophthalmol* 1998;**126**:362–72.
- 8 Apple DJ, Goldberg MF, Wyhinny G, et al. Argon laser photocoagulation of choroidal malignant melanoma. Tissue effects after a single treatment. *Arch Ophthalmol* 1973;**90**:97–101.
- 9 Vogel MH. Treatment of malignant choroidal melanomas with photocoagulation. Evaluation of 10-year follow-up data. *Am J Ophthalmol* 1972;**74**:1–11.
- 10 Journée-de Korver JG, Oosterhuis JA, de Wolff-Rouendaal D, et al. Histopathological findings in human choroidal melanomas after transpupillary thermotherapy. *Br J Ophthalmol* 1997;**81**:234–9.
- 11 Duvall J, Lucas DR. Argon laser and xenon arc coagulation of malignant choroidal melanoma: histological findings in six cases. *Br J Ophthalmol* 1981;**65**:464–8.
- 12 Jensen OA. Malignant melanomas of the uvea in Denmark 1943–1952. *Acta Ophthalmol Suppl* 1963;**75**:1–220.

Macular infarction after intravitreal amikacin: mounting evidence against amikacin

Retinal toxicity attributable to intravitreal use of aminoglycosides for endophthalmitis has been reported. Campochiaro and Conway reported 101 cases of retinal damage due to intravitreal aminoglycosides.¹ Amikacin, an aminoglycoside, is in widespread use in the United Kingdom for the treatment of Gram negative organisms in endophthalmitis. We report a case of macular toxicity following the use of intravitreal amikacin for postoperative endophthalmitis, outline mechanisms of retinal toxicity, and offer alternatives to amikacin. We believe that enough evidence now exists to support a change in the current Royal College of Ophthalmologists' endophthalmitis treatment guidelines that are based on the Endophthalmitis Vitrectomy Study.²

Case report

A 69 year old white woman presented 1 day after uneventful right phacoemulsification and intraocular lens implantation with a vision of counting fingers (CF), a relative afferent pupil defect, hypopyon with anterior chamber fibrin, and normal intraocular pressure. We were unable to visualise the fundus although a red reflex was noted. Ultrasound examination showed patchy increased vitreous reflectivity with a flat retina and choroid. Pars plana vitreous tap of 0.2 ml was performed followed by injection of 1 mg/0.1 ml of vancomycin and 0.4 mg/0.1 ml of amikacin. Sterile dilution was conducted with typewritten instructions. The globe never became tense. The ocular inflammation resolved on a daily regimen of oral prednisolone 60 mg, oral ciprofloxacin 750 mg four times daily, topical ofloxacin 0.3% 2 hourly, topical dexamethasone 0.1% 2 hourly, and topical atropine 1% once daily. Vision however remained CF because of angiographically proved macular ischaemia and vascular occlusion (Figs 1 and 2). There was no microbially growth from the vitreous sample.

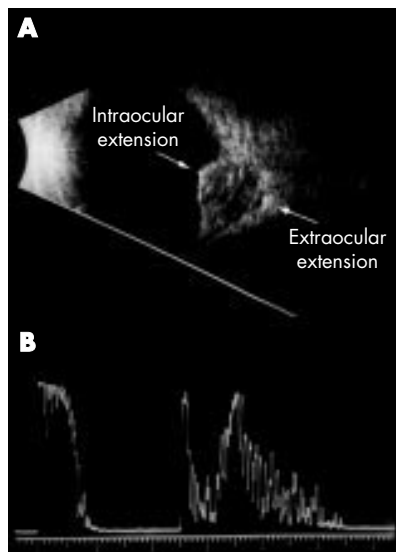


Figure 2 (A) B-scan ultrasonography demonstrates extraocular extension of the tumour and exhibits the choroidal excavation, acoustic quiet zone, and orbital shadowing characteristic of a uveal melanoma. Arrows surround areas of tumour extension. (B) A-scan ultrasonography shows spontaneous pulsation, low to medium internal reflectivity, and a sharp posterior spike. The measured intraocular tumour thickness was 3.0 mm with 7.7 mm of extraocular extension.

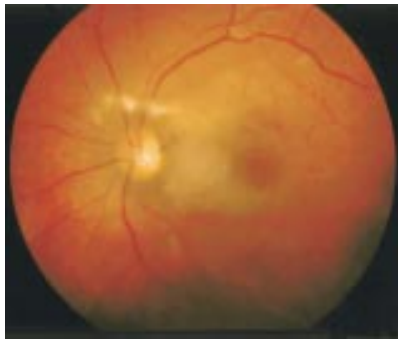

Figure 1 Fundus photograph showing diffuse posterior pole retinal cloudy swelling, cotton wool spots, and scattered intraretinal haemorrhages.

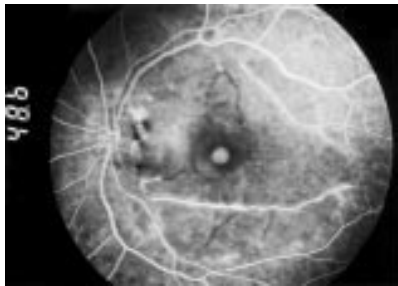

Figure 2 Fluorescein angiogram at 48 seconds showing diffuse macular arteriolar occlusion with staining of the arteriolar walls along the inferior and superior arcades.

Comment

The rationale for amikacin use relates to the relatively high incidence of Gram negative isolates in endophthalmitis (6.4–26.2%)^{3,5} and the broad spectrum of action with low resistance offered by this agent. Amikacin has largely superseded gentamicin because of its perceived safety profile. Our case and others reported in the literature^{6–8} serve to notify clinicians of the serious retinal toxicity occurring with amikacin use, which is possibly a class related phenomenon.

Hypotheses for toxicity include dilution errors, raised post-injection intraocular pressure, concomitant use of high concentrations of subconjunctival amikacin, and variations in vitreous concentration. Local variation in concentration may play a part if the agent is directly injected into the posterior vitreous space instead of the gel itself. Another possibility for macular predilection is that this is the dependent part in the supine patient during pars plana injection.

Large studies offer alternatives to aminoglycosides on the basis of culture sensitivities.^{3–5} Suggestions include ceftazidime, cefotaxime, and ciprofloxacin. Sensitivities of Gram negative organisms to ceftazidime range from 61% to 100% according to published studies.^{3–5} It appears that in most studies 2 mg (0.1 ml of 20 mg/ml solution) of ceftazidime has in vitro effectiveness equipotent to or greater than 0.4 mg amikacin.^{3–5} Primate studies have shown that intravitreal ceftazidime is non-toxic at doses of 2.25 mg.¹⁰ Ceftazidime is already in clinical use in the United Kingdom.⁶ There have been no reported cases of retinal toxicity with intravitreal ceftazidime use in humans.¹¹

With mounting evidence against amikacin we support a change in current UK treatment

guidelines. Choices will remain controversial until the incidence of toxicity for both amikacin and ceftazidime is determined by a prospective randomised controlled study; however, on the evidence currently available we suggest that ceftazidime should replace amikacin as the first line agent of choice against Gram negative organisms in postoperative endophthalmitis.

G Galloway, A Ramsay, K Jordan, A Vivian

Department of Ophthalmology, West Suffolk Hospital, Bury St Edmunds, IP33 2QZ, UK

Correspondence to: Mr Gavin Galloway; gavgal@doctors.org.uk
Accepted for publication 22 August 2001

References

- 1 **Campochiaro PA**, Conway BP. Aminoglycoside toxicity—a survey of retinal specialists: implications for ocular use. *Arch Ophthalmol* 1991;**109**:946–50.
- 2 **Endophthalmitis Vitrectomy Study Group**. Results of the Endophthalmitis Vitrectomy Study. A randomised trial of immediate vitrectomy and of intravenous antibiotics for the treatment of postoperative bacterial endophthalmitis. *Arch Ophthalmol* 1995;**113**:1479–96.
- 3 **Kunimoto DY**, Das T, Sharma S, *et al*. Microbiologic spectrum and susceptibility of isolates: part I. Postoperative endophthalmitis. Endophthalmitis Research Group. *Am J Ophthalmol* 1999;**128**:240–2.
- 4 **Han DP**, Wisniewski SR, Wilson LA, *et al*. Spectrum and susceptibilities of microbiologic isolates in the Endophthalmitis Vitrectomy Study. *Am J Ophthalmol* 1996;**122**:1–17.
- 5 **Donahue SP**, Kowalski RP, Eller AW, *et al*. Empiric treatment of endophthalmitis. Are aminoglycosides necessary? *Arch Ophthalmol* 1994;**112**:45–7.
- 6 **Jackson TL**, Williamson TH. Amikacin retinal toxicity. *Br J Ophthalmol* 1999;**83**:1199–200.
- 7 **Seawright AA**, Bourke RD, Cooling RJ. Macula toxicity after intravitreal amikacin. *Aust N Z J Ophthalmol* 1996;**24**:143–6.
- 8 **Kumar A**, Dada T. Preretinal haemorrhages: an unusual manifestation of intravitreal amikacin toxicity. *Aust NZ J Ophthalmol* 1999;**27**:435–6.
- 9 **Irvine WD**, Flynn HW Jr, Miller D, *et al*. Endophthalmitis caused by gram-negative organisms. *Arch Ophthalmol* 1992;**110**:1450–4.
- 10 **Campochiaro PA**, Green WR. Toxicity of intravitreal ceftazidime in primate retina. *Arch Ophthalmol* 1992;**110**:1625–9.
- 11 **Lim JI**, Campochiaro PA. Successful treatment of gram-negative endophthalmitis with intravitreal ceftazidime. *Arch Ophthalmol* 1992;**110**:1686.

Spontaneous involution of retinal and intracranial arteriovenous malformation in Bonnet-Dechaume-Blanc syndrome

Intracranial arteriovenous malformations are capable of spontaneous regression.^{1–3} There are also numerous recorded events of vascular remodelling, thrombosis, and autoinvolution in retinal arteriovenous malformations.^{4–7} This report documents a self obliterated retinal arteriovenous malformation in a patient with Bonnet-Dechaume-Blanc syndrome who developed neurological symptoms due to spontaneous regression of the intracranial component of the angiomatous malformation.

Case report

A 32 year old man from Guam was evaluated for a history of right parietal headaches for

several months and acquired temporal hemianopia in the left eye. He had a history of blindness in the right eye from early childhood, and had recently become aware of a temporal hemianopia in the left eye.

Visual acuity was no light perception in the right eye and 20/20 in the left eye. The right pupil was unreactive to light. The left pupil was sluggishly reactive and there was a right afferent pupillary defect. Slit lamp examination showed conjunctival venous engorgement in the right eye. Retinal examination disclosed white, sclerotic major retinal vessels, with no evidence of retinal vascular perfusion in the right eye (Fig 2). The major retinal vessels were surrounded by non-perfused clusters of white, racemose, telangiectatic, vessels (Fig 1). The left optic nerve showed band atrophy with corresponding nerve fibre layer dropout but no other retinal abnormality.

Magnetic resonance imaging showed numerous vascular channels permeating the right basal ganglia, anterior portion of the midbrain, prefrontal gyrus, optic chiasm, and the right orbit. The deep hemispheric portion of the lesion showed surrounding oedema. CT scanning showed punctate and conglomerate calcifications in the malformation, as well as enlargement of the right optic canal. Cerebral angiography demonstrated an angiomatous vascular malformation that permeated the basal ganglia as well as the optic chiasm region and extended into the right orbit (Fig 2). There was a relative lack of deep venous drainage in the chiasmatic region of the malformation, with diversion to the Sylvian vein system and over the convexities to the sagittal sinus. The lack of hypertrophy in these draining venous channels, together with the

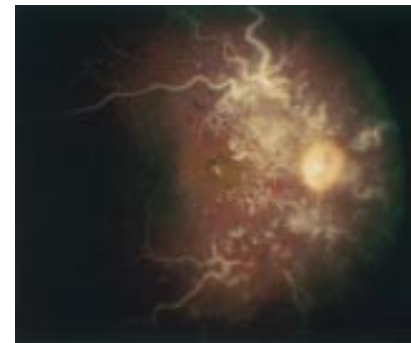

Figure 1 Fundus photograph of right eye demonstrating self obliterated retinal arteriovenous malformation. Sclerotic major retinal vessels are surrounded by smaller racemose ghost vessels.

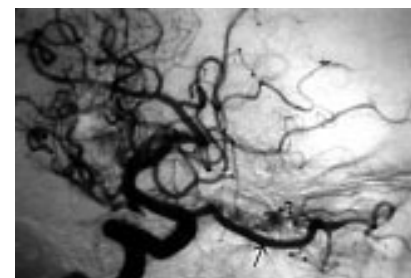


Figure 2 Internal carotid artery angiogram, arterial phase, demonstrating marked enlargement of the ophthalmic artery (bottom right, arrow). The right optic nerve is honeycombed by a vascular malformation (open arrow).

regional oedema on magnetic resonance imaging, suggested a recent obstruction of vascular flow within the angiomatous malformation.

Comment

The syndrome of unilateral retinocephalic arteriovenous malformation was first described in 1937 by Bonnet *et al.*⁸ Six years later, Wyburn-Mason published his report in the English language.⁹ These congenital unilateral retinocephalic arteriovenous malformations may involve the visual pathways from the retina and optic nerve to the ipsilateral occipital cortex, and may involve the chiasm, hypothalamus, basal ganglia, midbrain, and cerebellum.¹⁰ Since these arteriovenous malformations are high flow systems in which veins are exposed to arterial blood pressures, they are susceptible to turbulent blood flow and to vessel wall damage which can lead to thrombosis and occlusion.⁷ Over time, components of an angiomatous malformation can grow, haemorrhage, sclerose, thrombose, and involute.⁷

Our patient had longstanding involution of his retinal arteriovenous malformation, with new neurological symptoms resulting from thrombosis of the intracranial component of the tumour. Spontaneous occlusion of the major venous drainage within the deep cerebral hemisphere and optic chiasm may have caused headaches by producing regional oedema or by diverting flow to other venous structures. Since the major venous drainage within the malformation was already occluded at the time of presentation, no treatment was advised. The complex evolution of clinical signs in our patient underscores the need to distinguish disease progression from spontaneous involution in symptomatic patients with Bonnet-Dechaume-Blanc syndrome.

Acknowledgement

Supported in part by a grant from Research to Prevent Blindness, Inc.

M C Brodsky

Department of Ophthalmology and Pediatrics,
University of Arkansas for Medical Sciences,
AR, USA

W F Hoyt

Departments of Ophthalmology, Neurology, and
Neurosurgery, University of California, San
Francisco, CA, USA

Correspondence to: Michael C Brodsky, MD,
Arkansas Children's Hospital, 800 Marshall,
Little Rock, AR 72202, USA

Accepted for publication 29 August 2001

References

- Höök O, Johanson C. Intracranial arteriovenous aneurysm. A follow-up study with particular attention to their growth. *AMA Arch Neurol Psychiatr* 1958;**80**:39–54.
- Conforti P. Spontaneous disappearance of cerebral arteriovenous angioma. Case report. *J Neurosurg* 1971;**34**:432–4.
- Levin J, Misko JC, Seres JL, *et al.* Spontaneous angiographic disappearance of a cerebral arteriovenous malformation. Third reported case. *Arch Neurol* 1973;**28**:195–6.
- Dekking HM. Arteriovenous aneurysm of the retina with spontaneous regression. *Ophthalmologica* 1955;**130**:113.
- Augsburger JJ, Goldberg RE, Shields JA, *et al.* Changing appearance of retinal arteriovenous malformation. *Albrecht von Graefes Arch Klin Ophthalmol* 1980;**215**:65–70.
- Mansour AM, Wells CG, Jampol LM, *et al.* Ocular complications of arteriovenous communications of the retina. *Arch Ophthalmol* 1989;**107**:232–6.
- Schatz H, Chang LF, Ober RR, *et al.* Central retinal vein occlusion associated with retinal arteriovenous malformation. *Ophthalmology* 1993;**100**:24–30.
- Bonnet P, Dechaume J, Blanc E. L'anévrysme cirsoïde de la rétine (anévrysme recémeux): ses relations avec l'anévrysme cirsoïde de la face et avec l'anévrysme cirsoïde du cerveau. *J Med Lyon* 1937;**18**:165–78.
- Wyburn-Mason R. Arteriovenous malformation of the mid-brain and retina, facial naevi, and mental changes. *Brain* 1943;**18**:165–78.
- Théron J, Newton TH, Hoyt WF. Unilateral retinocephalic vascular malformations. *Neuroradiology* 1974;**7**:185–96.

NOTICES

Glaucoma

The latest issue of Community Eye Health (No 39) discusses the glaucomas, with an editorial by Professor Gordon J Johnson, director of the International Centre for Eye Health. For further information please contact: Journal of Community Eye Health, International Centre for Eye Health, Institute of Ophthalmology, 11–43 Bath Street, London EC1V 9EL, UK (tel: +44 (0)20 7608 6910; fax: +44 (0)20 7250 3207; email: eyesource@ucl.ac.uk; website: www.jceh.co.uk). Annual subscription (4 issues) UK£25/US\$40. Free to workers in developing countries.

International Centre for Eye Health

The International Centre for Eye Health has published a new edition of the *Standard List of Medicines, Equipment, Instruments and Optical Supplies* (2001) for eye care services in developing countries. It is compiled by the Task Force of the International Agency for the Prevention of Blindness. Further details: Sue Stevens, International Centre for Eye Health, 11–43 Bath Street, London EC1V 9EL, UK (tel: +44 (0)20 7608 6910; email: eyesource@ucl.ac.uk).

Second Sight

Second Sight, a UK based charity whose aims are to eliminate the backlog of cataract blind in India by the year 2020 and to establish strong links between Indian and British ophthalmologists, is regularly sending volunteer surgeons to India. Details can be found at the charity website (www.secondsight.org.uk) or by contacting Dr Lucy Mathen (lucymathen@yahoo.com).

Specific Eye ConditionS (SPECS)

Specific Eye ConditionS (SPECS) is a not for profit organisation which acts as an umbrella organisation for support groups of any conditions or syndrome with an integral eye disorder. SPECS represents over fifty different organisations related to eye disorders ranging from conditions that are relatively common to very rare syndromes. We also include groups who offer support of a more general nature to visually impaired and blind people. Support groups meet regularly in the Boardroom at Moorfields Eye Hospital to offer support to each other, share experiences and explore new ways of working together. The web site www.eyecconditions.org.uk acts as a portal giving direct access to support groups own sites. The SPECS web page is a valuable

resource for professionals and may also be of interest to people with a visual impairment or who are blind. For further details about SPECS contact: Kay Parkinson, SPECS Development Officer (tel: +44 (0)1803 524238; email: k@eyeconditions.org.uk; www.eyecconditions.org.uk).

XXIXth International Congress of Ophthalmology

The XXIXth International Congress of Ophthalmology will be held on 21–25 April 2002 in Sydney, Australia. Further details: Congress Secretariat, C/- ICMS Australia Pty Ltd, GPO Box 2609, Sydney, NSW 2001, Australia (tel: +61 2 9241 1478; fax: +61 2 9251 3552; email: ophthal@icmsaust.com.au; website: www.ophthalmology.aust.com).

Joachim Kuhlmann Fellowship for Ophthalmologists 2002

In honour of its founder's memory, the Joachim Kuhlmann AIDS-Stiftung, Essen, Germany, is sponsoring two fellowships for ophthalmologists at a well known institute, who want to train in CMV-retinitis and other HIV related ophthalmologic diseases. The fellowships each include \$US 5000. Deadline for application is 31 March 2002.

Detailed applications including a CV and publication list should be sent to the Joachim Kuhlmann AIDS-Foundation, Bismarckstr. 55, 45128 Essen, Germany. Further information is available at www.jk-aidstiftung.de.

12th Meeting of the European Association for the Study of Diabetic Eye Complications (EASDEC)

The 12th meeting of the EASDEC will be held on 24–26 May 2002 in Udine, Italy. The deadline for abstracts is 15 February 2002. Three travel grants for young members (less than 35 years of age at the time of the meeting) are available. For information on the travel grants, please contact Pr CD Agardh, President of EASDEC, Malmö University Hospital, SE-205 02 Malmö, Sweden (tel +46 40 33 10 16; fax: +46 40 33 73 66; email: carl-david.agardh@endo.mas.lu.se). Further details: NORD EST CONGRESSI, Via Aquilea, 21.–33100 Udine, Italy (tel: +30 0432 21391; fax: +39 0432 50687; email: nordest.congressi@ud.nettuno.it)

International Society for Behçet's Disease

The 10th International Congress on Behçet's Disease will be held in Berlin 27–29 June 2002. Further details: Professor Ch Zouboulis (email: zoubbere@zedat.fu-berlin.de).

Singapore National Eye Centre 5th International Meeting

The Singapore National Eye Centre 5th International Meeting will be held on 3–5 August 2002 in Singapore. Further details: Ms Amy Lim, Organising Secretariat, Singapore National Eye Centre, 11 Third Hospital Avenue, Singapore 168751 (tel: (65) 322 8374; fax: (65) 227 7290; email: Amy_Lim@snecc.com.sg).

BEAVRS Meeting

The next BEAVRS meeting will be held in the Dalmahoy Hotel near Edinburgh on 31 October to 1 November 2002. Further details: Susan Campbell, Medical Secretary, Gartnavel General Hospital (email: susan.j.campbell.wg@northglasgow.scot.nhs.uk).