

PostScript

LETTERS

If you have a burning desire to respond to a paper published in the *BJO*, why not make use of our "rapid response" option? Log on to our website (www.bjophthalmol.com), find the paper that interests you, and send your response via email by clicking on the "eLetters" option in the box at the top right hand corner.

Providing it isn't libellous or obscene, it will be posted within seven days. You can retrieve it by clicking on "read eLetters" on our homepage.

The editors will decide as before whether to also publish it in a future paper issue.

Treacher Collins syndrome with novel ophthalmic findings and visceral anomalies

Treacher Collins syndrome (TCS) (mandibulo-facial dysostosis (MFD) or zygomauro-mandibular dysplasia) is one of a group of congenital malformation syndromes that have in common maldevelopment of the first and second branchial arches.¹ Clinical features typically include hypoplasia of the mandible and zygoma; a complex variety of ear abnormalities including malformed pinnae, atresia of the external auditory canals and anomalies of the middle ear ossicles; cleft palate; receding chin; and sinus and choanal atresia.² We present a pair of twins that possessed not only classic features of TCS but also unusual visceral and previously unreported ophthalmic pathology.

Case reports

A 32 year old, gravida 3 para 2-0-0-2 woman underwent elective abortion after fetal death and major fetal malformations were diagnosed during pregnancy. Ultrasound examination at 20 weeks of gestation displayed monozygotic, diamniotic twins. Fetus A, noted alive at 16 weeks, was dead and surrounded

by minimal amniotic fluid. Fetus B was alive with several anomalies including bilateral infraorbital cystic masses, protruding tongue, and large median facial cleft. Amniocentesis revealed a 46XY karyotype without numerical or structural chromosomal abnormalities. The parents denied any significant medical history, family history, of congenital anomalies, or use of drugs or alcohol. Their two other children, ages 17 and 33 months, were normal. No family members exhibited features of TCS on visual examination.

Necropsy measurements were consistent with 16 weeks of gestational age for twin A and 21 weeks for twin B. Both twins had bilaterally hypoplastic zygomas, maxillae, and related muscles; severely hypoplastic and misplaced pinnae; bilaterally agenic external auditory canals; bilateral lateral facial clefts, and severe micognathia (Fig 1). Twin A exhibited left sided choanal atresia, agenesis of the hard and soft palate, and multiple visceral anomalies, including dual superior vena cava, bilobed right and unilobed left lungs, bilateral renal and ureteral agenesis, rudimentary urinary bladder, and absent epididymides. Twin B was noted to have right sided choanal atresia, soft palate aplasia, hard palate hypoplasia, and a left sided cleft; twin B had no visceral anomalies. Ocular pathological dissection of twin A illustrated bilateral microphthalmia; corneal scleralisation; and maldevelopment of the uvea, lens, and retina. Ocular dissection of twin B revealed microphthalmia, aniridia, congenital cataracts, and bilateral vascularisation of the corneas.

Comment

These twins had multiple features characteristic of TCS, most notably hypoplastic zygomas, maxillae, and related muscles—perhaps the most characteristic features of TCS. In contrast, visceral anomalies, such as those of twin A, are rare. Only two cases have been previously reported: one with tracheoesophageal fistula, rectovaginal fistula, and anal atresia; another with achalasia.³ Renal agenesis, found in twin A, has not been previously described in association with TCS. While ophthalmological features in TCS are often extensive, they seldom involve the intraocular structures. Common findings include a defective inferior lateral angle of the orbit, caudal displacement of the superolateral orbit, true

and pseudocolobomas of the lids, lateral canthal dystopia, orbital lipodermoids, corneal scleral dermoids, and microphthalmos.⁴ Cataracts, lacrimal duct atresia, pupillary ectopia, distichiasis, and uveal colobomas have been reported less commonly. The extensive intraocular involvement in these twins is rare in TCS. Furthermore, aniridia, corneal scleralisation, and uveal, lens, and retinal maldevelopment are previously unreported.

TCS is an autosomal dominant disorder affecting one in 50 000 live births. The disorder appears to have arisen in these twins with no relevant family history, as occurs in 60% of cases.⁵ Expressivity is highly variable, ranging from clinically undetectable to perinatal death secondary to airway compromise⁶; the disease severity that resulted in the fetal death of twin A is highly unusual. The responsible gene, *TCOF1*, has been mapped to 5q32-33.2⁷ and the structure of its protein product, treacle, elucidated.⁸ To date, 51 disease causing mutations have been identified,⁹ nearly all resulting in a premature termination codon.¹⁰ Significantly, no relation has been found between any single mutation and phenotype severity. The ophthalmic pathology observed in these twins may have resulted from a focal *TCOF1* mutation and a yet to be defined role treacle may have in eye (and renal) development. Considering the number and severity of abnormalities, the failure to identify a single "genetic hot spot," and the novel ophthalmic features, an alternative and perhaps more likely explanation is that a second gene, itself involved in ophthalmic embryology, was affected along with *TCOF1*. This unidentified gene may have been disrupted from a translocation involving 5q32-33.2 or from a deletion large enough to result in a contiguous gene syndrome. A final consideration is that these twins may not have had TCS but rather a new though closely related syndrome. Further genetic investigation may shed light upon these speculations.

Acknowledgements

JLP and GB contributed equally to this work.

J L Prenner, G Binenbaum, D F Carpentieri, S M Goldstein, R S Douglas, E Ruchelli, J A Katowitz
Scheie Eye Institute, Department of Ophthalmology, University of Pennsylvania; Departments of Pediatric Ophthalmology and Pathology, Children's Hospital of Philadelphia; Philadelphia, Pennsylvania, USA

R W Hertle

The Laboratory of Sensorimotor Research, The National Eye Institute, The National Institutes of Health; Bethesda, Maryland, USA

Correspondence to: J L Prenner, MD, Department of Ophthalmology, Scheie Eye Institute, University of Pennsylvania, 51 North 39th Street, Philadelphia, PA 19106, USA; jlprenner@excite.com

Accepted for publication 7 September 2001

References

- 1 Van der Meulen J, Mazzola R, Stricker M, et al. Classification of craniofacial malformations. In: Stricker M, Van der Meulen J, Raphael B, Mazzola R, eds. *Craniofacial malformations*. New York: Churchill Livingstone, 1989:149-309.
- 2 Phelps PD, Poswillo D, Lloyd GAS. The ear deformities in mandibulo-facial dysostosis. *Clin Otolaryngol* 1981;61:15-28.

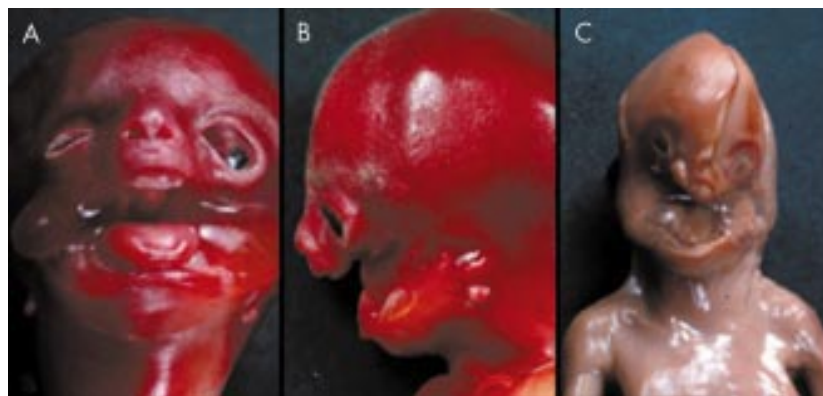

Figure 1 Gross photographs of fetal twins with features of Treacher Collins syndrome: (A) and (B) are twin B (21 weeks of gestational age); (C) is twin A (16 weeks of gestational age).

- 3 **Robb LJ**. Treacher Collins-Franceschetti syndrome with tracheoesophageal fistula, rectovaginal fistula, and anal atresia: variant or new syndrome? *Am J Med Genet* 1991;**39**:119–20.
- 4 **Hertle RW**, Ziyilan S, Katowitz JA. Ophthalmic features and visual prognosis in the Treacher-Collins syndrome. *Br J Ophthalmol* 1993;**77**:642–5.
- 5 **Jones KL**, Smith DW, Harvey MA, *et al*. Older paternal age and fresh gene mutation: data on additional disorders. *J Pediatr* 1975;**86**:84–8.
- 6 **Edwards SJ**, Fowle A, Cust MP, *et al*. Prenatal diagnosis in Treacher Collins syndrome using combined linkage analysis and ultrasound imaging. *J Med Genet* 1996;**33**:603–6.
- 7 **Treacher Collins Syndrome Collaborative Group**. Positional cloning of a gene involved in the pathogenesis of Treacher Collins syndrome. *Nat Genet* 1996;**12**:130–6.
- 8 **Wise CA**, Chiang LC, Paznekas WA, *et al*. TCOF1 gene encodes a putative nucleolar phosphoprotein that exhibits mutations in Treacher Collins syndrome throughout its coding region. *Proc Natl Acad Sci* 1997;**94**:3110–5.
- 9 **Splendore A**, Silva EO, Alonso LG, *et al*. High mutation detection rate in TCOF1 among Treacher Collins syndrome patients reveals clustering of mutations and 16 novel pathogenic changes. *Hum Mutat* 2000;**16**:315–22.
- 10 **Edwards SJ**, Gladwin AJ, Dixon MJ. The mutational spectrum in Treacher Collins syndrome reveals a predominance of mutations that create a premature-termination codon. *Am J Hum Genet* 1997;**60**:515–24.

Acute postural drop in optic nerve perfusion after vitrectomy and gas in a patient with diabetic autonomic neuropathy

We report the case of an insulin dependent diabetic who suffered transient blindness as a result of a change of posture following vitrectomy surgery with injection of gas.

This 34 year old woman with longstanding diabetic disease, postural hypotension, and proliferative retinopathy had undergone argon laser panretinal photocoagulation (PRP) to both eyes. Her right eye was amblyopic and had visual acuity of counting fingers (CF), whereas the left eye, at best, had vision of 6/12 that was frequently impaired by recurrent vitreous haemorrhage. She underwent left vitrectomy and required 30% sulphur hexafluoride (SF₆) gas to support an incidental small, inferior detachment related to a round hole. The patient postured supine overnight and remained under the care of the physicians.

The following day her vision dropped suddenly and severely on her way to the eye clinic. Visual acuity was no perception of light (NPL) in the operated eye and CF in the right eye. The left pupil was already dilated and anterior segment examination was satisfactory. The view of the fundus was limited owing to the presence of gas and residual haemorrhage but the retina was flat. The intraocular pressure (IOP) was 42 mm Hg and her blood pressure (BP) was 70/40. A decision to withdraw 0.5 ml of gas from the eye was made. While the patient was lying down for this procedure she immediately noted an improvement in vision to light perception. Her blood pressure improved in the supine position to 150/80. Following removal of gas the IOP fell to 20 mm Hg and the vision improved to counting fingers. Four weeks later, with disappearance of the gas her best corrected vision had improved to 6/18 and the retina remained flat.

Comment

Judging by the severity of the visual loss we believe that it was due to obstruction of both the central retinal artery and optic nerve perfusion. The precipitating factor in this case would appear to have been the change in posture from supine to erect. The presence of gas in the operated eye had raised the intraocular pressure to a level such that the perfusion pressure to the eye was effectively eliminated resulting in a period of no light perception. Restoring the patient to the supine position was sufficient alone to reverse the condition and improve the perfusion of the eye. When the IOP was reduced to normal she was out of this critical situation and was able to maintain the ocular perfusion, even when sitting.

Collapse of the central retinal artery is known to occur in conditions of high IOP¹ but vision does not fluctuate with posture. However, it is known that raised IOP also reduces orthograde axonal transport and compromises nerve head perfusion.²

Postural hypotension in diabetics is secondary to autonomic neuropathy. The pathophysiology is not clear but it seems the main factor is blunted catecholamine response to standing and failure of the lower limb vascular resistance to increase adequately.³ Systemic hypotension can reduce optic nerve blood flow as illustrated by numerous reports in the literature of non-arteritic anterior ischaemic optic neuropathy (NA-AION) occurring following acute blood loss.^{4,5} Patients with NA-AION have a significantly greater postural pressure change in IOP compared with healthy subjects as shown by James and Smith.⁷ In the same study they demonstrated a higher pulsatile ocular blood flow (POBF) on standing compared with supine. In this patient with autonomic neuropathy it is likely that the normal increase in POBF on standing was inadequate.

We advise particular caution in diabetics undergoing ocular surgery in which there may be a significant postoperative pressure rise. Similar problems can occur during surgery if hypotensive anaesthesia is either deliberately or inadvertently employed in diabetics. Beware of assuming poor postoperative vision to be purely the result of the presence of haemorrhage or gas; patients may have quite poor vision immediately after vitreoretinal surgery but will rarely have NPL unless there is also optic nerve compromise. We also suggest one should to aim for a lower postoperative IOP in diabetics.

A Al Khaier, J C Khan, R L Burton

Department of Ophthalmology, The West Norwich Hospital, Bowthorpe Road, Norwich NR2 3TQ, UK

Correspondence to: Mr Burton;
ted.burton@norfolk-norwich.thenhs.com

Accepted for publication 12 September 2001

References

- 1 **Abrams GW**, Swanson DE, Sabates WI, *et al*. The result of sulfur hexafluoride gas in vitreous surgery. *Am J Ophthalmol* 1982;**94**:165.
- 2 **Hayreh SS**, March W, Anderson DR. Pathogenesis of block of rapid orthograde axonal transport by elevated intraocular pressure. *Exp Eye Res* 1979;**28**:515–23.
- 3 **Pureval TS**, Goss DE, Zanone MM, *et al*. The splanchnic circulation and postural hypotension in diabetic autonomic neuropathy. *Diabet Med* 1995;**12**:513–22.
- 4 **Sharma R**, Desai S. Postpartum haemorrhage producing acute ischaemic optic neuropathy. *Asia Oceania J Obstet Gynaecol* 1993;**19**:249–51.
- 5 **Connolly SE**, Gordon KB, Horton JC. Salvage of vision after hypotension induced ischaemic

optic neuropathy. *Am J Ophthalmol* 1994;**117**:235–42.

- 6 **Chopra KB**, Banka NH, Chandalia HB. Bilateral optic nerve infarction following acute systemic hypotension and anaemia, a case report. *Indian J Ophthalmol* 1992;**40**:66–9.
- 7 **James CB**, Smith SE. The effect of posture on the intraocular pressure and pulsatile ocular blood flow in patients with non-arteritic anterior ischaemic optic neuropathy. *Eye* 1991;**5** (Pt 3):309–14.

Optical coherence tomography imaging of severe commotio retinae and associated macular hole

Commotio retinae results in retinal opacification following blunt trauma. Mild commotio retinae usually settles spontaneously with minimal sequelae but more severe cases are associated with visual loss. We are not aware of any previous reports describing optical coherence tomography (OCT) imaging of severe commotio retinae with an associated full thickness macular hole (FTMH).

Case report

A 15 year old boy presented 24 hours after blunt trauma from a football striking his right eye. On examination his best corrected visual acuity was counting fingers right eye and 6/6 left. Biomicroscopic examination revealed extensive commotio retinae over the posterior pole, no posterior vitreous detachment (PVD), and a FTMH. Colour photography and OCT imaging (OCT 2000 scanner, Zeiss-Humphrey) were performed (Fig 1). OCT confirms a FTMH and demonstrates extensive disruption of photoreceptor outer segments and retinal pigment epithelium (RPE).

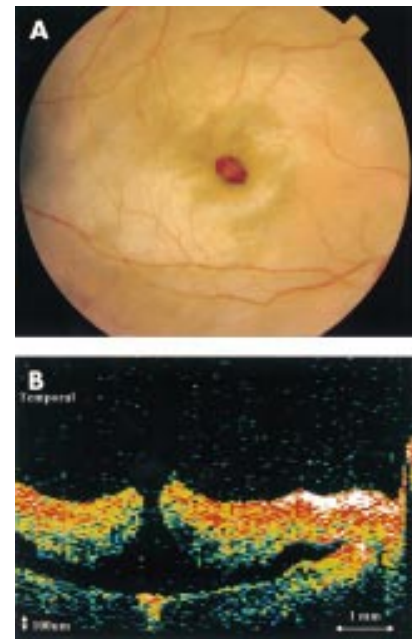


Figure 1 (A) Right macula of 15 year old boy with extensive commotio retinae over posterior pole and an associated macular hole at 1 day after blunt injury. (B) Horizontal OCT scan through centre of macula confirms a full thickness macular hole and demonstrates extensive disruption of photoreceptor outer segment/retinal pigment epithelium layer. The optic disc is seen at the nasal edge of the scan.

He was treated conservatively with a short course of topical steroids. The colour fundus and OCT appearance at 1 month are shown in Figure 2. Despite spontaneous macular hole closure, visual acuity remained at counting fingers at 1 year follow up.

Comment

The major site of retinal trauma appeared on OCT to be at the level of the photoreceptor outer segment/RPE interface. The OCT images are consistent with fragmentation of photoreceptor outer segments and damaged cell bodies, as suggested by Sipperley *et al*¹ in their study of the histological changes in commotio retinae in primates.

The exact pathogenesis of macular holes remains uncertain. Ho *et al*² outlined the three basic historical theories regarding aetiology—the traumatic theory, the cystic degeneration and vascular theory, and the vitreous theory. Of these, the latter has gathered the most support in the context of idiopathic macular holes.

In our case, the OCT imaging reveals that the edges of the macular hole are elliptical and irregular with no associated PVD, cortical vitreous condensation, or overlying prefoveal opacity. The characteristics suggest a different mechanism of hole formation from that proposed in idiopathic senile macular holes. We believe that mechanical distortion of the retina, relative to the vitreous and underlying sclera, created disruption of the photoreceptor outer segments and creation of a FTMH in this case. It is at the fovea and photoreceptor outer segment level that the retina has the least support from Müller cells and is therefore likely to undergo greatest deformation.

In the only previous report of OCT imaging in traumatic macular hole, a case with mild commotio retinae was described in which

extensive outer retinal disruption was not observed.³ There have been some encouraging reports suggesting that vitrectomy can successfully close traumatic macular holes as well as improve visual function in many cases.^{4,5} However, it seems unlikely that cases with severe commotio retinae, and associated photoreceptor/RPE damage, as demonstrated in our cases, would gain any benefit from surgical as opposed to spontaneous closure of a traumatic FTMH. The final visual prognosis is severely limited by the extent of initial photoreceptor damage, and the excessive pigment atrophy and clumping that follows.

We believe OCT imaging provides additional information both on the pathogenesis of commotio retinae and in the assessment of outer retina disruption following ocular trauma. This information may help in the selection of patients likely to benefit from surgical intervention.

R Ismail, V Tanner

Royal Berkshire Hospital, London Road, Reading, RG1 5AN, UK

T H Williamson

St Thomas's Hospital, Lambeth Palace Road, London SE1 7EH, UK

Correspondence to: Mr V Tanner; tannerone@aol.com

Accepted for publication 26 September 2001

References

- 1 Sipperley JO, Quigley HA, Gass DM. Traumatic retinopathy in primates. The explanation of commotio retinae. *Arch Ophthalmol* 1978;**96**:2267–73.
- 2 Ho AC, Guyer DR, Fine SL. Macular hole. *Surv Ophthalmol* 1998;**42**:393–416.
- 3 Parmar DN, Stanga PE, Reck AC, *et al*. Imaging of a traumatic macular hole with spontaneous closure. *Retina* 1999;**19**:470–2.
- 4 Amari F, Ogino N, Matsumura M, *et al*. Vitreous surgery for traumatic macular holes. *Retina* 1999;**19**:410–3.
- 5 Johnson RN, McDonald R, Lewis H, *et al*. Traumatic macular hole. Observations, pathogenesis, and results of vitrectomy surgery. *Ophthalmology* 2001;**108**:853–7.

Acute ocular ischaemia and orbital inflammation associated with systemic lupus erythematosus

We report a patient with systemic lupus erythematosus (SLE) who developed bilateral ocular ischaemic syndrome in association with orbital inflammation leading to devastating visual loss.

Case report

A 73 year old white woman presented with unilateral acute anterior uveitis and polyarthropathy of the hands, knees, and neck. Over the next 4 years she suffered recurrent anterior uveitis, marginal keratitis, and episcleritis, which were treated with topical steroids. She had bilateral age related cataract and underwent left cataract surgery. Postoperatively, her visual acuities were 6/60 right eye and 6/9 left eye.

She was admitted 7 months later with extensive erythematous, scaly plaques on sun exposed areas and a purpuric eruption over the abdomen, buttocks, and legs. Biopsy of a plaque showed changes consistent with SLE including follicular keratin plugging, epidermal atrophy, degeneration of the basal layer with colloid body formation, basement membrane thickening, myxoid change in the

dermis, and periappendageal lymphocyte infiltrates. Biopsy of the purpuric eruption was consistent with a leucocytoclastic vasculitis. Further investigations revealed positive rheumatoid factor (1/100), ANA (1/25), pANCA (1/100), and anti-EN antibodies (1/100). There was reduced C₃ and C₄, polyclonal increase in IgA and IgM, lymphopenia, thrombocytopenia, and reduced creatinine clearance but no proteinuria. Anticardiolipin antibodies were negative. A diagnosis of SLE was made and oral prednisolone (0.8 mg/kg) was commenced.

Three weeks later she developed a rapid onset of marked bilateral conjunctival and lid oedema, subconjunctival haemorrhage, and proptosis. Visual acuity deteriorated to perception of light in each eye. There was gross restriction of ocular movements. Signs of ocular ischaemia developed in both eyes with corneal oedema, iris neovascularisation, fibrous anterior uveitis, hyphaema, and raised intraocular pressure (Fig 1). Computed tomography and B-scan ultrasonography of the orbits showed posterior scleritis, choroidal detachment, vitreous haemorrhage, and thickening of the extraocular muscles (Fig 2).

She was treated with topical dexamethasone 0.1% and carteolol 1%, oral acetazolamide 500 mg daily, intravenous cyclophosphamide (10 mg/kg), and subsequently intravenous immunoglobulin (0.5 g/kg/day for 3 days). Over the following month there was regression of the proptosis, conjunctival and lid oedema, corneal oedema, and fibrous uveitis. The intraocular pressure was controlled and the visual acuity remained perception of light in each eye. Subsequently, the patient developed pneumonia, VIIIth nerve palsy, left sided hemiparesis, and died 7 weeks after admission. Postmortem examination revealed bronchopneumonia, lung abscess, pleural effusions, fibrous pericarditis, cardiomegaly, and jejunal mucosal haemorrhages.

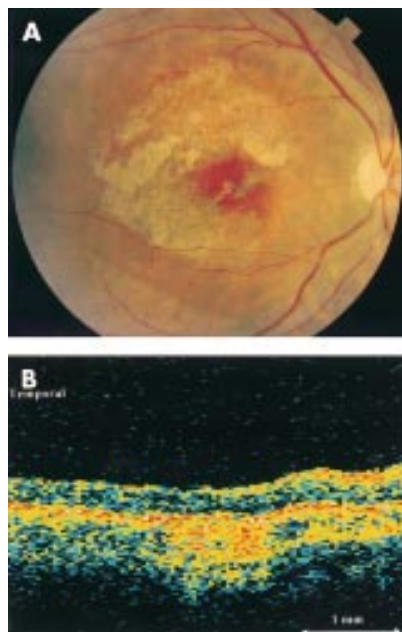


Figure 2 (A) Right macula 1 month after injury with extensive retinal pigment epithelium disruption, marked epiretinal membrane, and spontaneous closure of the macular hole. (B) Horizontal OCT scan through centre of right macula confirms resolution of commotio retinae, spontaneous closure of macular hole, and disruption of the photoreceptor/retinal pigment epithelium reflex.

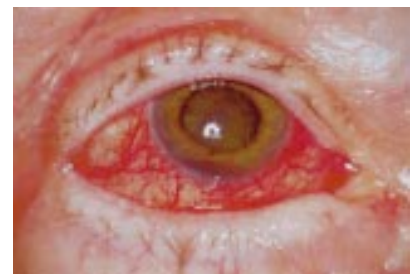

Figure 1 Anterior segment of right eye showing conjunctival injection, corneal oedema, hyphaema, rubeosis iridis, and cataract

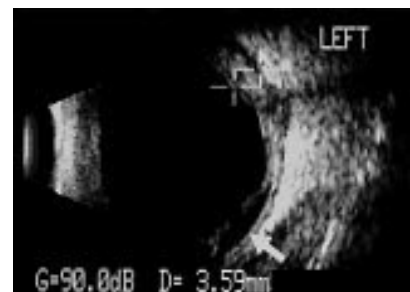

Figure 2 B-scan ultrasound of left eye showing marked posterior scleritis (crosses) and choroidal detachment (arrow).

The family did not consent to histopathological examination of the eyes.

Comment

Acute orbital inflammation and orbital myositis leading to proptosis are rare manifestations of SLE.^{1,2} To our knowledge acute ocular ischaemic syndrome with orbital inflammation is a novel complication of SLE. The ophthalmic manifestations may have resulted from a vasculitis involving the vessels supplying the globe and extraocular muscles. The limitation of ocular movements was most probably the result of mechanical restriction. Although the proptosis, lid and conjunctival oedema improved with immunosuppression, the visual acuity did not recover. This may have been because of irreversible visual loss from optic nerve dysfunction due to ischaemia, compression from the acute orbital inflammation, or secondary to raised intraocular pressure. Close cooperation between ophthalmologist and rheumatologist is essential in the management of these patients, in order to try and prevent blindness.

P Stavrou, P I Murray

Birmingham and Midland Eye Centre,
City Hospital NHS Trust, Birmingham, UK

K Batta

Birmingham Skin Centre,
City Hospital NHS Trust, Birmingham, UK

C Gordon

Department of Rheumatology,
City Hospital NHS Trust, Birmingham, UK

Correspondence to: Professor P I Murray, Academic Unit of Ophthalmology, Division of Immunity and Infection, Birmingham and Midland Eye Centre, City Hospital NHS Trust, Birmingham B18 7QU, UK; P.I.Murray@bham.ac.uk

Accepted for publication 10 October 2001

References

- 1 **Brenner EH**, Shock JP. Proptosis secondary to systemic lupus erythematosus. *Arch Ophthalmol* 1974;**91**:81–2.
- 2 **Wildinson LS**, Panush RS. Exophthalmos associated with systemic lupus erythematosus. *Arthritis Rheum* 1975;**18**:188–9.
- 3 **Grimson BS**, Simons KB. Orbital inflammation, myositis and systemic lupus erythematosus. *Arch Ophthalmol* 1983;**101**:736–8.
- 4 **Bankhurst AD**, Carlow TJ, Reidy RW. Exophthalmos in systemic lupus erythematosus. *Ann Ophthalmol* 1984;**16**:669–71.
- 5 **Fossaluzza V**, Dal Mas P. Proptosis and systemic lupus erythematosus. *Clin Exp Rheumatol* 1987;**5**:192–3.
- 6 **Gray RE**, Jenkins EA, Hall MA, et al. Recurrent acute proptosis in atypical systemic lupus erythematosus. *Clin Rheumatol* 1989;**8**:528–32.
- 7 **Serop S**, Vianna RN, Claeys M, et al. Orbital myositis secondary to systemic lupus erythematosus. *Acta Ophthalmol* 1994;**72**:520–3.

Chickenpox neuroretinitis in a 9 year old child

Chickenpox in children is usually thought of as a benign infectious disease with few ocular complications. Posterior segment involvement from primary varicella zoster infection has rarely been reported in children. We describe the clinical features and visual outcome of an unusual case of neuroretinitis presenting in a 9 year old child.

Case report

An immunocompetent 9 year old boy acquired primary varicella zoster virus (VZV) infection

from his sibling and developed the characteristic exanthematous vesicular rash. Four days after the onset of the rash he woke with discomfort in his right eye and described his vision as being "all grey" on that side. He presented to the emergency department the same day and was found to have a visual acuity of 3/6 on the right and 3/3 on the left (logMAR). A relative afferent pupillary defect (RAPD) was present on the right. His anterior segment was quiet with no vitritis; however, he had slight macular thickening and a subtle cherry red spot on funduscopy, along with some mild peripapillary swelling and disc haemorrhage.

On review in the ophthalmology clinic 2 days later his vision had reduced to 1/60 (Sheridan Gardiner singles) on the right. He had no new skin lesions and all those present had crusted. No lid lesions were present. He had a marked RAPD, red desaturation, and mild conjunctival injection. His anterior segment and vitreous remained clear. The right disc was hyperaemic with peripapillary swelling and haemorrhage. The macular area was pale and oedematous (Fig 1). Examination of the left eye was completely normal.

Considering the onset of ocular symptoms and signs following the appearance of the typical VZV skin lesions, a presumptive diagnosis of chickenpox neuroretinitis was made. He was admitted and commenced on intravenous aciclovir (250 mg × 3 per day). Confirmatory IgM titres for VZV were unfortunately not performed. No change in his acuity was observed over the next few days; however, his right disc was noted to become slightly pale after 2 days of treatment. At this point intravenous methyl prednisolone was instituted at a dose of 5 mg/kg per day. Despite a gradual resolution of the macular and peripapillary oedema over the next 5 days, his disc remained pale (Fig 2) and his acuity measured as 3/30 (logMAR) after 7 days of intravenous aciclovir and 5 days of methyl

prednisolone. Systemically he remained completely well and afebrile on treatment. He was discharged with a further 3 day course of oral aciclovir and a 6 day reducing course of oral prednisolone.

Over 5 months of follow up his acuity has not improved beyond 3/30 (logMAR). The right optic disc is pale and a yellow lipid deposit is present at the macula with some reticular macular pigmentation. The left eye has been normal throughout.

Comment

Posterior segment involvement as part of primary VZV infection in children has only been reported twice to our knowledge. Copenhaver¹ reported a 3 year old with bilateral papillitis and a unilateral macular lesion associated with encephalitis following VZV infection. In this case there was complete recovery of vision and resolution of the macular lesion within 3 weeks of presentation. Capone and Meredith² describe a case of unilateral central visual loss in a 2 year old child caused by chickenpox retinitis with optic neuritis resulting in a poor visual outcome. Their patient presented with an acute exotropia 24–48 hours before the onset of cutaneous VZV. Funduscopy revealed papillitis, phlebitis, and a macular lipid star; retinal opacification just outside the arcades and scattered intraretinal haemorrhages were also described. In these two cases sequential acuity measurement or photography were not possible because of the young age of the subjects.

Our case is particularly interesting, not only because these are the first published fundal photographs of VZV neuroretinitis in a child, but also because of the relatively mild ocular findings which have resulted in severe visual loss. The young age of the patient is atypical of ocular VZV infection.³ Adults who contract primary VZV infection tend to run a more severe course than children.⁴ Ocular complications in children are extremely rare.⁵

The typical posterior segment involvement of VZV is acute retinal necrosis (ARN).⁶ The youngest case of ARN in association with chickenpox has been reported in a 4 year old.⁵ In adults, ARN is described as being less severe when presenting at the time of primary zoster infection than as a result of secondary reactivation of latent, previously acquired VZV.⁶ The changes typical of ARN were absent in this case. Unilateral papillitis and retinitis confined to the macular area were the main features. Optic neuritis has been reported by several authors in association with primary VZV.^{7–9} Many of these cases are bilateral and coincident with encephalitis⁷ or occurring in those who are immunocompromised.⁸ Unilateral optic neuritis has been described in an 18 year old several weeks following a varicella rash which remitted without sequelae following the administration of corticosteroid.⁹

The mainstay of treatment of VZV retinitis is with intravenous aciclovir. Whether any advantage is gained in administering systemic steroid with the aciclovir is controversial.⁴ We do not know if a more positive visual outcome may have been achieved if intravenous therapy had been commenced on presentation. It is therefore suggested that prompt treatment of VZV retinitis with intravenous aciclovir be started in patients, particularly in a child, presenting with any posterior segment signs.

**J R MacKinnon, T Lim Joon,
J E Elder**

Department of Ophthalmology, Royal Children's Hospital, Melbourne, Australia

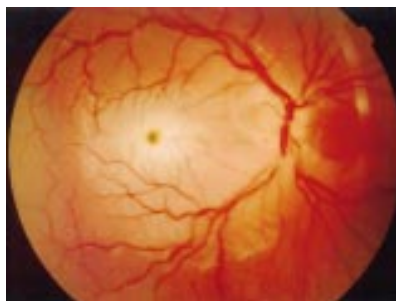

Figure 1 Right fundus: neuroretinitis with loss of vision to 1/60.

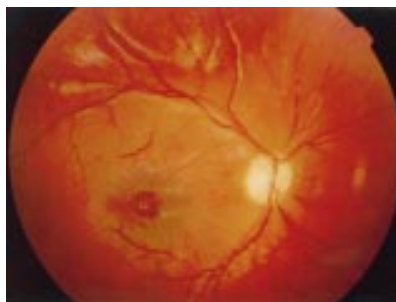

Figure 2 Right fundus: following treatment with intravenous aciclovir and methyl prednisolone.

Correspondence to: Jane R MacKinnon, Department of Ophthalmology, Aberdeen Royal Infirmary, Foresterhill, Aberdeen AB25 2ZD, UK; janermackinnon@hotmail.com

Accepted for publication 17 October 2001

References

- 1 Copenhaver RM. Chickenpox with retinopathy. *Arch Ophthalmol* 1966; **75**:199–200.
- 2 Capone A, Meredith TA. Central visual loss caused by chickenpox retinitis in a 2-year-old child. *Am J Ophthalmol* 1992; **113**:592–3.
- 3 Van Gelder RN, Willig JL, Holland GN, et al. Herpes simplex virus type 2 as a cause of acute retinal necrosis syndrome in young patients. *Ophthalmology* 2001; **108**:869–76.
- 4 Yoser SL, Forster DJ, Rao NA. Systemic viral infections and their retinal and choroidal manifestations. *Surv Ophthalmol* 1993; **37**:313–52.
- 5 Lee WH, Charles SJ. Acute retinal necrosis following chickenpox in a healthy 4 year old patient. *Br J Ophthalmol* 2000; **84**:667–8.
- 6 Culbertson WW, Brod RD, Flynn HW, et al. Chickenpox-associated acute retinal necrosis syndrome. *Ophthalmology* 1991; **98**:1641–5.
- 7 Selbst RG, Selhorst JB, Harbison JW, et al. Parainfectious optic neuritis. Report and review following varicella. *Arch Neurol* 1983; **40**:347–50.
- 8 Lee MS, Cooney EL, Stoessel KM, et al. Varicella zoster virus retrobulbar optic neuritis preceding retinitis in patients with acquired immune deficiency syndrome. *Ophthalmology* 1998; **105**:467–71.
- 9 Pina MA, Ara JR, Capablo JL, et al. Myelitis and optic neuritis caused by varicella. *Rev Neurol* 1997; **25**:1575–6.

Bilateral central retinal artery occlusion in Wegener's granulomatosis and α_1 antitrypsin deficiency

Visual loss occurs in up to 8% of patients with Wegener's granulomatosis (WG) during the disease lifetime,¹ although only a small proportion of these cases are the result of central retinal artery occlusion (CRAO). We describe an unusual case of a patient with bilateral CRAO as a presenting feature of WG and α_1 antitrypsin (AAT) deficiency.

Case report

A 58 year old white man presented with sudden painless loss of vision to the right eye. Vision was hand movements in the right eye and 6/6 in the left. Funduscopy revealed an acute right CRAO with macular oedema. There were no signs of uveitis or retinal vasculitis. Management consisted of intravenous acetazolamide (500 mg), ocular massage, and anterior chamber paracentesis. He was subsequently sent home with aspirin treatment, and referred to his family doctor for routine risk factors assessment.

The following morning, he returned to the eye casualty department with a left CRAO, which was treated in the same way. Vision was 6/60 in the right eye and hand movements in the left. Systemic inquiry revealed a 2 month history of general malaise, arthralgia, and myalgia. General examination revealed evidence of vasculitic rash (Fig 1) affecting the right elbow and nailfold infarcts (Fig 2). He was admitted for further investigation. His erythrocyte sedimentation rate in the first hour was 128 mm and C reactive protein (171 mg/l) were markedly raised. Liver enzymes were slightly abnormal (γ GT, 165 IU/l, ALT, 85, alkaline phosphatase, 153). There were traces of blood and protein in the urine, with a normal creatinine clearance (86 mmol/l). He was commenced on oral prednisolone

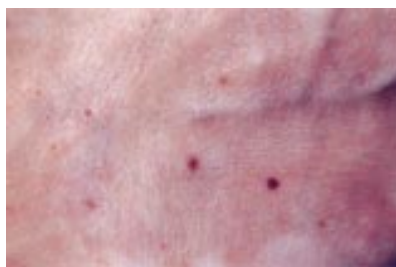

Figure 1 Photograph of right elbow showing vasculitic rash.

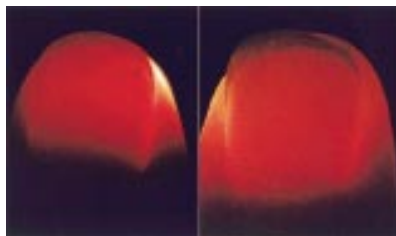


Figure 2 Retroillumination photograph of right and left index fingers showing nailfold infarcts.

(60 mg/day) for presumed systemic vasculitis. Normal echocardiography and blood cultures excluded endocarditis. Ultrasound of his carotid arteries was normal. His vision gradually improved, and was recorded 6 days later as 6/12 in the right eye and 6/6 in the left. Patchy peripheral field defects remained.

Subsequently, his serum was positive for cytoplasmic antineutrophil cytoplasmic antibody (cANCA) at a titre of 1/160, confirming the diagnosis of WG. Monthly pulses of intravenous cyclophosphamide were employed, with gradual tapering of oral prednisolone dose. There was also an incidental finding of homozygous AAT deficiency (Z allele) from serum protein electrophoresis.

Comment

WG is a rare disease with a reported annual incidence of 8.5 per million population² in the UK, of which up to 16% present initially with ocular disease.³ CRAO in patients with WG is rare, with only several reported cases^{3–4} since 1960. Ocular and ocular adnexal involvement is the result of parenchymal necrosis, small vessel vasculitis, and granulomatous inflammation. The orbit may be the site of primary inflammation or become secondarily involved from disease of the paranasal sinuses and nasopharynx. Mechanisms by which visual loss occurs in WG include vascular occlusion, macular oedema, inflammatory destruction of retina, optic nerve, or corneoscleral tissue.³ Systemically, the most commonly affected tissues are the lungs and kidneys. The current therapy for WG is cyclophosphamide (daily or pulse) and corticosteroids. Multicentre trials are in progress to assess the optimum treatment duration for induction, and subsequent maintenance of remission.⁵

This is the first reported case of bilateral CRAO in WG and AAT deficiency. AAT is normally present in serum and inhibits uncontrolled enzymic destruction of connective tissue during inflammation. Deficiency of AAT results in progressive emphysema and liver injury.⁶ Research suggests an increased incidence of WG in patients with AAT deficiency.⁷ The incidence of AAT deficiency has been reported as being significantly increased in

patients with anterior uveitis.⁸ We are not aware of any reports implicating AAT deficiency in CRAO, although it is possible that this is contributing to the ongoing inflammatory process underlying his vasculitis.

S C Wong, R L Boyce, T C Dowd

Department of Ophthalmology, North Riding Infirmary, Middlesbrough, UK

J N Fordham

Department of Rheumatology, James Cook University Hospital, Middlesbrough, UK

Correspondence to: Dr Sui Chien Wong, Department of Ophthalmology, North Riding Infirmary, Newport Road, Middlesbrough, TS1 5JE, UK

Accepted for publication 19 October 2001

References

- 1 Hoffman GS, Kerr GS, Leavitt RY. Wegener granulomatosis: an analysis of 158 patients. *Ann Intern Med* 1992; **116**:488–98.
- 2 Carruthers DM, Watts RA, Symmons DP, et al. Wegener's granulomatosis—increased incidence or increased recognition? *Br J Rheumatol* 1996; **35**:142–5.
- 3 Harman LE, Margo CE. Wegener's granulomatosis. *Surv Ophthalmol* 1998; **42**:458–80.
- 4 Lamprecht P, Lerin-Lozano C, Reinhold-Keller E, et al. Retinal artery occlusion in Wegener's granulomatosis. *Rheumatology* 2000; **39**:928–9.
- 5 Savage CO, Harper L, Cockwell P, et al. ABC of arterial and vascular disease: vasculitis [Review]. *BMJ* 2000; **320**:1325–8.
- 6 Perlmutter DH. Alpha-1-antitrypsin deficiency biochemistry and clinical manifestations. [Review]. *Ann Med* 1996; **28**:385–94.
- 7 Borgmann S, Endisch G, Urban S, et al. A linkage disequilibrium between genes at the serine protease inhibitor gene cluster on chromosome 14q32.1 is associated with Wegener's granulomatosis. *Clin Immunol* 2001; **98**:244–8.
- 8 Breit SN, Wakefield D, Robinson JP. The role of α_1 -antitrypsin deficiency in the pathogenesis of immune disorders. *Clin Immunol Immunopathol* 1985; **35**:363–80.

Complication of acupuncture in a patient with Behçet's disease

We would like to bring to your attention a complication resulting from acupuncture in a patient with Behçet's disease.

Case report

A 35 year old white man, who fulfilled the International Study Group criteria¹ for Behçet's disease, attended the Behçet's clinic at the Birmingham and Midland Eye Centre. He complained of four red areas on his left arm (Fig 1). Two days earlier he had undergone acupuncture for what he described as "tennis elbow." These red areas corresponded to where the acupuncture needles had been inserted. Examination revealed these areas to be pustules (inset) that were characteristic of a positive pathergy test.

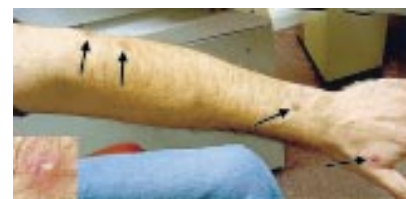

Figure 1 Arrows indicating pustules corresponding to a positive pathergy test. Inset: magnified image of one pustule.

Comment

A positive pathology test is an important diagnostic sign of Behçet's disease.¹ Its prevalence varies by geographic region, being less common in patients from Northern Europe. Nevertheless, patients with Behçet's disease should be made aware of this potential complication if they intend to undergo acupuncture.

P I Murray, N Aboteen

Birmingham and Midland Eye Centre, Birmingham B18 7QU, UK

Correspondence to: Professor P I Murray, Academic Unit of Ophthalmology, Division of Immunity and Infection, Birmingham and Midland Eye Centre, City Hospital NHS Trust, Dudley Road, Birmingham B18 7QU, UK; P.I.Murray@bham.ac.uk

Accepted for publication 22 October 2001

Reference

- 1 International Study Group For Behçet's Disease. Criteria for diagnosis of Behçet's disease. *Lancet* 1990;**335**:1078–80.

Corneoscleral fibrous histiocytoma

Fibrous histiocytomas of the corneoscleral limbus are rare tumours. We present a case report and a review of the clinical and histopathological findings from cases presented in the literature.

Case report

A 19 year old white male presented with a 6 month history of a painless growth on the inferior corneoscleral limbus of the left eye (Fig 1A and B). There were no other ocular symptoms. He had no medical history of note. His vision was 6/5 unaided in the right eye, and 6/6 unaided in the left eye. The growth was approximately 5 mm in diameter, vascularised, and yellowish in appearance. There were no other ocular abnormalities. The lesion was excised by conjunctival excision and superficial keratectomy under a general anaesthetic and sent for histopathological opinion.

Histological sections of the lesion showed a stromal hypercellular nodule consisting of spindle cells, small lymphocytes, multinucleated giant cells, and histiocytes. (Fig 1C–F). Some histiocytes had foamy cytoplasm. Many capillary sized blood vessels were present. In areas, the spindle cells were arranged in a storiform pattern. A fine collagenous meshwork extended throughout the lesion. Immunohistochemistry confirmed the cellular composition of the lesion (Fig 1G, H) as rich in macrophages (CD68), lymphoid cells (CD45), capillary sized blood vessels (CD34), and vimentin positive spindle cells. Mitotic figures were not evident after a careful search. The lesion was diagnosed as a benign fibrous histiocytoma. The tumour was incompletely excised and extended into the deep aspect of the lamella in the conjunctiva. However, 16 months after excision there has been no recurrence of the tumour.

Comment

Fibrous histiocytomas are soft tissue tumours and may be benign or malignant, the benign variety being the most common.¹ They are usually found on the extremities, but can occur in any part of the body, including orbital tissues. Fibrous histiocytomas account for 1% of all orbital tumours, and are the most common primary mesenchymal tumour of the orbit.² Benign fibrous histiocytomas have been reported in the orbit,³ eyelid,⁴ and

episclera.⁵ Symptoms and signs depend on the site, but may include decreased vision, pain, restricted eye movements, diplopia, and disc swelling. To date, there are only 18 cases of fibrous histiocytoma arising from the corneoscleral limbus reported in the literature^{1–6}; 11 of these were classified as benign. They usually present as painless masses and can develop at any age, but most commonly between the ages of 20–40 years. Their gross appearance is of a circumscribed yellow or white mass, and they may have focal areas of haemorrhage, which can make them appear brown or black in colour.

The histopathological appearance of a benign fibrous histiocytoma includes a mixture of fibroblastic and histiocytic cells that are often arranged in a cartwheel or storiform pattern, and accompanied by varying numbers of inflammatory cells, including foam cells and

siderophages. No atypical nuclei or mitotic figures are present. Although some authors regard these tumours as reactive proliferations of fibroblasts, others do not accept this view because the lesions tend not to regress spontaneously. Recurrence is rare, with less than 5% of cutaneous benign fibrous histiocytomas recurring after local excision.⁷

In contrast, malignant fibrous histiocytomas of the corneoscleral limbus characteristically appear in later life, between the ages of 50–70 years, with an equal distribution of males to females.¹ They are highly aggressive tumours, and have been reported to have a local recurrence rate of 100% if a limited excision is performed.⁸ Recurrence can occur within a few months of excision. There are seven reported cases of corneoscleral malignant fibrous histiocytoma. Two of the cases had an enucleation and two cases underwent orbital exenteration.

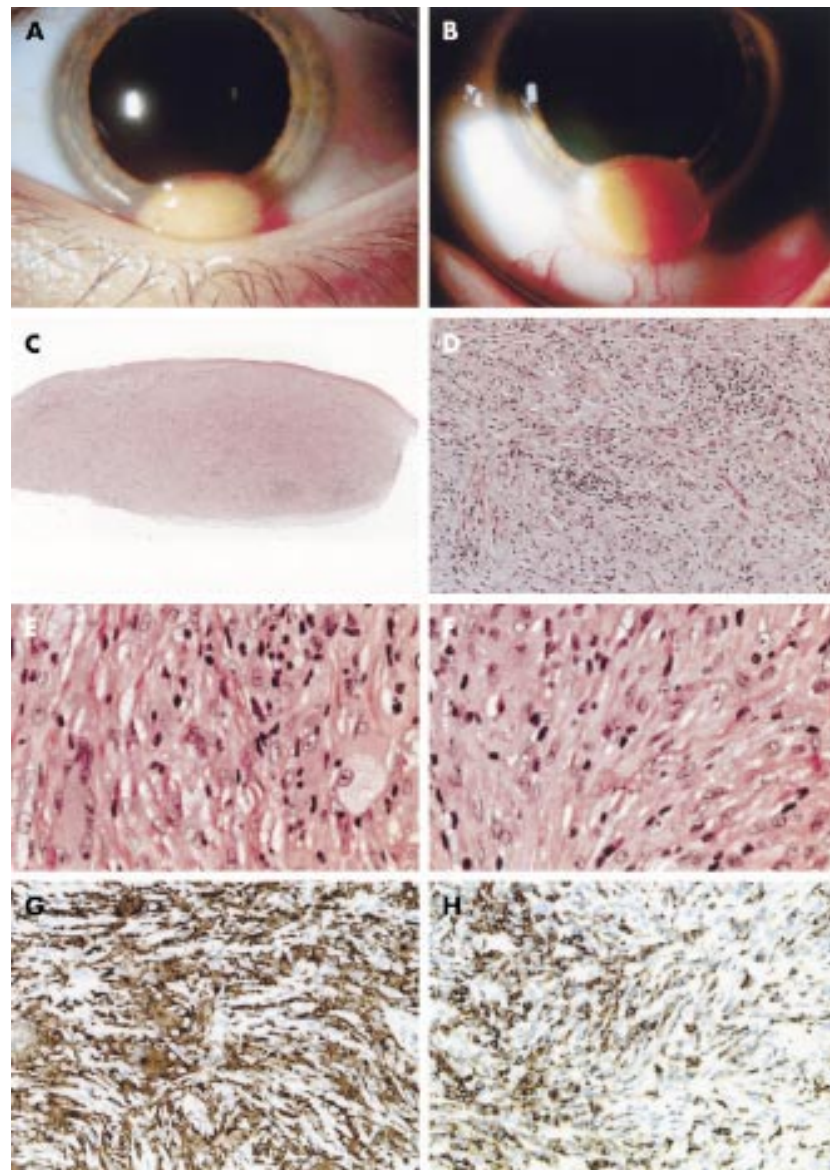


Figure 1 Fibrous histiocytoma arising from the corneoscleral limbus, showing the tumour extending into the cornea. It is moderately vascular and has a similar appearance to a dermoid. (B) Fibrous histiocytoma showing the inferior margin of the tumour. (C) Haematoxylin and eosin (H&E) stain, original magnification $\times 20$. (D) H&E stain, original magnification $\times 100$. (E) H&E stain, original magnification $\times 400$. (F) H&E stain, original magnification $\times 400$. (G) Immunoperoxidase CD68. Original magnification $\times 200$. (H) Immunoperoxidase CD45. Original magnification $\times 200$.

Follow up of these patients ranged from 18 months to 5 years and all were free from recurrence. The other three patients had a local excision. One patient developed local scleral recurrence 2 months later. (It is not evident from the literature if the borders of excision were clear of tumour.) He was found to have a metastasis in the "parotid gland" 4 months later, and even after a parotidectomy and radical neck dissection, the patient developed multiple pulmonary metastases and died within 1 year.⁹ One of the patients was lost to follow up. The third patient who had a local excision went on to develop two recurrences, which subsequently needed excision and cryotherapy.⁶ However, after 1 year he was free of any recurrence. Malignant fibrous histiocytomas have a broad range of histological appearances; storiform-pleomorphic, myxoid, giant cell, and inflammatory.¹⁰ The storiform-pleomorphic type is the most common. The cells are predominantly plump pleomorphic spindle-shaped with occasional large, ovoid histiocyte-like cells. Modest amounts of inflammatory cells, such as lymphocytes and plasma cells may be present. The differential diagnosis of a malignant fibrous histiocytoma includes pleomorphic carcinoma, malignant melanoma, and other sarcomas.

For those limbal fibrous histiocytomas with a benign histopathological appearance, the management should be local surgical excision. Malignant fibrous histiocytomas need to be managed cautiously, preferably by wide local excision and cryotherapy at the earliest opportunity. If necessary, enucleation should be considered to fully excise a limbal malignant fibrous histiocytoma.

C S Daniel, B J Clark, S J Tuft

Moorfields Eye Hospital, 162 City Road, London, EC1V 2PD, UK

Correspondence to: Miss Daniel, Department of Pathology, Institute of Ophthalmology, University College London, Bath Street, London EC1V 9EL, UK

Accepted for publication 22 October 2001

References

- Mietz H, Severin M, Arnold G, et al. Management of fibrous histiocytoma of the corneoscleral limbus: report of a case and review of the literature. *Graefes Arch Clin Exp Ophthalmol* 1997;**235**:87–91.
- Ulloa TK, Anderson SF. Orbital fibrous histiocytoma: case report and literature review. *J Am Optom Assoc* 1999;**70**:253–60.
- Font RL, Hidayat AA. Fibrous histiocytoma of the orbit. *Hum Pathol* 1982;**13**:199–209.
- Font RL. Eyelids and lacrimal drainage system. In: Spencer WH, ed. *Ophthalmic pathology: an atlas and textbook*. 4th ed. Philadelphia: WB Saunders, 1996:2218–437.
- Iwamoto T, Jakobiec FA, Darrel RW. Fibrous histiocytoma of the corneoscleral limbus. *Ophthalmology* 1981;**88**:1260–8.
- Allaire GS, Corriveau C, Teboul N. Malignant fibrous histiocytoma of the conjunctiva. *Arch Ophthalmol* 1999;**117**:685–7.
- Niemi KM. The benign fibrohistiocytic tumours of the skin. *Acta Dermatovener* 1970;**50**(suppl 63):1.
- Weiss SW. Malignant fibrous histiocytoma. A reaffirmation. *Am J Surg Pathol* 1982;**6**:773–84.
- Margo CE, Horton MB. Malignant fibrous histiocytoma of the conjunctiva with metastasis. *Am J Ophthalmol* 1989;**107**:433–4.
- Enzinger FM, Weiss SW. *Soft tissue tumours*. 3rd ed. St Louis: CV Mosby, 1995:351–466.

Haemophilus influenzae corneal ulcer associated with atopic keratoconjunctivitis and herpes simplex keratitis

Haemophilus influenzae is a rare cause of corneal ulceration, usually associated with previous corneal damage. To ensure appropriate treatment, the organism must first be identified by cultures in enriched media. We describe a case of keratitis caused by *H influenzae* associated with two risk factors—herpetic keratitis and atopic keratoconjunctivitis.

Case report

A 43 year old Hispanic male presented with 1 week of redness, blurred vision, pain, burning, and itching in the left eye. Past ocular history was remarkable for bilateral epithelial and interstitial herpetic keratitis and atopic keratoconjunctivitis with a previous shield ulcer in the left cornea. The patient was not using any medications at the onset of the current episode. He had a history of anhidrotic ectodermal dysplasia and atopic dermatitis since birth. On examination, uncorrected visual acuity was 20/100 in the left eye. The skin of the eyelids was wrinkled, thickened, and hyperpigmented bilaterally with madarosis of the lashes. The conjunctiva had a mild papillary reaction on the right and a severe reaction on the left, with giant papillae in the superior tarsal area. In the left eye, corneal sensation was markedly decreased and a central corneal epithelial defect of 1.0 × 0.5 mm was present with an underlying anterior stromal infiltrate measuring 2.5 × 1.5 mm (Fig 1). Scant keratic precipitates and a small hypopyon were also present.

Scrapings of the corneal ulcer were taken and inoculated on blood and chocolate agar as well as in thioglycollate broth. Viral cultures and polymerase chain reaction (PCR) were also performed to rule out the possibility of a recurrent herpes simplex infection. They were subsequently negative. The patient was started on ofloxacin and fortified cefazolin (50 mg/ml) drops every hour. He was also started on oral aciclovir 800 mg five times a day. On the fourth day, corneal cultures were positive with a heavy growth of *H influenzae* sensitive to ofloxacin (Fig 2). On the sixth day of treatment, uncorrected visual acuity improved to 20/30, the stromal infiltrate decreased to 1 × 1 mm, with a small epithelial defect, and there was no hypopyon. A supratarsal injection of dexamethasone was given and topical prednisolone acetate 1% three times a day was added. The papillae regressed and the corneal lesion healed completely, leaving a central scar with a deep stromal vessel.

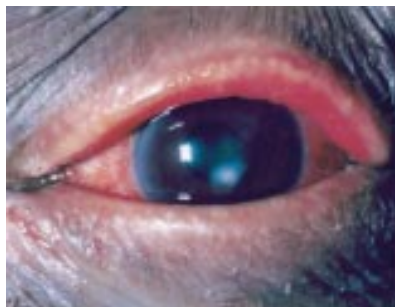


Figure 1 *Haemophilus influenzae* corneal ulcer.

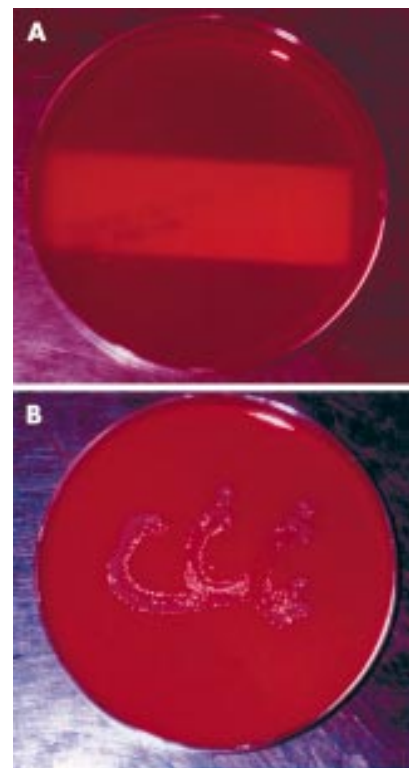


Figure 2 Corneal cultures: (A) no bacterial growth on blood agar; (B) heavy growth of *H influenzae* on chocolate agar.

Comment

H influenzae is a tiny Gram negative coccobacillus that is an uncommon cause of corneal ulceration. In most series it accounts for less than 2% of all corneal ulcers.^{2,3,5,7,8,10} It is a common cause of acute bacterial conjunctivitis, especially in children.⁹ Unlike *Staphylococcus aureus*, *Streptococcus pneumoniae*, and other bacterial causes of conjunctivitis, *H influenzae* seldom produces corneal ulceration. This is in marked contrast with *H egyptus* ocular infections where peripheral ulcers, infiltrates, and phlyctenules are commonly seen as complications of conjunctivitis. For *H influenzae* to infect the cornea, there must be an epithelial defect. Most of the reported cases of *H influenzae* keratitis have been associated with specific risk factors such as contact lens wear, application of cyanoacrylate glue, or systemic debilitating diseases.^{1,4,6} In this case, the patient had two significant risk factors—severe atopic keratoconjunctivitis and herpetic keratitis. Despite the negative results of the viral cultures and HSV-DNA PCR, we cannot rule out the possibility that a viral aetiology played a part in this case. Also, it seems likely that complications from the patient's atopic disease, delayed the healing of the ulcer.

H influenzae is a fastidious organism that needs media enriched with nicotinamide adenine dinucleotide (NAD), such as chocolate agar for growth. It will not grow in blood agar, unless there are also colonies of *Staphylococcus aureus*, which provide NAD. In that situation, *H influenzae* will then grow as satellite colonies around the *Staphylococcus aureus*. This case illustrates the importance of utilising chocolate agar as well as blood agar to make an aetiological diagnosis.

In conclusion, *H influenzae* is a rare cause of corneal ulceration, which can occur in patients with previous corneal damage from

Table 1 Average blink rates (No/min) for ophthalmic surgeons during periods of casual conversation and while operating using the microscope

Surgeon	1	2	3	4	5	6	7	8	9	Mean (SD)
Casual	17.29	17.75	7.75	17.60	27.44	24.67	11.50	13.86	12.33	16.69
Operating	9.71	9.00	0.29	7.40	1.68	8.67	1.59	3.86	0.54	4.75
p Value	0.000002	0.002	0.002	0.002	0.0001	0.0001	0.00003	0.0004	0.0002	0.0003

diseases such as herpetic keratitis and atopic keratoconjunctivitis. To ensure appropriate treatment the organism must first be identified by cultures in enriched media.

C D Siverio Jr, J P Whitcher

The Francis I Proctor Foundation-UCSF, San Francisco, CA 94143-0944, USA

Correspondence to: Dr John P Whitcher; nepal@itsa.ucsf.edu

Accepted for publication 31 October 2001

References

- 1 **Armstrong JR**, Cohen KL, McCarthy LR. Haemophilus influenzae corneal ulcer in a therapeutic contact lens wearer. *Br J Ophthalmol* 1984;**68**:188–91.
- 2 **Asbell P**, Stenson S. Ulcerative keratitis: survey of 30 years' laboratory experience. *Arch Ophthalmol* 1982;**100**:77–80.
- 3 **Carmichael TR**, Wolpert M, Koornhof HJ. Corneal ulceration at an urban African hospital. *Br J Ophthalmol* 1985;**69**:920–6.
- 4 **Cavanaugh TB**, Gottsch JD. Infectious keratitis and cyanoacrylate adhesive. *Am J Ophthalmol* 1991;**111**:466–72.
- 5 **Coster DJ**, Wilhelmus K, Peacock J, et al. Suppurative keratitis in London. In: Trevor-Roper PD, ed. *Vllth Congress of The European Society of Ophthalmology. The cornea in health and disease*. International Congress and Symposium Series 1981, No 40. The Royal Society of Medicine, Academic Press, Grune and Stratton.
- 6 **Leahey AB**, Jones D. Haemophilus influenzae central corneal ulcer associated with cosmetic lens wear. *CLAO J* 1996;**22**:213–14.
- 7 **Liesegang TK**, Forster RK. Spectrum of microbial keratitis in south Florida. *Am J Ophthalmol* 1980;**90**:38–47.
- 8 **Seal DV**, Barrett SP, McGill JI. Aetiology and treatment of acute bacterial infection of the external eye. *Br J Ophthalmol* 1982;**66**:357–60.
- 9 **Soukiasian SH**, Baum J. Bacterial conjunctivitis. In: Krachmer JH, Mannis MJ, Holland EJ, eds. *Cornea*. St Louis: Mosby-Year Book, 1997:759–71.
- 10 **Upadhyay MP**, Karmacharya PCD, Koirala S, et al. Epidemiologic characteristics, predisposing factors and etiologic diagnosis of corneal ulceration in Nepal. *Am J Ophthalmol* 1991;**111**:92–9.

Blinking and operating: cognition versus vision

The difference in the refractive indices between the air and the tear film results in the tear film having the greatest optical power of any part of the eye. Eyelid blinks are important for maintenance of the tear film. Between blinks there is progressive thinning of the tear film, which becomes non-uniform on the ocular surface and may break up. This produces an irregular air/tear interface, with a reduction in image quality.¹ The longer the period between blinks the greater the effect on the tear film and reduction in vision. Restoration of the tear film occurs immediately following a blink so that the ability to maintain a regular tear film is dependent on

the blink rate. A reduction in the blink rate such as, for example, a pause between blinks of 15 seconds has been associated with a change in the shape of the profile of the corneal tear film and up to a 6% reduction in visual acuity.² More importantly, however, a reduction in blink rate leads to a reduction in contrast visual acuity.¹

The ability to distinguish between different layers during surgery, such as the posterior capsule of the lens and anterior vitreous face, or peeling a layer off the retinal surface in vitreoretinal surgery, is dependent on the surgeon having and maintaining good contrast acuity. Blink rates and blink amplitude vary according to vision related behaviour and a reduction in the blink rate occurs with tasks of increasing visual difficulty.³ For example, visual tasks requiring concentration, such as video display terminal use, result in a decrease in average blink rate from 18.4/min to 3.6 blinks/min.⁴

In order to determine whether the blink rate of ophthalmic surgeons alters during intraocular surgery, the blink rate patterns of nine ophthalmic surgeons were recorded. Two observers recorded the blink rate during casual conversation and when the surgeons were using the operating microscope. None of the surgeons were aware that their blink rates were being recorded, which was done by two medical students during their ophthalmic attachment—that is, their presence in the theatre was accepted as part of their ophthalmic training. The blink rate for each surgeon was recorded in each condition between four and 10 times. The mean blink rate for each surgeon during casual conversation and while operating are presented in Table 1. There was a significant reduction in the average blink rate between both conditions (16.69/min and 4.75/min, $p = 0.0002$ paired t test), on average a three and a half fold decrease occurred while operating. It was also noted that the onset of conversation such as the request for an instrument or demonstration of an intraocular structure, was associated with the onset of a blink response.

The reduction in blink rates observed in this study—that is, 16.69 to 4.75, are similar to that found by Patel *et al* for visual tasks such as video display terminal use. A reduction in blink rate to 4.75 translates to a reduction in contrast acuity of approximately 10% with four surgeons having an expected reduction of more than 60%.¹ Such a reduction in contrast acuity is likely to have an effect on the ability to differentiate between different intraocular surgical layers. Blinking occurs between visual fixations and may be timed so as not to interfere with significant visual input.⁵ Blink rate is low when information memory is operating, and cognitive processes utilising display areas accessible to visual input are disrupted during the blackout period of a blink.⁵ Blinking is thus suspended during certain cognitive activities to avoid disrupting these processes.⁵

Tear evaporation is dependent on the width of the palpebral fissure and the surrounding

humidity. Evaporation increases with widening of the palpebral aperture leading to a lower tear film stability. This has led to a recommendation that video display unit screens be kept below eye level. During ophthalmic surgery the eye pieces are roughly perpendicular to the face, so that it might be reasonable to lower the height of the eye pieces to reduce the width of the palpebral aperture. Frequent instillation of artificial tears during surgery is not practicable and might also create an abnormal tear film and image contrast. Likewise, increasing the humidity of the theatre may not be feasible. It might be reasonable to make surgeons, and anyone who uses the microscope, aware of this potential problem so that they can train themselves to blink during parts of the operation or investigation where good contrast acuity is not essential and where disruption of the cognitive processes is likely to have a minimal effect.

K K W Wong, W Y Wan, S B Kaye

St Paul's Eye Unit, 8z Link, Royal Liverpool University Hospital, Prescot Street, Liverpool L7 8XP, UK

Correspondence to: Mr Kaye; stephen.kaye@rlbu-h-tr.nwest.nhs.uk

Accepted for publication 21 November 2001

References

- 1 **Tutt R**, Bradey A, Begley C, et al. Optical and visual impact of tear break-up in human eyes. *Invest Ophthalmol Vis Sci* 2000;**41**:4117–23.
- 2 **Nemeth J**, Erdelyi B, Csakany B. Corneal topography changes after a 15 second pause in blinking. *J Cataract Refract Surg* 2001;**27**:589–92.
- 3 **Cho P**, Sheng C, Chan C, et al. Baseline blink rates and the effect of visual task difficulty and position of gaze. *Curr Eye Res* 2000;**20**:64–70.
- 4 **Patel S**, Henderson R, Bradley L, et al. Effect of visual display unit use on blink rate and tear stability. *Optom Vis Sci* 1991;**68**:888–92.
- 5 **Holland MK**, Tarlow G. Blinking and thinking. *Percept Mot Skills* 1975;**41**:505–6.

Should we vaccinate for glaucoma surgery?

Trabeculectomy is the most common non-laser surgical procedure performed for treatment of all forms of glaucoma. It involves the fashioning of a fistula from the anterior chamber of the eye to the subconjunctival space. This allows for extra drainage of aqueous humour to the subconjunctival space. This produces a localised elevation of the conjunctiva in the area of the trabeculectomy called a "filtering bleb." Antimetabolites may be used intraoperatively and perioperatively to increase the success of glaucoma filtering surgery by their action on wound healing. 5-Fluorouracil or mitomycin C is administered to the scleral flap during the procedure. Post-operatively; subconjunctival injections of

5-fluorouracil may be given. This is known as an augmented trabeculectomy.

Infective endophthalmitis is a recognised complication of glaucoma filtering surgery. It may occur in the early postoperative period or it may happen years after surgery. Another entity, possibly a precursor to endophthalmitis has been described as blebitis.¹ Blebitis is an infection of the trabeculectomy bleb without vitreous involvement.

Clinical features of blebitis include pain, photophobia, conjunctival discharge, and severe conjunctival injection centred on an opalescent filtering bleb. A Siedel test may be positive (this indicates aqueous leakage from the bleb) and there may be an anterior chamber reaction. There is no vitritis.²

As many as one per 100 patients/year may develop infection of the bleb.³ Factors associated with increased risk of bleb related endophthalmitis include increased axial length, thin leaky bleb, conjunctivitis, upper respiratory tract infection, hibernal occurrence, trauma, and vitreous wicks.^{4,5} With the increased use of antimetabolites in glaucoma surgery, the incidence of thin walled cystic blebs seems to be increasing.⁶ These blebs are more prone to leakage.⁷ Some studies conclude the incidence of bleb related endophthalmitis is higher when antimetabolites are used.⁸ This is more common with inferior limbal trabeculectomy.⁸ However, some studies show equal incidence in augmented trabeculectomy and trabeculectomy without antimetabolite augmentation.³

There are few data available for the incidence of blebitis. In most reported cases conjunctival swabs were performed for culture and sensitivity, but organisms causing endophthalmitis may only be present transiently on the ocular surface. In many reports, ocular surface cultures came back positive for *Staphylococcus epidermidis* and *S aureus*, which may both be found on healthy normal eyes.

The microbiology of bleb associated endophthalmitis is different from other causes of endophthalmitis. Clinicians should not extrapolate the results of the Endophthalmitis Vitrectomy study to the post-filtration surgery endophthalmitis given the differing pathogenesis and unique spectrum of organisms.² The most common organisms are *Streptococcus* species.⁶ The second most common is *Haemophilus influenzae* type b at over 23%.⁸ Of the streptococci, *S pneumoniae* may account for approximately 12%.⁹ Between them *H influenzae* type b and *S pneumoniae* probably cause more than 35% of blebitis and bleb associated endophthalmitis.

The treatment of endophthalmitis is expensive. It usually involves admission of the patient and frequent use of expensive drops as well as surgical intervention. Inpatient treatment for blebitis has been priced at US\$892 (approximately £540) per 24 hours.¹⁰ This can work out to more than £5000 for a 10 day stay in hospital. Furthermore, the cost of follow up visits and the morbidity that is involved need to be taken into account. Frequently these patients have pre-existing visual compromise and an episode of endophthalmitis may result in partially sighted or blind registration, an individual disaster with wider social implications.

H influenzae type b vaccine is licensed for use in infants. However, its use is allowed in those patients considered to be at risk for invasive *H influenzae* type b disease such as sickle cell disease and those receiving treatment for malignancy.¹¹ After the age of 13 months the vaccine is effective after a single dose. This vaccine has already shown benefit in ophthal-

mology by the dramatic decrease in the incidence of orbital cellulitis in immunised children.¹² It consists of a capsular polysaccharide of *H influenzae* type b conjugated to a protein carrier. Side effects of the vaccine include fever, headache, malaise, irritability, loss of appetite, vomiting, diarrhoea, rash, urticaria, convulsions, erythema multiforme, and transient cyanosis of the lower limbs.¹¹ Its cost to the NHS is as low as £8.83 for a single dose of 0.5 ml.¹¹

Pneumococcal vaccine is available. It is a polyvalent pneumococcal polysaccharide from each of 23 capsular types of *S pneumoniae*. The vaccine is recommended from the age of 2 for people with the following conditions: homozygous sickle cell disease, asplenia or dysfunction of the spleen, chronic renal disease, nephrotic syndrome, immunodeficiency, immunosuppression, chronic heart disease, chronic lung disease, chronic liver disease, and diabetes mellitus. It is effective after a single dose if the strains of *S pneumoniae* prevalent in the community are reflected in the polysaccharides contained in the vaccine. Its cost to the NHS is £9.49 for a 0.5 ml vial.¹¹

There have been no reports of epidemics of infective blebitis. If it were contagious, there would have been epidemics or clustering in our glaucoma clinics. We can find no evidence of case to case transmission. In fact, all reported cases and series appear sporadic. The association with upper respiratory tract infections and hibernal occurrence are strongly suggestive of respiratory infection with consequent spread to the predisposed eye.^{4,5} We are uncertain whether this is systemic or droplet spread. However, the need for topical antibody protection is negated by the presence of systemic antibodies against the specific bacteria. We believe that by minimising the possibility of systemic infections with these agents we diminish the likelihood of blebitis.

It is possible that these vaccines could be given to patients who are destined for trabeculectomy. The cost for both vaccines would be less than £20.00.

Two hundred and fifty vaccinations could be paid for by the price of a single episode of bleb associated endophthalmitis. Assuming a long term infection rate of 2%, these vaccines could possibly prevent two cases of bleb associated endophthalmitis, representing a saving of £5000 to the NHS.

Apart from the cost, vaccination has the potential to prevent significant ocular morbidity. At the very least, these vaccines should be considered in high risk patients undergoing augmented trabeculectomy. We plan to conduct a prospective study of the effect of these vaccinations upon the incidence of blebitis and bleb related endophthalmitis.

R R Seemungal-Dass, T E James

Department of Ophthalmology, Calderdale Royal Hospital, Salterhebble, Halifax HX3 0PW, West Yorkshire, UK

Correspondence to: R R Seemungal-Dass

Accepted for publication 21 November 2001

References

- 1 Brown RH, Yang LH, Walker SD, et al. Treatment of bleb infection after glaucoma surgery. *Arch Ophthalmol* 1994;112:57-61.
- 2 Ciulla TA, Beck AD, Topping TM, et al. Blebitis, early endophthalmitis, and late endophthalmitis after glaucoma filtering surgery. *Ophthalmology* 1997;104:986-95.
- 3 Doyle JW, Smith M F. Complications of glaucoma surgery and their management. In: Yanoff M, Duker JS, eds. *Ophthalmology*. Mosby International, 1999:12.33.1-6.

- 4 Ashkenazi I, Melamed S, Avni I, et al. Risk factors associated with late infection of filtering blebs and endophthalmitis. *Ophthalmic Surg* 1991;22:570-4.
- 5 Mochizuki K, Jikihara S, Ando Y, et al. Incidence of delayed onset infection after trabeculectomy with adjunctive mitomycin C or 5-fluorouracil treatment. *Br J Ophthalmol* 1997;81:877-83.
- 6 Ayyala RS, Bellows AR, Thomas JV, et al. Bleb infections: clinically different courses of "blebitis" and endophthalmitis. *Ophthalmic Surg Lasers* 1997;28:452-60.
- 7 Higginbotham EJ, Stevens RK, Musch DC, et al. Bleb-related endophthalmitis after trabeculectomy with mitomycin C. *Ophthalmology* 1996;103:650-6.
- 8 Greenfield DS, Suner U, Miller MP, et al. Endophthalmitis after filtering surgery with mitomycin. *Arch Ophthalmol* 1996;114:943-9.
- 9 Mandelbaum S, Forster RK, Gelender H, et al. Late onset endophthalmitis associated with filtering blebs. *Ophthalmology* 1985;92:964-72.
- 10 Chen PP, Gedde SJ, Budenz DL, et al. Outpatient treatment of bleb infection. *Arch Ophthalmol* 1997;115:1124-8.
- 11 *British National Formulary* 39. London: British Medical Association and Royal Pharmaceutical Society of Great Britain, March 2000.
- 12 Donahue SP, Schwartz G. Preseptal and orbital cellulitis in childhood. A changing microbiologic spectrum. *Ophthalmology* 1998;105:1902-5; discussion 1905-6.

The wide field multifocal electroretinogram reveals retinal dysfunction in early retinitis pigmentosa

The diagnosis of retinitis pigmentosa (RP) is made on the basis of characteristic retinal pigmentation changes, visual field defects, and reduction in amplitude or loss of rod scotopic standard electroretinography (ERG) responses, with a possible history of night blindness and a positive family history of RP.¹ Multifocal electrophysiology (mfERG), is a new technique that constructs a topographical map reflecting retinal function.² Reports have suggested that the spatial resolution of mfERG is sufficient to detect focal changes in retinal function as RP progresses.³⁻⁵

We describe a case of early RP in which the amplitude and implicit times of the patient's standard ERG rod and maximal responses were normal in the right eye and equivocal in the left eye. However, the peripheral retinal mfERG amplitude and implicit times were reduced and delayed. These abnormalities were obtained using a custom built wide field mfERG,⁶ which facilitates assessment of a 90 degree retinal field.

Case report

A 29 year old woman was referred to the eye clinic by her optometrist. Abnormal retinal pigmentation was found in both fundi on routine examination. She had no visual problems and was otherwise systemically well. Her 51 year old mother is known to have RP.

On examination, she had 0.50 dioptres of hypermetropia in both eyes. Her best corrected logMAR visual acuities were -0.075 in the right eye and -0.025 in the left. Her colour vision, anterior segment examination, and intraocular pressures were normal in both eyes. Fundal examination revealed semicircular arcs of intraretinal "bone spicule" pigmentation in the inferior mid-periphery of each retina. Her optic discs appeared normal and there was no evidence of attenuation of the retinal vasculature.

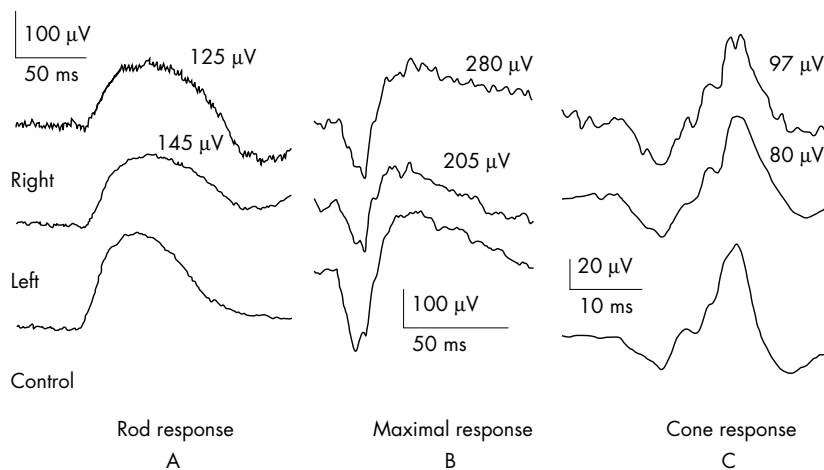


Figure 1 The Ganzfeld ERG responses of a normal eye compared with the patient's eyes. The rod b-wave of patient's right and left eye compared with control (normal range of rod b-wave amplitude 72–367 μ V) (A); the maximal b-wave response of patient's right and left eye compared with controls (normal range of maximal b-wave amplitude 241–709 μ V) (B); the cone b-wave response of patient's right and left eye compared with normal control (normal range of cone b-wave amplitude 68–222 μ V) (C).

A Humphrey 120 point threshold related perimetry test was performed and the patient maintained fixation throughout the test. There was an arc of absolute visual field defect in the superior field, symmetrical in both eyes, 40 degrees from fixation, which was more extensive superotemporally than superonasally.

A Ganzfeld ERG test was performed in accordance with international standards.⁷ The implicit times and amplitude of the scotopic rod, photopic cone and flicker responses of the patient were normal. The scotopic maximal

b-wave amplitude was reduced by 14% in the left eye and was normal in the right eye (Fig 1).

Wide field mfERG was performed, using a technique previously described.⁶ The amplitudes of the central and peripheral mfERG responses were grouped and averaged (Fig 2A) and compared with similar responses from normative data (Fig 2B). The average amplitude of the central mfERG response was 75 nV in the right and 101 nV in the left (normal range 74–122 nV) (Fig 2A). The average peripheral retinal mfERG responses were 29 nV in the right eye and 45 nV in the left eye (normal range 61–108 nV). The normal range is derived from a group of 40 controls, aged 20–40 years. In addition, the mfERG responses were reduced in areas that had normal visual field sensitivities.

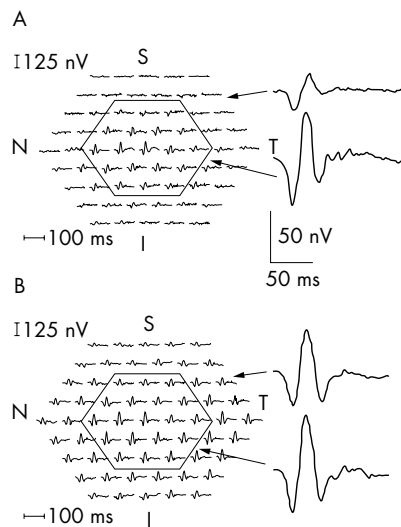


Figure 2 (A) Multifocal amplitude responses of patient's right eye with the central and peripheral responses grouped and averaged. The central responses are generated by the central 60 degrees of the retinal field. (B) Multifocal responses of a normal right eye with central and peripheral mfERG responses grouped and averaged. Note that the patient's averaged central response is normal (normal range 74–122 nV). However, the averaged peripheral mfERG response of the patient is reduced at 29 nV (normal range 61–108 nV).

Comment

Retinitis pigmentosa in its early stages of evolution is characterised by rod dominated photoreceptor dysfunction.¹ Although mfERG is a photopic response, thought to predominantly reflect cone function,⁵ the nature of mfERG stimulation (that is, stimulation frequencies from 5 Hz to 75 Hz),⁸ indicates that this composite response may contain contributions from rods, in addition to cones and post receptor cells.

The global nature of the Ganzfeld ERG requires approximately 30% of the retina to be dysfunctional before abnormalities can be detected.⁹ In this case report, the standard ERG did not help to confirm the diagnosis of RP. However, the spatial resolution of the peripheral wide field mfERG indicated peripheral retinal dysfunction, suggestive of RP.

We conclude that wide field mfERG may have advantages over Ganzfeld ERG in the electrophysiological diagnosis of some forms of early RP. Further evaluation of wide field mfERG in the diagnosis and follow up of early RP is indicated.

F M Dolan, S Parks, H Hammer

ElectroDiagnostic Imaging Unit, Tennent Institute of Ophthalmology, Gartnavel General Hospital, Glasgow G12 0JT, UK

D Keating

ElectroDiagnostic Imaging Unit, Tennent Institute of Ophthalmology, Gartnavel General Hospital, Glasgow, and Department of Clinical Physics and Bio-Engineering, University of Glasgow, UK

Correspondence to: Dr Stuart Parks

Accepted for publication 26 November 2001

References

- 1 Marmor MF, Aguirre G, Arden G, et al. Retinitis pigmentosa, a symposium on terminology and methods of examination. *Ophthalmology* 1983;**90**:124–31.
- 2 Sutter EE, Tran D. The field topography of ERG component in man—1. The photopic luminance response. *Vis Res* 1992;**2**: 433–46.
- 3 Hood DC, Holopigian K, Greenstein V, et al. Assessment of local retinal function in patients with retinitis pigmentosa using the multifocal ERG technique. *Vis Res* 1998;**38**:163–79.
- 4 Parks S, Keating D, Evans AL, et al. A change in the delay of multifocal ERGs is found in retinitis pigmentosa over a one-year period. *Invest Ophthalmol Vis Sci* 1998;**39**:S186.
- 5 Seeliger M, Kretschmann U, Apfelstedt-Sylla E, et al. Multifocal electroretinography in retinitis pigmentosa. *Am J Ophthalmol* 1998;**125**:214–26.
- 6 Parks SW, Keating D, Evans AL. Wide field functional imaging of the retina. *IEEE Medical Applications of Signal Processing* 1999; **99/107**:9/1–9/6.
- 7 Marmor MF, Zrenner E. Standard for clinical electroretinography. *Doc Ophthalmol* 1995; **89**:199–210.
- 8 Keating D, Parks S, Smith DC, et al. A new LED stimulator for multifocal electroretinography. *Invest Ophthalmol Vis Sci* 2001;**42**:S785.
- 9 Jacobi PC, Miliczek K, Zrenner E. Experiences with the international standard for clinical practice, interindividual and intraindividual variations and possible extensions. *Doc Ophthalmol* 1993;**85**:95–114.

Day 1 review following cataract surgery: are we seeing the precise details?

The Royal College of Ophthalmologists published cataract surgery guidelines¹ in February 2001. This document includes protocols relating to postoperative visits suggesting that there are no additional risks to patients who are not reviewed on the first postoperative day. This is a change in recommendation from previous college guidelines in 1995 suggesting a review within 48 hours.

There may follow a growing impetus for ophthalmologists to dispense with the first day review, given the reduced demand on clinician time and the corresponding accrual of staffing and financial resource benefits. While we applaud the dissemination of practice guidelines, they constitute “merely tools, not rules” to aid clinical decision making. They may have inherent limitations in particular circumstances and may require evaluation for effective application in clinical settings.

Four studies were quoted by the guideline authors, three of which advocated the omission of day after review^{2–4} and one of which was equivocal,⁵ suggesting that it was unsafe to abandon this practice unless raised intraocular pressures (IOP) were controlled. The numbers of patients included ranged from 100 to 387. The results of these studies are shown in Table 1.

Comment

In our view, deriving meaningful conclusions that may underpin clinical practice are difficult, owing to the varying methodological

Table 1 Day 1 postoperative complications noted in clinical studies

Study/(n) patients	Cornea oedema	Raised IOP	Uveitis	Others
Tufail <i>et al</i> ¹ (387)	4 (1%)	8 (2%)	–	12 (3.1%)
Whitefield <i>et al</i> ⁶ (100)	10 (10%)	3 (3%)	–	–
Cohen <i>et al</i> ⁷ (201)	26 (13%)	12 (6%)	–	–
Tan <i>et al</i> ⁸ (227)	5 (4.4%)	3 (1.3%)	1 (0.4%)	3 (1.3%)

approaches used in these studies. In Tufail's study,² extracapsular cataract extraction was the predominant surgical technique used. Cohen *et al*⁷ excluded more than 50% of patients with complicated ocular histories or complicated surgery and Whitefield *et al*⁶ had similar extensive exclusion criteria, although the number excluded was not mentioned.

We would draw attention to a recently published study by McKellar and Elder,⁶ which to our knowledge is one of the largest cohort studies, aside from national cataract surveys, reporting on first and seventh day complications of cataract surgery. Of 1000 patients, the study found that on the first postoperative day, complications were observed in 10% of eyes, of which 88% was raised IOP. Unlike most of the previous studies, all patients with available records were eligible, including those with preoperative risk factors and those with surgical complications. These figures align more closely with our "gold standard" of the National Cataract Surgery Survey⁷ than the previous mentioned studies. The events most frequently occurring within 48 hours after surgery in the national survey were corneal oedema (9.5%), raised IOP (7.9%), and uveitis (5.6%). Overall, 23.3% of patients had early postoperative complications ranging from minor to sight threatening conditions. The survey also found that several risk indicators were associated with poorer visual outcomes and complications related to cataract surgery: age, ocular co-morbidity (glaucoma, macular disease, amblyopia, and previous ocular surgery), diabetes mellitus, stroke, type of surgical procedure, and grade of surgeon.

In summary, up to 20 000 patients a year in the United Kingdom (10%) may have an undetected early postoperative complication such as corneal oedema or raised IOP, if first day review was abandoned. And if McKellar's study is representative, then 5% of patients would have raised pressure without any previous history or surgical complication and 0.9% of patients could have other potentially serious early complications. Nationally, that equates to almost 12 000 patients annually. It is worth noting that the American Academy of Ophthalmology in its white paper,⁸ concludes that there are enough significant early postoperative complications to warrant first day review. Are we sufficiently confident in our own practices to diverge?

Credit should be apportioned to the distinguished authors of the cataract surgery guidelines suggesting 24 hour follow up of patients who had undergone complicated surgery, had coexisting eye disease, or had large incision cataract surgery. We would like to reiterate the importance of explicit criteria as part of any review policy and suggest that clinical interpretation of individual circumstances is paramount.

To reconcile the need for an efficient, cost effective review protocol together with a necessity to give due consideration to the entirety of detrimental post-cataract complications, especially given the NHS resource

constraints, is difficult. A pragmatic approach may be for clinicians to be discriminately aware of those patients most at risk of developing early complications and instituting review policies accordingly, together with an open door policy for patients who need or want reassurance on the first day following uncomplicated surgery. Furthermore, a multi-professional management approach involving the extended role of trained ophthalmic nurses in postoperative care may reduce demands on physician time.

At the moment, there is a paucity of a good prospective literature on the subject and a need for future studies to address whether those identified complications would result in a change of management at the first postoperative day visit and whether patients would have a poorer outcome if the changes were not instituted.

D Goh

Royal Surrey County Hospital,
Guildford GU2 5XX, UK

N Lim

The Western Eye Hospital, Marylebone Road,
London NW1 5YE, UK

Correspondence to: Dr Goh; davidgoh1@aol.com

Accepted for publication 29 November 2001

References

- 1 **Royal College of Ophthalmologists.** *Cataract surgery guidelines.* London: RCO, 2001.
- 2 **Tufail A, Forse AJE, Hamilton AMP.** Is the first day postoperative review necessary after cataract extraction? *Br J Ophthalmol* 1995;**79**:646–8.
- 3 **Whitefield L, Crowston J, Little BC.** First day follow-up for routine phacoemulsification? *Br J Ophthalmol* 1996;**80**:148–50.
- 4 **Tan JHY, Newman DK, Klunker C, et al.** Phacoemulsification cataract surgery: is routine review necessary on the first postoperative day. *Eye* 2000;**14**:53–5.
- 5 **Cohen VM, Demetria H, Jordan K, et al.** First day post-operative review following uncomplicated phacoemulsification. *Eye* 1998;**12**:634–6.
- 6 **McKellar MJ, Elder MJ.** The early complications of cataract surgery: is routine review of patients 1 week after cataract extraction necessary. *Ophthalmology* 2001;**108**:930–5.
- 7 **Desai P, Minassian DC, Reidy A.** National cataract surgery survey 1997–1998: a report of the results of the clinical outcomes. *Br J Ophthalmol* 1999;**83**:1336–40.
- 8 **American Academy of Ophthalmology, American Society of Cataract and Refractive Surgery.** White paper on cataract surgery. *Ophthalmology* 1996;**103**:1152–6.

Choroidal abnormalities in neurofibromatosis type 1 with non-invasive infrared imaging

Retinal abnormalities have been reported worldwide in patients with neurofibromatosis type 1.^{1–3} However, there have been few reports of choroidal abnormalities.⁴ We report a patient with choroidal abnormalities, associated with neurofibromatosis type 1, using a scanning laser ophthalmoscope (SLO).

Case report

A 37 year old woman presented for an examination with hard contact lenses. Her best corrected visual acuity was 20/20 in both eyes. A diagnosis of neurofibromatosis type 1 was made on the basis of multiple café au lait spots, plexiform neurofibroma, and Sakurai-Lisch nodules in the iris in both eyes. The conventional ophthalmoscopic and biomicroscopic fundus examinations were unremarkable. A general medical examination showed no abnormalities except signs of neurofibromatosis type 1. SLO examination showed no abnormalities with a helium-neon laser (633 nm) and regions of multiple, bright patches with infrared imaging (780 nm) using the direct confocal mode⁴ (Fig 1) and dark patches with the indirect mode⁵ (Fig 2) at the corresponding regions in the posterior pole in both eyes. There were no scotomas in those regions using SLO microperimetry.

Comment

In this case, we observed choroidal abnormalities in a patient with neurofibromatosis type 1. The conventional fundus examination, including biomicroscopic examination and fundus colour photography, did not show remarkable changes. However, the SLO examination showed regions of bright patches with infrared imaging using the direct confocal mode and dark patches using the indirect mode at both posterior poles. Infrared light penetrates the retina into the choroid more than visible light.⁶ Therefore, the bright patchy regions seen with confocal infrared imaging and the absence of such regions under helium-neon light examination indicates that the patchy regions are of choroidal origin, as reported by Yasunari and colleagues.⁴ In addition, we observed dark patchy regions in the corresponding area using the indirect mode of infrared imaging (which also can obtain images of the deeper retinal layers non-invasively) instead of using indocyanine green fundus angiography. Yasunari and colleagues reported that choroidal abnormalities (100%) occurred more frequently than plexiform neurofibroma (29%) and Sakurai-Lisch nodules in the iris (76%).⁴

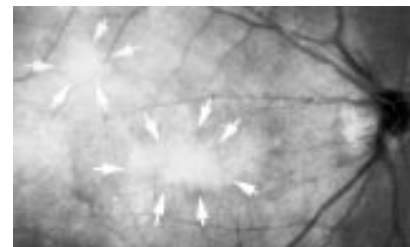


Figure 1 SLO image of the right eye using the infrared direct confocal mode.

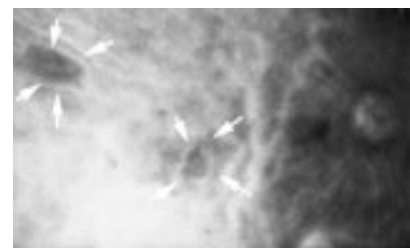


Figure 2 SLO image of the right eye using the infrared indirect mode.

They also reported that bright patchy choroidal regions should be a new diagnostic criterion for neurofibromatosis type 1. The non-invasive SLO examination with confocal and indirect infrared imaging may be useful in the diagnosis of patients with neurofibromatosis type 1.

F Mori, N Kitaya, T Hikichi, A Yoshida

Department of Ophthalmology, Asahikawa Medical College, Asahikawa, Japan

Correspondence to: Fumihiko Mori, MD, PhD, Department of Ophthalmology, Asahikawa Medical College, Midorigaoka Higashi 2-1-1-1, Asahikawa 078-8510, Japan; morinao@d5.dion.ne.jp

The authors have no proprietary interest in any aspect of this report.

Accepted for publication 5 October 2001

References

- 1 **Destro M, D'Amico DJ, Gragoudas ES, et al.** Retinal manifestations of neurofibromatosis. *Arch Ophthalmol* 1991;**109**:662-6.
- 2 **Mori F, Nozu K, Kado M, et al.** A case of von Recklinghausen's disease with retinal tumor. *Folia Ophthalmol Jpn* 1994;**45**:883-5.
- 3 **Mori F, Kawai M, Sato E, et al.** Branch retinal vein occlusion in a Japanese patient with neurofibromatosis 1. *Jpn J Ophthalmol* 2001;**45**:634-5.
- 4 **Yasunari T, Shiraki K, Hattori H, et al.** Frequency of choroidal abnormalities in neurofibromatosis type 1. *Lancet* 2000;**356**:988-92.
- 5 **Haynes RJ, Manivannan A, Walker S, et al.** Imaging of optic nerve head drusen with the scanning laser ophthalmoscope. *Br J Ophthalmol* 1997;**81**:654-7.
- 6 **Shiraki K.** Fundus examination using a scanning laser ophthalmoscope. *Folia Ophthalmol Jpn* 1996;**47**:629-36.

Corneal melt and perforation secondary to floppy eyelid syndrome in the presence of rheumatoid arthritis

Floppy eyelid syndrome (FES) is an uncommon condition that it is often underdiagnosed or misdiagnosed owing to the somewhat trivial and non-specific symptoms with which it often presents.^{1,2} In association with the dry eye of rheumatoid arthritis it can, however, have devastating effects.

Case report

A 60 year old moderately obese man with well controlled rheumatoid arthritis (RA) presented to the eye clinic with recurrent red and gritty eyes. A diagnosis of dry eye syndrome with blepharitis was made. He was also found to have a mucocoele of the left lacrimal sac. Lid hygiene and ocular lubricants yielded an initial encouraging response and he was discharged.

He re-presented 5 years later with similar symptoms and reduced visual acuity (VA) of 6/36 in the left eye. A diagnosis of dry eye syndrome with secondary corneal epithelial changes was made. Topical lubricants failed to relieve the condition satisfactorily and he was therefore scheduled for punctal occlusion. However, upon admission for this 8 weeks later, he was found to have an asymptomatic perforation of the left cornea, with a VA of 6/60. The perforation was treated with glue and a bandage contact lens, topical antibiotic, steroids, and lubricants. Systemic immunosuppression was considered in view of the history of RA, but was withheld as a heavy growth of staphylococcus had been cultured from the cornea. The right eye demonstrated signs of dryness but was otherwise healthy with VA of 6/9.

Bilateral punctal occlusion was undertaken as planned, and in addition a left dacryocystorhinostomy (DCR) to eliminate the mucocoele as a potential reservoir of infection. The eye, however, continued to slowly deteriorate, with persisting mucopurulent discharge, despite the DCR. Eventually uncontrolled endophthalmitis developed requiring enucleation.

He re-presented 8 months later with reduced VA of 6/60 in the right eye secondary to a corneal melt (Fig 1A). A chronic mucopurulent discharge had also developed in the right eye, but no lacrimal sac mucocoele was identifiable. On this occasion, however, it was noted on examination that while everting the eyelids, all four lids exhibited excessive laxity (Fig 1B). This, together with a florid papillary tarsal conjunctival reaction and the chronic mucus discharge, led to a diagnosis of RA associated dry eye syndrome exacerbated by FES.

All four eyelids were immediately subjected to considerable shortening by pentagonal excision; the corneal melt was treated with a bandage contact lens, with topical antibiotic, steroids and lubricants. The response to surgery was dramatic with complete resolution of discharge and gradual spontaneous repair of the corneal melt (Fig 2). The VA eventually recovered to 6/9.

Comment

FES occurs most frequently in middle aged obese males,¹ although it has been described

in young, slim males, females, and one child.³ Typically, the upper tarsus is rubbery and the upper eyelid everts easily with gentle upward pressure. A florid papillary conjunctivitis and chronic mucus discharge are common. Severe corneal involvement is rare, with only four reports in the literature of ulceration in association with FES and only two cases of perforation.^{2,4}

Although the exact pathophysiology of FES is uncertain, a sequence of events that may lead to its development and to the secondary corneal changes has been proposed.^{1,4} Unknown predisposing factors, possibly congenital, create a floppy upper tarsus. Whereas examination of post-excisional specimens has revealed normal tarsal collagen, elastin fibres are nearly absent.⁵ It is unclear whether this finding is causative or secondary. During sleep, a local pressure induced ischaemia may develop in the tarsus that, when relieved, results in a reperfusion injury which could injure tarsal elastin. In addition, there is a high incidence of obstructive sleep apnoea in FES patients and nocturnal dips in Pao₂ could further contribute to the local ischaemia and subsequent elastin damage.²

Corneal involvement may occur through one or more mechanisms. Spontaneous nocturnal lid eversion resulting from pressure of the pillow on the lax upper lid may lead to repeated trauma of the corneal epithelium. Lash ptosis may contribute to this direct trauma. The cornea, however, may be damaged from a more subtle but important mechanism. Affected lid specimens demonstrate a marked polymorphonuclear infiltrate, which may be the sequelae of the reperfusion injury described above; this tarsal infiltrate and the associated papillary response may have direct toxic effects on corneal epithelium and stroma.⁴ It is perhaps intuitive that the corneal complications found in FES may be more severe when, as in our case, co-existing pathologies are present. Blepharitis and RA associated dry eye may both independently cause significant corneal pathology.

This case serves as a reminder that multiple pathologies may contribute to the clinical picture. If FES is not to be missed, ocular examination must include lid eversion and inspection of the tarsus.

J D Rossiter

Southampton Eye Unit, Southampton General Hospital, Tremona Road, Southampton SO16 6YD, UK

R Ellingham

Bristol Eye Hospital, Lower Maudlin Street, Bristol BS1 2LX, UK

K N Hakin, J M Twomey

Department of Ophthalmology, Taunton and Somerset Hospital, Taunton TA1 5DA, UK

Correspondence to: Mr Rossiter

Accepted for publication 10 October 2001

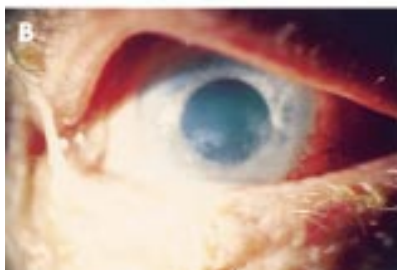

Figure 1 Right eye before eyelid shortening showing (A) the corneal melt and (B) marked laxity of the upper and lower lids with a chronic mucus discharge.

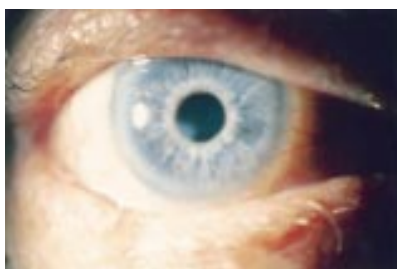

Figure 2 Postoperative photograph of right eye demonstrating the marked improvement.

References

- 1 **Culbertson WW, Ostler HB.** The floppy eyelid syndrome. *Am J Ophthalmol* 1981;**92**:568-75.
- 2 **McNab AA.** Floppy eyelid syndrome and obstructive sleep apnoea. *Ophthalmic Plast Reconstr Surg* 1997;**13**:98-114.
- 3 **Moore MB, Harrington J, McCulley JP.** Floppy eyelid syndrome: management including surgery. *Ophthalmology* 1986;**93**:184-8.
- 4 **Culbertson WW, Tseng SCG.** Corneal disorders in floppy eyelid syndrome. *Cornea* 1994;**13**:33-42.
- 5 **Netland PA, Sugrue SP, Albert DM, et al.** Histopathologic features of the floppy eyelid syndrome. *Ophthalmology* 1994;**101**:174-81.

Ocular trauma with small framed spectacles

Penetrating injuries are widely reported with spectacle related eye trauma, particularly in car accidents.¹⁻⁴ The use of high grade plastics and secure frames have been shown to reduce the incidence of spectacle related eye trauma.⁵ Spectacle safety may be compromised in the trend for small frames and frameless spectacles and may place patients at risk of serious ocular injury.³

We present the case of an aphakic patient who sustained a blunt injury following ocular compression by her spectacles. Her injuries could have been avoided if larger framed spectacles had been worn.

Case report

A 79 year old aphakic woman sustained a non-penetrating injury to her left globe by walking into a door. She noted a sharp pain and sudden loss of vision. The globe was compressed by her spectacles, which were smaller than her orbital rim. Her glasses were not damaged and there was minimal periocular soft tissue injury.

She was aphakic, following bilateral cataract extraction for congenital cataracts. The spectacle refraction was +9.00 with a short back vertex distance of 5 mm (Fig 1).

The pinhole acuity was 6/36, a quiet, deep anterior chamber was noted with no aqueous leak, the intraocular pressure was 0 mm Hg. Funduscopy revealed a light vitreous haemorrhage, peripapillary choroidal ruptures, and a 360 degree suprachoroidal haemorrhage (Fig 2).

Hypotony following traumatic ciliary artery spasm was diagnosed and the patient was treated conservatively, with topical atropine twice daily and dexamethasone four times daily. After 4 days the hypotony resolved and the intraocular pressure returned to 14 mm Hg. The suprachoroidal haemorrhages resolved over 2 weeks and the visual acuity improved to 6/24.

Comment

The potential ocular damage from framed and frameless spectacles has been highlighted in a

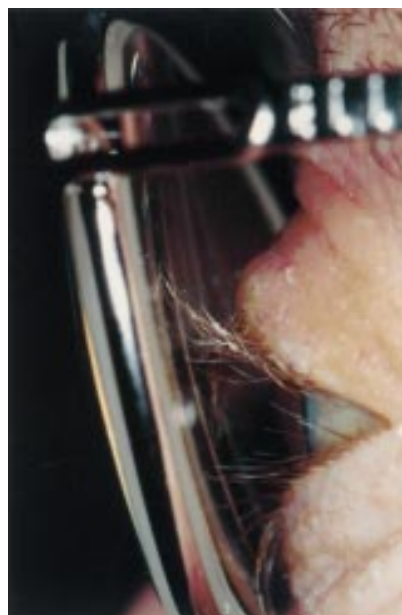

Figure 1 Note the short back vertex distance in this aphakic correction.

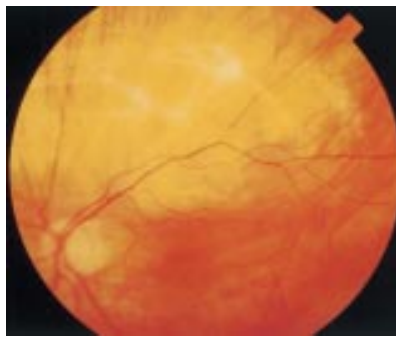


Figure 2 The choroidal rupture following blunt injury to the globe.

number of reports.¹⁻⁴ These often result from minor road traffic accidents or inflation of air bags that damage the spectacles. The trauma is usually sufficient to break the lenses in the spectacles and the resultant globe laceration is the main cause of morbidity.

The recent trends towards smaller framed spectacles has not been reported as a potential risk to the patient; however, in this case, with small framed spectacles (with a short back vertex distance), minor trauma was sufficient to cause serious eye injury. The patient's previous larger framed spectacles would have prevented such an injury as the lenses would have been supported by the orbital margin and not the globe.

This case demonstrates the previously unconsidered risk of small framed spectacles in aphakic patients. The back vertex distance may be short, increasing the risk of blunt injury.

J Clarke, R Newsom, C Canning

Southampton Eye Unit, Southampton, UK

Correspondence to: Mr J C K Clarke, Southampton Eye Unit, Southampton General Hospital, Tremona Road, Southampton SO16 6YD, UK

Accepted for publication 10 October 2001

References

- 1 **Christianson MD**, Parker JA, Arndt J. Material and thickness: the important factors in the impact resistance of spectacles. *Canad J Ophthalmol* 1977;**12**:300-3.
- 2 **Gault JA**, Vichnin MC, Jaeger EA, et al. Ocular injuries associated with eyeglass wear and airbag inflation. *J Trauma Injury Infect Crit Care* 1995;**38**:494-7.
- 3 **Newsom RSB**, Williamson TH. Globe perforation with frameless spectacles. *Br J Ophthalmol* 2000;**84**:668-9.
- 4 **Vichnin MC**, Jaeger EA, Gault JA, et al. Ocular injuries related to air bag inflation. *Ophthalmic Surg Lasers* 1995;**26**:542-8.
- 5 **Keeney AH**, Renaldo D. Newly defined lens and frame factors in the reduction of eye injuries. *Eye Ear Nose Throat Monthly* 1973;**52**:19-24.

Late opacification of SC60B-OUV acrylic intraocular lenses

Optical clarity of the intraocular lens (IOL) is paramount in maintaining visual improvement after cataract extraction. While the advent of newer foldable IOLs have revolutionised cataract surgery by the smaller incisions required, their long term safety will be established only with time. There have been recent reports of two separate groups of hydrophilic IOLs that have shown various degrees of opacification, 6 months to 2 years after implantation.¹ These include the Hydroview lens (Bausch & Lomb

Surgical, Claremont, CA, USA) and the model SC60B-OUV (Medical Developmental Research, Clearwater, FL, USA).^{1,2} We report our experiences with two patients who had permanent reduction in visual acuity 1-2 years after implantation of the SC60B-OUV IOL.

Case reports

Case 1

An 82 year old man with visual acuities of 6/60 in both eyes because of a right macular hole and left posterior subcapsular cataract underwent routine left phacoemulsification and intraocular lens implantation in March 1998. A foldable hydrophilic acrylic IOL (Model SC60B-OUV, MDR, Inc) was implanted in the capsular bag. Postoperative recovery was uneventful, with left visual acuity improving to 6/4 with correction, 6 weeks after the surgery.

He was referred back to the clinic in March 2000 with symptoms of intermittent binocular diplopia, which was relieved with fresnel prisms. His left visual acuity was 6/6, but the intraocular lens was found to be uniformly cloudy (Fig 1A). As the patient was not experiencing any symptoms from his cloudy IOL, no intervention was advised. Over the next 6 months the brownish discoloration of the IOL increased in intensity and the patient complained of "foggy vision." His visual acuity dropped to 6/12 and he was disturbed by the distorted, but clear images from his right eye and hazy images from his left eye. Fundus examination of the left eye has also become progressively difficult. IOL exchange is being considered, bearing in mind the presence of the macular hole in the fellow eye and the risks of removing a posterior chamber IOL 3 years after implantation.

Case 2

A 78 year old woman with bilateral Fuchs' corneal endothelial dystrophy and long standing central retinal vein occlusion in the left eye, underwent uneventful right phacoemulsification with intraocular lens implantation (Model SC60B-OUV, MDR, Inc) in August 1998. Her right visual acuity improved to 6/9,

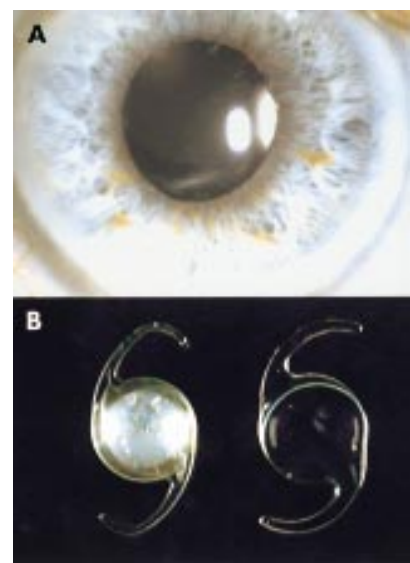


Figure 1 (A) Diffuse opacification of the IOL 2 years after implantation in case 1. (B) The explanted opacified IOL optic from case 2 is compared to a normal acrylic IOL.

but approximately 1 year after the surgery there was gradual deterioration of vision to 6/24 in August 2000. At this stage the IOL was noted to be cloudy; there was also progression of her endothelial dystrophy. She underwent uneventful right penetrating keratoplasty with exchange of posterior chamber IOL in November 2000 and has a current right visual acuity of 6/12. The explanted opacified IOL is compared to a normal clear acrylic IOL in Figure 1B.

Comment

The safety and efficacy of AcrySof polyacrylic IOLs has been reported to be equal to or better than poly(methylmethacrylate) IOLs.³ The unexpected late opacification of the acrylic IOL (SC60B-OUV), implanted in the only "good" eye of both our patients, resulted in significant visual disability and clinical dilemma. This model of IOL was first produced in June 1997 by Medical Development Research (MDR, Inc). More than 60 000 of these lenses have been implanted worldwide, but only outside the United States.¹ Reports of opacification of the IOL started coming through to the manufacturer in May 1999. (Summary of SC60B-OUV lens opacification investigation, personal communication from MDR, Inc, 20 July 2001.)

Several theories have been put forward to explain the late clouding of the IOL optic.^{2,4,5} Analysis of 23 explanted IOLs of the same model has shown that degeneration of the ultraviolet filtration material and calcium deposits within the optic biomaterial are responsible for the opacification of the IOL.¹ Werner *et al* analysed nine explanted IOLs of the same model and demonstrated the presence of calcium phosphate salts in the deposits within the optics of the IOL.⁶ Investigations by the manufacturers identified four lots of polymer biomaterial formulated and prepared by Vista Optics (London) and used by MDR, Inc in the IOL manufacture, that correlated with opacification complaints (Summary of SC60B-OUV lens opacification investigation, personal communication from MDR, Inc, 20 July 2001).

Ninety two of the estimated 60 000 SC60B-OUV IOLs implanted were explanted and returned to the company. MDR, Inc ceased exporting SC60B-OUV lenses in June 2000 and claims that the opacification represents only 0.15% of total SC60B-OUV IOLs implanted. (Summary of SC60B-OUV lens opacification investigation, personal communication from MDR, Inc, 20 July 2001). However, this does not account for those patients who have not yet had their opaque IOLs identified or explanted. The lateness of the onset of opacification and resulting visual disability may mean that we are seeing only the tip of the iceberg.

A Joseph, H S Dua

Division of Ophthalmology and Visual Sciences, University of Nottingham

Correspondence to: Professor H S Dua, Division of Ophthalmology and Visual Sciences, B Floor, Eye Ear Nose and Throat Block, University Hospital, Queen's Medical Centre, Nottingham NG7 2UH, UK; harminder.dua@nottingham.ac.uk

Accepted for publication 3 December 2001

References

- 1 Apple DJ, Werner L, Pandey SK. Newly recognized complications of posterior chamber intraocular lenses. *Arch Ophthalmol* 2001;119:581-2
- 2 Chang BYP, Davey KG, Gupta M, *et al*. Late clouding of an acrylic intraocular lens

following routine phacoemulsification. *Eye* 1999;13:807-8.

- 3 Kobayashi H, Ikeda H, Imamura S, *et al*. Clinical assessment of long-term safety and efficacy of a widely implanted polyacrylic intraocular lens material. *Am J Ophthalmol* 2000;130:310-21.
- 4 Woodruff SA, Khan J, Dhingra N, *et al*. Letter to the editor. *Eye* 2001;15:361-2.
- 5 Sharma A, Ram J, Gupta A. Letter to the editor. *Eye* 2001;15:362.
- 6 Werner L, Apple J, Kaskaloglu M, *et al*. Dense opacification of the optical component of a hydrophilic acrylic intraocular lens: a clinicopathological analysis of 9 explanted lenses. *J Cataract Refract Surg* 2001;27:1485-92.

Treatment of superior limbic keratoconjunctivitis with a unilateral bandage contact lens

The typical patient with superior limbic keratoconjunctivitis (SLK) is a woman aged between 20 and 60 years of age with chronic red and irritable eyes.¹ Although both eyes are usually affected, the condition may be asymmetrical.¹ After episodes of exacerbation and remission it usually resolves. The patient may also have abnormal thyroid function.²

SLK has been treated with silver nitrate or thermal cauterisation of the superior bulbar conjunctiva, pressure patching, and large diameter bandage contact lenses (BCL), topical trans-retinoic acid 0.1%, and recession or resection of the superior bulbar conjunctiva.^{1,3} Over 50% of patients with SLK are said to have keratoconjunctivitis sicca⁴ and recently upper punctal plugs have been used to treat SLK.⁵

We report two cases in which a unilateral BCL wear ameliorated the symptoms of bilateral SLK and a possible explanation is discussed.

Case reports

Case 1

A 38 year old woman presented with a 3 month history of irritable photophobic eyes that were unresponsive to preserved lubricants. Her right eye was amblyopic. On systemic review she reported weight loss, heat intolerance, and insomnia.

Slit lamp examination revealed bilateral superior conjunctival hyperaemia, superior punctate epithelial erosions, and four to five filaments and micropannus on the superior cornea of each eye. Both superior tarsal conjunctivae had moderate papillary reactions. Schirmer's test without anaesthesia was 14 mm on the right and 15 mm on the left at 5 minutes. Non-preserved lubricants every 1-2 hours and Lacrilube ointment at night were prescribed. Thyroid function tests revealed hyperthyroidism and she was referred to an endocrinologist who commenced carbimazole.

Three months later she returned still complaining of persistent severe discomfort, photophobia, and a burning sensation in both eyes. The ocular examination was unchanged. A silicone hydrogel BCL (Pure Vision, Bausch and Lomb, 36% water content) was inserted into the right eye and within an hour she had symptomatic relief in both eyes. Non-preserved lubricants were continued for the left eye.

On review 2 months after insertion of the BCL she remained asymptomatic. Mild superior limbal hyperaemia on the right and punctate staining of the superior conjunctiva and adjacent cornea on the left were found on examination.

Case 2

A 54 year old woman was referred with a 3 year history of sore, gritty eyes, worse on the left. The tear break up time was <10 seconds and Schirmer test without anaesthesia was right 0 mm and left 1 mm after 3 minutes. There was some relief from lubricants, though on occasion the pain was so severe that she required oral analgesia.

On examination punctate epithelial erosions were found on the superior bulbar conjunctiva of both eyes, but were more marked on the left (Fig 1). A silicone hydrogel BCL (Pure Vision, Bausch and Lomb) was inserted into the left eye, which rapidly ameliorated the symptoms in both eyes. Lubricants were continued for the right eye.

Three months later she remained asymptomatic and no fluorescein staining was seen. The BCL was removed. Within a month her bilateral ocular discomfort returned and the left BCL was refitted with immediate symptomatic relief in both eyes. Two months later the BCL was lost and her bilateral ocular discomfort recurred within 2 days. Since then her BCL has been replaced every 3 months. Occasionally she has used lubricants for the right eye.

One year following her presentation she became tachycardic and hyperthyroidism was diagnosed. Her endocrinologist commenced carbimazole and β blockers. Her treatment was later changed to propylthiouracil after she suffered from carbimazole induced arthralgia. Thyroid function tests were normal 6 months later and the propylthiouracil was stopped.

Comment

The pathogenesis of SLK is unclear. It may be the result of mechanical irritation from increased pressure of the upper eyelid against the globe and/or increased motility of the upper bulbar conjunctiva from hypothyroidism or ageing.^{2,6} Increased upper eyelid tightness may be the result of thyroid eye disease or chronic inflammation and, in addition, may

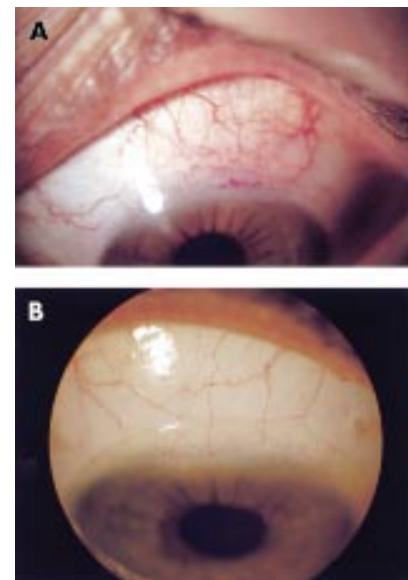


Figure 1 Case 2, left eye. (A) The superior bulbar conjunctiva, at presentation, showing hyperaemia and rose bengal staining. (B) After 3 months of bandage contact lens wear the superior conjunctival hyperaemia had resolved and the patient was asymptomatic.

impair the normal turnover of bulbar conjunctival epithelial cells.² This may be aggravated, in some patients, by blepharospasm, which increases the force on the globe.^{1,3}

Therapeutic lenses can produce rapid symptomatic relief in SLK.^{2,3} They may be helpful in the treatment of SLK as they relieve pain, facilitate healing of punctate epithelial erosions by protecting the ocular surface from the eyelids, reduce upper lid pressure on the globe, and alter tear dynamics.⁷ During blinking as the upper lid moves downwards to meet the lower lid significant forces are exerted on the globe.⁸ The lens can reduce the force on the superior limbus from blinking as it has a lower mechanical stiffness and elastic modulus.^{3,9}

In the first week of contact lens wear tear production increases dramatically and tear tonicity decreases.⁸ Tear production then normalises and tear tonicity rises as evaporation increases.⁸ A lens may then aid aqueous tear deficiency, which can accompany SLK,⁴ by ensuring a continuous precorneal tear film.⁷

It is difficult to be certain of the mechanism of bilateral symptom relief from unilateral BCL wear in SLK. One possible explanation is that BCL wear reduces the tactile corneal reflex, measurable 1–2 hours after lens insertion, and this reduction, which increases with the duration of lens wear, would then decrease bilateral reflex blinking.^{8,10} This would protect the superior limbus in both eyes from the mechanical friction associated with blinking and may also break the cycle that leads to blepharospasm in SLK.³

It should not be forgotten that continuous BCL wear carries risks including microbial keratitis and corneal vascularisation.^{6,11} New extended wear silicone BCL, as used in our patients, increase oxygen transfer and have been shown to reduce such risks.¹¹

S Watson, A B Tullo, F Carley

Corneal Unit, Manchester Royal Eye Hospital, Oxford Road, Manchester M13 9WH, UK

Correspondence to: Mr Tullo;
atullo@central.cmht.nwest.nhs.uk

Accepted for publication 17 December 2001

References

- Theodore FH.** Further observations on superior limbic keratoconjunctivitis. *Trans Am Acad Ophthalmol Otolaryngol* 1967;**71**: 341–51.
- Wright P.** Superior limbic keratoconjunctivitis. *Trans Ophthalmol Soc UK* 1972;**92**:555–60.
- Mandino BJ, Zaidman GW, Salamon SW.** Use of pressure patching and soft contact lens in superior limbic keratoconjunctivitis. *Arch Ophthalmol* 1982;**100**:1932–4.
- Udell IJ, Kenyon KR, Sawa M, et al.** Treatment of superior limbic keratoconjunctivitis by thermocauterisation of the superior bulbar conjunctiva. *Ophthalmology* 1986;**93**:162–6.
- Yang H-Y, Fujishima H, Toda I, et al.** Lacrimal punctal occlusion for the treatment of superior limbic keratoconjunctivitis. *Am J Ophthalmol* 1997;**124**:87.
- Cher I.** Superior limbic keratoconjunctivitis: multifactorial mechanical pathogenesis. *Clin Exp Ophthalmol* 2000;**28**:181–4.
- John T, Mobilia EF, Kenyon KR.** Therapeutic soft contact lens. In: Ruben M, Guillon M, eds. *Contact lens practice*. 1st ed. London: Chapman and Hall, 1994:889–890, 906–7, 910.
- Larke JR.** *The eye in contact lens wear*. 2nd ed. Oxford: Butterworth-Heinemann, 1997:9, 43, 141.
- Guillon M, Sammons WA.** Contact lens design. In: Ruben M, Guillon M, eds. *Contact lens practice*. 1st ed. London: Chapman and Hall, 1994:108.

10 Burton H. Somatic sensations from the eye. In: Hart WM, ed. *Adler's physiology of the eye*. 9th ed. St Louis: Mosby-Year Book, 1992:90.

11 Sankaridurg PR, Sweeney DF, Sharma S, et al. Adverse events with extended wear of disposable hydrogels: results for the first 13 months of lens wear. *Ophthalmology* 1999;**106**:1671–80.

MAILBOX

Keratectasia after PTK

Takahashi and colleagues have elegantly described an interesting and rare complication of phototherapeutic keratectomy (PTK) in their recent report of an unusual case of keratectasia after PTK.¹ The hypothesis that risk of ectasia is proportional to residual stromal base, or depth of ablation, fits with the assumed biomechanical aetiology of this recently reported complication of laser refractive surgery. The generally accepted empirical minimum thickness of 250–300 µm of corneal stroma, excluding flap thickness, remains speculative, as we do not understand the underlying pathophysiology. Indeed, although Holland *et al* highlighted the association of thin residual stromal thicknesses, post-PRK and LASIK, with keratectasia, they also described this complication after surface based hypermetropic PRK ablation, where the centre was minimally ablated and residual stromal thickness was greater than 360 µm.²

The authors suggest, in the reported case, that band-shaped keratopathy (BSK) may have compromised the tensile strength of the cornea. This seems unlikely as this condition generally affects the superficial anterior cornea, and usually does not penetrate deeper than Bowman's layer, hence its suitability for treatment by PTK. However, further clinical detail which the authors have not provided might reveal underlying corneal pathology with secondary "rough" BSK rather than "smooth" BSK.

However, there are a number of reasons, other than simple biomechanical compromise, for keratectasia following PTK in this case: (1) forme fruste keratoconus—as no preoperative topography or surface asymmetry values are presented to enable the reader to rule this out; (2) clinical keratoconus, which seems less likely in respect of patient's age and a preoperative cylindrical error of only –1.5D; (3) idiopathic keratectasia, possibly secondary to widespread deregulated keratocyte apoptosis. The latter has been demonstrated after LASIK, with a considerable and longstanding decrease in keratocytes in the peri-ablation area.³ Also, Helena *et al* demonstrated apoptosis to a depth of at least 50 µm after all of the following procedures: epithelial scrape, corneal scrape PRK, transepithelial PRK, and LASIK. Epithelial scrape and LASIK demonstrated keratocyte apoptosis to depths of up to 75 µm and 100 µm, respectively. The authors have recently identified a keratocyte free zone 160 µm into the stroma following LASIK, and theoretically more widespread apoptosis as a response to excimer laser photorefractive surgery, may contribute to keratectasia.

While it is difficult to ascertain why keratectasia occurs, in this case with a residual stromal thickness of over 500 µm, from the data provided the most likely aetiologies would seem to be either undiagnosed forme fruste keratoconus or idiopathic keratectasia. Currently,³ recent reviews illustrate the dearth

of substantial information available regarding idiopathic keratectasia (iatrogenic keratoconus), with a little over 60 cases published. At this point, although some are likely to be due to over-ablation, for many cases such as this the exact aetiology remains unknown and is likely to be multifactorial, and one of these factors is residual corneal thickness. The fact that keratectasia can occur, after what would be considered minimal ablation, highlights the unpredictability of occurrence, but with over a million cases of LASIK or PRK occurring each year, the stimulus to identify contributing factors is significant.

Simon J Dean, Charles N J McGhee

Discipline of Ophthalmology, Faculty of Medicine and Health Sciences, University of Auckland, Private Bag 92019, Auckland, New Zealand

Correspondence to: Professor C N J McGhee;
c.mcgee@auckland.ac.nz

References

- Miyata K, Takahashi T, Tomidokoro A, et al.** Iatrogenic keratectasia after phototherapeutic keratectomy. *Br J Ophthalmol* 2001;**85**:247–8.
- Holland SP, Sriwannaboon S, Reinstein DZ.** Avoiding serious corneal complications of laser assisted in situ keratomileusis and photorefractive keratectomy. *Ophthalmology* 2000;**107**:640–52.
- Vesaluoma M, Perez-Santonja J, Petroll WM, et al.** Corneal stromal changes induced by myopic LASIK. *Invest Ophthalmol Vis Sci* 2000;**41**:369–76.
- Helena MC, Baerveldt F, Kim WJ, et al.** Keratocyte apoptosis after corneal surgery. *Invest Ophthalmol Vis Sci* 1998;**39**:276–83.
- Edwards M, Kent D, McGhee CNJ.** Keratectasia (iatrogenic keratoconus) following laser refractive surgery. *J CME Ophthalmol* 2001;**50**:70–3.

BOOK REVIEWS



Age Related Macular Degeneration—Current Treatment Concepts.

Eds WE Alverti, G Richard, RH Sagerman. Pp 150; £51.50. Berlin: Springer, 2000. ISBN 3-540-66643-5.

This book is one in a large series of medical radiology textbooks concentrating on diagnostic imaging and radiation oncology. There are 71 authors in all, the majority of whom work either in the eastern United States or Germany, and the book contains 24 chapters.

The text is aimed at specialists in radiotherapy rather than ophthalmology. The majority of the chapters are concerned with radiotherapy of age related macular degeneration (ARMD) with contributions from experts in this field. Some of the chapters contain results of controlled studies and are of good value, whereas others have less scientific merit in that they are long term follow up studies without controls. For ophthalmologists wishing to look into the subject of

radiotherapy for ARMD this would be a good source of material and is well referenced.

There are a few chapters on the clinical manifestations, diagnosis, and surgery of ARMD but there is no real mention of laser treatment. Many of these chapters are of limited scope and do not provide a comprehensive overview of the ophthalmic assessment and management of ARMD.

Although not stated in the book it reads as if it is the proceedings of a clinical meeting. The chapters do not read in a coordinated way and essentially present the results of individual units describing their methods and results of radiotherapy. As such it is a useful source of information for those with an interest in this topic but it is of limited value for ophthalmologists wishing to obtain a balanced view of current treatment of ARMD.

R H B Grey

Bristol Eye Hospital, Lower Maudlin Street, Bristol
BS1 2LX, UK

Clinical Ophthalmic Pathology.

John Harry, Gary Misson. Pp 376; £125. Oxford: Butterworth-Heinemann, 2001 ISBN 0 7506 2171 0.

This is an excellent, easy to read, well illustrated book. It is one of the first of its kind to bring pathology alive by describing diseases via pathogenesis as opposed to anatomy. For the trainee in ophthalmology, optometry, and visual science it, therefore, provides a more logical approach to the understanding of ocular diseases. As the book attempts to cover many subjects it sometimes does not do justice to the basic science. It would have been better to have had the reading lists at the end of each chapter. However, as it stands the book is an excellent introduction to pathology complementing clinical textbooks. If read together with clinical texts it certainly will broaden the knowledge base of all trainee ophthalmologists. As a result of its logical and simple approach I was left frustrated at times with the lack of background knowledge. However, going through pathologically based chapters including injury and repair, immunity, genetics, growth, degeneration, vascular disorders, and disorders of the nerve and muscle, I was left entertained, as a clinician, with a greater understanding of pathological processes.

The final chapter for the clinician in the laboratory I felt could have been expanded, delivering more detail, particularly, on the current molecular methods used in pathological practice today.

A Dick

NOTICES

Childhood blindness

The latest issue of *Community Eye Health* (No 40) discusses new issues in childhood blindness, with an editorial by Clare Gilbert, senior lecturer at the International Centre for Eye Health. For further information please contact: Journal of Community Eye Health,

International Centre for Eye Health, Institute of Ophthalmology, 11–43 Bath Street, London EC1V 9EL, UK (tel: +44 (0)20 7608 6910; fax: +44 (0)20 7250 3207; email: eyeresource@ucl.ac.uk; website: www.jceh.co.uk). Annual subscription (4 issues) UK£25/US\$40. Free to workers in developing countries.

International Centre for Eye Health

The International Centre for Eye Health has published a new edition of the *Standard List of Medicines, Equipment, Instruments and Optical Supplies* (2001) for eye care services in developing countries. It is compiled by the Task Force of the International Agency for the Prevention of Blindness. Further details: Sue Stevens, International Centre for Eye Health, 11–43 Bath Street, London EC1V 9EL, UK (tel: +44 (0)20 7608 6910; email: eyeresource@ucl.ac.uk).

Second Sight

Second Sight, a UK based charity whose aims are to eliminate the backlog of cataract blind in India by the year 2020 and to establish strong links between Indian and British ophthalmologists, is regularly sending volunteer surgeons to India. Details can be found at the charity website (www.secondsight.org.uk) or by contacting Dr Lucy Mathen (lucymathen@yahoo.com).

Specific Eye ConditionS (SPECS)

Specific Eye ConditionS (SPECS) is a not for profit organisation which acts as an umbrella organisation for support groups of any conditions or syndrome with an integral eye disorder. SPECS represents over fifty different organisations related to eye disorders ranging from conditions that are relatively common to very rare syndromes. We also include groups who offer support of a more general nature to visually impaired and blind people. Support groups meet regularly in the Boardroom at Moorfields Eye Hospital to offer support to each other, share experiences and explore new ways of working together. The web site www.eyecconditions.org.uk acts as a portal giving direct access to support groups own sites. The SPECS web page is a valuable resource for professionals and may also be of interest to people with a visual impairment or who are blind. For further details about SPECS contact: Kay Parkinson, SPECS Development Officer (tel: +44 (0)1803 524238; email: k@eyeconditions.org.uk; www.eyecconditions.org.uk).

XXIXth International Congress of Ophthalmology

The XXIXth International Congress of Ophthalmology will be held on 21–25 April 2002 in Sydney, Australia. Further details: Congress Secretariat, C/- ICMS Australia Pty Ltd, GPO Box 2609, Sydney, NSW 2001, Australia (tel: +61 2 9241 1478; fax: +61 2 9251 3552; email: ophthal@icmsaust.com.au; website: www.ophthalmology.aust.com).

12th Meeting of the European Association for the Study of Diabetic Eye Complications (EASDEC)

The 12th meeting of the EASDEC will be held on 24–26 May 2002 in Udine, Italy. The deadline for abstracts is 15 February 2002. Three travel grants for young members (less than 35 years of age at the time of the meeting) are available. For information on the travel grants, please contact Pr CD Agardh, President of EASDEC, Malmö University Hospital, SE-205 02 Malmö, Sweden (tel +46 40 33 10 16; fax: +46 40 33 73 66; email: carl-david.agardh@endo.mas.lu.se). Further details: NORD EST CONGRESSI, Via Aquileia, 21–33100 Udine, Italy (tel: +30 0432 21391; fax: +39 0432 50687; email: nordest.congressi@ud.nettuno.it).

3rd Interdisciplinary Symposium on the Treatment of Autoimmune Disorders

The 3rd Interdisciplinary Symposium on the Treatment of Autoimmune Disorders will be held in Leipzig, Germany on the 6–8 June 2002. Topics to be covered include: basic aspects of autoimmune diseases, experimental therapeutic concepts, and clinical studies providing novel concepts or novel focus on established therapies. There will also be the presentation of the Nils-Ilja-Richter Award (application deadline is April 2002, further details on the web site). Further details: Prof. Dr. med. Michael Sticherline, Department of Dermatology, University of Leipzig (email: sticm@medizin.uni-leipzig.de; website: www.autoimmun.org); Fördergesellschaft zur Therapie von Autoimmunerkrankungen e.V. (email: autoimmun.org@gmx.de).

International Society for Behçet's Disease

The 10th International Congress on Behçet's Disease will be held in Berlin 27–29 June 2002. Further details: Professor Ch Zouboulis (email: zoubbere@zedat.fu-berlin.de).

Singapore National Eye Centre 5th International Meeting

The Singapore National Eye Centre 5th International Meeting will be held on 3–5 August 2002 in Singapore. Further details: Ms Amy Lim, Organising Secretariat, Singapore National Eye Centre, 11 Third Hospital Avenue, Singapore 168751 (tel: (65) 322 8374; fax: (65) 227 7290; email: Amy_Lim@snecc.com.sg).

BEAVRS Meeting

The next BEAVRS meeting will be held in the Dalmahoy Hotel near Edinburgh on 31 October to 1 November 2002. Further details: Susan Campbell, Medical Secretary, Gartnavel General Hospital (email: susan.j.campbell.wg@northglasgow.scot.nhs.uk).

CORRECTION

The authors of the letter "Recurrent corneal ulceration as late complication of toxic keratitis", appearing in the February issue of *BJO* (2002;86:245–6), would like to add an author, SH Santander.