

# PostScript

## LETTERS

If you have a burning desire to respond to a paper published in the *BJO*, why not make use of our "rapid response" option?

Log on to our website ([www.bjophthalmol.com](http://www.bjophthalmol.com)), find the paper that interests you, and send your response via email by clicking on the "eletters" option in the box at the top right hand corner.

Providing it isn't libellous or obscene, it will be posted within seven days. You can retrieve it by clicking on "read eletters" on our homepage.

The editors will decide as before whether to also publish it in a future paper issue.

### Solitary CD30+ anaplastic large cell lymphoma of the eyelid showing regression

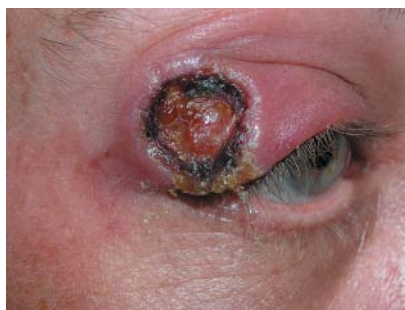CD30+ anaplastic large cell lymphoma (ALCL) belongs to the group of T cell non-Hodgkin's lymphomas. The primary cutaneous variant of ALCL usually presents as a solitary, cutaneous, or subcutaneous reddish violet lesion, which can be superficially ulcerated. We present the case of a solitary CD30+ ALCL of the eyelid showing regression.

#### Case report

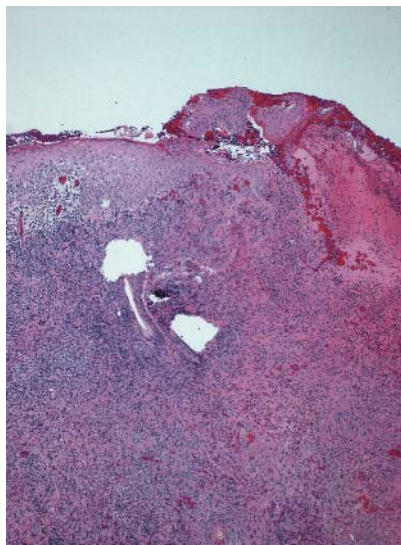
A 39 year old man presented with a 4 week history of a progressive painless ulcerating nodule on the right upper eyelid, unresponsive to oral flucloxacillin. He was systemically well and denied recent foreign travel or contact with animals.

A 17 mm diameter ulcer with rolled margins and serosanguinous exudate was evident over the right upper eyelid (fig 1). His cornea, conjunctiva, and anterior chamber were normal. Systemic examination was unremarkable.

Investigations including full blood count, urea and electrolytes, bone and liver profile, immunoglobulins and electrophoresis, auto-antibody screening, and *Treponema* antibody were normal or negative. Tissue culture failed to demonstrate a bacterial, viral, or fungal



**Figure 1** Ulcer right upper eyelid at initial presentation.

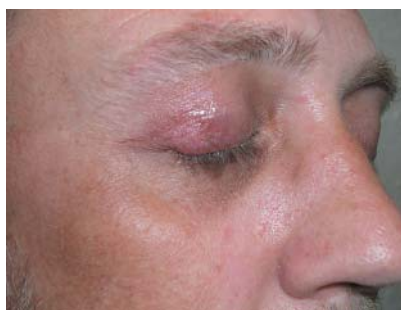

**Figure 2** Histopathology from ulcer edge.

pathogen. There was no clinical, radiological, or bone marrow evidence of extracutaneous disease.

Histology of the biopsy taken from the lid ulcer margin showed epidermal necrosis associated with ulceration (fig 2). The ulcer base showed haemorrhagic granulation tissue infiltrated by a mixture of lymphocytes, plasma cells, neutrophils, and eosinophils. There were also ill defined groups of large blast cells showing enlarged and pleomorphic nuclei and high mitotic activity. The immunohistochemical staining showed these cells to be of T cell lymphoid lineage. Many of the large blast cells were CD30 positive but negative for ALK-1 protein. The features were of a CD30 positive anaplastic large cell lymphoma (ALK negative).

Treatment options such as surgery and radiotherapy were discussed with the patient but as the lesion remained stable over a 10 day period, a conservative approach was agreed. A moderately potent topical corticosteroid (mometasone furoate 0.1% cream) was applied to the lesion once daily. When followed up 8 weeks later the ulcer had completely healed without scarring (fig 3).



**Figure 3** Resolution of lesion 8 weeks after first presentation.

Eighteen months has elapsed since presentation. There has been no recurrence of his disease, and he remains in good health.

#### Comment

ALCL represents a group of large cell lymphomas. They consist of a proliferation of predominantly large lymphoid cells with strong expression of the cytokine receptor CD30 (>75%). Using molecular and clinical criteria, three entities have been identified: primary systemic anaplastic lymphoma kinase (ALK) + ALCL, primary systemic ALK - ALCL, and primary cutaneous ALCL.<sup>1</sup>

Primary cutaneous ALCL arise de novo in the skin, commonly on the head and neck of older patients with a median age of 60 years and a male/female ratio of 3:2. Most patients present with solitary, asymptomatic nodules, which can be superficially ulcerated. Primary cutaneous ALCL has a more favourable prognosis than systemic ALCL, with a 5 year survival of approximately 90%. Partial or complete spontaneous regression can be observed in up to 25% of patients with primary cutaneous ALCL, accounting for the previous designation of "regressing atypical histiocytosis." Treatment of localised lesions usually includes excision with or without radiation. However, patients with disseminated skin disease may benefit from systemic polychemotherapy.<sup>2,3</sup> In our patient the lesion had resolved within 3 months of initial appearance. The application of a moderate potent topical steroid might have contributed to the regression of the ulcer.

We present a case of a primary cutaneous ALCL of the eyelid showing regression. Ophthalmologists should be aware of this sometimes self regressing entity and an expectant policy might be indicated in non-progressing tumours, thus avoiding potentially mutilating surgery or radiotherapy.

**S M Winhoven, S Murugesan, I H Coulson**  
Dermatology Department, Burnley General Hospital,  
Burnley, UK

Correspondence to: S M Winhoven, Dermatology Department, Burnley General Hospital, Burnley BB10 2PQ, UK; [swinhoven@hotmail.com](mailto:swinhoven@hotmail.com)

doi: 10.1136/bjo.2004.042804

Accepted for publication 14 July 2004

#### References

- 1 Stein H, Foss H, Dürkopp H, *et al*. CD30+ anaplastic large cell lymphoma: a review of its histopathologic, genetic, and clinical features. *Blood* 2000;**96**:3681–95.
- 2 Willemze R, Kerl H, Sterry W, *et al*. EORTC classification for primary cutaneous lymphomas: a proposal from the Cutaneous Lymphoma Study Group of the European Organization for Research and Treatment of Cancer. *Blood* 1997;**90**:354–71.
- 3 Burg G, Kempf W, Kazakov DV, *et al*. Pyogenic lymphoma of the skin: a peculiar variant of primary cutaneous neutrophil-rich CD30+ anaplastic large cell lymphoma. Clinicopathological study of four cases and review of the literature. *Br J Dermatol* 2003;**148**:580–6.

## Choroidal translocation with a pedicle following excision of a type 1 choroidal neovascular membrane

Excision of type 1 choroidal neovascular membranes (CNVM) in age related macular degeneration (AMD) have a poor visual outcome because of loss of retinal pigment epithelium (RPE).<sup>1</sup> Simple replacement of the RPE may not work because the relation with Bruch's membrane and choroidal complex is disturbed. Creating a free graft of these three layers detaches the choroid from its blood supply. Hence, restoration of these three layers to the subfoveal position while maintaining a connection to the adjacent choroidal blood supply is desirable.

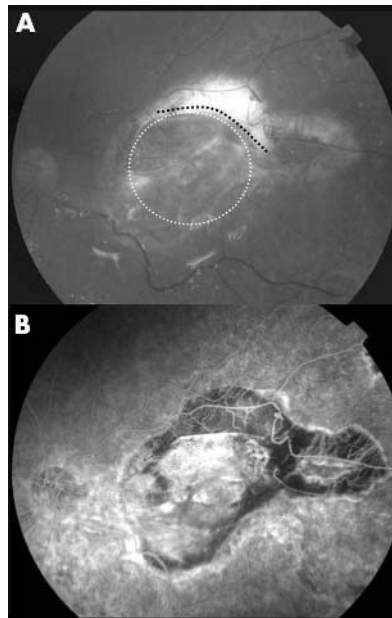
### Case report

A 74 year old woman presented with a 3 month history of a left central scotoma and visual acuity (VA) of counting fingers (CF). Clinical examination and fluorescein fundus angiography (FFA) confirmed a type 1 subfoveal CNVM. The fellow eye was 20/30 with scattered soft drusen. Pars plana vitrectomy (PPV) and excision of the CNVM were performed as described previously.<sup>2</sup> Atrophic choroidal vessels underlying the CNVM were not removed. A retinotomy was formed temporal to the fovea and vertical scissors inserted into the subretinal space. The RPE, Bruch's membrane, and choroid were incised en bloc in the area temporal to the site of the CNVM to create a graft on a pedicle. The graft was manipulated to a subfoveal position. The pedicle and graft were equally sized to maximally exploit the rich choroidal vasculature and maintain continuity to the choroidal circulation. We were unable to predetermine the position of choroidal vessels as indocyanine green angiography (ICG) was unavailable to us at the time of surgery. Surprisingly, little bleeding occurred and was easily controlled by increasing the infusion height. The patient required two subsequent operations for a rhegmatogenous retinal detachment with grade B proliferative vitreoretinopathy. The retina was flattened after inferior retinectomy and silicone oil insertion.

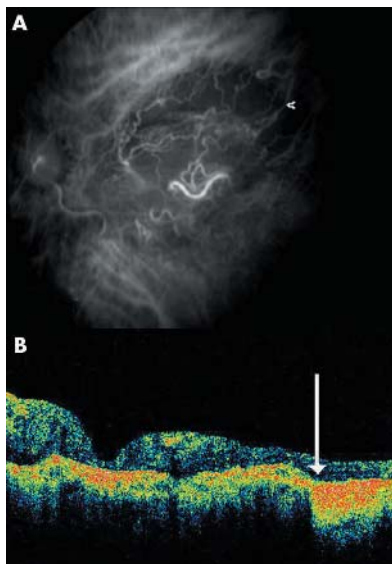
At review 4 years following initial surgery her vision was CF with a central scotoma on Goldmann field testing. The area of translocated RPE, Bruch's membrane, and choroid was visible beneath the fovea with bare sclera demarcating its original site (fig 1A). At 4 years following surgery there was no recurrence of the CNVM on FFA (fig 1B) and ICG angiography demonstrated that the graft and pedicle were vascularised (fig 2).

### Comment

Excision of type 1 CNVMs has a poor prognosis because of loss of RPE and atrophy of the choroid.<sup>2</sup> Restoration of the normal anatomical relation between the retinal receptors and the underlying structures is essential for visual recovery. Retinal translocation with strabismic surgery for the movement of the retina to healthy RPE is prolonged and hazardous. Transplantation of homologous RPE cells alone to a subfoveal position has met with varied success.<sup>3</sup> Aylward *et al* reported no visual improvement after transplantation of an autologous free graft, with fibrosis of the grafts at 10 months, perhaps because of loss of blood supply.<sup>4</sup> Late



**Figure 1** Retinal images 4 years following surgery (A) Fundus photograph demonstrating the area of RPE/choroidal translocation to a subfoveal position. The dark hashed line denotes the site of incision. The white dotted line denoted the resected area of choroid (B) Fluorescein angiography of the same eye in the late arteriovenous phase shows absence of late leakage and no recurrence of the CNVM.



**Figure 2** (A) Indocyanine green angiography (27 seconds) at 4 years following surgery demonstrates good vascular flow within the RPE/choroidal graft and through the pedicle (arrow). (B) Ocular coherence tomography scan thorough patient's macula shows clear demarcation between the highly reflective residual sclera and the less reflective signal from the transplanted choroid and RPE (arrow).

revascularisation of some grafts has been reported at 1 year.<sup>5</sup>

There was no visual improvement in our patient as she had a retinal detachment and additional procedures. We thought that the

rich and redundant blood supply of the choroid allowed some freedom in the choice of graft harvest site. As proof of principle we have demonstrated that a choroidal/RPE graft with a pedicle is a feasible surgical technique, resulting in a sustained and vascularised graft. This technique is simpler than time consuming retinal translocation and does therefore merit further investigation.

**R I Angunawela, T H Williamson**

Department of Ophthalmology, St Thomas's Hospital, London SE1 7EH, UK

**M A J Khan, V Chong**

Department of Ophthalmology, King College Hospital, London SE5 9RS, UK

Correspondence to: Dr Ramesh I Angunawela, Department of Ophthalmology, St Thomas's Hospital, London SE1 7EH, UK; romeshi@hotmail.com

doi: 10.1136/bjo.2004.050716

Accepted for publication 4 August 2004

### References

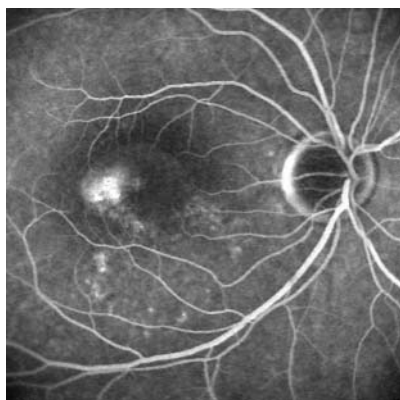
- Grossniklaus HE, Gass JD. Clinicopathologic correlations of surgically excised type 1 and type 2 submacular choroidal neovascular membranes. *Am J Ophthalmol* 1998;**126**:59-69.
- Merrill PT, LoRusso FJ, Lomeo MD, *et al*. Surgical removal of subfoveal choroidal neovascularization in age-related macular degeneration. *Ophthalmology* 1999;**106**:782-9.
- Binder S, Stalba U, Krebs I, *et al*. Transplantation of autologous retinal pigment epithelium in eyes with foveal neovascularization resulting from age-related macular degeneration: a pilot study. *Am J Ophthalmol* 2002;**133**:215-25.
- Stanga PE, Kychenthal A, Fitzke FW, *et al*. Retinal pigment epithelium translocation after choroidal neovascular membrane removal in age-related macular degeneration. *Ophthalmology* 2002;**109**:1492-8.
- Van Meurs JC, Van Den Biesen PR. Autologous retinal pigment epithelium and choroid translocation in patients with exudative age-related macular degeneration: short-term follow-up. *Am J Ophthalmol* 2003;**136**:688-95.

## Intravitreal triamcinolone acetonide and central serous chorioretinopathy

Intravitreal injections of triamcinolone acetonide have increasingly been performed as treatment for intraocular diseases with intraretinal oedema and with subfoveal fluid accumulation, such as diffuse diabetic macular oedema, persistent pseudophakic cystoid macular oedema, central retinal vein occlusion, and exudative age related macular degeneration.<sup>1-4</sup> In view of the widening spectrum of indications for intravitreal triamcinolone acetonide injections, it was the purpose of this study to evaluate whether intravitreal triamcinolone acetonide injections may be useful as treatment of long-standing central serous chorioretinopathy.

### Case report

A 50 year old patient presented with a decrease in visual acuity to 1/20 in his right eye because of long-standing central serous chorioretinopathy. Six years earlier, visual acuity had started to deteriorate, and had remained at 1/20 for the past 2 years. Fluorescein angiograms showed a mottled appearance of the retinal pigment epithelium close to the foveola, and a leakage of dye in the late phase of the angiogram. There was

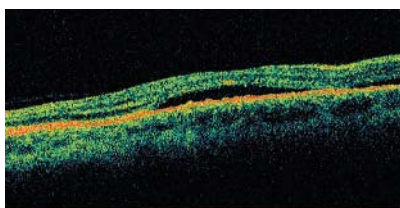


**Figure 1** Fluorescein angiogram taken before the intravitreal injection of triamcinolone acetonide. Mottled appearance of the retinal pigment epithelium, and shallow detachment of the fovea.

no clear smoke stalk phenomenon (fig 1). In optical coherence tomography, the central retina was detached. Despite intensive topical treatment with prednisolone acetate eye drops and oral intake of carbonic anhydrase inhibitors, the morphological appearance of the fovea and visual acuity remained unchanged. Under topical anaesthesia, the patient received an intravitreal application of 20–25 mg of triamcinolone acetonide, which was transconjunctivally injected through the pars plana into the centre of the vitreous cavity. The technique has already been described in detail.<sup>2</sup> The patient was fully informed about the experimental character of the treatment and had signed an informed consent. After the injection, all topical and systemic medication for his macular disorder was stopped.

Within the first 5 months after the injection, fluorescein angiograms and optical coherent tomograms did not show any marked changes in the macula (fig 2). Correspondingly, visual acuity remained at 1/20. Intraocular pressure increased up to levels of 30 mm Hg and was reduced to the normal values by topical application of a carbonic anhydrase inhibitor. Thirteen months after the injection, the fovea was still slightly detached. Visual acuity remained at 1/20.

The clinical course suggests that in this eye with longstanding central serous chorioretinopathy an intravitreal injection of a high dosage of triamcinolone acetonide was not accompanied by a fast resolution of the subfoveal fluid and an increase in visual acuity. For more than 5 months after the injection, the fovea remained clearly detached. The



**Figure 2** Optical coherent tomogram taken 5 months after the intravitreal injection of triamcinolone acetonide. Note: shallow detachment of the fovea.

partial resorption of the subfoveal fluid 13 months after the injection may not have necessarily been caused by intravitreal triamcinolone but may be explained by the natural course of the disease. The report agrees with other investigations in which patients with central serous chorioretinopathy did not markedly benefit from systemic steroid treatment.<sup>5</sup> This single case report, therefore, does not favour the use of intravitreal triamcinolone acetonide for this treatment.

J B Jonas, B A Kamppeier

Department of Ophthalmology, Faculty of Clinical Medicine Mannheim, Ruprecht-Karls-University of Heidelberg, Germany

Correspondence to: J Jonas, Universitäts-Augenklinik, Theodor-Kutzer-Ufer 1-3, 68167 Mannheim, Germany; Jost.Jonas@augen.ma.uni-heidelberg.de

doi: 10.1136/bjo.2004.054247

Accepted for publication 20 July 2004

Proprietary interest: None.

## References

- 1 Machemer R, Sugita G, Tano Y. Treatment of intraocular proliferations with intravitreal steroids. *Trans Am Ophthalmol Soc* 1979;**77**:171–80.
- 2 Jonas JB, Söfker A. Intraocular injection of crystalline cortisone as adjunctive treatment of diabetic macular edema. *Am J Ophthalmol* 2001;**132**:425–7.
- 3 Greenberg PB, Martidis A, Rogers AH, et al. Intravitreal triamcinolone acetonide for macular oedema due to central retinal vein occlusion. *Br J Ophthalmol* 2002;**86**:247–8.
- 4 Conway MD, Canakis C, Livir-Rallatos C, et al. Intravitreal triamcinolone acetonide for refractory chronic pseudophakic cystoid macular edema. *J Cataract Refract Surg* 2003;**29**:27–33.
- 5 Bouzas EA, Karadimas P, Pournaras CJ. Central serous chorioretinopathy and glucocorticoids. *Surv Ophthalmol* 2002;**47**:431–48.

## Vascular occlusion in serpiginous choroidopathy

Serpiginous choroidopathy (SC) is a rare disease inducing a permanent loss of vision, caused by a progressive destruction of the retinal pigment epithelium and choriocapillaris. Until now, no aetiology or predisposing factors have been reported. SC, usually, affects both eyes and occurs in patients between the fourth and sixth decade, without any sex or race predilection. Clinically, deep cream-coloured lesions develop in the peripapillary region and then along the retinal vessels, centrifugally, inducing an atrophy of the retina. Other lesions may develop, isolated, in the posterior segment. The anterior segment is typically quiet; nevertheless, a mild anterior uveitis and/or vitritis has been observed. The course of the disease results in successive attacks and recurrences inducing permanent retinal atrophic changes and subsequently an irreversible loss of vision. Choroidal neovascularisation may occasionally develop. No specific diagnostic tests are available such that the diagnosis of SC is mostly clinical.<sup>1</sup>

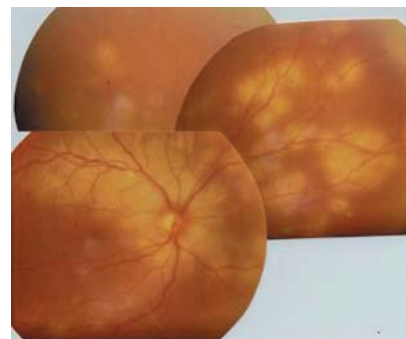
## Case report

A 30 year old Indian man presented with a history of painless progressive visual loss affecting the right eye. No other ophthalmological or systemic complaints were present. His medical history was unremarkable.

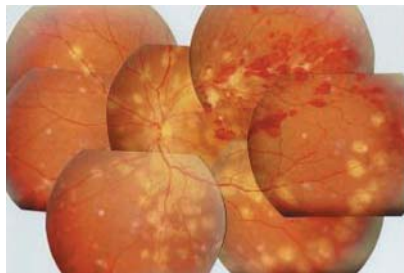Ophthalmological examination revealed a visual acuity of 20/50 in the right eye and 20/20 in the left eye without a correction in both eyes. Anterior segment examination revealed a mild inflammation with fine keratic precipitates on the inferior part of the right corneal endothelium. Intra-ocular pressure was 10 mm Hg in both eyes. Fundus examination of the right eye disclosed a moderate vitreous inflammation (cells: +) and multiple deep cream choroidal lesions around the optic disc and along the superior and inferior retinal (temporal and nasal) vessels (fig 1). Our differential diagnosis was a white dot syndrome (APMPPE, SC), an infection (tuberculosis), or a sarcoidosis. We decided to hospitalise the patient.

A clinical examination revealed an erythrocyte sedimentation rate of 8 mm in the first hour (normal range 1–12), and a normal white blood count. Immunoglobulin electrophoresis, quantitative immunoglobulin levels, CD4-CD8 lymphocytes count, C3-C4 and CH50 examination were within the normal range. Tests for connective tissue disorders were negative and serum angiotensin converting enzyme was discreetly elevated (74 U/l, normal range = 18–55) with a normal lysozyme level. Infectious serologies (toxoplasmosis, *Borrelia burgdorferi*, *Treponema pallidum*, HIV, herpesvirus, *Leptospira*, *Bartonella*, rickettsiosis, brucellosis) were within the normal limits. An anterior chamber tap (polymerase chain reaction for herpes simplex virus (HSV) 1, HSV2, varicella zoster virus, cytomegalovirus, Epstein-Barr virus, toxoplasmosis, *Mycobacterium tuberculosis*) was negative. A lumbar puncture was normal (proteins 0.31 g/l, white cells  $3 \times 10^6$ /l, lymphocytes 74%), without oligoclonal bands on electrophoresis. PPD skin test was positive (15 mm) but chest x ray was normal. We have to consider that the patient has had a BCG vaccine in his childhood. The patient was HLA-B27 and A-29 negative but HLA B-7 positive. The initial clinical examination was completed by a neurological and a dermatological examination which were normal. A magnetic resonance image cerebral scan was normal.

The patient was given a course of methylprednisolone intravenously ( $4 \times 250$  mg/day for 5 days) followed by oral prednisone (1 mg/kg) at tapering doses, and aciclovir ( $3 \times 10$  mg/kg), intravenously for 10 days. We covered the patient with rifampicin, isoniazide, ethambutol, pyrazinamide, and B6 vitamin. Topical steroids and mydriatics were administered.



**Figure 1** Fundus of the right eye. Presence of multiple deep creamy choroidal lesions along the retinal vessels.



**Figure 2** Fundus of the left eye. Presence of multiple deep creamy choroidal lesions along the retinal vessels with a vascular occlusion along the superior temporal vein. The patient was treated with steroids, aciclovir, and anti-tuberculosis treatment.

A regression of the inflammation in the right eye was noted as well as a "cicatrisation" of the choroidal lesions, which appeared as multiple geographical areas of atrophy of both the retina and pigmentary epithelium between areas of normal retina. Our suspected diagnosis was a SC.

After 3 weeks, the patient developed the same lesions in the left eye with an occlusion of the superior temporal vein (fig 2). At that time the patient was on prednisone 40 mg/day and anti-TB treatment. A complete clinical examination was done again, but still all results were within the normal limits. The same treatment was introduced (methylprednisolone, intravenous aciclovir).

As the relapse occurred under steroid therapy (prednisone 40 mg/day), the administration of an immunosuppressive drug was discussed. The patient was given mycophenolate mofetyl (Cellcept, 2 g/day) and oral prednisone for 1 year, at tapering doses. Anti-TB treatment was continued too. No secondary effects were noted.

We followed the patient during 12 months; his visual acuity returned to 20/20, without a correction, in both eyes. The anterior segment was normal. Posterior segment examination disclosed permanent geographic chorioretinal atrophic lesions along the vessels in both eyes, confirming the diagnosis of SC.

### Comment

SC induces a progressive loss of the retinal pigment epithelium and choriocapillaris. The cause of this disorder is still under investigation but some studies suggest that an inflammatory or a vascular factor are involved in the pathogenesis.<sup>2</sup> Histopathological studies have shown the presence of extensive lymphocyte choroidal infiltrates but in eyes chronically affected.<sup>3</sup> The distribution of the lesions and their angiographic features (fluorescein and green indocyanine) may suggest a choroidal occlusion.<sup>4</sup> Genetic studies demonstrated an increased frequency of HLA-B7 in this affection<sup>5</sup>; our patient was positive. SC affects not only white people but also oriental and blacks people. There is no sex predilection and the patients are middle aged when the diagnosis is made. The patient described in this report was 30 year old which is uncharacteristic. The aetiology remains unknown although recently tubercular serpigino-like choroiditis has been reported.<sup>6</sup>

Clinically, inflammatory signs may be noted both in segments (anterior uveitis, vitritis) along with the classic whitish choroidal lesions in the acute stage. The most

frequent ocular complication of SC is subretinal neovascularisation which affects 13% to 20% of the eyes. Retinal vasculitis is also observed.

Gupta *et al* reported a case of SC with a branch vein occlusion in the acute phase.<sup>6</sup> Our patient developed a vein occlusion while under treatment (steroids, aciclovir, and anti-TB therapy) which is rare and was never reported to our knowledge. Haemorrhages are sometimes observed in inflammatory diseases (Behçet's syndrome, sarcoidosis) or in infectious posterior uveitis (syphilis, viral infections, toxoplasmosis<sup>7</sup>).

This case demonstrates that SC can affect young patients and that HLA-B7 can be found in Indian patients with SC. The clinical features (vascular occlusion in this case) and the development of new lesions while under treatment let us suspect that the cause of this disease is still not clear.

**E Baglivo, S Boudjema, C Pieh, A B Safran**

Clinique d'Ophthalmologie-Hôpitaux Universitaires de Genève, Rue Alcide-Jentzer, 22-CH 1205 Geneva, Switzerland

**C Chizzolini**

Département d'immunologie clinique-Hôpitaux Universitaires de Genève, Rue Micheli du Crest-CH 1205 Geneva, Switzerland

**C Herbert**

Clinique de la Source. Avenue des Bergières, Lausanne, Switzerland

**N Rao**

Doheny Eye Institute. University of Southern California Keck School of Medicine, Los Angeles, CA, USA

Correspondence to: Edoardo Baglivo, Hôpitaux Universitaires de Genève, Clinique d'Ophthalmologie-Uveitis Department, rue Alcide-Jentzer, 22, CH-1205 Geneva, Switzerland; Edoardo.Baglivo@hcuge.ch

doi: 10.1136/bjo.2004.052126

Accepted for publication 27 August 2004

### References

- 1 Hooper PL, Secchi AG, Kaplan HJ. Serpiginous choroiditis. In: Pepose JS, Holland GN, Wilhelmus KR, eds. *Ocular infection and immunity*. St Louis: Mosby, 1996:1262-85.
- 2 King DG, Grizzard WS, Sever RJ, *et al*. Serpiginous choroidopathy associated with elevated factor VIII. *Retina* 1990;10:97-101.
- 3 Wu JS, Lewis H, Fine S, *et al*. Clinicopathologic findings in a patient with serpigino choroiditis and treated choroidal neovascularization. *Retina* 1989;9:292-301.
- 4 Giovannini A, Mariotti C, Ripa E, *et al*. Indocyanine green angiographic findings in serpigino choroidopathy. *Br J Ophthalmol* 1996;80:536-40.
- 5 Erkkilä H, Laatikainen L, Jokinen E. Immunological studies on serpigino choroiditis. *Graefes Arch Clin Exp Ophthalmol* 1982;219:131-4.
- 6 Gupta V, Gupta A, Arora S, *et al*. Presumed tubercular serpigino-like choroiditis. *Ophthalmology* 2003;110:1744-9.
- 7 Baglivo E, Safran AB. Haemorrhagic toxoplasmic retinochoroiditis: description of an unusual clinical presentation. *Br J Ophthalmol* 2003;87:1051-2.

### Persistent acanthamoeba keratitis in a non-contact lens wearer following exposure to bird seed dust

Acanthamoeba keratitis is a serious and vision threatening disease. It is commonly associated with contact lens wear (up to

93%).<sup>1</sup> Early diagnosis and treatment are essential to improve the visual outcome.<sup>2</sup> Devastating ocular damage can be attributed to various factors such as misdiagnosis,<sup>3</sup> incorrect treatment, excessive topical steroid before diagnosis,<sup>4</sup> and resistance.<sup>5</sup>

Acanthamoeba keratitis in non-contact lens wearers is rare and poses a diagnostic challenge. We present a case of acanthamoeba keratitis in a non-contact lens wearer following accidental exposure to bird seed dust. The strain of acanthamoeba obtained from this patient appeared to show in vivo and in vitro resistance to poly(hexamethylene biguanide, PHMB) and chlorhexidine after a good clinical response initially.

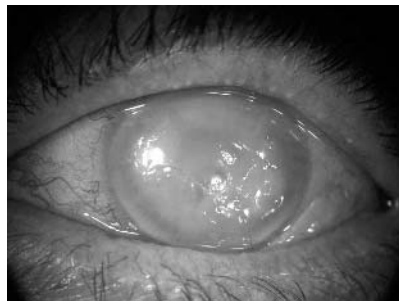
### Case report

A 57 year male patient presented with pain, blurring of vision, and photophobia of his left eye. Two weeks before the presentation he had an accidental exposure to bird seed dust (brand name Trill, manufactured by Master Foods, Hungary) for his budgies while cleaning the seed pot. It was a seemingly trivial injury, not likely to have caused a breach of epithelium. Examination revealed a visual acuity of 6/6 of the right eye and 6/18 for the left eye. The left eye showed multiple punctate epithelial erosions with epithelial and stromal infiltrates. There was no retained debris at the time of presentation. Initially he was treated as a case of viral keratitis with topical aciclovir and steroid. Although there was an early improvement, the keratitis relapsed after 2 weeks. At that stage a typical ring infiltrate suggestive of acanthamoeba keratitis developed and epithelial culture grew *Acanthamoeba polyphaga*. He was started on intensive treatment with PHMB, Brolene, and neomycin. His symptoms improved and his visual acuity recovered to 6/9 over a period of 3 weeks. Topical steroids were then added. The antimicrobial treatment was given for 2-3 months and withdrawn gradually over next 4-6 weeks after complete resolution. But following complete cessation of all drops he developed a recurrence with positive cultures. We restarted the intense treatment with PHMB and chlorhexidine, but the clinical response was poor. Pain was severe with intense limbal inflammation and signs of scleritis.

A corneal biopsy was performed which showed persistence of infection. Resistance to PHMB (minimum inhibitory concentration (MIC), 3.125 µg/ml) and chlorhexidine (MIC, 6.25 µg/ml) was demonstrated in the culture obtained from the biopsy. The strain showed in vitro sensitivity to propamidine (MIC, 3.9 µg/ml). A change of treatment to topical propamidine isethionate 0.1% (Brolene) and neomycin led to a rapid response with a decrease in symptoms. Six months after initial diagnosis he is comfortable on maintenance treatment with propamidine isethionate 0.1% and neomycin, but unfortunately has developed a dense central corneal scar (fig 1) and vision of hand movements.

### Comment

Acanthamoeba keratitis not related to contact lens wear has been reported before and risk factors include trauma, dirty water splash, and exposure to leaf juice.<sup>6</sup> Exposure to bird seed dust has to our knowledge not been reported previously as a known risk factor. Unfortunately, an attempt to culture acanthamoeba from the actual bird seeds and tray was unsuccessful. The second



**Figure 1** Photograph showing diffuse central corneal haziness. This photograph was taken 5 months after the initial visit. The area of biopsy is visible infranasally.

uncommon feature in our case is the demonstration of in vitro resistance of this strain of acanthamoeba to two of the modern first line acanthamoeba drugs (PHMB and chlorhexidine) while showing a good sensitivity to propamidine.

This is contrary to what has been reported by other authors.<sup>7,8</sup> We are unable to say whether resistance developed during treatment or was pre-existent, as sensitivity profiles of the earlier isolates were not obtained. This patient's initial good clinical response was achieved with a combination of PHMB and propamidine with the latter tapered early during the course of treatment, indicating at least partial in vivo sensitivity to PHMB in the earlier stages. A poor association between in vivo and in vitro resistance has been described for biguanides,<sup>7</sup> but this case shows that in vitro MIC can be useful information in the management of persistent acanthamoeba keratitis.

Other authors have stressed the need for long term treatment<sup>2</sup> and this case also underscores the importance of prolonged effective antimicrobial treatment in order to prevent recurrences.

**P P Syam, R Narendran, J van der Hoek**  
Department of Ophthalmology, Scarborough Hospital, Woodlands Drive, Scarborough, YO12 6QL, UK

Correspondence to: Mr P P Syam, Department of Ophthalmology, Peterborough Hospital, Thorpe Road, Peterborough PE3 6DA, UK; ppayam@aol.com

doi: 10.1136/bjo.2004.047670

Accepted for publication 26 July 2004

**References**

- 1 Radford CF, Lehmann OJ, Dart JKG. Acanthamoeba keratitis: multicentre survey in England 1992–1996. *Br J Ophthalmol* 1998;**82**:1387–92.
- 2 Bacon AS, Frazer DG, Dart JKG, et al. A review of 72 consecutive cases of acanthamoeba keratitis, 1984–1992. *Eye* 1993;**7**:719–25.
- 3 Berger ST, Mondino BJ, Hofl RH, et al. Successful medical management of Acanthamoeba keratitis. *Am J Ophthalmol* 1990;**110**:395–403.
- 4 McClellan K, Howard K, Niederkorn JY, et al. Effect of steroids on Acanthamoeba cysts and trophozoites. *Invest Ophthalmol Vis Sci* 2001;**42**:2885–93.
- 5 Ficker L, Seal D, Warhurst D, et al. Acanthamoeba keratitis: resistance to medical therapy. *Eye* 1990;**4**:835–8.
- 6 Sharma S, Garg P, Rao GN. Patient characteristics, diagnosis, and treatment of non-contact lens related Acanthamoeba keratitis. *Br J Ophthalmol* 2000;**84**:1103–8.

- 7 Perez-Santonja JJ, Kilvington S, Hughes R, et al. Persistently culture positive acanthamoeba keratitis. *Ophthalmology* 2003;**110**:1593–600.
- 8 Wysenbeek YS, Blank-Porat D, Harizman N, et al. The reculture technique: individualizing the treatment of Acanthamoeba keratitis. *Cornea* 2000;**19**:464–7.

**Brinzolamide induced reversible corneal decompensation**

Topical carbonic anhydrase inhibitors (CAIs) such as brinzolamide 1% (Azopt; Alcon Laboratories, Fort Worth, TX, USA) attenuate bicarbonate efflux, and this may lead to corneal oedema.

To our knowledge, this is the first report of complete resolution of corneal oedema after cessation of topical brinzolamide 1%.

**Case reports**

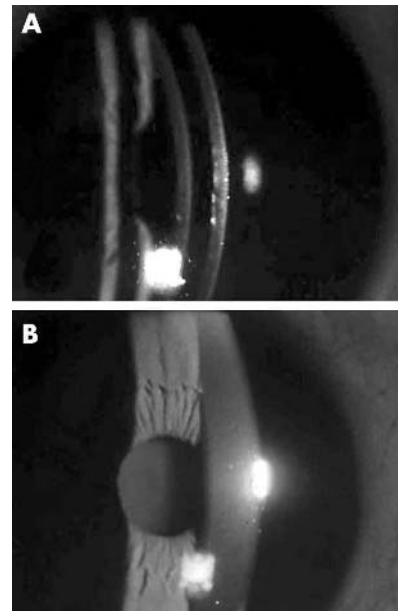
A 57 year old African-American man with primary open angle glaucoma (POAG) presented with painless blurry vision left eye 1 hour after instilling brinzolamide 1% in both eyes. He had been on brinzolamide 1% both eyes twice daily, brimonidine tartrate 0.2% (Alphagan) in both eyes twice daily, and latanoprost 0.005% (Xalatan) in both eyes once at night for 2 years. On presentation, best corrected visual acuity (BCVA) was 20/25 right eye and 20/50 left eye. The left eye had mild corneal oedema, Descemet's folds, and whitish fleck-like debris on the corneal endothelium (fig 1A). Intraocular pressures (IOPs) were 15 mm Hg and 16 mm Hg. The brinzolamide 1% in both eyes was discontinued. Timolol maleate 0.5% (Timoptic) in both eyes twice daily and topical prednisolone acetate 1% (Pred Forte) left eye four times daily were started. By 1 week follow up, the cornea was clear (fig 1B). Specular microscopy revealed endothelial cell counts (ECC) of 1355 cells/mm<sup>2</sup> right eye and 648 cells/mm<sup>2</sup> left eye with enlarged pleomorphic endothelial cells left eye (fig 2). Central corneal thickness (CCT) was measured as 512 µm right eye and 505 µm left eye.

A 77 year old white man, who had had cataract extraction 46 years earlier and subsequent aphakia right eye, had been followed for open angle glaucoma in both eyes for 25 years. He was on timolol maleate 0.5% in both eyes twice daily, latanoprost 0.005% in both eyes once at night, and pilocarpine hydrochloride 4% gel (Pilopine Gel HS) in both eyes once at night. His visual acuities were hand movement right eye and counting fingers at 1 foot left eye. An IOP of 19 mm Hg right eye and 10 mm Hg left eye necessitated the addition of brinzolamide 1% twice daily right eye. Both corneas were clear at that time. Fifteen months after starting brinzolamide 1%, there was moderate corneal oedema right eye. Brinzolamide 1% was discontinued. Over 3 months, the corneal oedema in the right eye gradually resolved. The patient later needed trabeculectomy with mitomycin C right eye because of medically uncontrolled IOP.

**Comment**

The Merck Worldwide Adverse Experience System database for dorzolamide 2% includes 25 reports of corneal oedema. Nearly all of these cases had a history of multiple ocular surgeries and compromised corneas.<sup>1</sup>

Dorzolamide is a reversible inhibitor of carbonic anhydrase II and does not accumulate in the cornea with repeat dosing,<sup>2</sup> so any




**Figure 1** Case 1. (A) Corneal oedema left eye with Descemet's folds 10 hours after the last dose of topical brinzolamide 1%. (B) Corneal oedema completely resolved 7 days after discontinuing brinzolamide 1% with minimal guttata noted.

corneal effect from a similar medication should indeed be potentially reversible.<sup>1</sup> Dorzolamide's peak concentration in rabbit corneas is also reached 1 hour after dosing, and the half life in the cornea is approximately 2 hours.<sup>3</sup> This is consistent with case 1 having blurry vision 1 hour after instilling brinzolamide 1%.

Patients with primary open angle glaucoma or ocular hypertension and a baseline ECC of greater than 1500 cells/mm<sup>2</sup> have an average 3.6% decrease in ECC after a year of dorzolamide 2% three times daily.<sup>4</sup> This endothelial loss is much higher than the 0.6% annual rate seen in normal subjects.<sup>5</sup>

Topical CAIs can cause corneal oedema in compromised corneas—for example, those



**Figure 2** Case 1. Specular microscopy showing an ECC of 1355 cells/mm<sup>2</sup> right eye and 648 cells/mm<sup>2</sup> with pleomorphic cells left eye.

with cornea guttata,<sup>6</sup> but the oedema is reversible if identified early. Before initiating brinzolamide 1%, an ECC may be needed for high risk patients (that is, monocular, previous ocular surgery, corneal disease, etc). Because of the potentially irreversible nature of the corneal decompensation,<sup>7</sup> topical CAIs may be relatively contraindicated in patients with significant corneal disease.

Although dorzolamide and brinzolamide are both topical CAIs, their chemical formulas are different, and a side effect that is associated with dorzolamide may not necessarily be assumed to be associated with brinzolamide. It is important to be aware that brinzolamide can also potentially cause corneal oedema.

J C Zhao, T Chen

Department of Ophthalmology, Glaucoma Service, Massachusetts Eye and Ear Infirmary, Harvard Medical School, 243 Charles Street, Boston, MA 02114, USA

Correspondence to: Jing Cheng Zhao, MD, Progressive Vision Institute, 201 East Laurel Blvd, Pottsville, PA 17901, USA; jcz2020@hotmail.com

doi: 10.1136/bjo.2004.049544

Accepted for publication 25 July 2004

## References

- 1 Adamsons I. Irreversible corneal decompensation in patients treated with topical dorzolamide. *Am J Ophthalmol* 1999;**128**:774–6.
- 2 Sugrue MF, Johns B. Concentrations of dorzolamide in the pigmented rabbit eye after repeated dosing with Trusopt. *Invest Ophthalmol Vis Sci* 1999;**40**(Suppl):S171.
- 3 Sugrue MF, Harris A, Adamsons I. Dorzolamide hydrochloride: a topically active, carbonic anhydrase inhibitor for the treatment of glaucoma. *Drug of Today* 1997;**33**:283–98.
- 4 Lass JH, Khosrof SA, Laurence JK, et al. A double-masked randomized, 1-year study comparing the corneal effects of dorzolamide, timolol, and betaxolol. *Arch Ophthalmol* 1998;**116**:1003–10.
- 5 Bourne WN, Nelson LR, Hodge DO. Central corneal endothelial cell changes over ten-year period. *Invest Ophthalmol Vis Sci* 1997;**38**:779–82.
- 6 Wirtsch MG, Findl O, Kiss B, et al. Short-term effect of dorzolamide hydrochloride on central corneal thickness in humans with cornea guttata. *Arch Ophthalmol* 2003;**121**:621–5.
- 7 Konowal A, Morrison JC, Brown SV, et al. Irreversible corneal decompensation in patients treated with topical dorzolamide. *Am J Ophthalmol* 1999;**127**:403–6.

## An unusual cause of acquired horizontal diplopia in a young adult

Cysticercosis is caused by infection from the larval form of *Taenia solium*, is endemic to regions with poor sanitation. Human cysticercosis more commonly affects the central nervous system, with less common involvement of ocular tissues. Myocysticercosis is a subset of orbital cysticercosis and is considered a rare entity.

### Case report

A 19 year old Nepalese housewife presented with left sided headache that had been present for 1 year. She had been treated for migraine headache in another hospital.

Ocular examination revealed orthotropia in primary gaze with Snellen acuity of 6/6 bilaterally. Both the Humphrey visual fields and the colour vision testing were normal in

both eyes. There was no relative afferent pupillary defects detected. Ocular motility testing revealed left abduction deficit with the resulting horizontal diplopia. Hertel's exophthalmometer reading revealed no proptosis. Her fundi examination were both normal and there were no optic disc swelling.

Magnetic resonance image (MRI) (brain/orbit) with gadolinium contrast (fig 1) showed a cystic enhancing mass measuring 1.2 cm×0.6 cm adjacent to and including left medial rectus muscle, sparing the muscle tendon. Further assessment with B-scan ultrasonography (fig 2) revealed an intramuscular cyst within the left medial rectus muscle located within mid-orbit.

Full blood count found no eosinophilia; systemic cysticercosis involvement was excluded by negative radiological findings (chest x ray and computed tomography (CT) of brain and abdomen were all normal).

The patient was prescribed treatment with albendazole 15 mg/kg per day for 8 days. Unfortunately, she had intolerable side effects (nausea, vomiting, and distressing nocturnal left eye pain) to the medication which she used for only 3 days. She was reluctant to continue with albendazole. Her symptoms settled after a short course of oral analgesic.

She has remained asymptomatic. Repeated Hess and diplopia charts B-scan ultrasonography re-evaluation at 6 months did not reveal any cysts in the muscle and her ocular motility had returned to normal.

### Comment

The finding of "scolex" within the intramuscular cyst and her status of Nepalese native lend strongly to a diagnosis of myocysticercosis. Enzyme linked immunosorbent assay (ELISA) to detect the antibody to cysticercosis was unavailable in Singapore. A positive test may lend support to the diagnosis but a negative ELISA result does not rule out the diagnosis. Owing to the largely isolated and relatively mild infection of myocysticercosis, the sensitivity of ELISA is low.<sup>1</sup> For the same reason, the absence of peripheral eosinophilia in this case is not surprising, consistent with the finding in literature.<sup>2</sup>

None of the cases in a large series of orbital hydatid cysts were found within an extraocular muscle,<sup>2</sup> hence making this diagnosis unlikely. The location within an extraocular muscle accounted for only 1.1% to 4.1% of the total reported cases of cysticercosis.<sup>2</sup> Statistically, medial rectus is the most commonly involved extraocular muscle,<sup>2</sup> although any of them can be involved. As a general rule, the restriction of extraocular movements is

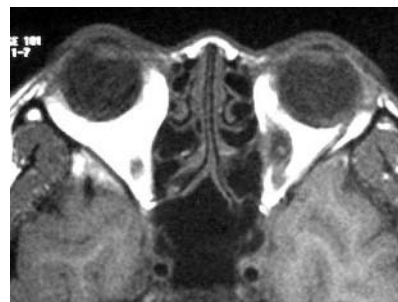


Figure 1 T1 axial MRI scan showing left intramuscular cyst with "scolex" within.

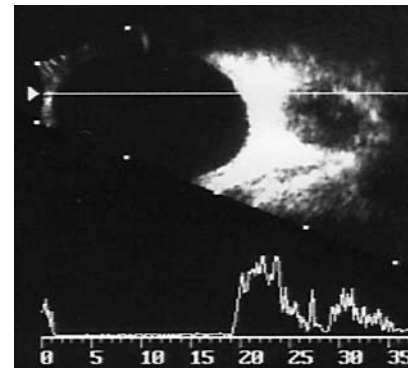


Figure 2 Left medial rectus intramuscular cystic lesion on B-scan (pretreatment).

greatest in the direction opposite to the involved muscle,<sup>2</sup> as in this case (fig 2).

Broad spectrum antihelmintics such as albendazole have been proved to be effective in the treatment of myocysticercosis.<sup>4,5</sup> Recommended duration of treatment varies from a few days to up to 6 weeks. Prolonged drug administration may not be necessary as seen in this case, in view of the drug's potential side effects.

Among the known side effects of albendazole are gastrointestinal upsets. The nausea and vomiting in this patient settled when the medication was discontinued. On the other hand, her nocturnal left eye pain would be best explained by secondary inflammation from the release of toxins by the dying parasite.<sup>2</sup> Concomitant administration of oral steroids has been suggested to reduce the secondary inflammation.<sup>1–4</sup>

Surgical excision of an extraocular muscle cyst had been described.<sup>6</sup> However the potential risk of damage to adjacent tissue and adhesion from surgical exploration should not be taken lightly, particularly when effective medical therapy is available.

Stool tests should be done for all the members of the family to detect asymptomatic carrier because the treatment with systemic antihelmintic treatment is highly effective.<sup>2</sup> It also serve to break the life cycle of the parasite.

Y C Wong, K Y Goh, C T Choo, L L Seah  
Singapore National Eye Centre, Singapore

J Rootman  
University of British Columbia, Canada

Correspondence to: Yiing Cheong Wong, Singapore National Eye Centre, Singapore; wonglyndr@yahoo.com

doi: 10.1136/bjo.2004.052258

Accepted for publication 1 July 2004

## References

- 1 Sekhar GC, Lemke BN. Orbital cysticercosis. *Ophthalmology* 1997;**104**:1599–604.
- 2 Pushker N, Bajaj MS, Betharia SM. Orbital and adnexal cysticercosis. (Review) *Clin Exp Ophthalmol* 2002;**30**:322–33.
- 3 Pushker N, Bajaj MS, Betharia SM. Ocular and orbital cysticercosis. *Acta Ophthalmol Scand* 2001;**79**:406–13.
- 4 Puri P, Grover AK. Medical management of orbital myocysticercosis: a pilot study. *Eye* 1998;**12**:795–9.

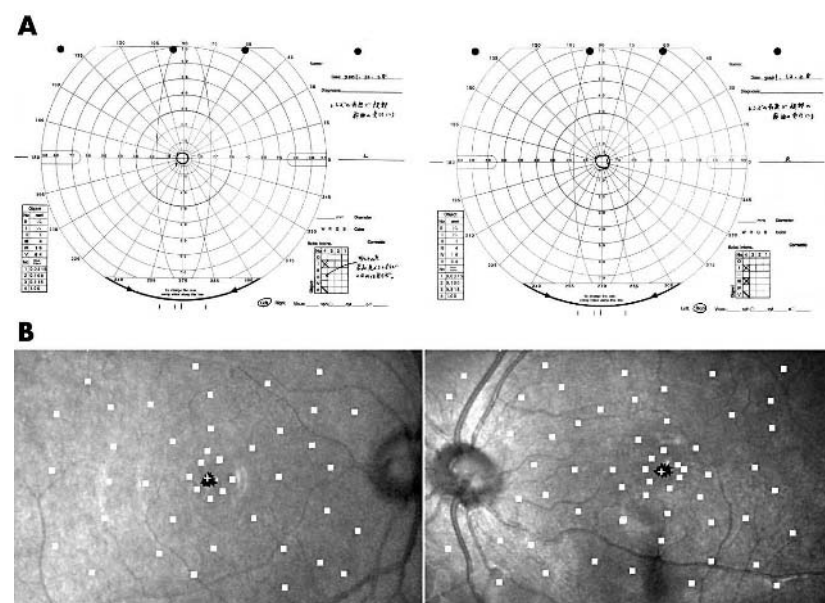
- 5 **Sihota R**, Honavar SG. Oral albendazole in the management of extraocular cysticercosis. *Br J Ophthalmol* 1994;**78**:621-3.
- 6 **DiLoreto DA**, Kennedy RA, Neigel JM, et al. Infestation of extraocular muscle by *Cysticercus cellulosa*. *Br J Ophthalmol* 1990;**74**:751-2.

### Use of scanning laser ophthalmoscopy in visual conversion reaction

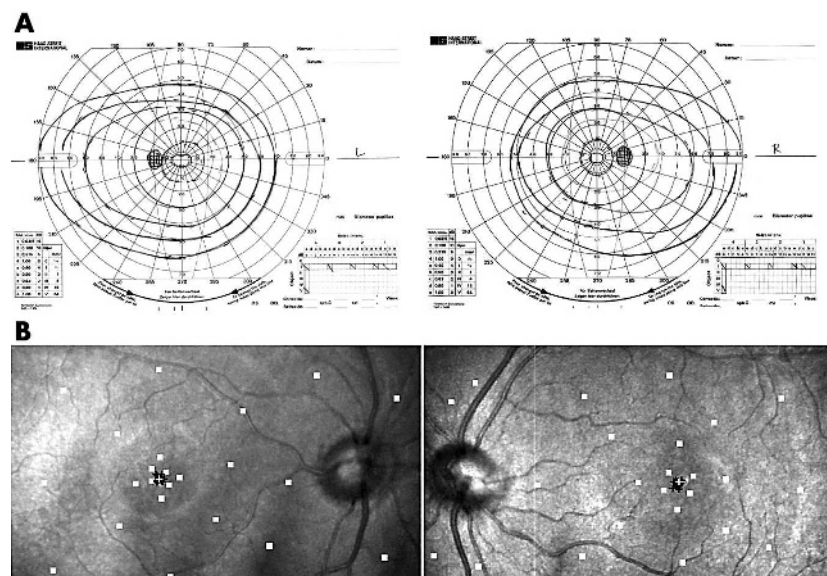
Visual conversion reaction is a psychosomatic anomaly that manifests as reduced visual acuity (VA) and visual field defects.<sup>1,2</sup> Scanning laser ophthalmoscopy (SLO) can detect a scotoma and VA under direct fundus observation.<sup>3-6</sup> However, there have been no reports of patients diagnosed with visual conversion reaction using SLO. We report a patient with visual conversion reaction using SLO.

#### Case report

A 20 year old woman presented with a sudden bilateral loss of vision. She reported being under severe stress at work. The best corrected visual acuity (BCVA) was counting fingers in both eyes. The external eye examination and pupillary responses were normal in both eyes. Conventional ophthalmoscopy, funduscopy, and fluorescein angiography were unremarkable. The visual fields were constricted to within 5° of fixation using Goldmann perimetry (fig 1A). The results of magnetic resonance imaging, computer tomography of the brain and orbits, visual evoked potentials, and electroretinography were unremarkable. A general medical examination showed no abnormalities. There were no scotomas (based on Goldmann size III stimulus on the retina), and the stability of fixation were central and stable using SLO microperimetry in both eyes (fig 1B). The VA using SLO was 20/200 in both eyes. We followed this patient for 10 months, and she consistently demonstrated impaired VA and visual field defects. She ultimately retired from the workforce.



**Figure 1** (A) The visual fields at the first visit using Goldmann perimetry (right eye, left; left eye, right). (B) The visual field at the first visit using SLO microperimetry (right eye, left; left eye, right).



**Figure 2** (A) The visual fields using Goldmann perimetry 10 months after the first visit (right eye, left; left eye, right). (B) The visual fields using SLO microperimetry 10 months after the first visit (right eye, left; left eye, right).

Ten months later, the BCVA was 20/20 both eyes. The visual fields in both eyes using Goldmann perimetry were normal (fig 2A). There were no scotomas, and the stability of fixation was central and stable in both eyes using SLO microperimetry (fig 2B). The VA using SLO was 20/20 in both eyes. We diagnosed visual conversion reaction in this case.

#### Comment

This is the first report of a patient with visual conversion reaction using SLO. In this case, the BCVA was counting fingers in both eyes at the first visit. However, the VA using SLO was 20/200 both eyes and better than the

conventional examination. The visual fields were constricted in both eyes to within 5° of fixation using Goldmann perimetry. However, there were no scotomas in either eye using SLO microperimetry. The distinction between the VA and visual fields between the conventional and SLO examinations was demonstrated over the 10 month follow up period. Ten months after the initial examination, the VA and visual fields were normal in both eyes by both conventional and SLO examinations. There was no distinction between them during the recovery period. Van de Velde reported that SLO results were comparable with those obtained during a conventional examination in normal subjects.<sup>3</sup> The distinction between the VA and visual field between the conventional and SLO examinations may help in the diagnosis of patients with visual conversion reaction. Future clinical studies of several cases of visual conversion reaction using SLO are needed.

**E Shimamoto, F Mori, S Ishiko, A Takahashi, N Izumi, A Yoshida**  
Department of Ophthalmology, Asahikawa Medical College, Asahikawa, Japan

Correspondence to: Fumihiko Mori, MD, PhD, Department of Ophthalmology, Asahikawa Medical College, Midorigaoka Higashi 2-1-1-1, Asahikawa 078-8510 Japan; morinao@d5.dion.ne.jp

doi: 10.1136/bjo.2004.052282  
Accepted for publication 13 July 2004

#### References

- 1 **Yasuna ER**. Hysterical amblyopia in children and young adults. *Arch Ophthalmol* 1951;**45**:70-6.
- 2 **Krill AE**, Newell FW. The diagnosis of ocular conversion reaction involving visual function. *Arch Ophthalmol* 1968;**79**:254-61.
- 3 **Van de Velde FJ**. Scanning laser ophthalmoscopy optimized testing strategies for psychophysics. *Lasers in ophthalmology IV*. Bellingham, WA: Proceedings of SPIE, 1996;**2930**:79-90.

- 4 **Yoshida A.** New examination methods for macular disorders—application of diagnosis and treatment. *Nippon Ganka Gakkai Zasshi* 2000;**104**:897–942.
- 5 **Mori F, Ishiko S, Kitaya N, et al.** Scotoma and fixation patterns using scanning laser ophthalmoscope microperimetry in patients with macular dystrophy. *Am J Ophthalmol* 2001;**132**:897–902.
- 6 **Mori F, Ishiko S, Kitaya N, et al.** Use of scanning laser ophthalmoscope microperimetry in clinically significant macular edema in type 2 diabetes mellitus. *Jpn J Ophthalmol* 2002;**46**:650–5.

## MAILBOX

### The severe acute respiratory syndrome coronavirus in tears

We welcome the article by Loon *et al.*<sup>1</sup> Earlier, we published our finding of the SARS coronavirus in specimens collected by the novel technique of conjunctiva upper respiratory tract irrigation (CURTI), but not in paired nose and throat swabs, very early in the course of the disease.<sup>2</sup> In designing CURTI, we considered safety to medical personnel and, also, finding a method that samples all three portals of entry for upper respiratory viral pathogens—the eyes, nose, and mouth. Loon *et al.*'s findings complement our study by showing that SARS coronavirus can indeed be found in tears.

While we agree with their conclusion that the ability to isolate the virus early in the course is important, we do not think that the eyes are important organs that propagate the virus, other than to ophthalmologists and to unwary close contacts. For instance, the eyes cannot generate infectious aerosol. Rather, we feel that the eyes are important portals of entry and have not been given sufficient attention—witness medical personnel in full personal protection gear and N95 masks but without watertight goggles, and sometimes without splashguards.

We also think that employing the services of ophthalmologists for the purpose of collecting tear specimens for the diagnosis of SARS is difficult to achieve in most medical environments. On the other hand, our method of CURTI is entirely self help, deployable in quarantine locations, and avoids unnecessary contact between an infectious source and susceptible individuals.

The finding of SARS CoV in tear raises several additional questions:

- (1) How does the virus end up in the tear? Was it the result of direct inoculation at the time of infection into permissive conjunctival epithelial cells, either by hand or aerosol, or was it the result of secretion from a lacrimal gland infected haematogenously? The lacrimal glands are not very different anatomically from the salivary glands. Yet saliva has been shown to be a poor specimen for the laboratory diagnosis of SARS.<sup>3</sup>
- (2) Was there any evidence of conjunctivitis, lacrimitis, or evidence of infection of the globe or nasolacrimal sac?
- (3) Is there any means or advantage in sampling the nasolacrimal sac, to which the tear drains, and could the nasolacrimal duct system be itself a hiding place for the SARS coronavirus during the incubation period?

T Tong, T Sik-to Lai

Room P-725, Block P, 7/F Princess Margaret Hospital, Lai King Hill Road, Laichikok, Hong Kong

Correspondence to: Dr Tommy Tong, Room P-725, Block P, 7/F Princess Margaret Hospital, Lai King Hill Road, Laichikok, Hong Kong; tommytong@yahoo.com

doi: 10.1136/bjo.2004.054130

Accepted for publication 14 July 2004

### References

- 1 **Loon SC, Teoh SC, Oon LL, et al.** The severe acute respiratory syndrome coronavirus in tears. *Br J Ophthalmol* 2004;**88**:861–3.
- 2 **Tong TR, Lam BH, Ng TK, et al.** Conjunctiva-upper respiratory tract irrigation for early diagnosis of severe acute respiratory syndrome. *J Clin Microbiol* 2003;**41**:5352.
- 3 **Drosten C, Chiu LL, Panning M, et al.** Evaluation of advanced reverse transcription-PCR assays and an alternative PCR target region for detection of severe acute respiratory syndrome-associated coronavirus. *J Clin Microbiol* 2004;**42**:2043–7.

### Comments on using fibrin glue in pterygium surgery

I read with great interest the article by Koranyi and coworkers, who evaluated a new technique for pterygium surgery using a fibrin tissue adhesive (Tisseel Duo Quick).<sup>1</sup> In their randomised trial the authors concluded that using the glue instead of sutures caused less postoperative pain and shortened the surgical time. Nevertheless, the timing of the randomisation is not clearly stated in their report.

Whether or not the surgeon knew the patient's group (sutures or fibrin glue) at the time of pterygium removal and conjunctival graft harvesting may have influenced the extent of the removal and the size of the graft. Therefore, the differences in postoperative pain and/or recurrence could be related to those initial steps and not only to the final step, as the authors suggest. Ideally, the surgeon should be informed if the conjunctival graft should be sutured or glued after harvesting it.

Additionally, in their discussion the authors did not mention the risk of infection when using fibrin glue. Some viruses, such as parvovirus B19 (HPV B19) are particularly difficult to remove or inactivate, and human infection has been reported after the use of fibrin glue.<sup>2</sup> In thoracic surgery, epidemiological evidence suggests that more than 20% of uninfected people were subsequently infected with HPV B19 by use of fibrin during the procedure.<sup>3</sup> Prions are also of concern. The direct application of any of the apparently effective methods of prion decontamination to plasma products is inappropriate because they are harsh and denaturing.<sup>4</sup> Although the risks for both diseases are minimal, the authors should have addressed this issue in their discussion.

Correspondence to: L S Alvarenga, Federal University of Sao Paulo, University of California Davis, Sacramento, CA 95825, USA; lsalvarenga@aol.com

doi: 10.1136/bjo.2004.054031

Accepted for publication 13 July 2004

### References

- 1 **Koranyi G, Seregard S, Kopp.** Cut and paste: a no suture, small incision approach to pterygium surgery. *Br J Ophthalmol* 2004;**89**:911–14.
- 2 **Hino M, Ishiko O, Honda K-I, et al.** Transmission of symptomatic parvovirus B19 infection by fibrin sealant used during surgery. *Br J Haematol* 2000;**108**:194–5.
- 3 **Kawamura M, Sawafuji M, Watanabe M, et al.** Frequency of transmission of human parvovirus B19 infection by fibrin sealant used during thoracic surgery. *Ann Thorac Surg* 2002;**73**:1098–100.
- 4 **Taylor DM.** Inactivation of TSE agents: safety of blood and blood-derived products. *Transfus Clin Biol* 2003;**10**:23–5.

### Authors' response

We thank Dr Alvarenga for his comment on our article about using fibrin glue for pterygium surgery.

We write in the "Material and methods" section that only the thickened and keratinised portion of the conjunctiva was excised and the graft was prepared to have the same size as the nasal conjunctival defect, regardless of which group the patient was randomised to. Thus, the knowledge of the surgery method did not influence the results or conclusions of the study. It is also impossible to randomise the patients without the surgeon's knowledge, because the grafts were handled somewhat differently in the different methods described.

The fibrin adhesives in the references mentioned by Alvarenga are clearly not Tisseel Duo Quick (Baxter). In the article by Hino *et al.*, the specific trade name of the fibrin sealant is not given, but the text states that the sealant in question is treated by dry heat to inactivate viruses—Tisseel is vapour heated, so it cannot be Tisseel. In the article by Kawamura *et al.* the product is Beriplast (Aventis Behring). Nevertheless, we will pay attention to this matter in the future. We have not been able to find any report of HPV B19 infection when fibrin glue was used in minor surgery. To date we have used the fibrin glue in more than 700 eye procedures since 1999. Any clinical infection with HPV B19 has not yet been detected in our patients.

G Koranyi, S Seregard, E D Kopp

St Erik's Eye Hospital, Karolinska Institute, Polhemsg 50 Stockholm, 11282, Sweden

Correspondence to: Dr G Koranyi, St Erik's Eye Hospital, Karolinska Institute, Polhemsg 50 Stockholm, 11282, Sweden; gabor.koranyi@sankterik.se

doi: 10.1136/bjo.2004.056648

Accepted for publication 19 August 2004

### Korean kindergarten vision screen programme

Lim *et al.* report a large scale effort to mix home plus health centre acuity screening in preschool children.<sup>1</sup> We are very encouraged by the work of Lim *et al.*, particularly concerning the frequency of ocular symptoms in the Korean preschooler, the number of children who were not dismissed from specified follow up (presumed amblyopia risk), and the inclusion of a simple, home administered test which over 97% of children were able to pass. It is of high merit that parents were carefully instructed to place tissue and tape over the non-tested eye,



though this does not preclude peeking if the parent is not paying particular attention. Positive answers to the parental questionnaire were not very specific for eye disease and therefore could greatly increase societal cost if used as a screening method. We have a few points of clarification for these authors: How was the home acuity test initially validated? Did a number of children who passed their home exam have gold standard confirmatory exams from which false negative and true negative rates could be estimated? The positive predictive value estimates utilise gold standard exam criteria that need further definition and/or standardisation. (1) It is not clear whether amblyopia was diagnosed at multiple eye clinics and by general or paediatric ophthalmologists, it is not clear what criteria are used to define amblyopia, and the criteria to be included as a "significant" cycloplegic refractive error vastly overestimates risk factors compared to a recently published attempt to standardise reporting of vision screening research.<sup>2</sup>

We would urge the authors to perform additional calculations on the breakdown of gold standard exam "significant" refractive errors<sup>2</sup> and better define how amblyopia was diagnosed.

**R W Arnold, J Ruben, S P Donahue,  
AAPOS Vision Screening Committee**

Alaska Blind Child Discovery, 542 West Second Avenue, Anchorage, AK 99501, USA

Correspondence to: Dr Robert Wendell Arnold, Alaska Blind Child Discovery, 542 West Second Avenue, Anchorage, AK 99501, USA; eyedoc@alaska.net

doi: 10.1136/bjo.2004.056663

Accepted for publication 19 August 2004

## References

- 1 **Lim HT, Yu YS, Park SH, et al.** The Seoul Metropolitan Preschool Vision Screening Programme: results from South Korea. *Br J Ophthalmol* 2004;**88**:929–33.
- 2 **Donahue S, Arnold R, Ruben JB.** Preschool vision screening: what should we be detecting and how should we report it? Uniform guidelines for reporting results from studies of preschool vision screening. *J AAPOS* 2003;**7**:314–15.

## IVF and retinoblastoma

I read with great interest the letter published in the *BJO* by Lee *et al.*<sup>1</sup> It reports on the first child born after in vitro fertilisation (IVF) and harbouring a unilateral retinoblastoma in the United States.

However, it should be noted that this reported child is the eighth documented child (not the sixth as mentioned by the authors). The first child ever observed was reported by our group in 2001. He had a unilateral disease.<sup>2</sup> In 2002, a second child with bilateral disease was documented in the Netherlands.<sup>3</sup> In 2003, five additional cases were reported from the Netherlands (two with bilateral disease and three with unilateral disease). In this paper, an estimated relative risk of 4.9 to 7.2 for an IVF born child

in the Netherlands to develop retinoblastoma was surmised.<sup>4</sup>

The issue of the possible association of assisted reproductive techniques (ART) with an increased risk of retinoblastoma has raised great concern worldwide. The interest of this association is highlighted by the fact that the expression of retinoblastoma in childhood is influenced by epigenetics—a regulatory mechanism not involving DNA sequence which could be affected by the various ART techniques.

In recent years, tens of thousands of children were born after ART. However, not one single case of retinoblastoma was observed until 2001. The possible reasons for this phenomenon were discussed.<sup>5</sup> Awareness regarding the occurrence of retinoblastoma in ART born children sparked by our original observation of the first case in 2001 has probably been a trigger for the unveiling of additional cases. Therefore, more cases are to be expected in the near future.

Whether the increased number of observed cases indicates that ART born babies have a higher risk of developing retinoblastoma remains to be carefully investigated. None the less, a thorough prospective assessment of the possible association between ART and retinoblastoma is mandatory. Ongoing multi-centre and multinational control studies will hopefully provide the needed answers to this "thorny" but most crucial aspect of ART. Till then, accurate accounting of previous observations is, of course, a key factor for a better insight into these issues.

Correspondence to: D BenEzra, Hadassah University Hospital, POB 12000, Jerusalem 91120, Israel; benezra@md.huji.ac.il

doi: 10.1136/bjo.2004.056739

Accepted for publication 20 August 2004

## References

- 1 **Lee I, Finger PT, Grifo JA, et al.** Retinoblastoma in a child conceived by in vitro fertilisation. *Br J Ophthalmol* 2004;**88**:1098–9.
- 2 **Anteby I, Cohen E, Anteby E, et al.** Ocular manifestations in children born after in-vitro fertilization. *Arch Ophthalmol* 2001;**119**:1525–9.
- 3 **Cruysberg JR, Moll AC, Imhof SM.** Bilateral sporadic retinoblastoma in a child born after in vitro fertilization. *Arch Ophthalmol* 2002;**120**:1773.
- 4 **Moll AC, Imhof SM, Cruysberg JR, et al.** Incidence of retinoblastoma in children born after in-vitro fertilization. *Lancet* 2003;**361**:309–10.
- 5 **BenEzra D.** In-vitro fertilization and retinoblastoma. Commentary. *Lancet* 2003;**361**:273–4.

## NOTICES

### Worldwide clinical trials for new technique for early detection of eye disease

A unique new non-invasive technique for high resolution optical imaging of the eye is

receiving global acclaim. By combining two high-resolution imaging technologies, the new technique provides doctors with 3-D images of the retina, macula and the optic nerve.

For more information, contact the Media Office on 01227 823581/823100 or email MediaOffice@kent.ac.uk News releases can also be found at: <http://www.kent.ac.uk/news>

## Vision 2020 Priority Diseases

The latest (redesigned) issue of *Community Eye Health* (No 51) deals with the gaps between aims of Vision 2020 and how far we are still from them, especially in Africa. For further information please contact: Journal of Community Eye Health, International Resource Centre, International Centre for Eye Health, Department of Infectious and Tropical Diseases, London School of Hygiene and Tropical Medicine, Keppel Street, London WC1E 7HT, UK (tel: +44 (0)20 7612 7964; email: Anita.Shah@lshtm.ac.uk; online edition: [www.jceh.co.uk](http://www.jceh.co.uk)). Annual subscription (4 issues) UKE28/US\$45. Free to developing country applicants.

## British Oculoplastic Surgery Society

Call for papers for the 5<sup>th</sup> annual meeting of the BOPSS to be held on 15 and 16 May 2005 at The Belfry, Birmingham. The abstract submission deadline is 4 February 2005, and abstracts can be submitted online at [www.bopss.org](http://www.bopss.org).

## EVER 2005 meeting

This will take place on 5–8 October 2005 in Vilamoura, Portugal. Further details: Christy Lacroix, EVER Secretary, Kapucijnenvoer 33, B-3000 Leuven, Belgium (tel: +32 (0)16 233 849; fax: +32 (0)16 234 097; email: [ever@skynet.be](mailto:ever@skynet.be)).

## CORRECTIONS

doi: 10.1136/bjo.2004.020305corr1

In the paper titled Prospective case control study on genetic association of apolipoprotein ε2 with intraocular pressure (*Br J Ophthalmol* 2004;**88**:581–2), the authors have been listed incorrectly. The correct listing is A Jünemann, S Bleich, U Reulbach, K Henkel, N Wakili, G Beck, B Rautenstrauss, C Mardin, G O H Naumann, A Reis, J Kornhuber. The journal apologises for this error.

doi: 10.1136/bjo.2004.049767corr1

In the letter titled Bilateral decompression retinopathy after orbital decompression surgery (*Br J Ophthalmol* 2004;**88**:1605–6), the authors have been listed incorrectly. The correct listing is G J Ben Simon, R A Goldberg, J D McCann. The journal apologises for this error.