

## EXTENDED REPORT

## Chorioretinal temperature monitoring during transpupillary thermotherapy for choroidal neovascularisation

S Miura, H Nishiwaki, Y Ieki, Y Hirata, Y Honda, Y Sugino, Y Okazaki

*Br J Ophthalmol* 2005;89:475-479. doi: 10.1136/bjo.2004.049189

See end of article for authors' affiliations

Correspondence to: Hirokazu Nishiwaki, MD, Department of Ophthalmology and Visual Sciences, Kyoto University Graduate School of Medicine, 54 Shogoinkawahara-cho, Sakyo-ku, Kyoto 606-8507, Japan; nishiwak@kuhp.kyoto-u.ac.jp

Accepted for publication 1 September 2004

**Aims:** To investigate the difference in temperature rise between normal choroid and choroidal revascularisation (CNV) during transpupillary thermotherapy (TTT) and the relation between laser spot size and power in the rat fundus.

**Methods:** A modified slit lamp, which was installed with two laser wavelengths (490 nm for illumination and fluorescein excitation and 810 nm for hyperthermia), was developed for TTT and temperature monitoring. Temperature rise during TTT was monitored by observing fluorescence released from thermosensitive liposomes encapsulating carboxyfluorescein. Two types of liposomes were prepared; their phase transition temperatures were 40°C and 46°C, respectively. Laser power settings required to observe fluorescence released from 46°C liposome in normal choroid or CNV were compared. Next, the power settings with 0.5 mm and 0.25 mm spot sizes were compared following administration of 40°C liposome or 46°C liposome.

**Results:** The minimum power values when release from 46°C liposome was observed showed a significant difference in distribution of power values between normal choroid and CNV. CNV required significantly higher power than normal choroid. With 40°C liposome, the power was 9.7 (1.9) mW (mean (SD)) at a spot size of 0.25 mm, and 12.1 (1.6) mW at 0.5 mm, respectively. When using 46°C liposome, the power setting was 10.2 (1.2) mW at a spot size of 0.25 mm, and 14.6 (2.2) mW at 0.5 mm, respectively.

**Conclusions:** CNV demonstrated varying heat conduction, compared with normal choroid. Laser power required to raise the temperature should not necessarily be doubled, even when the spot size is doubled. Close attention should be given to the selection of power settings when performing TTT for CNV.

Age related macular degeneration is the leading cause of central visual loss in patients older than 50 years of age in the United States.<sup>1, 2</sup> The majority of eyes have severe visual loss as a result of choroidal neovascularisation (CNV), which is the formation of new blood vessels either between the retinal pigment epithelium (RPE) and Bruch's membrane or RPE and subretinal space. The only proved effective treatment is laser photocoagulation. The Macular Photocoagulation Study<sup>3</sup> demonstrated that treatment of well defined subfoveal CNV was beneficial, but most patients experienced an immediate decline in vision because of damage to the overlying sensory retina.

Transpupillary thermotherapy (TTT) has recently emerged as an advance for treating occult choroidal neovascularisation (CNV).<sup>4</sup> Initially used for the treatment of choroidal melanoma,<sup>5</sup> TTT is a technique in which heat is delivered to the choroid and retinal pigment epithelium (RPE) through the pupil using a modified laser diode (usually 810 nm) delivered from the ophthalmic slit lamp. TTT for CNV is a subthreshold photocoagulation procedure. If retinal whitening is observed, treatment should be stopped, because the goal of treatment is to deliver laser energy to CNV while sparing overlying retina. In contrast with conventional laser photocoagulation,<sup>6</sup> in which an estimated retinal temperature rise of 42°C occurs, the estimated retinal temperature elevation with TTT is calculated at approximately 10°C.<sup>7</sup> Reichel *et al* reported that, after TTT, 94% of CNV showed clinical or angiographic improvement and vision was stabilised or improved in 75%.<sup>8</sup> Miller-Rivero reported 26 of 30 eyes treated with TTT demonstrated a decrease in exudation after TTT.<sup>9</sup> These earlier reports have suggested that TTT can result in closure of subfoveal CNV, with relative sparing of the overlying neurosensory retina, compared to conventional laser photocoagulation therapy.

Mainster and Reichel recommended<sup>7</sup> (1) adjusting the power of TTT based on the fundus environment such as media clarity, degree of pigmentation, RPE atrophy, and choroidal circulation, and (2) doubling or halving the power if spot size is doubled or halved, because the power needed to produce a particular retinal temperature rise is roughly proportional to the diameter rather than the area of laser spot on the retina. In several clinical studies<sup>10, 11</sup> concerning TTT, treatment was thought to be performed according to the recommendations above. However, complications caused by overcoagulation have been reported. Although Matsumoto and Yuzama performed TTT in Japanese patients with 50% of power suggested by Reichel *et al*, excessive coagulation was observed in two of 48 eyes.<sup>10</sup> Auer and Herbolt reported that choroidal atrophy, which might be caused by overcoagulation was observed after TTT in five of 38 eyes.<sup>11</sup> These reports suggested that a uniform irradiation setting can lead to the difference in treatment effects among patients.

However, it may be difficult to deliver the appropriate irradiation of TTT in every case, because we have no way to measure chorioretinal temperature rise directly. Thermal dosimetry techniques, subretinal or episcleral microthermocouple,<sup>12</sup> and magnetic resonance imaging (MRI)<sup>13</sup> have been reported. At present, however, it may be difficult to apply these techniques to chorioretinal temperature monitoring, since the former is invasive and the latter requires specially adapted and initially costly devices. Because temperature monitoring devices are lacking, there has been no clinical

**Abbreviations:** CF, carboxyfluorescein; CNV, choroidal revascularisation; FAG, fluorescein angiography; LTM, liposomal temperature monitoring; MRI, magnetic resonance imaging; RPE, retinal pigment epithelium; T<sub>c</sub>, phase transition temperatures; TTT, transpupillary thermotherapy

examination of thermal features of CNV through subthreshold thermotherapy. Thus, appropriate treatment methods for TTT, such as power, duration, and spot size are still controversial.<sup>14–15</sup>

We previously introduced a non-invasive technique to monitor chorioretinal temperature during TTT, the liposomal temperature monitoring (LTM) technique.<sup>16</sup> Thermosensitive liposomes, vesicles of lipid bilayers, were shown to entrap carboxyfluorescein (CF) at a high concentration and release their contents when liposomes are warmed above their phase transition temperatures ( $T_c$ ). LTM consisted of applying TTT on the fundus following intravenous injections of thermosensitive liposomes encapsulating CF (CF liposomes). The background fluorescein intensity before and after TTT was low, because the circulating CF liposomes were invisible in the angiograms as a result of self quenching. However, once TTT was started and tissue temperature reached the  $T_c$  of injected liposomes, the excitation argon laser in the slit lamp brightly visualised the bolus of CF released from liposomes at the heated lesion. Temperature rise during TTT was monitored by observing the dye front from CF liposomes circulating in the heated tissues.

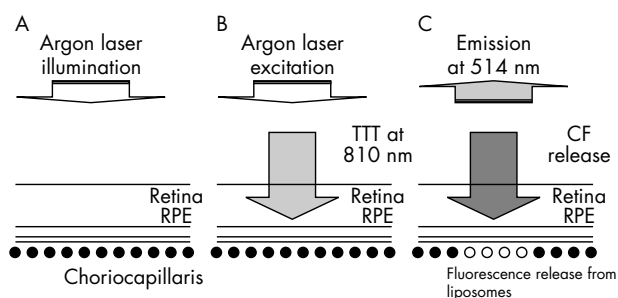
In this study, with LTM, we investigated features of temperature rise in the rat fundus during TTT. Firstly, we compared the TTT power required to raise tissue temperature to threshold temperature (46°C) between the normal choroid and CNV. Secondly, we investigated the relation between the spot size and the power with a rise in temperature.

## MATERIALS AND METHODS

### Animal anaesthesia and induction of CNV

Male Long-Evans (LE) rats, weighing 180–200 g each, were used for this study. Twenty four rats were used to perform TTT on normal choroid and 10 rats were used to perform TTT on CNV. The animals were treated in compliance with the ARVO statement for the use of animals in ophthalmic and vision research. The rats were anaesthetised with intramuscular ketamine (10 mg/kg) and xylazine (4 mg/kg). Topical 1% tropicamide and 2.5% phenylephrine hydrochloride were instilled for mydriasis during laser photocoagulation and TTT.

Dye laser irradiation (545 nm; argon dye laser model 920; Coherent Medical Laser, Canada) was delivered through a slit lamp (Carl Zeiss, Germany) with a hand held 90 dioptre lens (Nikon, Japan). A contact lens was used to retain corneal clarity throughout photocoagulation. Laser spots were placed separately, five burns in each eye, using a setting of 100  $\mu$ m in diameter, for 0.1 second duration, at 150 mW intensity.



**Figure 1** Principle of liposomal temperature monitoring (LTM). (A) Immediately after injection of CF liposome, an illuminating argon laser was delivered to the rat fundus. (B) TTT started. No release of fluorescent bolus was observed, when the temperature increase was below  $T_c$  in the heated lesion. (C) The TTT power setting was raised to an adequate value. When the temperature in the lesion was above the  $T_c$  of the injected liposome, the emitted fluorescent bolus was observed in and around the heated lesion.

CNV was evaluated on day 14 by ophthalmoscopy, fundus photography, and conventional fluorescein angiography.<sup>17</sup>

### CF liposome preparation

Dipalmitoylphosphatidylcholine (DPPC), dipalmitoylphosphatidylglycerol (DPPG), distearoylglycerophosphocholine (DSPC) (Genzyme, Liestal, Switzerland), and myristoylphosphatidylcholine (MPCC) (Avanti, Alavaster, AL, USA) were used without further purification. Liposomes were prepared by the method previously described.<sup>18–21</sup> Briefly, a 100 mM solution of 5,6-CF (Molecular Probes, Junction City, OR, USA) was mixed with the dried lipid film, and the mixture was subjected to five cycles of freezing and thawing. This process was followed by extrusion sizing in a thermobarrel extruder (Lipex Biomembranes, Vancouver, Canada) through a stack of two 25 mm, 0.2  $\mu$ m polycarbonate membranes (Millipore, Bedford, MA, USA) to yield large, unilamellar vesicles. Untrapped CF was removed through a Sephadex G-50 column (Pharmacia Biotech, Uppsala, Sweden).

Two types of liposomes were prepared as follows:

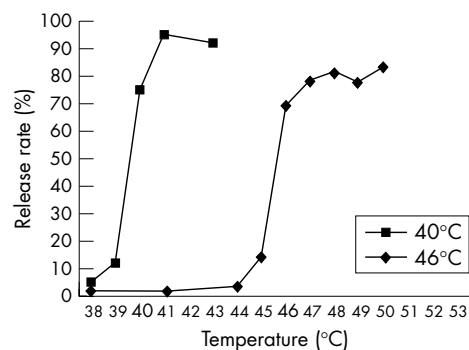
- (1) 40°C liposome ( $T_c = 40^\circ\text{C}$ ),  
DSPC:DPPC:DPPG:MPCC = 0:16:3:1 (mol/mol)
- (2) 46°C liposome ( $T_c = 46^\circ\text{C}$ ),  
DSPC:DPPC:DPPG:MPCC = 47:43:10:20 (mol/mol).

### Release yield versus suspension temperature in vitro

The amount of CF released was assayed by measuring fluorescence with a spectrofluorophotometer (Shimadzu, Kyoto, Japan) at 490 nm (excitation) and 514 nm (emission). A liposome suspension of 30  $\mu$ l was mixed with 3 ml of 50% human serum. Next, 0.1 ml of Triton X-100 (Sigma, St Louis, MO, USA), which disrupts the vesicles and releases the entrapped CF, was added to the control samples at room temperature. The samples were heated in the water bath at different temperatures for 1 minute. The percentage of CF release was calculated by comparing the fluorescent values of heated samples with total release of CF obtained after the addition of Triton X-100 to the control sample.

### Slit lamp modification for TTT

We modified a slit lamp for TTT, based on the commercial model of SL-10L (Topcon, Tokyo, Japan). The illumination of the slit lamp was switched to an argon laser at 490 nm (Novus 2000, Coherent, Palo Alto, CA, USA), which made it possible to perform the treatment while visualising and diagnosing the lesion with fluorescein angiography (FAG). In addition, a laser diode at 810 nm (F-System, Coherent, Palo Alto, CA, USA) was installed as aiming beam and to perform TTT. The zoom system allowed the spot diameter of 810 nm



**Figure 2** Temperature profiles of CF liposome. Note that CF release rate significantly increased at  $T_c$  of each liposome. Squares; 40°C liposome, diamonds, 46°C liposome.





CNV. At the start of TTT, a bright white circle that exhibited the heated lesion covered the centre of the CNV lesion. Patchy fluorescence, reported by Asrani *et al* as choriocapillary pattern,<sup>19, 20</sup> began to spread around the CNV and reached a plateau immediately after the start of TTT. It disappeared immediately after TTT ended.

#### Comparison of minimum TTT power setting for temperature rise between normal choroid and CNV

LTM were performed on normal choroid or CNV with a fixed spot size (0.5 mm) after injections of 46°C liposome suspension. Figure 4 shows the minimum power values when release of CF from 46°C liposome was observed. The p value of the F test was  $p < 0.00001$ , and showed a significant difference in distribution of power values between normal choroid and CNV. This difference in power distribution means power settings to warm CNV to a particular temperature should have a wide range, compared with normal choroid. In addition, CNV (mean 26.9 (SD 8.3) mW) required significantly higher power than normal choroid (12.5 (1.6) mW).

#### Investigation of relation between spot sizes and TTT power settings in temperature rise

LTM were performed on normal choroid with a 0.25 mm or 0.5 mm spot size, following 40°C liposome or 46°C liposome. Figure 5 shows the power values when release of CF from 40°C liposome and 46°C liposome, respectively, was observed. In LTM with 40°C liposome, the power was 9.7 (1.9) mW at a spot size of 0.25 mm, and 12.1 (1.6) mW at 0.5 mm. When using 46°C liposome, the power setting was 10.2 (1.2) mW at a spot size of 0.25 mm, and 14.6 (2.2) mW at 0.5 mm. These results indicated statistically significant differences in TTT power settings between the spot sizes of 0.25 mm and 0.5 mm.

### DISCUSSION

TTT was initially reported as a hyperthermic technique for treating choroidal melanoma.<sup>5, 22, 23</sup> Laser irradiation at 810 nm, which was minimally absorbed by ocular media, was delivered to RPE and tumour melanin. The absorbed laser power produced tissue necrosis within the tumour by causing a temperature rise to levels of approximately 65°C. The goal of therapy was to achieve a greyish-white colour change in the tumour at the end of TTT.

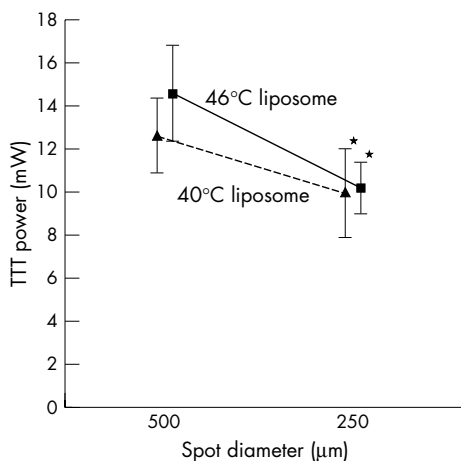
Recently, TTT was applied to the treatment of CNV as a subthreshold therapy to spare the overlying neurosensory

retina.<sup>4, 24–26</sup> The tissue temperature in TTT for CNV was calculated to be about 46–47°C,<sup>27</sup> which was lower than that for melanomas. In contrast with TTT for melanomas, TTT for CNV required no or barely visible colour change in the treated lesion to prevent thermal coagulation from occurring in the overlying retina.

Previously, we had introduced a non-invasive technique to monitor chorioretinal temperature during TTT—liposomal temperature monitoring (LTM).<sup>16</sup> LTM entailed the observation of fluorescence of released CF from thermosensitive liposomes with a modified slit lamp. CF liposomes released capsulated CF effectively when choroid or retina was heated to the levels of their phase transition temperatures (Tc). Released CF produced bright fluorescent images, which signalled to us that tissue temperature in the spot reached the Tc. On the other hand, LTM had some problem when applied to human eyes. Firstly, LTM required an intravenous injection of CF liposome suspension and a specially modified slit lamp. This complexity of procedure could make the application of LTM difficult. Secondly, LTM is indirect temperature monitoring. With LTM, we could just see that the temperature in the irradiated lesion reached or exceeded the Tc of the injected liposome; but we could not measure an arbitrary temperature. However, when we performed LTM, the TTT power setting gradually increased. Thus, the values presented here should be regarded as the best approximation to those values to heat the irradiated lesion to the target temperature (Tc). In addition, our previous report with LTM was consistent with the calculated model.<sup>16</sup> Thus, LTM was considered to be a reliable method.

In this study with LTM, we observed two findings concerning temperature rise during TTT for normal choroid or CNV. The first finding was that CNV demonstrated varying heat conduction compared with normal choroid. In contrast with TTT on the normal choroid, the power settings to warm CNV varied individually. We speculated that the form or thickness of CNV, damage to the RPE, or existence of subretinal fluid resulted in a variation of heat conduction in experimental CNV. This feature of varying heat conduction could be applied to clinical CNV, since clinical CNV is often accompanied by subretinal haemorrhage, exudative retinal detachment, retinal oedema, or RPE atrophy. Haemoglobin absorbs visible and infrared irradiation less effectively than melanin.<sup>28</sup> However, thick haemorrhage can generate significant temperature elevations and prevent optical irradiation from reaching underlying CNV. Subretinal exudation and RPE atrophy would also cause variations in temperature rise across the TTT field. Thus, our results suggested that it would be difficult to obtain an appropriate temperature rise in all patients with TTT under uniform power settings, and it could be necessary to individualise appropriate power settings for each CNV by using a temperature monitoring technique such as LTM.

The second finding was that the laser power required to raise temperature should not necessarily be doubled, even when the spot size is doubled. Theoretically, if the spot size were doubled, doubled power would be necessary to raise temperature.<sup>29</sup> However, in the experiment with LTM, when the spot size was doubled we observed released fluorescence from 40°C or 46°C liposome with less power than the theoretical values. We considered two reasons why this result was obtained. Firstly, a small cooling effect by choroidal blood flow<sup>30, 31</sup> might occur in the centre of the spot. Because there were low temperature (that is, body temperature) areas near the peripheral part of the spot, the blood flow of choriocapillaris from these low temperature areas could easily cool the peripheral part. However, since the blood flow into the centre had been already heated in the periphery, the temperature in the centre might easily



**Figure 5** The power values at release of CF from 40°C liposome (triangles) and 46°C liposome (squares) was observed ( $*p < 0.05$ ).

increase. As a result, the centre might be heated by a power that was less than the theoretical value even when the spot size was increased. Secondly, there would be a laser density gradient in the spot. In other words, laser density would decrease more in the periphery, further away from the centre. Under these circumstances, when the spot size was doubled, the target temperature (that is, phase transition temperature of liposome) could be achieved with a power that was less than the calculated one because the centre of the spot, with higher laser density, was heated effectively. This might result in observations of CF released from liposome with a lower power setting than expected.

In conclusion, our results suggested that close attention should be given to the selection of power settings when performing TTT for CNV to accommodate individual difference in temperature rise in CNV. We should adjust TTT power settings to the individual cases. In addition, we should also pay close attention to TTT power settings when we change spot size. Our results suggested that we should not lightly increase the power because appropriate laser power for TTT is not proportional to the spot size.

#### Authors' affiliations

S Miura, H Nishiwaki, Y Ieki, Y Hirata, Y Honda, Department of Ophthalmology and Visual Sciences, Kyoto University Graduate School of Medicine, Kyoto, Japan

Y Sugino, Y Okazaki, Topcon Corporation, Tokyo, Japan

Grant support: Supported by a grant in aid for Scientific Research from the Ministry of Education, Science, and Culture.

Proprietary interest category: None.

#### REFERENCES

- Freund KB, Yannuzzi LA, Sorenson JA. Age-related macular degeneration and choroidal neovascularization. *Am J Ophthalmol* 1993;**115**:786–91.
- Ferris FL, Fine SL, Hyman L. Age-related macular degeneration and blindness due to neovascular maculopathy. *Arch Ophthalmol* 1984;**102**:1640–2.
- Macular Photocoagulation Study Group. Age-related macular degeneration. The Macular Photocoagulation Study. *Am J Ophthalmol* 1984;**98**:376–7.
- Newsom RS, McAlister JC, Saeed M, et al. Transpupillary thermotherapy (TTT) for the treatment of choroidal neovascularisation. *Br J Ophthalmol* 2001;**85**:173–8.
- Keunen JE, Journee-de-Korver JG, Oosterhuis JA. Transpupillary thermotherapy of choroidal melanoma with or without brachytherapy: a dilemma. *Br J Ophthalmol* 1999;**83**:1212–13.
- Mainster MA. Decreasing retinal photocoagulation damage: principles and techniques. *Sem Ophthalmol* 1999;**14**:200–9.
- Mainster MA, Reichel E. Transpupillary thermotherapy for age-related macular degeneration: long-pulse photocoagulation, apoptosis, and heat shock proteins. *Ophthalmic Surg Lasers* 2001;**31**:359–73.
- Reichel E, Berrocal AM, Ip M, et al. Transpupillary thermotherapy of occult subfoveal choroidal neovascularization in patients with age-related macular degeneration. *Ophthalmology* 1999;**106**:1908–14.
- Miller-Rivero. Transpupillary thermotherapy in the treatment of occult and classic choroidal neovascularization. *Abstract ARVO Invest Ophthalmol Vis Sci* 2001;**41**:S179.
- Matsumoto Y, Yuzawa M. Short-term evaluation and angiography findings in transpupillary thermotherapy. *Folia Ophthalmol Jpn* 2003;**54**:578–83.
- Auer C, Herbart C. Transpupillary thermotherapy for occult subfoveal neovessels in age-related macular degeneration: importance of patient pigmentation for the determination of laser settings. *Klin Monatsbl Augenheilkd* 2002;**219**:250–3.
- Cain CP, Welch AJ. Measured and predicted laser-induced temperature rises in the rabbit fundus. *Invest Ophthalmol* 1974;**13**:60–70.
- Stollberger R, Ascher PW, Huber D, et al. Temperature monitoring of interstitial thermal tissue coagulation using MR phase images. *J Magn Reson Imaging* 1998;**8**:188–96.
- Thach A, Dugel PU, Sneed SR, et al. Large-spot size transpupillary thermotherapy for the treatment of occult choroidal neovascularization associated with age-related macular degeneration. *Arch Ophthalmol* 2002;**121**:817–20.
- Connolly BP, Regillo CD, Eagle RC Jr, et al. The histopathologic effects of transpupillary thermotherapy in human eyes. *Ophthalmology* 2003;**110**:415–20.
- Miura S, Nishiwaki H, Ieki Y, et al. Noninvasive technique for monitoring chorioretinal temperature during transpupillary thermotherapy with a thermosensitive liposome. *Invest Ophthalmol Vis Sci* 2002;**44**:2717–21.
- Kamizuru H, Kimura H, Yasukawa T, et al. Monoclonal antibody-mediated drug targeting to choroidal neovascularization in the rat. *Invest Ophthalmol Vis Sci* 2001;**42**:2664–72.
- Asrani S, Zou S, D'Anna S, et al. Noninvasive visualization of blood flow in the choriocapillaris of the rat. *Invest Ophthalmol Vis Sci* 1996;**37**:312–17.
- Asrani S, Zou S, D'Anna S, et al. Selective visualization of choroidal neovascular membranes. *Invest Ophthalmol Vis Sci* 1996;**37**:1642–50.
- Kiryu J, Shahidi M, Mori MT, et al. Noninvasive visualization of the choriocapillaris and its dynamic filling. *Invest Ophthalmol Vis Sci* 1994;**35**:3724–31.
- Hirata Y, Nishiwaki H, Miura S, et al. In vivo analysis of choroidal circulation by continuous laser-targeted angiography in the rat. *Invest Ophthalmol Vis Sci* 2003;**44**:3103–9.
- Robertson DM, Buettner H, Bennett SR. Transpupillary thermotherapy as primary treatment for small choroidal melanomas. *Arch Ophthalmol* 1999;**117**:1512–19.
- Ip M, Kroll A, Reichel E. Transpupillary thermotherapy. *Sem Ophthalmol* 1999;**14**:11–18.
- Kaga T, Fonseca RA, Dantas MA, et al. Transient appearance of classic choroidal neovascularization after transpupillary thermotherapy for occult choroidal neovascularization. *Retina* 2001;**21**:172–3.
- Rogers AH, Reichel E. Transpupillary thermotherapy of subfoveal occult choroidal neovascularization. *Curr Opin Ophthalmol* 2001;**12**:212–15.
- Gillies MC, Sarks JP, Beaumont PE, et al. Treatment of choroidal neovascularisation in age-related macular degeneration with interferon alpha-2a and alpha-2b. *Br J Ophthalmol* 1993;**77**:759–65.
- Mainster MA, White TJ, Tips JH, et al. Retinal-temperature increases produced by intense light sources. *J Opt Soc Am* 1970;**60**:264–70.
- Mainster MA. Wavelength selection in macular photocoagulation. Tissue optics, thermal effects, and laser systems. *Ophthalmology* 1986;**93**:952–8.
- Mainster MA, Allen RG. Spectral dependence of retinal damage produced by intense light sources. *J Opt Soc Am* 1970;**60**:848–55.
- Parver LM, Auken C, Carpenter DO. Choroidal blood flow as a heat dissipating mechanism in the macula. *Am J Ophthalmol* 1980;**89**:641–6.
- White TJ, Mainster MA, Tips JH, et al. Chorioretinal thermal behavior. *Bull Math Biophys* 1970;**32**:315–22.