

PostScript

LETTERS

Primary nasolacrimal duct malignant mucosal melanoma

Primary nasolacrimal duct malignancy is rare. Only a few tumours from this location including lymphoma,¹ Kaposi's sarcoma,² adenocarcinoma,³ angiofibroma,⁴ and squamous cell carcinoma.⁵

Mucosal melanoma represents 1–2% of all melanomas,⁶ with 25–50% in the head and neck—that is, upper respiratory tract, oral cavity, and pharynx. Other sites include urinary, female genital, and ano-rectal tracts. These tumours are uncommon, present in the fifth to eighth decades, have slight male preponderance and are more common in darker skinned individuals. Cutaneous melanoma presents two decades earlier and is more common in white people and is associated with sun exposure.

Case report

A 41 year old Asian male presented to the oculoplastic service with a 3 month history of right sided intermittent bloody tears and epistaxis. He described right simple epiphora for at least 2 years treated with a three snip procedure. Probing the right nasolacrimal system confirmed normal canaliculi and easy entry of the probe into the lacrimal sac. Irrigation demonstrated complete nasolacrimal duct block and reflux of dark bloody tears. Nasal endoscopy (rigid Hopkins nasal endoscope) revealed a greyish mass emerging from the lower end of the nasolacrimal duct into the inferior meatus (fig 1).

Magnetic resonance imaging (MRI) and computed tomography (CT) scans (fig 2) demonstrated dilation of the entire length of the nasolacrimal bony canal with a soft tissue mass occupying the lumen of the nasolacrimal duct. The mass was invading the osteomeatal complex, extending into the anterior ethmoidal sinus, causing obstruction to drainage of both maxillary and frontal sinuses.

A transnasal incisional biopsy of the inferior meatus lesion was performed under local anaesthetic. Histopathological analysis of the biopsy showed sheets of epithelioid cells with prominent nucleoli and vesicular cells on a routine haematoxylin and eosin

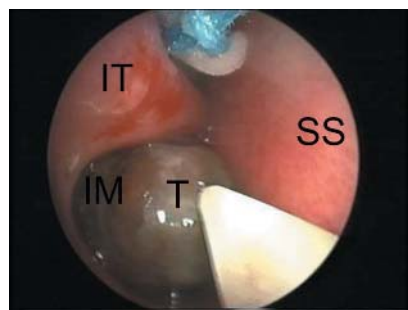


Figure 1 Endonasal view of right nasal cavity. IT, inferior turbinate; SS, septal spur; IM, inferior meatus; T, tumour.

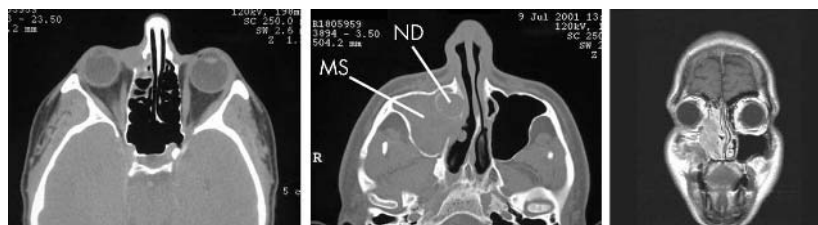


Figure 2 Imaging. (Left) CT scan head, axial view. Lesion in region of lacrimal sac. (Middle) CT scan head, axial view. ND, dilated nasolacrimal duct; with fluid in maxillary sinus (MS). (Right) MRI scan head, coronal view. Soft tissue mass extending from lacrimal sac, via nasolacrimal duct, to inferior meatus.



Figure 3 Histopathology slides. (A) High power 400 \times . Haematoxylin and eosin stain showing epithelioid cells and vesicular cells and pigment. (B) Medium power 200 \times . HMB-45 stain, positive for melanocytes. (C) High power 400 \times . Strongly positive S-100 protein immunohistochemical stain.

stain (fig 3). Although the lesion was pale, pigment was visible on the haematoxylin and eosin stain, suggestive of melanoma. Immunohistochemical studies were positive for immunological markers HMB45 and S-100 protein, confirming a diagnosis of melanoma.

No regional lymphadenopathy was present and PET (positron emission tomography) scan excluded the presence of metastases.

Wide local cranio-facial-orbital resection of the tumour was performed, via a lateral rhinotomy approach (fig 4). The nasolacrimal duct, part of the lateral wall of the nose, the lacrimal sac, distal upper and lower canaliculi, and inferomedial orbital fat were excised. Tumour extended into the maxilla but not into the lacrimal sac. Peroperative frozen sections from the excision margins, including orbital fat, demonstrated clearance of tumour. This allowed preservation of the eye.

Adjunctive therapy was given to limit local recurrence and distant spread. The patient received 20 sessions of radiotherapy (50 Gy) to the right maxillary antrum, and also immunological therapy (vaccination with autologous dendritic cells pulsed with allo-

genic tumour lysate, and whole body hyperthermia accompanied by low dose interferon).

Three years after presentation there was no local recurrence of tumour. Unfortunately, the patient developed bone pain and CT scan revealed metastatic spread to the right acetabulum and T8, T9, and T11 vertebrae with localised spinal cord compression. He underwent radiotherapy to the right acetabulum and spine. The patient died approximately 6 months later.

Comment

Nasolacrimal duct primary mucosal melanoma is previously unreported. The closest relations are lacrimal sac melanoma (5% of lacrimal sac tumours)^{7,8} and sinonasal mucosal melanoma (5% of all sinonasal malignancy).^{6,9}

Lacrimal sac melanoma can present with epiphora, bloody tears, and epistaxis. Sinonasal melanoma can present with nasal obstruction and epistaxis. Orbital extension causes proptosis and diplopia. Both lacrimal sac melanoma and sinonasal melanoma are insidious in onset with poor visibility leading to late presentation.

Standard treatment of primary sinonasal melanoma is radical wide local surgical excision. Local recurrence can occur and the very vascular nature of mucosal tissue makes regional and distant metastases common, often accompanying late presentation. Post-surgical radiotherapy may prevent local recurrence, but is unlikely to prevent distant metastases.¹⁰ Other adjunctive treatments are not clinically proved to be beneficial. Chemotherapy has no positive effect, and newer immunological treatments are still under investigation.

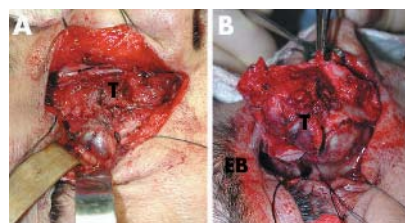


Figure 4 Wide local excision of malignant mucosal melanoma. T, tumour; EB, eyebrow.

Sinonasal mucosal melanoma has a high mortality rate, with 5 year survival between 10–50%.⁶ Lacrimal sac melanoma has a similar prognosis.^{7,8}

This case demonstrates the importance of thorough clinical examination (including nasal endoscopy) and imaging in patients presenting with epiphora, bloody tears, and/or epistaxis. Delay in detection and treatment may be fatal.

A M Lewis

Western Eye Hospital, London, UK

P M Clarke

Charing Cross Hospital and Royal Marsden Hospital, London, UK

J M Olver

Western Eye Hospital, London, UK

Correspondence to: J M Olver, Oculoplastic and Orbital Service, The Western Eye Hospital, Marylebone Road London NW1 5YE, UK; janeolver@aol.com

doi: 10.1136/bjo.2005.073239
Accepted for publication 24 July 2005

Competing interests: none declared.

References

- 1 Yip CC, Bartley GB, Haberman TM, et al. Involvement of the lacrimal drainage system by leukaemia or lymphoma. *Ophthalmol Plast Reconstr Surg* 2002;18:242–6.
- 2 Khan MA, Dhillon B. Epiphora due to Kaposi's sarcoma of the nasolacrimal duct. *Br J Ophthalmol* 1999;83:501–2.
- 3 Baredes S, Ludwin DB, Troublefield YL, et al. Adenocarcinoma ex-pleomorphic adenoma of the lacrimal sac and nasolacrimal duct: a case report. *Laryngoscope* 2003;113:940–2.
- 4 Yazici B, Setzen G, Meyer DR, et al. Giant cell angiofibroma of the nasolacrimal duct. *Ophthalmol Plast Reconstr Surg* 2001;17:202–6.
- 5 Spira R, Mondshine R. Demonstration of nasolacrimal duct carcinoma by computed tomography. *Ophthalmol Plast Reconstr Surg* 1986;2:159–61.
- 6 Batsakis JG, Suarez P. Mucosal melanomas: a review. *Adv Anat Pathol* 2000;7:167–80.
- 7 Pe'er JJ, Stefansyn M, Hidayat AA. Nonepithelial tumours of the lacrimal sac. *Am J Ophthalmol* 1994;118:650–8.
- 8 Stefansyn MA, Hidayat AA, Pe'er JJ, et al. Lacrimal sac tumours. *Ophthalmic Plast Reconstr Surg* 1994;10:169–84.
- 9 Lengyel E, Gilde K, Remenar E, et al. Malignant mucosal melanoma of the head and neck—a review. *Pathol Oncol Res* 2003;9:7–12.
- 10 Owens JM, Roberts DB, Myers JN. The role of postoperative adjuvant radiation therapy in the treatment of mucosal melanomas of the head and neck region. *Arch Otolaryngol Head Neck Surg* 2003;129:864–8.

Glycosylation type Ic disorder: idiopathic intracranial hypertension and retinal degeneration

We report a young woman with type Ic congenital disorder of glycosylation (CDG) with new clinical features of idiopathic intracranial hypertension, retinal degeneration, and novel mutations of ALG6. Patients with known or suspected CDG should receive a full ophthalmic examination including dilated fundus examination and electroretinography.

CDG is a rare group of autosomal recessive metabolic disorders. The two major subgroups are type I, caused by dysfunction of glycosylated protein assembly, and type II, caused by abnormal processing of glycosylated protein end products after assembly.¹ Patients with type Ic (OMIM #603147) have mental retardation, axial hypotonia, very low factor XI, and seizures; the gene defect in α 1,3-glucosyltransferase (human homologue of ALG6; OMIM *604566) encodes an enzyme that catalyses the transfer of the first glucose residue to the lipid linked oligosaccharide precursor for N-linked glycosylation. The reported ophthalmic manifestations of type I CDG are summarised in table I. We report a case of type Ic congenital disorder of glycosylation with new clinical features of idiopathic intracranial hypertension, retinal degeneration and novel mutations of ALG6.

Case report

Our patient, with non-consanguineous parents, was noted at birth to have incomplete digits on her hands and feet. She had episodes of apnoea early in life and the onset of seizures at age 20 months. Delayed physical and developmental milestones were evident early. Levels of follicle stimulating hormone and luteinising hormone were low and a diagnosis of polycystic ovarian disease was made. She underwent esotropia surgery at age 4 years and at 19 years developed thrombosis of the superficial femoral vein. Coagulation factor studies revealed very low factor XI levels. Isoelectric focusing of serum transferrin was suggestive of a congenital disorder of glycosylation. Sequencing of the ALG6 gene showed a novel three base deletion (897–899 delATT) and an intronic splice site mutation (IVS7+2T>G).²

The patient was obese without signs of abnormal fat distribution. She blinked to light and no strabismus was identified by corneal light reflex. Further ocular examination was not feasible. On examination under anaesthesia at age 20 years, the anterior segment was normal. Dilated ophthalmoscopy showed bilateral optic nerve pallor with elevation of each nerve, diffuse retinal pigment epithelial granularity most notable in the macula, and attenuated retinal vessels (fig 1).

Electroretinography revealed prolonged implicit times on scotopic and photopic functions. Because of the elevated optic nerve heads, head magnetic resonance imaging was performed and was normal; lumbar puncture revealed an elevated opening pressure of 350 mm H₂O (nl 70–180 mm H₂O), a glucose of 50 mg/dl (nl 50–75 mg/dl), and a protein of 44 mg/dl (nl 15–45 mg/dl) without white blood cells. A diagnosis of idiopathic intracranial hypertension was made.

Comment

Isoelectric focusing of serum transferrin is the most common screening technique for

types I and II CDG.¹ Many congenital disorders of glycosylation have been identified based on mutational and enzyme analyses. Type I congenital disorders of glycosylation are caused by reduced functions of the genes for the assembly and processing pathways of N-glycosylation; a decrease in anodal fractions and an increase of disialo-transferrin and asialotransferrin are suggestive of the diagnosis.

Ophthalmic features of the most common congenital disorder of glycosylation, type Ia (OMIM #212065) include myopia, attenuated retinal vessels, bone spicules, esotropia, and nyctalopia³; this disease subtype is caused by a deficiency of phosphomannomutase (OMIM #212065) encoded by phosphomannomutase-2 (PMM2; OMIM *601785) gene. In CDG type Ic, much less common, a homozygous amino acid substitution, A333V substitution, in the gene encoding α 1,3-glucosyltransferase is the most common mutation.⁴ There is no known biochemical link between CDG and idiopathic intracranial hypertension; the association in our patient may be coincidental. Grunwald and colleagues⁵ found strabismus to be present in all eight patients with CDG type Ic; neither idiopathic intracranial hypertension nor retinal abnormalities were reported.

The developmental delay evident in our patient was severe. She possessed simple communication skills limiting her ability to complain of visual changes or symptoms of intracranial hypertension. No specific clinical presentation has been identified for the CDG group of diseases. Failure to thrive, unexplained seizures, hypotonia, and developmental delays are all frequently present.

In conclusion, we report an adult patient with CDG type Ic, confirmed by identification of mutations in the ALG6 gene, and describe new systemic and ocular features including idiopathic intracranial hypertension, optic

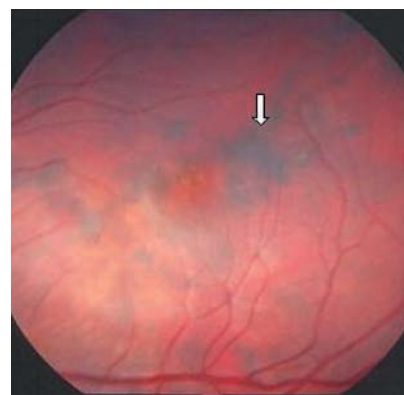

Figure 1 Left fundus showing attenuated vessels with retinal pigment cell granularity of the macula (white arrow).

Table 1 Reported ophthalmic manifestations in type I congenital disorder of glycosylation (CDG)

	CDG Ia	CDG Ib	CDG Ic
Strabismus	+	–	+
Retinopathy	+	–	–
Optic atrophy	+	–	–

atrophy, and a retinal dystrophy with abnormal electroretinography.

M Y Kahook, N Mandava, J B Bateman
Rocky Mountain Lions Eye Institute, Department of
Ophthalmology, Denver, CO, USA

J A Thomas, J B Bateman
Rocky Mountain Lions Eye Institute, Department of
Pediatrics, Denver, CO, USA

Correspondence to: Malik Y Kahook, MD, 589
Franklin Blvd, Freedom, PA 15042, USA; malik.
kahook@gmail.com

This is an institutional review board (IRB) exempt
single case report with no identifiable patient
information.

doi: 10.1136/bjo.2005.080648

Accepted for publication 1 August 2005

Supported in part by NEI Grant EY 08282 (JBB).

The authors have no interests or disclosures to report.

References

- 1 Jaeken J. Congenital disorders of glycosylation (CDG): it's all in it! *J Inherit Metab Dis* 2003;**26**:99–118.
- 2 Sun L, Eklund E, Van Hove J, et al. Clinical and molecular characterization of the first adult congenital disorder of glycosylation (CDG) type Ic patient. *Am J Med Genet* (accepted).
- 3 Jensen H, Kjaergaard S, Klie F, et al. Ophthalmic manifestations of congenital disorder of glycosylation type 1a. *Ophthalmol Genet* 2003;**24**:81–8.
- 4 Imbach T, Burda P, Kuhnert P, et al. A mutation in the human ortholog of the *Saccharomyces cerevisiae* ALG6 gene causes carbohydrate-deficient glycoprotein syndrome type-Ic. *Proc Natl Acad Sci USA* 1999;**96**:6982–7.
- 5 Grunewald S, Imbach T, Huijben K, et al. Clinical and biochemical characteristics of congenital disorder of glycosylation type Ic, the first recognized endoplasmic reticulum defect in N-glycan synthesis. *Ann Neurol* 2000;**47**:776–81.

Woodhouse Sakati syndrome associated with bilateral keratoconus

Keratoconus is a non-inflammatory degenerative corneal disease characterised by a localised region of stromal thinning spatially associated with a cone-shaped deformation of the surface. It is most commonly an isolated sporadic condition.¹ Recent reports demonstrate genetic mapping to chromosomes 16q, 21q, and 18p, as well as association of HLA-A26, B40, and DR 9.^{2,3} Keratoconus has been reported in clinical contexts with 36 other multisystem disorders.^{1,2} We describe the first two cases of keratoconus in association with Woodhouse Sakati syndrome.

Case report

Two sisters (aged 14 years and 18 years) presented with history of bilateral progressive loss of vision over 8 years. Progeny of a first degree consanguineous marriage, they were the only members in the family of six siblings with a diagnosis of Woodhouse Sakati syndrome. Both sisters exhibited variable manifestations of the syndrome including hypogonadism, primary amenorrhoea, hypothyroidism, electrocardiographic abnormalities, and dysmorphic features. The elder sister also had a mild degree of mental retardation. None of their siblings or parents

had eye complaints but a maternal aunt's daughter had bilateral keratoconus.

Ophthalmic evaluation of the elder sister revealed uncorrected visual acuity (UCVA) of 20/200 in both eyes. Her refraction was -19.0 -8.0×120 in the right eye and -9.0 -3.75×165 in the left eye. Spectacles improved only left eye vision slightly to 20/160. Slit lamp biomicroscopy showed bilateral central corneal protrusion and stromal thinning at the apex (fig 1A). Keratometry was 71.00/63.00 @ 68 in the right eye and 53.00/49.50 @ 135 in the left eye. Hard contact lens fitting failed and surgical intervention was not conducted.

Ophthalmic evaluation of the younger sister revealed UCVA of 20/40 in the right eye and 20/160 in the left eye, which improved to 20/80 with spectacles. Slit lamp biomicroscopy showed similar findings to her sister (fig 1B). Keratometry was 36.6 D/54.1 D @ 170 in the right eye and 49.2 D/56.6 D @ 48 in the left eye. She developed corneal hydrops in the left eye and contact lens fitting failed. Because of central corneal scarring and progressive deterioration of her left eye vision, she underwent penetrating keratoplasty (fig 1C). Fourteen months post-operatively, UCVA was 20/50, improving to 20/30 with pin hole.

Comment

Woodhouse Sakati syndrome (MIM 241080) is an extremely rare genetically determined autosomal recessive disorder. It was first described in two Saudi Arabian families,⁴ and later reported in a single Turkish family.⁵ Table 1 presents manifestations of the syndrome.^{4,5}

We report a new association in our two cases. Such concurrence of early keratoconus and the syndrome raises the possibility of a genetic linkage, although a chance association cannot be excluded.

On one hand, either chromosomal rearrangements such as chromosome 7, 11 translocation or genetically determined syndromes

such as this syndrome should be considered in cases where keratoconus is present during childhood.⁶ That may explain the early presentation of keratoconus in our cases. An additional factor is that keratoconus tends to be more prevalent and diagnosed at a younger age in Asians than in white people.³

On the other hand, familial keratoconus in our cases cannot be excluded because of the presence of keratoconus in a single relative and parental consanguinity. Positive family history has been reported in 6% to 10% of keratoconus cases and is suggested to be caused by autosomal dominant inheritance with incomplete penetrance.^{1,3}

To the best of our knowledge, this is the first report of bilateral keratoconus in association with Woodhouse Sakati syndrome. Ophthalmologists and endocrinologists should be aware that patients with this syndrome who complain of poor vision should be suspected of having keratoconus once other more common conditions are ruled out.

S A Al-Swailem, A A Al-Assiri, A A Al-Torbak

Anterior Segment Division, Department of
Ophthalmology, King Khaled Eye Specialist Hospital,
Riyadh, Kingdom of Saudi Arabia

Correspondence to: Samar A Al-Swailem, MD,
Anterior Segment Division, King Khaled Eye Specialist
Hospital, PO Box 7191, Riyadh 11462, Kingdom of
Saudi Arabia; angelofsa@yahoo.com

doi: 10.1136/bjo.2005.080101

Accepted for publication 12 August 2005

Competing interests: none declared

References

- 1 Rabinowitz YS. Keratoconus. *Surv Ophthalmol* 1998;**42**:297–319.
- 2 Tyynismaa H, Sistonen P, Tuupainen S, et al. A locus for autosomal dominant keratoconus: linkage to 16q22.3-q23.1 in Finnish families. *Invest Ophthalmol Vis Sci* 2002;**43**:3160–4.

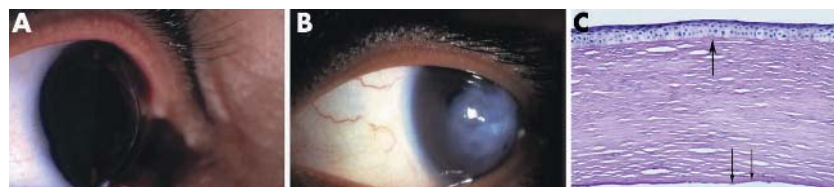

Figure 1 Features of keratoconus are seen. (A) Slit lamp biomicroscopy of the right cornea in the elder patient, showing advanced cone deformation and deep Descemet's membrane scarring. (B) Slit lamp biomicroscopy of the left cornea in the younger patient, showing dense central scarring following hydrops attack. (C) Histopathological section of left corneal button illustrating the fragmentation of Bowman's layer (large arrow) and large break in Descemet's membrane (small arrows) (periodic acid Schiff stain, $\times 200$).

Table 1 Variable manifestations in the nine reported patients with Woodhouse Sakati syndrome

Delayed psychomotor development
Variable degree of mental retardation (very frequent sign)
Alopecia (very frequent sign), spare/absent scalp and eyebrow hair (frequent sign), dysarthria
Dysmorphic features: high forehead, flat occiput, triangular face, prominent nasal root, hypertelorism, and down-slanting palpebral fissures.
Hyper/hypogonadotropic hypogonadism and late puberty (very frequent sign)
Sensorineural deafness (very frequent sign)
Electrocardiographic abnormalities and insulin dependent diabetes mellitus (very frequent signs)
No ocular manifestations

- 3 Adachi W, Mitsuishi Y, Terai K, *et al.* The association of HLA with young-onset keratoconus in Japan. *Am J Ophthalmol* 2002;133:557–9.
- 4 Woodhouse NJ, Sakati NA. A syndrome of hypogonadism, alopecia, diabetes mellitus, mental retardation, deafness and ECG abnormalities. *J Med Genet* 1983;20:216–19.
- 5 Gul D, Ozata M, Mergen H, *et al.* Woodhouse and Sakati syndrome (MIM 241080) report of a new patient. *Clin Dysmorph* 2000;9:123–5.
- 6 Morrison DA, Rosser EM, Claoue C. Keratoconus associated with a chromosome 7, 11 translocation. *Eye* 2001;15:556–7.

Retinal ischaemia in type 1 neurofibromatosis

Systemic occlusive arteriopathy associated with type 1 neurofibromatosis (NF-1) has been well described in the aortic and cerebral vasculature¹; however, it is poorly documented in the retinal vasculature with, to our knowledge, only three reported patients whose retinal vasculopathy was diagnosed at a later sequelae stage.^{2–4} We report the case of a young woman with NF-1 who presented with acute macular ischaemia combined with diffuse retinal arterial occlusive disease.

Case report

A 26 year old woman with NF-1 presented with a sudden painless loss of vision in her left eye. Visual acuity was counting fingers left eye and 20/20 right eye. NF-1 had previously been diagnosed on the basis of multiple café au lait spots, plexiform neurofibromas, and a paternal history of NF-1. Left fundus examination revealed confluent cottonwool spots in the perifoveal area, focal dilations and narrowings of retinal venules, and progressive enlargement of retinal arterioles towards the periphery. The right fundus showed only peripapillary myelinated nerve fibres (fig 1).

Fluorescein angiography (FA) of the left eye showed no delayed perfusion in the choriocapillaris or central retinal artery, but a delayed retinal arteriovenous filling time. It revealed occlusion of macular arterioles, retinal arteriovenous communications in the mid-periphery, and a relatively well perfused retinal periphery (fig 2).

Cerebral and cervical magnetic resonance imaging and colour Doppler ultrasonography showed no vascular flow abnormalities. Internal medical examination and laboratory results excluded other diseases associated with retinal microvasculopathies.

One month after the initial examination, all the cottonwool spots disappeared, and sheathing appeared in a few veins. FA showed worsening of the retinal arteriolar occlusions in the mid-periphery (fig 2). A panretinal photocoagulation was subsequently performed. At 2 year follow up, left visual acuity remained unchanged, and the patient did not exhibit any preretinal fibrovascular proliferation.

Comment

To our knowledge, only three cases of retinal vascular occlusion in patients with NF-1 have been previously reported. All cases were diagnosed at a later sequelae stage. Moadel *et al.*² and Kadoi *et al.*³ respectively, reported the cases of a child who presented with a unilateral amblyopia, and a young woman with a history of unilateral poor vision. They both presented with diffuse sheathing of retinal vessels, retinal arteriovenous

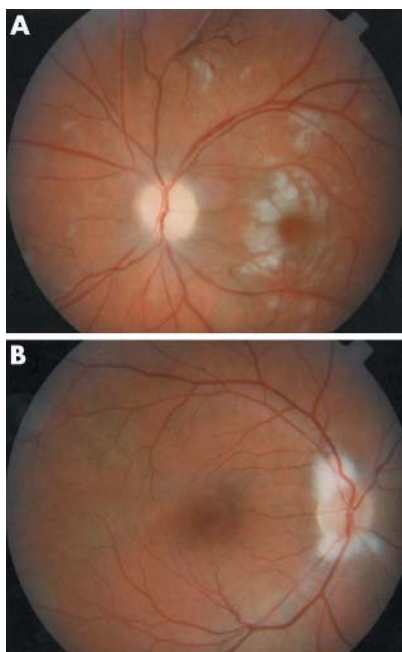


Figure 1 Fundus photographs of the left and the right eyes at presentation. (A) Colour fundus photograph of the left eye showing large confluent cottonwool spots in the perifoveal area. (B) Colour fundus photograph of the right eye showing peripapillary myelinated nerve fibres. (C) Red-free fundus photograph of the left eye. Upper periphery showing focal dilations and narrowings of retinal veinules, and capillary rarefaction. Retinal arteriovenous communications are also present (arrows).

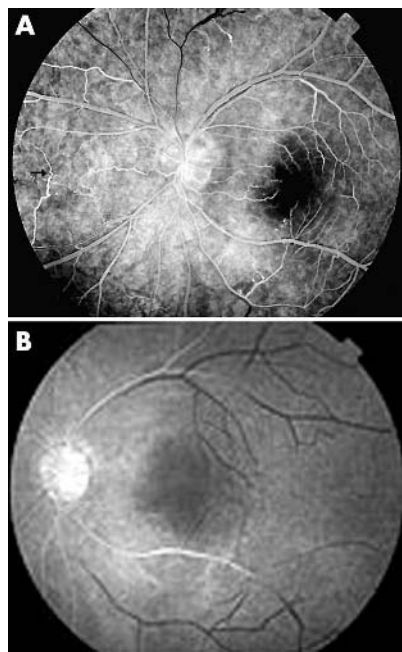


Figure 2 Fluorescein retinal angiography of the left eye, 40 seconds after dye injection, at presentation (A) and 1 month later (B). (A) Occlusion of macular arterioles and retinal arteriovenous communications are visible (black arrow). (B) Retinal arteriolar occlusions have worsened in the temporal periphery.

communications, and avascular peripheral retina with fibroglial proliferation. Thölen *et al.*⁴ described a young man whose routine eye examination showed narrowing of a superotemporal retinal arteriole with irregular diameter of the corresponding vein, fibroglial proliferation, and arteriovenous communications. These authors suggested the possibility of either a primary occlusion of a retinal arterial or venous branch or alterations of vessel development. In contrast with other reported cases, our patient presented with acute unilateral occlusion of macular arterioles, combined with diffuse retinal arterial occlusive disease, in adulthood. Panretinal photocoagulation may have prevented fibroglial proliferation which was described in previous reported cases. Recent reports suggest that pathogenesis of NF-1 vasculopathy may result from dysfunction of neurofibromin, the NF-1 gene product, in vessel endothelial and smooth muscle cells.⁵

Our case shows that NF-1 related occlusive retinal arteriopathy may suddenly appear during adulthood and should be considered in patients with NF-1 or in young adults with retinal vascular occlusive disease and unknown NF-1.

A Leclaire-Collet, S Y Cohen, C Vignal, A Gaudric

Department of Ophthalmology, Hôpital Lariboisière, Assistance Publique-Hôpitaux de Paris and Université Paris 7, France

A Leclaire-Collet

Department of Ophthalmology, Rouen University Hospital Charles Nicolle, Rouen, France

S Y Cohen, G Quentel

Centre Ophtalmologique d'Imagerie et de Laser, Paris, France

Correspondence to: Dr Salomon Y Cohen, Centre Ophtalmologique d'Imagerie et de Laser, 11 Rue Antoine Bourdelle, 75015 Paris, France; sycohen@club-internet.fr

doi: 10.1136/bjo.2005.077701

Accepted for publication 12 August 2005

References

- 1 Saylor WR, Saylor DC. The vascular lesions of neurofibromatosis. *Angiology* 1974;25:510–19.
- 2 Moadel K, Yannuzzi LA, Ho AC, *et al.* Retinal vascular occlusive disease in a child with neurofibromatosis. *Arch Ophthalmol* 1994;112:1021–3.
- 3 Kadoi C, Nagaki Y, Hayasaka S. Unilateral peripheral retinal vascular occlusion in a young Japanese woman with neurofibromatosis-1. *Retina* 2003;23:541–3.
- 4 Thölen AM, Messmer EP, Landau K. Peripheral retinal vascular occlusive disorder in a young patient with neurofibromatosis 1. *Retina* 1998;18:184–6.
- 5 Hamilton SJ, Friedman JM. Insights into the pathogenesis of neurofibromatosis 1 vasculopathy. *Clin Genet* 2000;58:341–4.

Are biometric parameters a risk factor for idiopathic macular hole formation? Results of a matched case-control series

Recognised risk factors for the formation of idiopathic full thickness macular holes (IFTMH) include age, female, sex, and high myopia.^{1,2} However, we noticed that patients with IFTMH within our population, tended to have shorter than normal axial lengths. An age and sex matched case-control study was

therefore performed to test this hypothesis and determine whether biometric factors may be associated with formation of IFTMH.

Methods

Consecutive patients undergoing surgery for IFTMH had age, sex, axial length in millimetres (mm), and corneal keratometry (K) measurements in dioptres (D) recorded.

For each case three age and sex matched controls were randomly identified from a cataract surgery database (Medisoft). Biometric measurements were made in all cases and controls using the IOL-Master (Zeiss, Jena). Mean corneal curvature was calculated by averaging the two K readings.

Descriptive statistics and conditional logistic regression method for analysis of matched pair data were used to infer estimates.

Results

Thirty five consecutive cases and 105 controls were identified with a mean age of 67.3 years (35–77 years) and a female to male ratio of 24:11. The mean (SD) axial length in the cases was 22.94 (0.96) mm whereas in controls it was 23.48 (1.44) mm. The axial lengths of the cases also fell within a narrower range than those of the controls (fig 1). Mean K readings in cases was 44.04 D (range 41.87–46) and 43.44 D in controls. (range 40.56–47.92).

Evidence suggests that the longer the axial length the less the odds of being a case; odds ratio (OR) 0.67 ($p = 0.036$, CI 0.47 to 0.77) and the higher the dioptre power of the curvature the higher the odds of being a case as opposed to a control; OR 1.50 ($p = 0.02$, CI 1.07 to 2.01).

Comment

As in previous studies our population sample demonstrates an increased risk of IFTMH in females with most cases clustering in the 60–70 year age group.^{3,4} The mean axial length in controls was also found to be similar to results in the published literature.^{5,6}

Mean spherical equivalence (MSE) was measured by the Eye Disease Case Control Study Group⁷ and although their findings were statistically insignificant, their regression analysis found an increased likelihood of hypermetropia in the IFTMH cases. Our cases clustered in a relatively narrow range of axial

lengths (21 mm–25.31 mm in the cases compared to 20.64 mm–29.48 mm in the controls) with the maximum axial length in the cases being 25.31 mm (fig 1). In Japanese literature, high myopia is a prominent, recognised risk factor and in one study the overall mean MSE was -0.66 D.² From our study it appears myopic macular holes are encountered much less frequently in a predominantly white population.

We believe the significant corneal dioptric differences found may be a result of the natural process of emmetropisation of a shorter eye, or alternatively be an independent risk factor.

IFTMH are thought to arise from retinal surface traction which in turn arises from an abnormal and incomplete posterior vitreous detachment.⁸ Our results suggest that eyes with shorter than average axial lengths and therefore lower volume vitreous cavity are either at increased risk of developing such incomplete and abnormal vitreous detachments or, in the presence of such an incomplete vitreous detachment, of developing a macular hole. We are not aware that shorter axial length has previously been shown to be significantly associated with IFTMH.

S P Shah

Vitreoretinal Speciality, Eye Department, St Thomas's Hospital, Lambeth Palace Road, London SE1 7EH, UK

C Bunce

Moorfields Eye Hospital, London, UK

R L Johnston

Cheltenham General Hospital, Cheltenham, Sandford Road, Cheltenham GL53 7AN, UK

D A H Laidlaw

St Thomas's Hospital, Lambeth Palace Road, London SE1 7EH, UK

Correspondence to: Shaheen P Shah, MRCOphth, Ophthalmology, Vitreoretinal Speciality, Eye Department, St Thomas's Hospital, Lambeth Palace Road, London SE1 7EH, UK; shaheen_shah@hotmail.com

doi: 10.1136/bjo.2005.077008

Accepted for publication 21 August 2005

RLJ has a commercial and proprietary interest in the cataract database from which control data were derived.

References

- Evans JR, Schwartz SD, McHugh JD, *et al*. Systemic risk factors for idiopathic macular holes: a case-control study. *Eye* 1998;**12**(Pt 2):256–9.
- Kumagai K, Ogino N, Demizu S, *et al*. Clinical features of idiopathic macular holes. *Nippon Ganka Gakkai Zasshi* 2000;**104**, **118**:19–25.
- James M, Feman SS. Macular holes. *Graefes Arch Clin Exp Ophthalmol* 1980;**215**:59–63.
- McDonnell PJ, Fine SL, Hillis AI. Clinical features of idiopathic macular cysts and holes. *Am J Ophthalmol* 1982;**93**:777–86.
- Shimmyo M, Orloff PN. Corneal thickness and axial length. *Am J Ophthalmol* 2005;**139**:553–4.
- Gudmundsdottir E, Arnarsson A, Jonasson F. Five-year refractive changes in an adult population: Reykjavik Eye Study. *Ophthalmology* 2005;**112**:672–7.
- No authors listed. Eye disease case control study group. Risk factors for idiopathic macular holes. *Am J Ophthalmol* 1994;**118**:754–61.
- Chauhan D, Antcliff R, Rai P, *et al*. Papillofoveal traction in macular hole formation: the role of optical coherence tomography. *Arch Ophthalmol* 2000;**118**:32–8.

Choroiditis and exudative macular detachments in a post transplant leukaemic patient: an unusual presentation of *Pneumocystis jiroveci* infection

Pneumocystis jiroveci is a commensal found in the respiratory tract of healthy individuals. It can cause infections of almost any organ in immunocompromised hosts. *P jiroveci* choroiditis, featuring multifocal choroidal lesions, has been reported in immunocompromised patients despite prophylactic use of inhaled pentamidine. We report a post-transplant leukaemic patient whose posterior segment findings demonstrate an atypical picture of recurrent *P jiroveci* choroiditis.

Case report

A 20 year old woman presented with a 1 week history of bilateral blurred vision, dyspnoea, and dry cough. Visual acuity was reduced to 6/36 bilaterally with posterior subcapsular cataracts. Funduscopy disclosed multifocal, creamy-yellow choroidal lesions at both posterior poles with exudative retinal detachments at the maculae (fig 1). Optic discs and retinal vessels were normal. Fluorescein angiography showed early patchy hypofluorescence (corresponding to the choroidal lesions) and late hyperfluorescence with pooling beneath the detachments.

Three years earlier she had undergone a successful allogeneic bone marrow transplant for chronic myeloid leukaemia. Her maintenance therapy included inhaled pentamidine as prophylaxis against *P jiroveci* infection. However, she admitted to not taking her inhaled pentamidine. Molecular genetic and radiological investigations excluded leukaemic recurrence. Chest x ray showed left lung shadowing and bronchoalveolar lavage isolated *P jiroveci*. *P jiroveci* pneumonia with *P jiroveci* choroiditis was diagnosed and high dose oral co-trimoxazole 7.2 g/day (120 mg/kg/day) and prednisolone 60 mg/day commenced. Within 2 weeks her respiratory and ocular symptoms improved. Visual acuities returned to 6/9 and the fundal appearances resolved. She was discharged on daily oral co-trimoxazole 960 mg, prednisolone 20 mg, and inhaled pentamidine.

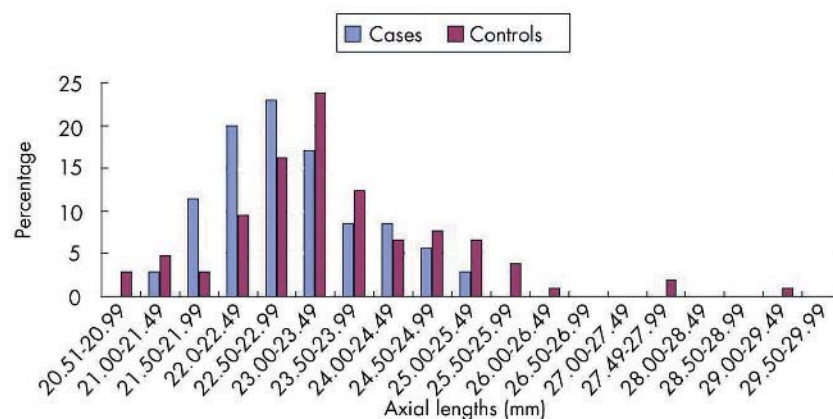


Figure 1 Axial lengths (mm) of patients with macular holes compared with age and sex matched controls.

Three weeks later she was readmitted with increasing dyspnoea and blurred vision. Chest x ray and computed tomography findings were compatible with diffuse interstitial fibrosis in both lungs. Funduscopy revealed peripapillary choroidal lesions with disc swelling bilaterally (fig 2). This time the choroidal lesions were peripapillary only rather than throughout the posterior pole, with exudative detachments inferiorly. Recurrent *P jiroveci* pneumonia and choroiditis was diagnosed and oral atovaquone and high dose prednisolone were commenced. Within 3 weeks her fundal appearance resolved leaving only some pigmentary changes. Her discharge medication included daily oral prednisolone 40 mg, cotrimoxazole 960 mg, and inhaled pentamidine. There have been no further intraocular recurrences.

Comment

Pneumocystis jiroveci is a commensal, found in the respiratory tract of healthy individuals. It can cause infections of almost any organ in immunocompromised hosts.¹⁻³ *P jiroveci* choroiditis has been reported in immunocompromised patients despite prophylactic use of inhaled pentamidine.^{4,5} The diagnosis is based on the clinical findings of multifocal yellowish circular choroidal lesions at the posterior pole. *P jiroveci* has been found in these lesions on histological sections^{3,5} and the lesions resolve on systemic anti-pneumocystis treatment.⁴ However, most cases of *P jiroveci* choroiditis are diagnosed histologically post mortem.^{3,6}

Thus, the acute clinical findings may be more varied than previously described. In our patient, massive exudative retinal detachments were associated with the previously described choroidal lesions. The clinical picture varied on the second presentation, but there was complete and rapid resolution of

the signs with anti-pneumocystis therapy. To the best of our knowledge, this is the first report of *P jiroveci* choroiditis causing exudative retinal detachments. *P jiroveci* should be considered in the differential diagnosis of susceptible patients, even if the ophthalmological findings are "atypical."

K Sabri, K Bibby

Department of Ophthalmology, Leicester Royal Infirmary, Leicester LE1 5WW, UK

Correspondence to: K Sabri, Department of Ophthalmology, Leicester Royal Infirmary, Leicester LE1 5WW, UK; ksabri@yahoo.com

doi: 10.1136/bjo.2005.077479

Accepted for publication 21 August 2005

References

- 1 Dugel PU, Rao NA, Forster DJ, *et al*. Pneumocystis carinii choroiditis after long term aerosolized pentamidine therapy. *Am J Ophthalmol* 1990;110:113-17.
- 2 Whitcup SM, Fenton RM, Pluda JM, *et al*. Pneumocystis carinii and Mycobacterium avium-intracellulare infection of the choroid. *Retina* 1992;12:331-5.
- 3 Northfelt DW, Clement MJ, Safran S. Extrapulmonary pneumocystosis: clinical features in human immunodeficiency virus infection. *Medicine* 1990;69:392-8.
- 4 Sneed SR, Blodi CF, Berger BB, *et al*. Pneumocystis carinii choroiditis in patients receiving inhaled pentamidine. *N Engl J Med* 1990;322:936-7.
- 5 Rao NA, Zimmerman PL, Boyer D, *et al*. A clinical, histopathologic, and electron microscopic study of pneumocystis carinii choroiditis. *Am J Ophthalmol* 1989;107:218-28.
- 6 Macher A, Bardenstein D, Zimmerman L, *et al*. Pneumocystis carinii choroiditis in a male homosexual with AIDS and disseminated pulmonary and extrapulmonary P carinii infection. *N Engl J Med* 1987;316:1092.

Prothrombotic and atherosclerotic risk factors lack significance in NAION patients harbouring mitochondrial DNA mutations

We recently reported that a group of patients with non-arteritic anterior ischaemic optic neuropathy (NAION) had an increased prevalence of potentially pathological mitochondrial DNA (mtDNA) mutations, implying a link between mitochondrial disease and this optic neuropathy.¹ We decided to investigate the association of other risk factors for NAION in these same patients.

Case reports

NAION patients were genotyped for the presence of prothrombotic polymorphisms that have been reported in association with NAION,^{2,3} including factor II G20210A prothrombin variant, factor V Leiden G1691A variant, MTHFR C677T and A1298C variants, platelet glycoprotein receptor IIIa (PI^{A2}) allele, and apolipoprotein E (4) allele, as described previously.⁴⁻⁸ These reports included large control groups that were ethnically matched to our NAION patients and that had been queried regarding the presence of atherosclerotic risk factors. Controls older than 50 years were selected for comparison with NAION patients.

Table 1 shows that the prevalence rates for prothrombotic variants among NAION patients did not differ from controls. Reported prevalence of diabetes, hypertension, and hyperlipidaemia was relatively high in NAION patients but was also not significantly different from controls.

Comment

The lack of a significant association between NAION patients and controls in relation to thrombophilic genetics markers has been reported before,⁹ and the role of these factors remains uncertain. More surprising is the lack of a statistical association with atherosclerotic risk factors. For example, in our group of NAION patients, 68% were diabetic, but this figure did not differ significantly from the prevalence of more than 50% in well matched controls. This observation reflects the high, and rising, frequency of diabetes and other atherosclerotic risk factors in the developing world.

A few qualifications are appropriate. NAION patients were a relatively small group of Middle Eastern Arabs, and it is possible that a larger group would have yielded statistically significant results or that the observations reported here are specific to this genetically homogeneous population. Atherosclerotic risk factors were assessed by individual report from patients and controls, and the actual prevalence of these disorders may be different from that recognised. Finally, other risk factors, such as homocysteine levels, nocturnal hypotension, or environmental factors¹⁰ were not consistently investigated.

Nevertheless, the fact that the occurrence of NAION cannot be easily explained by the presence of prothrombotic or atherosclerotic risk factors shifts focus to the possibility that mitochondrial abnormalities may be important in the development of NAION. Based on these observations, testing for mitochondrial abnormalities may be warranted in NAION patients, especially the ones without a

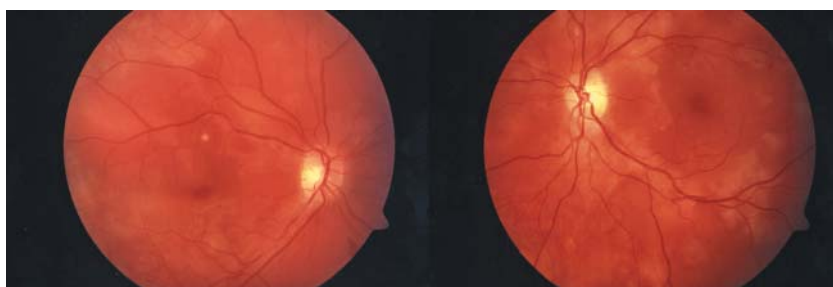

Figure 1 Multifocal, creamy-yellow choroidal lesions at both posterior poles with massive exudative retinal detachments at the maculae.

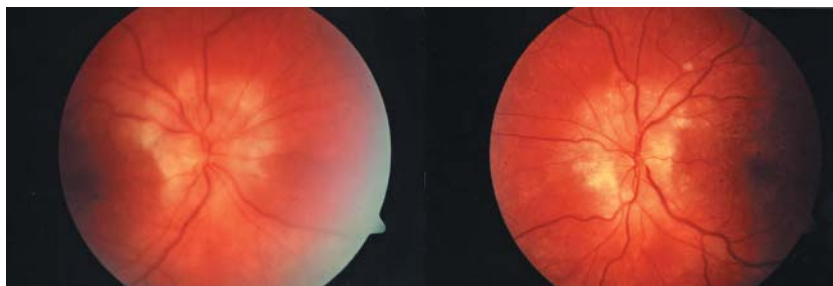

Figure 2 peripapillary choroidal lesions with disc swelling.

Table 1 Comparison of risk factors in NAION patients and controls

Risk factor		NAION patients	Controls	Odds ratio	95% CI	p Value
Apo E4	Homo	0/19	0/593	31.2	0.60 to 1615.3	1
Factor II G20210A	Homo	0/19	0/593	31.2	0.60 to 1615.3	1
	Hetero	0/19	10/593	0	0.00 to 17.52	1
Factor V G1691A	Homo	0/19	0/200	10.5	0.20 to 545.6	1
	Hetero	0/19	5/200	0	0.00 to 13.10	1
MTHFR C677T	Homo	0/19	12/625	0	0.00 to 15.06	1
	Hetero	4/19	161/625	0.77	0.21 to 2.52	0.79
MTHFR A1298C	Homo	0/19	57/625	0	0.00 to 2.71	0.39
	Hetero	7/19	322/625	0.55	0.19 to 1.52	0.30
PI ^{A2} allele	Homo	0/19	12/509	0	0.00 to 12.22	1
	Hetero	3/19	137/509	0.51	0.12-1.89	0.41
Age, mean (SD)	–	58.8 (8.5)	57.1 (4.2)	–	–	0.40
Sex (M:F)	–	14:5	351:160	1.28	0.42 to 4.13	0.64
Diabetes	–	13/19	256/511	2.16	0.75 to 6.47	0.18
Hypertension	–	10/19	209/511	1.61	0.59 to 4.38	0.43
Hyperlipidaemia	–	2/19	59/511	0.68	0.11 to 3.17	1
CAD	–	1/19	27/511	0.55	0.03 to 4.03	1
NS mtDNA changes	–	14/19	11/100	22.6	6.03 to 91.07	< 0.001

NAION, non-arteritic ischaemic optic neuropathy; CAD, coronary artery disease; NS mtDNA changes, non-synonymous (changing an amino acid in the resultant protein) mitochondrial DNA nucleotide change; Homo, homozygous; Hetero, heterozygous. Diabetes, hypertension, hyperlipidaemia, and CAD were assessed by patient report both from NAION patients and from controls. Controls previously reported for mtDNA changes and for atherosclerotic and prothrombotic risk factors (see text). Odds ratio and p values compare prevalence of different risk factors in NAION patients to controls.

medical or family history of a thrombotic or vascular event.

K K Abu-Amero

Mitochondrial Research Laboratory, Department of Genetics, King Faisal Specialist Hospital and Research Centre, Riyadh, Kingdom of Saudi Arabia

T M Bosley

Neuro-ophthalmology Service, King Khaled Eye Specialist Hospital, Riyadh, Kingdom of Saudi Arabia

Correspondence to: Dr Khaled K Abu-Amero, Mitochondrial Research Laboratory, Department of Genetics, King Faisal Specialist Hospital and Research Center (MBC # 03), PO Box 3354, Riyadh 11211, Kingdom of Saudi Arabia; kamero@kfsjhr.edu.sa

doi: 10.1136/bjo.2005.078071

Accepted for publication 9 July 2005

References

- Bosley TM, Abu-Amero KK, Ozand PT. Mitochondrial DNA nucleotide changes in non-arteritic ischaemic optic neuropathy. *Neurology* 2004;**63**:1305–8.
- Nagy V, Facska A, Takacs L, et al. Activated protein C resistance in anterior ischaemic optic neuropathy. *Acta Ophthalmol Scand* 2004;**82**:140–3.
- Glueck CJ, Wang P, Bell H, et al. Nonarteritic anterior ischemic optic neuropathy: associations with homozygosity for the C677T methylenetetrahydrofolate reductase mutation. *J Lab Clin Med* 2004;**143**:184–92.
- Abu-Amero KK, Wyngaard CA, Kambouris M, et al. Prevalence of the 20210 G→A prothrombin variant and its association with coronary artery disease in a Middle Eastern Arab population. *Arch Pathol Lab Med* 2002;**126**:1087–90.
- Abu-Amero KK, Wyngaard CA, Dzimiri N. Prevalence and role of methylenetetrahydrofolate reductase 677 C→T and 1298 A→C polymorphisms in coronary artery disease in Arabs. *Arch Pathol Lab Med* 2003;**127**:1349–52.
- Abu-Amero KK, Wyngaard CA, Dzimiri N. Association of the platelet glycoprotein receptor IIIa (PLA1/PLA1) genotype with coronary artery disease in Arabs. *Blood Coagul Fibrinolysis* 2004;**15**:77–9.
- Dzimiri N, Meyer BF, Hussain SS, et al. Relevance of apolipoprotein E polymorphism for coronary artery disease in the Saudi population. *Arch Pathol Lab Med* 1999;**123**:1241–5.
- Dzimiri N, Meyer B. World distribution of factor V Leiden. *Lancet* 1996;**347**:481–2.
- Salomon O, Huna-Baron R, Kurtz S, et al. Analysis of prothrombotic and vascular risk factors in patients with nonarteritic anterior ischemic optic neuropathy. *Ophthalmology* 1999;**106**:739–42.
- Hayreh SS. Risk factors in AION. *Ophthalmology* 2001;**108**:1717–18.

Inflammatory cytokine of basal and reflex tears analysed by multicytokine assay

Tear cytokine has a major role in various pathophysiological conditions of the ocular surface. So far, studies on tear cytokines have shown significant progress in providing an understanding of ocular surface diseases.^{1–3} The information that could be acquired from each subject, however, until recently has been severely hampered by limited sample volume and assay sensitivity. More importantly, it has become apparent that the relative balance between various cytokines and combinations of cytokines could be more important than absolute concentrations. Previous studies showed that the composition of basic and reflex tears was different, which made it more difficult to understand the ocular surface disorder correctly or to treat the patients suitably.^{4,5} Cytometric bead array (CBA) is a microparticle based flow cytometric assay that allows us to quantify multiple molecules from a very small sample.^{3,6,7} Using this method, we evaluated the inflammatory cytokines of basal and reflex tears from a single sample of individual eyes.

Methods

Twenty three normal volunteers (11 males and 12 females, 22–44 years of age, average 28 years) were recruited for this study. None of the subjects had signs of ocular diseases. The study was performed with the approval of the institutional review board. The basal tear samples of 10–15 µl were obtained from each eye by capillary flow, with no nasal stimulation or previous instillation of drugs or vital dyes. Each sample was collected at

5 pm. No anaesthetic drops were instilled. The samples were collected non-traumatically from the inferior meniscus. Successively, reflex tear samples were collected by inserting application sticks into a participant's nose. The amounts of six inflammatory molecules interleukin (IL)-1β, IL-6, IL-8, IL-10, IL-12p70, and tumour necrosis factor α (TNF-α), were measured by CBA (BD Biosciences, San Diego, CA, USA), according to the manufacturer's instructions. Briefly, for the tear sample and cytokine standard mixture, 10 µl of sample or standard were added to 40 µl sterile purified water, a mixture of 50 µl each of capture Ab-bead reagent and detector Ab-phycoerythrin (PE) reagent. The mixture was subsequently incubated for 3 hours at room temperature, and washed to remove any unbound detector Ab-PE reagent before data acquisition using flow cytometry. A two colour flow cytometric analysis was performed using a FACScan flow cytometer (Beckton Dickinson Immunocytometry Systems). Data were acquired and analysed using BD cytometric bead array software.

Results

The concentrations of IL-1β, IL-6, IL-10, IL-12p70, and TNF-α were not significantly different between basal and reflex tears. In contrast, the concentration of IL-8 was significantly decreased in reflex tears compared with basal tears in each eye (paired *t* test, *p*<0.01, fig 1). In order to illuminate the inter-relation of each cytokine, the ratio of two different cytokines is shown in table 1.

Comment

Previously published studies have demonstrated that CBA correlates well with enzyme linked immunosorbent assay (ELISA), but the absolute concentrations obtained from each assay were differed for kits of different manufacturers.⁷ Indeed, the concentrations of tear cytokines in the present results were almost equal to the previous report using the same kit.³ Nakamura *et al* performed ELISA for multiple cytokines measuring pooled tears.¹ The pooled tears enable measurement of multiple cytokines; however the results

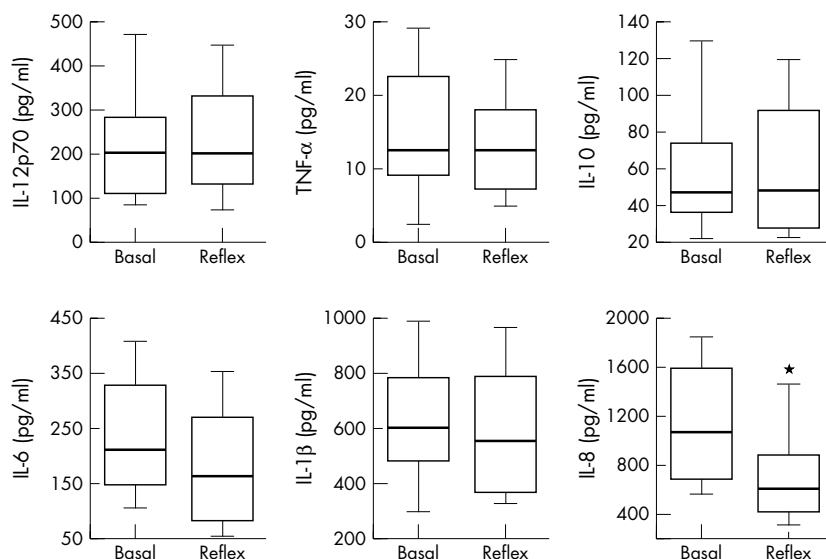


Figure 1 Change of concentrations of cytokines in basal and reflex tears. The concentration of IL-1 β , IL-6, IL-10, IL-12p70 and TNF- α are not significantly different between basal and reflex tears. In contrast, IL-8 is significantly less in reflex tears compared with basal tears in each eye (paired *t* test, **p*<0.01).

can be strongly influenced by samples with high concentrations. Because the absolute concentrations of tear cytokines varied widely, this can have a strong bias. In this study, to our knowledge, we measured the multiple cytokines of basal and reflex tears from a single sample for the first time, which can provide concentration ranges for these cytokines in normal subjects that may prove important for studies of ocular inflammation. Of note, only the concentration of IL-8 was decreased more significantly in reflex tears than in basal tears. Maitchouk *et al* showed that there is no distinctive role of major and accessory glands in secreting basal or reflex tears, thus these tears might be produced primarily by the same tissue and differences might be only the result of the secretory rate of reflex tears.⁸ It was reported that a neuropeptide released from corneal sensory nerves stimulated conjunctival epithelium to secrete IL-8.⁹ Because sensory nerves are

present in the cornea so abundantly, IL-8 can be produced constantly on the ocular surface. IL-8 is a potent pro-inflammatory cytokine, and has a pivotal role in the host defence system.¹⁰ But excessive IL-8 might be so harmful that constant washout might be helpful for homeostasis of the ocular surface. Indeed, a large amount of IL-8 was found in the tears of dry eyes.¹¹ Thus, basal tears might be composed of products of the ocular surface including IL-8 and small amounts of reflex tears that are induced by mild stimulation such as blinks.

In summary, the present study showed that pro-inflammatory and anti-inflammatory cytokines/chemokines are present in the ocular surface even in the absence of inflammation and this was detectable from a small sample of single eyes. Stimulating tears, with the exception of IL-8, has minimal effect on cytokine concentration. We believe the CBA technique can make a valuable contribution

in understanding the specific immunopathological mechanisms underlying cytokine interaction with the ocular surface.

S Sonoda, E Uchino, K Nakao, T Sakamoto
Department of Ophthalmology Faculty of Medicine, Kagoshima University Graduate School of Medicine and Dental Sciences, Kagoshima, Japan

Correspondence to: Taiji Sakamoto, MD, Department of Ophthalmology, Faculty of Medicine, Kagoshima University Graduate School of Medicine and Dental Sciences, 8-35-1 Sakuragaoka, Kagoshima 890-8520, Japan; tsakamot@m3.kufm.kagoshima-u.ac.jp

doi: 10.1136/bjo.2005.076737

Accepted for publication 12 August 2005

References

- 1 Nakamura Y, Sotozono C, Kinoshita S. Inflammatory cytokines in normal human tears. *Curr Eye Res* 1998;17:673-6.
- 2 Lema I, Duran JA. Inflammatory molecules in the tears of patients with keratoconus. *Ophthalmology* 2005;112:654-9.
- 3 Cook EB. Tear cytokines in acute and chronic ocular allergic inflammation. *Curr Opin Allergy Clin Immunol* 2004;4:441-5.
- 4 Sack RA, Conradi L, Krumholz D, *et al*. Membrane array characterization of 80 chemokines, cytokines, and growth factors in open- and closed-eye tears: angiogenin and other defense system constituents. *Invest Ophthalmol Vis Sci* 2005;46:1228-38.
- 5 Fukuda M, Fullard RJ, Willcox MD, *et al*. Fibronectin in the tear film. *Invest Ophthalmol Vis Sci* 1996;37:459-67.
- 6 Chen R, Lowe L, Wilson JD, *et al*. Simultaneous quantification of six human cytokines in a single sample using microparticle-based flow cytometric technology. *Clin Chem* 1999;45:1693-4.
- 7 Khan SS, Smith MS, Reda D, *et al*. Multiplex bead array assays for detection of soluble cytokines: comparisons of sensitivity and quantitative values among kits from multiple manufacturers. *Cytometry B Clin Cytom* 2004;61:35-9.
- 8 Maitchouk DY, Beuerman RW, Ohta T, *et al*. Tear production after unilateral removal of the main lacrimal gland in squirrel monkeys. *Arch Ophthalmol* 2000;118:246-52.
- 9 Tran MT, Ritchie MH, Lausch RN, *et al*. Calcitonin gene-related peptide induces IL-8 synthesis in human corneal epithelial cells. *J Immunol* 2000;164:4307-12.

Table 1 Ratios of cytokine concentration

		B					
		IL-1b	IL-6	TNF- α	IL-12p70	IL-10	IL-8
(A) Basal tear							
	IL-1b	1	3.022 (0.246)	54.162 (6.549)	3.322 (0.316)	12.556 (0.889)	0.716 (0.086)
	IL-6	0.386 (0.037)	1	23.568 (5.952)	1.238 (0.184)	4.705 (0.553)	0.246 (0.03)
A	TNF- α	0.022 (0.002)	0.07 (0.008)	1	0.074 (0.011)	0.275 (0.028)	0.017 (0.003)
	IL-12p70	0.349 (0.026)	0.989 (0.071)	18.269 (2.086)	1	3.981 (0.166)	0.261 (0.042)
	IL-10	0.087 (0.005)	0.253 (0.02)	4.518 (0.47)	0.261 (0.012)	1	0.067 (0.011)
	IL-8	2.14 (0.34)	5.576 (0.694)	144.913 (45.971)	7.447 (1.546)	28.257 (5.078)	1
(B) Reflex tear							
	IL-1b	1	3.71 (0.252)	53.061 (5.46)	2.918 (0.331)	12.012 (1.123)	0.972 (0.094)
	IL-6	0.304 (0.027)	1	15.807 (1.976)	0.808 (0.061)	3.381 (0.274)	0.276 (0.029)
A	TNF- α	0.021 (0.001)	0.078 (0.007)	1	0.062 (0.007)	0.254 (0.026)	0.02 (0.002)
	IL-12p70	0.390 (0.023)	1.361 (0.082)	21.357 (3.427)	1	4.231 (0.147)	0.382 (0.046)
	IL-10	0.093 (0.005)	0.324 (0.018)	4.837 (0.524)	0.241 (0.007)	1	0.093 (0.012)
	IL-8	1.043 (0.231)	4.779 (0.665)	73.465 (13.897)	4.02 (0.727)	17.235 (3.251)	1

Ratio of cytokine concentration was calculated as A/B. Each cell shows the mean (SEM).

- 10 Scapini P, Lapinet-Vera JA, Gasperini S, *et al.* The neutrophil as a cellular source of chemokines. *Immunol Rev* 2000;**177**: 195–203.
- 11 Jones DT, Monroy D, Ji Z, *et al.* Alterations of ocular surface gene expression in Sjogren's syndrome. *Adv Exp Med Biol* 1998;**438**:533–6.

Outcome of implementing the national services framework guidelines for diabetic retinopathy screening: results of an audit in a primary care trust

Systematic screening for diabetic retinopathy is the key to achieving the targets set out in the recently published national service framework (NSF) guidelines.^{1,2} One of the two priorities and planning framework (PPF) targets is that by March 2006 a minimum of 80% of people with diabetes are to be offered screening, rising to 100% by December 2007.^{3,4} Digital photography is the modality for screening.^{5–8} The British Diabetic Association has established standards for any diabetic retinopathy screening programme of at least 80% sensitivity and 95% specificity.

Screening programme

Our screening programme was set up to evaluate the existing nationally recommended diabetic retinopathy screening service.

In all, 2165 patients were invited over a period of 12 months; 909 participated. At the screening mydriatic drops (1% tropicamide and 2.5% phenylephrine) were instilled. The patients were photographed with a Topcon fundus camera and each photograph was screened and graded by consultant ophthalmologists (table 1).

Of the total 909; there were 198 patients with retinopathy (grades R1, M, R2, and R3), 644 patients without retinopathy (grade 0), 63 patients with OL (other lesions), and one was (grade U) ungradeable (tables 2 and 3). The sensitivity was 98% and specificity 97%. The retinopathy present was 21% and the referral rate for retinopathy (STDR) was 7%; 59% did not take up the offer to be screened. Some of the reasons cited: 956 (44%) declined or did not respond, 251 (11%) are being screened elsewhere, 11 (0.5%) are not diabetic, five (0.18%) are dead, six (0.27%) are registered blind, and 21 (1%) have moved.

Comment

Our screening methods surpassed the standards set by the NICE guidelines. However 59% of patients did not take up the offer. The achievable standard to which strategic health authorities and primary care trusts are working is 90% uptake of those offered screening with the minimum standards of 70%–80%,

Table 1 Referred patients

Diabetic patients type 1			
Invited	93	Appointment made	41
Diabetic patients type 2			
Invited	1442	Appointment made	609
Diabetic patients type not stated			
Invited	630	Appointment made	259

but even though quality assurance systems are in place uptake is still very poor.

In the intercollegiate audit, led by the Royal College of Ophthalmologists, data were analysed from 9827 patients with diabetes from 129 general practices in 25 health authorities. The lowest level of coverage in a district was 38% and the highest 85%. In general practice the coverage ranged from 14% to 97%. The likelihood of having an eye examination was marginally higher in districts with a systematic examination rather than opportunistic or without recognised schemes at all.

In the Hounslow Primary Care Trust our hospital episode statistics (HES) are the only existing screening programme. Patients registered with a GP are referred to the HES for the screening. The reasons for the 44% who did not respond were that some did not have the time, some were elderly living on their own with nobody to take them, some did not understand the screening leaflet, and some just forgot.

Problems about coverage could be tackled if we had a central electronic database linked to all screening programmes. Although software providers have been agreed for such a data collection exercise, primary care trusts

have yet to implement this. People unable to attend during the week could be accommodated in weekend or evening clinics. These clinics could also be reserved, with bilingual support workers to explain the importance of screening for the ethnic patients. Community networks like the rotary, patient groups, ethnic resource centres, and senior citizens groups can be used. The National Service Framework targets will be achieved only if the diabetic population is convinced of the importance of screening.

M J Saldanha, U Meyer-Bothling
Ashford and St Peter's NHS Trust

Correspondence to: Mr Mario J Saldanha, Ashford and St Peter's NHS Trust, Ashford, TW15 3AA, UK; mariosaldanha@yahoo.com

doi: 10.1136/bjo.2005.076760

Accepted for publication 29 August 2005

Competing interests: none.

References

- 1 Department of Health. *National service framework for diabetes. The standards.* London: DoH, December, 2001.
- 2 Department of Health. *National service framework for diabetes. Delivery strategy.* London: DoH, 2003.
- 3 Garvican I, Scanlon P. *Quality assurance for the national screening programme for sight threatening diabetic retinopathy: development of a set of key quality assurance standards.* September, 2003.
- 4 National Diabetes Support Team. *Fact sheet No 5, hitting the target for retinopathy screening.* July, 2004.
- 5 Buxton MJ, Sculpher MJ, Ferguson BA, *et al.* Screening for treatable diabetic retinopathy: a comparison of different methods. *Diabet Med* 1991;**8**:371–7.
- 6 Gibbins RL, Owens DR, Allen JC, *et al.* Practical application of the European Field Guide in screening for diabetic retinopathy by using ophthalmoscopy and 35 mm retinal slides. *Diabetologia* 1998;**41**:59–64.
- 7 O'Hare JP, Hopper A, Madhavan C, *et al.* Adding retinal photography to screening for diabetic retinopathy: a prospective study in primary care. *BMJ* 1996;**312**:679–82.
- 8 Harding SP, Broadbent DM, Neoh C, *et al.* Sensitivity and specificity of photography and direct ophthalmoscopy in screening for sight threatening eye disease: the Liverpool diabetic eye study. *BMJ* 1995;**311**:1131–5.
- 9 Audit Commission. *Testing times. A review of diabetic services in England and Wales.* London: Department of Health, Audit Commission, 2000.

Table 2 Outcome by grade

Grade	Sex	Total
O	M	363
	F	261
	T	624
R1	M	74
	F	54
	T	128
M	M	23
	F	21
	T	44
R2	M	17
	F	9
	T	26
R3	M	1
	F	0
	T	1
OL	M	33
	F	30
	T	63
U	M	0
	F	1
	T	1

Table 3 Final data

Total patients screened	Sample size	Ungradable	True positives	False negatives	True negatives	False positive	Sensitivity	Specificity	Retinopathy present
909	909	1	198	4	644	8	98%	97%	21.78%

Late improvement in upward gaze in a patient with hydrocephalus related Parinaud dorsal midbrain syndrome

Acute hydrocephalus is a common cause of the Parinaud dorsal midbrain syndrome.^{1,2} Most patients with this condition improve either immediately following treatment of the hydrocephalus or within a few months,¹ and it is generally assumed that those who do not do so have no potential for subsequent improvement. I recently evaluated a patient whose upward gaze spontaneously improved 4½ years after treatment of trauma related hydrocephalus.

Case report

A 23 year old Asian man was in his usual excellent general and ocular health until October 2000, when he was struck by a car while walking across the street. He was taken to a local hospital where he was found to have extensive injuries, including bilateral subdural and epidural haematomas. He also had evidence of increased intracranial pressure and required an emergency cranial decompression. Postoperatively, he was evaluated by a neuro-ophthalmologist who noted that the patient's only ocular disturbance was a mild left trochlear nerve paresis. The paresis resolved within about 3 weeks.

About 6 months after the injury, the patient developed severe headaches and double vision. He was evaluated by the same neuro-ophthalmologist who had evaluated him previously. He noted that the patient now had a severe dorsal midbrain syndrome characterised by lack of elevation of either eye above the midline associated with an exotropia of 25–30 prism dioptres at distance and near, and a left hypotropia of 5 prism dioptres. An evaluation that included neuroimaging and measurement of intracranial pressure revealed hydrocephalus, and the patient underwent placement of a ventriculo-peritoneal shunt with normalisation of intracranial pressure, resolution of neuroimaging evidence of hydrocephalus, and resolution of headaches but without any change in ocular motility or alignment. He was eventually referred to the neuro-ophthalmology unit of the Wilmer Eye Institute at the Johns Hopkins Hospital for evaluation and management.

The patient was examined by me for the first time in September 2001, 11 months after the original injury and about 5 months after he had first been noted to have a dorsal midbrain syndrome. At that time, the examination revealed visual acuity of 20/20 in both eyes at distance and near. Automated perimetry revealed bilateral, incomplete, congruous, superior homonymous quadrantic field defects. Pupils were normally reactive to both light and near stimulation. In primary position, the patient had a 25 prism dioptre exotropia that increased to 35 prism dioptres on attempted right gaze and decreased to 15 prism dioptres on attempted left gaze. There was also a 5 prism dioptre left hypotropia. Both eyes could elevate just barely to the midline. There was no difference in degree of elevation with pursuit versus saccades, and elevation did not improve with the oculocephalic manoeuvre. Lateral gaze and downgaze were normal bilaterally for both pursuit and saccadic eye movements. I recommended consideration of strabismus surgery and asked the patient to return in

4 months for reassessment. He did so in January 2002, at which time his ocular motility and alignment were stable. Specifically, neither eye was able to elevate above the midline, either voluntarily or by the oculocephalic manoeuvre.

In May 2002, I performed a left lateral rectus muscle recession of 7.5 mm and a left medial rectus resection of 6.5 mm with superior transposition of both the lateral and medial rectus muscles one muscle width. Postoperatively, the patient had excellent horizontal alignment, although he still had a small left hypotropia of about 5 prism dioptres and was still unable to elevate either eye above the midline.

I subsequently followed the patient at regular intervals. When I examined him in April 2004, he had no change in his ocular motility or alignment, and I recommended that he consider obtaining a small vertical prism to try to eliminate his residual vertical diplopia. I also recommended that he return in 1 year for reassessment. He did so in August 2005.

When I examined the patient in August 2005, he indicated that he thought his vision had improved. He stated that although he was aware of some double vision, it was somewhat less than it had been previously. He also thought his eyes were "moving better."

On examination, the patient's visual acuity with correction was 20/15 in each eye at distance and J1 in each eye at near. Colour vision testing using Hardy-Rand-Rittler pseudoisochromatic plates was 10/10 bilaterally. Visual fields were performed by static technique and showed stable bilateral, incomplete, congruous, superior homonymous quadrantic defects, consistent with damage to both inferior occipital lobes. Pupils were isocoric and normally reactive to light and near stimulation. The patient had full abduction, adduction, and infraduction of both eyes. In addition, he now was able to elevate both eyes about 35° above the midline. He had normal velocity saccades in all directions, but he developed convergence-retraction nystagmus when looking at an optokinetic drum whose targets were being rotated downward. When the targets were moving upward, to the right, or to the left, the response was normal. In primary position, the patient had a 4 prism dioptre intermittent left hypotropia at distance and near, associated with 4° of intorsion of the left eye using double Maddox rods. He was most comfortable with a 4 prism dioptre prism placed base up over the left spectacle lens, and a Fresnel prism of this strength and orientation was placed on the left lens of his glasses. He had no ptosis or lid retraction, and the results of slit lamp biomicroscopy, applanation tonometry, and ophthalmoscopy were normal.

Comment

The dorsal midbrain syndrome of Parinaud usually results from damage to premotor pathways for binocular upward gaze in the dorsal mesencephalon.² Depending on the extent of damage, the patient may have pursuit saccadic dissociation, with better upward gaze during pursuit than when attempting upward saccades, and some patients have improved upward gaze with the oculocephalic manoeuvre, indicating sparing of infranuclear pathways. The dorsal midbrain syndrome may be caused by extrinsic or intrinsic lesions, with hydrocephalus

being a common aetiology in some series.^{1,3} Depending on the nature and extent of damage as well as the length of time the condition has been present before the underlying disorder is treated, some patients improve, often substantially, whereas others do not. In general, patients whose underlying condition is treated successfully but who do not improve within a few weeks to months are thought to have no potential to improve; however, our patient's spontaneous improvement about 4½ years after onset and treatment of the underlying condition indicates that some patients retain the potential to improve even after several years have passed. This information may be of value in counselling patients with the dorsal midbrain syndrome who ask if there is any chance of improvement when none has occurred after months to a few years.

Correspondence to: N R Miller, Wilmer Eye Institute, Johns Hopkins Hospital, 600 North Wolfe Street, Baltimore, MD 21287, USA; nrmiller@jhmi.edu

doi: 10.1136/bjo.2005.081810

Accepted for publication 7 September 2005

References

- 1 Keane JR. The prefrontal syndrome: 206 patients. *Neurology* 1990;**40**:684–90.
- 2 Zee DS, Newman-Toker D. Supranuclear and internuclear ocular motility disorders. In Miller NR, Newman NJ, Biousse V, et al. *Walsh and Hoyt's clinical neuro-ophthalmology*. 6th ed. Vol 1. Baltimore: Lippincott, Williams & Wilkins, 2005:907–67.
- 3 Rowe FJ. The presenting features of Parinaud's dorsal midbrain syndrome. *Br Orthopt J* 1997;**54**:20–3.

MAILBOX

Purification of triamcinolone acetate suspension for intravitreal injection

In the article by García-Arumí and associates,¹ the authors reported the results of several techniques used for purification of triamcinolone acetate suspension for intravitreal injection (two filter and two non-filter techniques). I very much appreciate that they finally recommended our method (centrifugation for 5 minutes at 3000 rpm with extraction of 0.9 ml of the supernatant and pellet resuspension with 0.9 ml of balanced salt solution, BSS) among those compared.²

This could have been an interesting report but I want to raise some important issues mentioned in their paper. The source of the evaluated techniques was not clearly specified by the authors. Are they previously published techniques? Are they techniques developed entirely by García-Arumí *et al*? As far as I know, the centrifugation technique described by García-Arumí *et al* was first reported by Hernaez-Ortega in 2003³ and it was first published by Hernaez-Ortega and myself in the 2004 July/August issue of *Ophthalmic Surgery, Lasers & Imaging*.² In fact, the term "purification" was first applied to removal of most of the vehicle from a commercially available triamcinolone acetate suspension by us.

Parametric tests tend to be more powerful than non-parametric tests if their distributional assumptions are met. However, non-parametric methods require fewer

assumptions, and they are generally robust against problems like outliers and non-constant variances. The authors tested statistical significance by the Kruskal-Wallis test, a non-parametric procedure that is a K-sample generalisation of the two sample rank sum test (also called the Mann-Whitney U test). It tests the null hypothesis of identical group medians, rather than means. With the data available in this report, the authors should have noticed that figures 1 and 2 show means and standard deviations; they should instead have shown group medians. Moreover, their results should have been expressed as medians.⁴ It also remains unclear how many assays were performed. By looking at figures 1 and 2, it seems that three assays were done each time but somehow they were done in duplicate. This is important to show the real sample size that was used to compute the estimates.

The pellet resuspension with 0.9 ml of BSS in the centrifugation technique appeared in their final recommendation at the end of the paper. However, the authors stated in the methods section that the pellet was resuspended with 1 ml of BSS. This point needs to be explained.

I recommend that the authors clarify the above mentioned issues. I also suggest that they learn the golden rule of fair use of another author's protected material: take from someone else only what you wouldn't mind someone taking from you.

Correspondence to: Dr Enrique Soto-Pedre, European Innovative Biomedicine Institute, C/Jardines #2, Apt 1-G, 39700 Castro-Urdiales, Cantabria, Spain; eibi@eurodiab.com

The author does not have commercial interest in any product mentioned in the manuscript.

doi: 10.1136/bjo.2005.083501

Accepted for publication 26 September 2005

References

- 1 **García-Arumi J**, Boixadera A, Giral J, *et al*. Comparison of different techniques for purification of triamcinolone acetonide suspension for intravitreal use. *Br J Ophthalmol* 2005;**89**:1112-14.
- 2 **Hernaez-Ortega MC**, Soto-Pedre E. A simple and rapid method for purification of triamcinolone acetonide suspension for intravitreal injection. *Ophthalmic Surg Lasers Imaging* 2004;**35**:350-1.
- 3 **Hernaez-Ortega MC**. [Intraocular steroids]. *Arch Soc Esp Oftalmol* 2003;**78**:523-4.
- 4 **Snedecor GW**, Cochran WG. *Statistical methods*, 5th ed. Ames, Iowa: Iowa State University Press, 1989.

PHEMA as a keratoprosthesis material

An aim to provide an optimised keratoprosthesis, with excellent biointegration, and all other properties meeting ideal requirements, is one we share with Mehta *et al*.¹ However, their paper includes some points that require clarification.

PHEMA (poly(2-hydroxyethyl methacrylate)) is a non-toxic polymer of the toxic monomer HEMA, though cytotoxicity is still possible if non-reacted monomer has not been fully removed. The "polyhydroxyethyl methacrylate" the authors obtained for their study was not fully described, and may have

been contact lens blanks, unlikely to have been processed for "implantable quality." Whether the samples had been fully extracted was not stated, nor was the hydration of the samples when used for the study. Contact lens blanks are not designed for cell adhesion and the results of this study, with regard to PHEMA, are entirely predictable and have been previously reported.

The commercially available keratoprosthesis AlphaCor is made from a form of PHEMA, specifically modified for its intended purpose within the cornea. In particular, the AlphaCor OPTIC is made from a relatively low water content, but hydrated, microporous form, similar to the samples evaluated by the authors, specifically because it does not encourage cellular adhesion (epithelial coverage is not desired for this model, nor would adherent posterior cells and membranes be desirable).

In contradistinction, the biointegratable SKIRT region of AlphaCor is made from a macroporous form of PHEMA with a very high water content; this material, with its interconnecting channels, has been optimised to promote viable biocolonisation, which has been extensively described in the literature. Mehta *et al* do concede that cells "may behave differently in colonising a 3-D porous keratoprosthesis skirt": indeed they do. Further, very subtle modifications of the sponge structure significantly affect all aspects of biointegration.

Both early trial results, such as the preliminary cases cited by Mehta *et al*, and current results for over 250 AlphaCor devices, have been extensively presented and made available to all device users. Histology now available from AlphaCor devices explanted from human recipients confirms that the biointegration process in humans is similar to that previously shown in the animal model, and maintained in the long term. As expected, specific inflammatory processes can cause localised reversal of biointegration in areas of stromal melting. Certainly, porosity itself does not prevent melting processes, as is also seen in relation to hydroxyapatite keratoprostheses and orbital implants.

There is no argument that keratoprosthesis materials and design require ongoing revision and improvement. The authors' findings in relation to hydroxyapatite are interesting although, as they note, this rigid material has its own limitations. Novel approaches are undergoing early evaluation and may offer benefits. However, at present, in our view, AlphaCor is a device worthy of consideration for those in whom a donor graft would fail.

C R Hicks, T V Chirila, S Vijayasekaran, G J Crawford

Lions Eye Institute, Perth, Western Australia

Correspondence to: Celia Hicks, Lions Eye Institute, Perth, Western Australia; crhicks@cyllene.uwa.edu.au

doi: 10.1136/bjo.2005.084855

Accepted for publication 11 October 2005

CH is medical director of CooperVision Surgical, manufacturer of AlphaCor. The Biomaterials and Polymer Research Department of the Lions Eye Institute has a financial interest in CooperVision Surgical through support of departmental funding, travel, and research.

Reference

- 1 **Mehta JS**, Futter CE, Sandeman SR, *et al*. Hydroxyapatite promotes superior keratocyte adhesion and proliferation in comparison with current keratoprosthesis skirt materials. *Br J Ophthalmol* 2005;**89**:1356-62.

Expression of TSH-R in normal human extraocular muscles

We read with interest the paper published by Boschi *et al*,¹ in which immunohistochemistry was performed on orbital tissues from patients with thyroid associated ophthalmopathy (TAO) and compared with non-diseased orbital tissue.

Our laboratory recently reported positive TSH receptor staining within normal human muscle fibres, using one of the same antibodies (3G4) as Boschi *et al* (supplied by Costagliola) and a commercial antibody (3B12).²

Our findings differ from Boschi *et al*'s as no staining of the muscle fibres was visible in their experience.

Assessing the techniques used suggested some possibilities as to why our findings differ. Our paraffin embedded tissues were subjected to a proteolytic antigen retrieval step, as commonly used in avidin-biotin staining.³ The reason for this is that formalin used in fixation is notorious for altering protein immunoreactivity, and hence masking protein expression.^{4,5}

Moreover, the amplification immunohistochemistry kit used in our experiments is possibly more sensitive than conventional immunohistochemistry used in the experiments of Boschi *et al*.⁶

We do not dispute the finding that TSH-R expression is elevated in orbital connective tissue of diseased patients. Combined with our findings, Boschi *et al*'s paper also suggests that expression of TSH-R on normal muscle fibres is lower than in the connective tissue of diseased patients. Boschi *et al* have successfully produced more evidence that connective tissues in the orbit are active in TAO affected patients; however, the potential role of the extraocular muscle in the pathogenesis of TAO should also be considered.

S J Klopogge, A G Frauman

Department of Medicine, University of Melbourne, Clinical Pharmacology and Therapeutics Unit, Level 5, Lance Townsend Building, Austin Health, Studley Road, Heidelberg, Victoria, 3084, Australia

Correspondence to: Mr Steven Klopogge, Department of Medicine, University of Melbourne, Clinical Pharmacology and Therapeutics Unit, Level 5, Lance Townsend Building, Austin Health, Studley Road, Heidelberg, Victoria, 3084, Australia; s.klopogge@pgrad.unimelb.edu.au

doi: 10.1136/bjo.2005.084863

Accepted for publication 11 October 2005

References

- 1 **Boschi A**, Daumerie C, Spiritus M, *et al*. Quantification of cells expressing the thyrotropin receptor in extraocular muscles in thyroid associated orbitopathy. *Br J Ophthalmol* 2005;**89**:724-9.
- 2 **Klopogge SJ**, Busuttill BE, Frauman AG. TSH receptor protein is selectively expressed in normal human extraocular muscle. *Muscle Nerve* 2005;**32**:95-8.

- 3 **Thompson LD**, Miettinen M, Wenig BM. Sinonasal-type hemangiopericytoma: a clinicopathologic and immunophenotypic analysis of 104 cases showing perivascular myoid differentiation. *Am J Surg Pathol* 2003;27:737-49.
- 4 **Fox CH**, Johnson FB, Whiting J, et al. Formaldehyde fixation. *J Histochem Cytochem* 1985;33:845-53.
- 5 **Puchler H**, Meloan SN. On the chemistry of formaldehyde fixation and its effects on immunohistochemical reactions. *Histochemistry* 1985;82:201-4.
- 6 **Erber WN**, Willis JJ, Hoffman GJ. An enhanced immunocytochemical method for staining bone marrow trephine sections. *J Clin Pathol* 1997;50:389-93.

Trabeculotomy versus trabeculotomy-trabeculectomy for congenital glaucoma

The article by Al-Hazmi *et al*¹ states that combined trabeculotomy-trabeculectomy with mitomycin C (CTTM) gave better results than trabeculotomy alone for primary congenital glaucoma (PCG) at the King Khaled Eye Specialist Hospital (KKESH) in Riyadh, Saudi Arabia, between 1982 and 2002. For moderate PCG the success rate is stated as 40% and 80% for trabeculotomy and CTTM, respectively. For severe PCG the stated success rate is 10% and 70% for trabeculotomy and CTTM, respectively. However, without more specific information regarding when the trabeculectomies were performed at KKESH, the authors cannot advocate CTTM over trabeculotomy for moderate and severe PCG.

As the article states, over the years at KKESH the success rate for trabeculotomy for PCG dramatically improved (29% from 1982-90; 47% from 1991-4; 82% from 1995-2002). The authors attribute these improved results over the years to improved primary health-care facilities within the kingdom, earlier referrals, better equipment availability, and surgeons becoming more adept at surgical intervention. In contrast, CTTM for PCG was first performed at KKESH in 1994 with less of a "learning curve"; the success rate from 1994-2002 was 72%. The complication rate, however, was higher for CTTM than for trabeculotomy.

Because initial trabeculotomy success for PCG at KKESH has dramatically increased with time, it is important to know how many of the reported trabeculotomy failures for moderate and severe PCG were from the earlier periods in the hospital. This information was not in the paper. It may be that trabeculotomy as currently performed at KKESH for moderate and severe PCG has a success rate similar to that of CTTM for the same patient population with fewer surgical complications.

Correspondence to: A O Khan, King Khaled Eye Specialist Hospital, PO Box 7191, Riyadh, Saudi Arabia; arif.khan@mssm.edu

doi: 10.1136/bjo.2005.084871

Accepted for publication 11 October 2005

Reference

- 1 **Al-Hazmi A**, Awad A, Zwaan Z, et al. Correlation between surgical success rate and severity of congenital glaucoma. *Br J Ophthalmol* 2005;89:449-53.

CORRECTIONS

doi: 10.1136/bjo.2005.66431corr1

The letter titled, Bevacizumab suppresses choroidal neovascularisation caused by pathological myopia (*Br J Ophthalmol* 2005;10:1368-87), was previously published online at <http://bjo.bmjournals.com/cgi/content/full/89/6/e1>.

doi: 10.1136/bjo.2005.68171corr1

In the paper titled, The achiasmia spectrum: congenitally reduced chiasmal decussation (*Br J Ophthalmol* 2005;89:1311-17), one of the authors names has been misspelt. The correct list of authors is, D A Sami, D Saunders, D A Thompson, I M Russell-Eggitt, K K Nischal, G Jeffrey, M Dattani, R A Clement, A Liasis, D S Taylor. The journal apologises for this error.

doi: 10.1136/bjo.2005.bj75184corr1

In the letter titled, Two novel mutations of connexion genes in Chinese families with autosomal dominant congenital nuclear cataract (*Br J Ophthalmol* 2005;11:1535-6), the authors have been listed incorrectly. The correct listing is, Z W Ma, J Q Zheng, J Li, X R Li, X Tang, X Y Yuan, X M Zhang, H M Sun.

doi: 10.1136/bjo.2005.bj82453corr1

In the mailbox item titled, TTT: local light absorption and heat convection versus heat (*Br J Ophthalmol* 2005;11:1544-5), the second author's name has been misspelt. The correct spelling is D H Sliney. The journal apologises for this error.

doi: 10.1136/bjo.2005.bj74468corr1

In the letter titled, Confocal microscopy of the cornea in nephropathic cystinosis (*Br J Ophthalmol* 2005;89:1530-1), the order of the authors is incorrect. The correct order is A H Alsuhaibani, A O Kahn, M D Wagoner. The journal apologises for this error.

NOTICES

World Ophthalmology Congress 2006 – Brazil

The World Ophthalmology Congress (which is replacing the International Congress of Ophthalmology) is meeting in February 2006 in Brazil.

For further information on the congress and committees, scientific program and coordinators of different areas are available at the congress website www.ophthalmology2006.com.br

19th International Society for Geographical & Epidemiological Ophthalmology Congress

The 19th ISGEO congress will be held in Sao Paulo, Brazil on 18-19 February, 2006, just prior to the ICO. Abstract submission and registration forms can be obtained by emailing Dr Paul Courtright (pcourtright@kcco.net) or by accessing the ISGEO website at www.kcco.net/isgeo.

EYE INJURIES

The latest issue of *Community Eye Health* (No 55) discussed the assessment and management of eye injuries in the developing world. For further information please contact: Journal of Community Eye Health, International Resource Centre, International Centre for Eye Health, Department of Infectious and Tropical Diseases, London School of Hygiene and Tropical Medicine, Keppel Street, London WC1E 7HT, UK (tel: +44 (0)20 7612 7964; email: Anita.Shah@lshtm.ac.uk; online edition: www.jceh.co.uk). Annual subscription (4 issues) UK £28/US\$45. Free to developing country applicants.

8th EUNOS Meeting – 2007

The 2007 European Neuro-ophthalmology Society meeting (EUNOS; www.eunos.web.org) will be taking place in Istanbul, Turkey on 26-29th May 2007. For further information please visit www.eunos2007.org, email: or contact Pinar Aydin aydinp@eunos2007.org.

Teaching courses on Retinal and Vitreous Surgery

Several teaching courses on Retinal and Vitreous Surgery have been organised throughout 2006 and 2007 around the world in association with the International Faculty. For further information on each of these courses please contact Ingrid Kressig, Univ. Augenklinik Theodor-Kutzer-Ufer 1-3, 68164 Mannheim, Germany; email: Ingrid.kreissig@augen.ma.uni-heidelberg.de; website: <http://kressig.uni-hd.de/>.