

million people are infected with trachoma. Five million people are infected with its late stages and two million are blind because of it.

The trachoma biovar of *C trachomatis* can be subdivided into 15 serovars which are designated by the letters A–K based on the polymorphism in the sequence of the major outer membrane protein.^{2,3} Serovars A–C can usually be isolated from patients with clinical trachoma in regions where trachoma is endemic.

Oculogenital infection caused by serovars D–K is common in developed countries and leads to inclusion conjunctivitis, also called paratrachoma. Up to 90% have concurrent urogenital infections.

Although the different groups of serovars display unique tissue tropisms, they are not tissue selective, and serovars D–F, J and K have all been isolated from conjunctival swabs taken from individuals with typical clinical signs of active trachoma.^{4–7} However, all these reports are from areas where trachoma is endemic.

Therefore, the traditional distinction between ocular and genital strains may have to be reconsidered.

Clinically, it is difficult to diagnose the beginning of trachoma or inclusion body conjunctivitis, and it is only by laboratory testing that the diagnosis can be confirmed. Among the available assays, nucleic acid amplification tests have proven superior in detecting, quantifying and genotyping *C. trachomatis*.⁸ Because chlamydia is an intracellular organism, the correct swab technique is very important to obtain a positive test result. This includes firm rubbing with the swab in the fornix, which is unpleasant for the patient. Because chlamydial infection is frequently oligosymptomatic and routine laboratory screening is seldom not readily available for the ophthalmologist practitioner, the diagnosis of the disease is often delayed or even missed. Additionally, repeated reinfection occurs when the sexual partner is not treated as well.

These difficulties lead to a prolonged course of the infection and possibly to scarring due to chronic inflammation and repeated reinfections. Unfortunately, we were not able to differentiate the serovar of the *C trachomatis* isolate in our case, as serotyping is not routinely performed in Switzerland. However, the advanced clinical findings leading to entropion necessitating surgery emphasise not only the need for early diagnosis and treatment of this disease but also the need for thorough clinical examination including eversion of the upper lid and inspection of the tarsal conjunctiva in any patient with conjunctivitis.

Martin Zinkernagel, Elena Catalano, Dagmar Ammann-Rauch, Martin Zinkernagel, Elena Catalano, Dagmar Ammann-Rauch
Department of Ophthalmology, Cantonal Hospital St Gallen, St Gallen, Switzerland

Correspondence to: Dr M Zinkernagel, Department of Ophthalmology, Cantonal Hospital St Gallen, 9007 St Gallen, Switzerland; martin.zinkernagel@kssg.ch

Informed consent was obtained for publication of the person's details in this report.

doi: 10.1136/bjo.2006.101295

Accepted 6 August 2006

References

- 1 **MacCallan AF**. The epidemiology of trachoma. *Br J Ophthalmol* 1931;**15**:369–411.
- 2 **Solomon A**, Peeling R, Foster A, *et al*. Diagnosis and assessment of trachoma. *Clin Microbiol Rev* 2004;**17**:982–1011.
- 3 **Hayes LJ**, Pecharatana S, Bailey RL, *et al*. Extent and kinetics of genetic change in the *omp1* gene of *Chlamydia trachomatis* in two villages with endemic trachoma. *J Infect Dis* 1995;**172**:268–72.
- 4 **Brunham RC**, Laga M, Simonsen JN, *et al*. The prevalence of *Chlamydia trachomatis* infection among mothers of children with trachoma. *Am J of Epidemiol* 1990;**132**:946–52.
- 5 **Harrison HR**, Boyce WT, Wang SP, *et al*. Infection with *Chlamydia trachomatis* immunotype J associated with trachoma in children in an area previously endemic for trachoma. *J Infect Dis* 1985;**151**:1034–6.
- 6 **Mabey DC**, Forsey T, Treharne JD. Serotypes of *Chlamydia trachomatis* in the Gambia. *Lancet* 1987;**22**:452.
- 7 **Ballard RC**, Fehler HG, Fotheringham P, *et al*. Trachoma in South Africa. *Soc Sci Med* 1983;**17**:1755–65.
- 8 **Frost EH**, Deslandes S, Bourgaux-Ramoisy D. *Chlamydia trachomatis* serovars in 435 urogenital specimens typed by restriction endonuclease analysis of amplified DNA. *J Infect Dis* 1993;**168**:497–501.

CORRECTIONS

doi: 10.1136/bjo.2006.102541corr1

Several errors occurred in the paper titled, Linezolid-induced optic neuropathy: a mitochondrial disorder? (*Br J Ophthalmol* 2007;**91**:111–5). A fully corrected pdf is available online at <http://bjo.bmj.com/>. The journal apologises for these errors.

doi: 10.1136/bjo.2006.93856corr1

In the paper titled, Plasma apolipoproteins and risk for age-related maculopathy (*Br J Ophthalmol* 2006;**90**:1028–33) previous literature has been incorrectly cited within the text.

In second paragraph of the Discussion section (page 1030, right column), the authors refer to "large associations between neovascularisation and plasma cholesterol (OR = 4.1) in the Eye Disease Case Control Study (EDCCS)⁴⁸ and neovascularisation and apoB (OR = 9.2) in the Beaver Dam Eye Study (BDES).⁴⁹" Further on in the same paragraph, we state, "It is not clear why the EDCCS and BDES obtained the strong effects they did".

In both cases these results were incorrectly attributed to the BDES. These two sentences should have instead cited Reference 79, which pertains to data from the NHANES III study. Citations to References 49 (BDES) and 79 (NHANES II) are correct in the 3 tables.

PERSPECTIVE

Linezolid-induced optic neuropathy: a mitochondrial disorder?

M Javaheri, R N Khurana, T M O'Hearn, M M Lai, A A Sadun

Br J Ophthalmol 2007;91:111–115. doi: 10.1136/bjo.2006.102541

We report a case of bilateral optic neuropathies secondary to long-term linezolid treatment, show the nature of recovery, review the findings in the literature and propose a potential mitochondrial mechanism for linezolid-induced optic neuropathy. This is an observational case report and literature review with presentation of the clinical course of linezolid optic neuropathies through clinical and psychophysical documentation. Main outcome measures included: visual acuity, funduscopic examinations and peripapillary retinal nerve fibre layer (PRNFL) optical coherence tomography (OCT). A 6-year-old boy presented with bilateral optic neuropathies secondary to 1 year of linezolid treatment for osteomyelitis of the mandible. On presentation, visual acuities were 20/400 in both eyes, with considerable optic disc oedema, hyperaemia and PRNFL swelling confirmed by OCT. 2 weeks after the discontinuation of linezolid, visual acuities returned to 20/25 in both eyes, with reduction in the optic disc oedema, hyperaemia and PRNFL swelling. 3 months after the discontinuation of linezolid treatment, visual acuities were stable at 20/20 in both eyes, with a marked decrease in PRNFL swelling confirmed by OCT, and the development of mild temporal optic disc pallor in both eyes. Doctors should be aware of impairments of vision among patients on long-term linezolid treatment and promptly discontinue treatment to prevent irreversible vision loss. The development and resolution of bilateral optic neuropathies with considerable PRNFL swelling in this patient provide insight into the more general rubric of mitochondrial optic neuropathies.

linezolid treatment has been established for use only up to 28 days.^{6,7} Optic and peripheral neuropathies have been reported in patients with prolonged use outside the 28-day window. Investigators have postulated mitochondrial dysfunction as a possible aetiology, but the exact mechanism leading to linezolid-induced optic neuropathy (LION) is still unknown.^{8–16} Here, we report a case of reversible bilateral optic neuropathies in a 6-year-old boy undergoing treatment with linezolid for MRSA osteomyelitis of the jaw, review the findings in the literature and propose a potential mitochondrial mechanism for LION.

CASE REPORT

A 6-year-old Vietnamese boy presented with a 2-month history of painless, decreased vision in both eyes. Medical history included long-standing MRSA osteomyelitis of the right mandible. Current drugs included oral metronidazole (125 mg daily) and linezolid (170 mg twice daily); he was allergic to penicillin and vancomycin. Linezolid treatment had been going on for 1 year. Best-corrected visual acuity (BCVA) values were 20/400 in both eyes. Ishihara colour plates showed decreased colour vision in both eyes (2 of 15 plates OU). Brightness sense was subjectively diminished in both eyes. Pupils were round and reactive with no relative afferent pupillary defect. The anterior segment examination was unremarkable. Examination of the optic discs was remarkable for moderate bilateral, symmetrical optic disc hyperaemia, optic disc swelling, peripapillary retinal nerve fibre layer (PRNFL) swelling and vessel tortuosity (fig 1A). Dilated fundus examination was otherwise unremarkable. Fluorescein angiography did not show any optic disc leakage. The patient was unable to perform a reliable Humphrey visual field examination. Neurological examination was unremarkable.

Results of the initial laboratory tests were normal, including serum folate, thiamine, serum lead, computed tomography of the head and lumbar puncture with normal opening pressures. The patient was then diagnosed with bilateral optic neuropathies induced by long-term linezolid treatment. Linezolid treatment was discontinued

Abbreviations: BCVA, best-corrected visual acuity; LHON, Leber's hereditary optic neuropathy; LION, linezolid-induced optic neuropathy; MRSA, methicillin-resistant *Staphylococcus aureus*; OCT, optical coherence tomography; PMB, papillomacular bundle; PRNFL, peripapillary retinal nerve fibre layer; RGC, retinal ganglion cell; ROS, reactive oxygen species

With the emergence of methicillin-resistant *Staphylococcus aureus* (MRSA) and vancomycin-resistant *Enterococcus*, the treatment of complicated joint infections, osteomyelitis, skin infections and nosocomial pneumonias has become increasingly problematic.^{1–3} Linezolid (Zyvox, Pfizer, New York, New York, USA) was introduced in 2000 as the first member of the new oxazolidinone synthetic group of antibiotics to help treat patients with these drug-resistant pathogens. Linezolid acts through inhibiting protein synthesis by binding specifically to the bacterial 50S ribosomal subunit, thereby inhibiting the formation of a viable initiation complex.^{4,5}

Linezolid is usually well tolerated, with few described adverse effects.⁶ However, the safety of

See end of article for authors' affiliations

Correspondence to:
Dr A A Sadun, Department of Ophthalmology, Doheny Eye Institute, Keck School of Medicine, University of Southern California, 1450 San Pablo Street DEI 5802, Los Angeles, CA 90033, USA; asadun@usc.edu

Accepted 3 August 2006

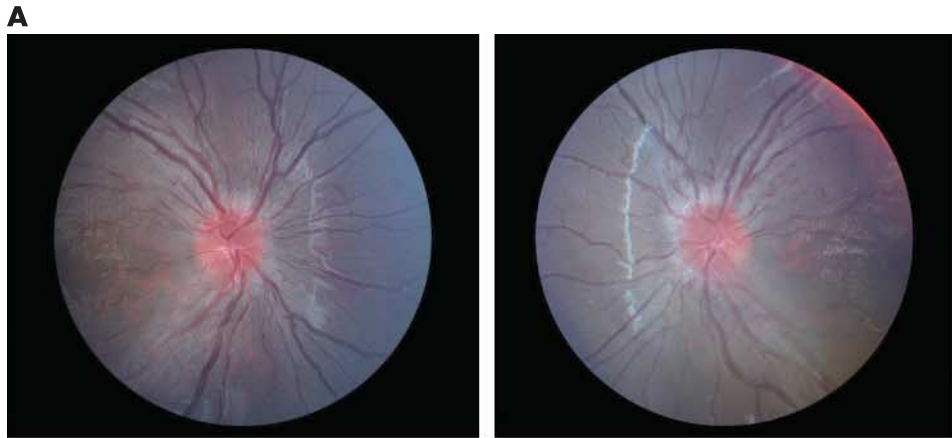
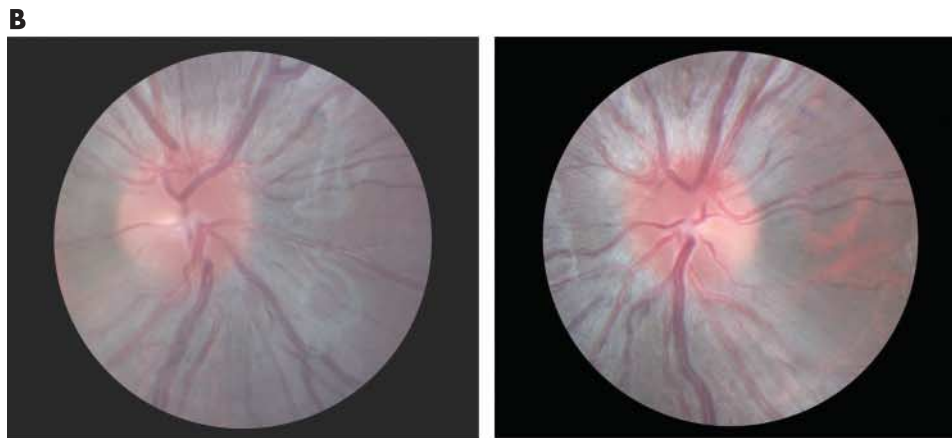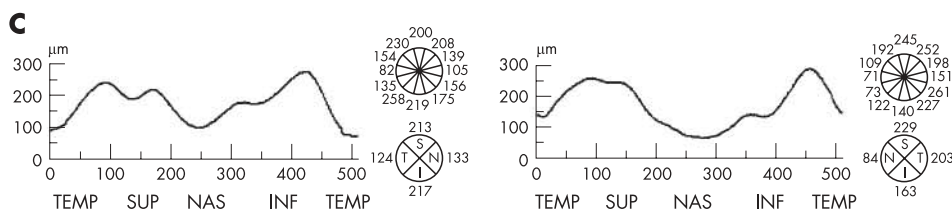


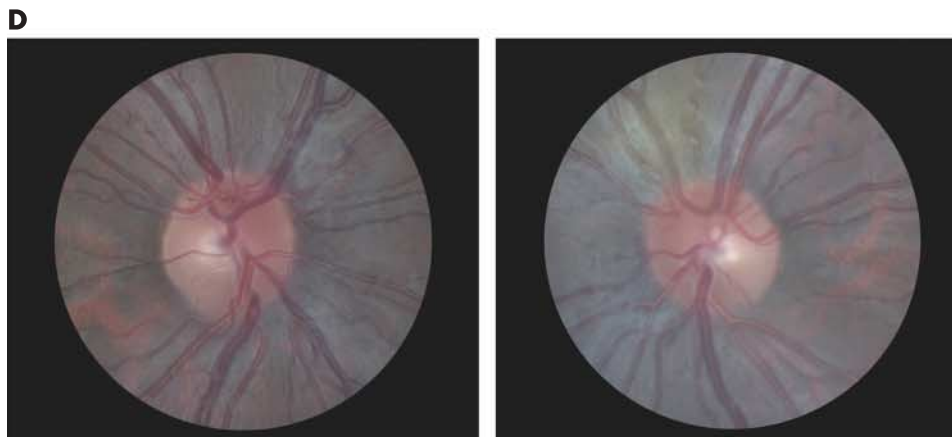
Figure 1 (A) Fundus photographs of our patient on presentation after 1 year of treatment with linezolid. Visual acuity was 20/400 in both eyes. Bilaterally, symmetrical moderate optic disc swelling, optic disc hyperaemia, swelling of the peripapillary retinal nerve fibre layer (PRNFL) and vessel tortuosity are seen.



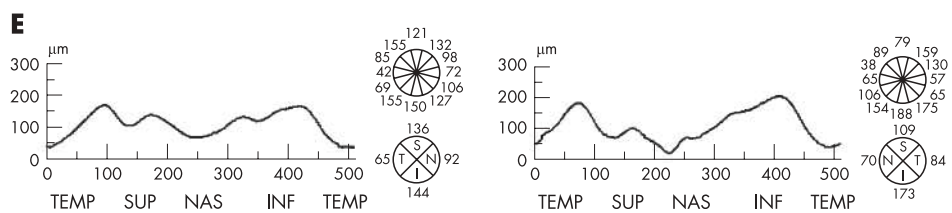
(B) Disc photographs of our patient 2 weeks after discontinuing treatment with linezolid. Visual acuity was 20/25 in both eyes. Bilaterally, a slightly decreased symmetrical optic disc swelling, optic disc hyperaemia, swelling of the PRNFL and vessel tortuosity are seen. Temporal optic disc pallor can be seen bilaterally.



(C) PRNFL optical coherence tomography (OCT) of our patient 2 weeks after discontinuing treatment with linezolid showed an increased 360° average measurement (171.84 µm right eye (OD), 170.00 µm left eye (OS)), with significant increase in thickness detected in the temporal (TEMP), superior (SUP) and inferior (INF) quadrants in both eyes, and in the nasal (NAS) quadrant of the right eye.



(D) Disc photographs of our patient 3 months after discontinuing treatment with linezolid. Visual acuity was 20/20 in both eyes. Bilaterally, a marked decrease in symmetrical optic disc swelling, optic disc hyperaemia, swelling of the PRNFL and vessel tortuosity can be seen. Temporal optic disc pallor is still evident bilaterally.



(E) PRNFL OCT of our patient 3 months after discontinuing treatment with linezolid, showing a marked decrease in the 360° average measurement (109.30 µm OD, 108.87 µm OS), with notable decreases in thickness detected in the temporal, superior and inferior quadrants in both eyes, and in the nasal quadrant of the right eye.

in favour of clindamycin. Two weeks later, BCVAs were 20/25 in both eyes. Ishihara colour plates also showed an improvement in colour vision in both eyes (9 of 15 plates OU). Brightness sense was equal and subjectively improved in both eyes. Examination of the optic discs was remarkable for decreased optic disc hyperaemia, trace optic disc swelling, decreased PRNFL swelling and minimal vessel tortuosity in both eyes. Temporal optic disc pallor was now evident in both eyes (fig 1B). Dilated fundus examination was otherwise unremarkable. A PRNFL scan by optical coherence tomography (OCT; Stratus OCT, Carl Zeiss Ophthalmic Systems, Dublin, California, USA) was conducted and showed an increased 360° average measurement (171.84 µm right eye (OD), 170 µm left eye (OS)). A considerable increase was detected in PRNFL thickness in the temporal (124 µm OD and 203 µm OS), superior (213 µm OD and 229 µm OS), inferior (217 µm OD and 163 µm OS) and nasal (133 µm OD) quadrants (fig 1C).

Three months after discontinuation of treatment, BCVA improved slightly to 20/20 in both eyes, with stable colour vision shown by Ishihara colour plates (9 of 15 OU). Examination of the optic discs was remarkable for markedly decreased optic disc hyperaemia, the absence of optic disc swelling, decreased PRNFL swelling and an absence of vessel tortuosity in both eyes (fig 1D). Dilated fundus examination was otherwise unremarkable. PRNFL scan by OCT was carried out and showed a marked decrease in the 360° average measurement (109.30 µm OD, 108.87 µm OS). Marked decreases in thickness were detected in the temporal (65 µm OD and 64 µm OS), superior (136 µm OD and 109 µm OS), inferior (144 µm OD) and nasal (92 µm OD) quadrants. Other quadrants remained stable (fig 1E). At the time of submission of this report, the patient had been stable for >9 months.

DISCUSSION

Linezolid represents the first member of the synthetic oxazolidinone group of antimicrobials designed to treat MRSA and vancomycin-resistant *Enterococcus*, and is well tolerated when used for <28 days.⁴⁻⁷ The safety of linezolid has not been established beyond 28 days, and all reported cases of optic and peripheral neuropathies have occurred with use outside of the 28-day window.⁸⁻¹⁶ Recent studies have also shown that linezolid has excellent posterior segment penetration, reaching inhibitory concentrations above the minimum inhibitory concentrations for most Gram-positive pathogens within 4 h after a single oral dose (600 mg) in both aqueous and vitreous samples.⁵

Reports of at least 12 patients with LION have been published; the presenting symptoms, duration, treatment and results have varied (table 1).⁸⁻¹⁵ In previously reported cases, the duration of treatment varied from 5 to 44 months at doses of 600 mg once or twice per day. Typical clinical findings at the time of diagnosis include bilateral decreases in visual acuities, BCVA ranging from 20/60 to counting fingers, caecocentral and arcuate visual field defects, and temporal pallor of the optic discs.⁸⁻¹⁵ Only two previous articles reported optic disc oedema or temporal PRNFL defects.¹²⁻¹⁵ Some reports did not describe any objective findings from the clinical examination.⁸⁻¹⁰ None of the previous reports described PRNFL swellings and only one showed a PRNFL OCT.⁸⁻¹⁵

Characteristic features of all the reported patients include the long-term use of linezolid and some visual recovery after discontinuation of the antibiotic. Among the 13 patients (including the current report), the median duration of linezolid treatment was 280 days (range 120–1505 days), well outside the 28-day safety window recommended by the manufacturer. Interestingly, 8 of 13 (62%) patients had osteomyelitis or infected prosthetic hardware that required chronic antibiotic

treatment. These infections are often challenging, as they are indolent, involve bacteria that are drug resistant and require long-term antibiotic use. Termination of linezolid treatment resulted in dramatic and rapid improvement in visual status in all of the patients. It is interesting that 3 of the 12 patients received a steroid pulse treatment that either had no effect or worsened the visual field or visual acuity and delayed the visual recovery in two patients.⁸⁻¹⁶

All cells depend on mitochondria for oxidative metabolism. However, the optic nerve may be particularly sensitive to mitochondrial dysfunction, as evidenced by a wide category of optic neuropathies of both genetic and acquired origin, which share common clinical features and produce mitochondrial impairment.¹⁷⁻¹⁹ Retinal ganglion cells (RGCs) contribute axons, which travel together in the retinal nerve fibre layer towards the optic nerve. These axons are rich in mitochondria, especially in the unmyelinated intraocular and prelaminar region (and in the postlaminar region at the nodes of Ranvier); these have been interpreted as sites with high energy demands.²⁰ These axons are myelinated by oligodendroglia posterior to the lamina cribrosa, and thereby enjoy the efficiency of salutatory conduction.²¹

To maintain their transparency, the prelaminar axons of the RGCs are unmyelinated and hence have slower conduction velocities when compared with the postlaminar myelinated portion of the same axons.¹⁸ However, it is the ubiquitous presence of sodium and potassium channels that gives the unmyelinated portion the considerably greater energy required to maintain the electrical potential at resting states.²² These observations are supported by electron microscopy studies showing an inverse relationship between the presence of mitochondria and myelination, and immunohistochemical studies indicating decreased cytochrome *c* oxidase staining, a marker of oxidative phosphorylation, posterior to the lamina cribrosa when compared with prelaminar RGC axons.²³⁻²⁵ Therefore, RGCs with their long unmyelinated but active axons have a spatial dependence on mitochondria.

The papillomacular bundle (PMB) is composed mostly of parvocellular neurones, with few magnocellular neurones, both with considerably smaller-calibre RGCs.²⁶ The smaller size of these PMB axons (down to 0.6 µm in diameter) represents a physical limit to the axoplasmic transport of mitochondria, which average 0.5 µm in diameter. However, in so far as the mitochondria are created and replicated only in the soma, the RGCs must transport and distribute these mitochondria in an energy-dependent fashion along the optic nerve, all the way to the synaptic terminals, doing so within the short lifetime of the mitochondria (7–10 days).¹⁸⁻²⁷

Linezolid is designed to inhibit protein synthesis by binding specifically to 23S rRNA of the 50S ribosomal subunit and inhibiting the formation of a viable initiation complex, thereby inhibiting bacterial protein synthesis.⁴ Mammalian ribosomes lack the 50S component, and hence linezolid produces little effect on normal mammalian protein synthesis. Unfortunately, mitochondria in mammalian cells remain vulnerable as they contain DNA and use ribosomes that more closely approximate that of bacteria.¹⁷⁻¹⁹ Long-term linezolid use has shown to interfere with bacterial ribosomes and possibly also with mitochondrial ribosomes, disrupting protein synthesis in mitochondria. This process can theoretically mimic the respiratory chain dysfunction seen in the mitochondrial optic neuropathies and produce an optic neuropathy similar, for example, to that seen in patients with Leber's hereditary optic neuropathy (LHON). Ophthalmoscopic features of the acute phase of LHON include teleangiectatic microangiopathy, vessel tortuosity and PRNFL swelling, particularly involving the PMB. In addition, the optic disc appears hyperaemic and swollen, but no leakage is noted in fluorescein angiography.¹⁷⁻¹⁹⁻²⁸

Table 1 Previously reported cases of linezolid-induced optic neuropathy

Reference	Number of patients	Age (years)	Indication for linezolid/ dosage	Duration of linezolid treatment (days)		Fundus findings at diagnosis	Visual field findings (at diagnosis)	BCVA (OD/OS)		Ancillary treatments
				Before onset of symptoms	Before cessation			At cessation	At last follow-up	
Corallo and Paull ⁸	1	76	Prosthetic joint (MRSA)/600 PO bid	168	168	Not recorded	Not recorded	Not recorded	Not recorded	None
Lee <i>et al</i> ⁹	2 (Patient 1)	71	Prosthetic joint (MRSA)	280	NR	Temporal optic nerve pallor OU, mild hyperreflexive retinopathy	Bilateral defects	20/200 OU	20/30, 20/25 (9 month f/u)	None
(Patient 2)		45	Infected spinal orthopaedic hardware (MRSA)	280	308	Infero-temporal pallor of optic nerves OU	Bilateral defects	20/80 OU	20/30, 20/40 (6 months)	Short course of steroid treatment
Frippiat <i>et al</i> ¹⁰	1	72	Prosthetic joint infection (MRSE, VRE)	287	308	Normal OU	Not performed	Not reported	Not reported	Methylprednisolone 1 g/day × 5 days
McKinley and Foroozan ¹¹	2 (Patient 1)	75	Pneumonia (<i>Mycobacterium abscesses</i>)	308	448	Normal optic nerve OD, slight temporal pallor OS	Caecentral and arcuate defects OU	20/400, CF at 4 feet	20/25, 20/30 (4 months)	None
(Patient 2)		73	Pneumonia (<i>Mycobacterium avium</i>)	224	308	Normal optic nerves OU	Caecentral and arcuate defects OU	20/100 OU	20/40, 20/25 (3 months)	None
Saijo <i>et al</i> ¹²	1	27	Osteomyelitis (MRSA)	154	194	Moderate disc oedema OU	Central scotomas OU	20/200, 20/400	20/20 OU	Methylprednisolone pulses on days 171, 172, 180
Kulkarni and Del Priore ¹³	1	56	Osteomyelitis (MRSA)/600 mg PO bid	1505	365 (bid)/1320 (qd)	Temporal pallor OU, small NFL defect OD > OS	Central scotomas OU	20/400 OU	20/40 OU	None
Rucker <i>et al</i> ¹⁴	3 (Patient 1)	40	MRSA wound infection and frontal lobe abscess/600 mg PO bid	180	180	Mild disc elevation	Caecentral OD (monocular) scotoma OD	20/200 OD	20/40 OD (4 months)	None
(Patient 2)		66	MRSA bacteraemia/600 mg PO bid	150	150	Disk swelling, peripapillary haemorrhages OU	Caecentral scotoma OS	20/70 OD	20/25 OD	None
(Patient 3)		79	MRSA wound infection/600 mg PO bid	300	300	Mild disk pallor OU	Central scotoma OU	20/60 OS	20/20 OS (3 months)	None
De Vriese <i>et al</i> ¹⁵	1	63	MRSA-infected prosthetic joint/600 mg PO bid	120	120	Pale discs with narrowed retinal vessels OU	Not performed	CF OD (Hx Amblyopia) 20/400 OS	CF OD, 20/30 OS (6 months)	None
							Not reported	Not reported	Not reported	None

BCVA, best corrected visual acuity; bid, twice daily; f/u, follow-up; MRSA, methicillin-resistant *Staphylococcus aureus*; NFL, nerve fibre layer; OD, right eye; OS, left eye; qd, daily; VRE, vancomycin-resistant *Enterococcus*.

Mitochondria, through their respiratory chain, are the major source of cellular reactive oxygen species (ROS) as a byproduct of ATP synthesis. The disruption of oxidative phosphorylation at any step in the respiratory chain leads to considerable energy depletion coupled with the accumulation of ROS in the RGCs. This accumulation of ROS lowers the electrical potential across the mitochondrial membrane and this opens the mitochondrial permeability transition pores, which acts as an apoptotic switch by releasing factors promoting cell death such as cytochrome *c*.²⁹⁻³⁰ This mitochondrial dysfunction may also trigger compensating increases in mitochondria, manifesting on OCT as retinal nerve fibre oedema.³¹

Previous reports showed a lack of response to corticosteroids in patients with optic neuropathy secondary to linezolid and further showed that steroid pulses worsened the visual field or visual acuity in two reported patients.¹⁰⁻¹² Linezolid creates noticeable RGC intraxonal swelling, which would not be responsive to corticosteroids.³² In addition, corticosteroids can exacerbate mitochondrial dysfunction, thereby uncoupling oxidative phosphorylation, lowering ATP phosphorylation and aggravating energy deficits.³³

Recently, De Vriese *et al*¹⁵ reported a patient with LION in whom they analysed the patient's muscle, kidney and liver samples for potential mitochondrial abnormalities. No major histological changes were found, but a marked decrease in the activity of complexes I and IV was noted in each tissue type by spectrophotometric assays. Similar results were also observed in experimental rats treated with linezolid for at least 2 weeks, with decreased protein levels of multiple complexes observed relative to control samples.¹⁵ Although these results are preliminary, they support the hypothesis that mitochondrial function is compromised with long-term linezolid treatment.

The patient in our study has clinical findings that included marked optic disc swelling and notable PRNFL swelling. This case is the first to quantify PRNFL layer swelling as a result of linezolid-induced mitochondrial optic neuropathy, and to show resolution of the swelling after cessation of linezolid treatment. Consistent with previous reports, our patient showed toxicity only after long-term treatment.⁸⁻¹⁶ Few patients develop this optic neuropathy from linezolid use as a consequence of this unusual long-term treatment, possibly reflecting a yet undetermined genetic susceptibility.

The clinical presentation of LION is similar to that seen in toxic, metabolic, and Cuban epidemic, pharmaceutical neuropathy and LHON.^{17-19, 26-28} This is not surprising as in all of these conditions, including long-term linezolid use, mitochondria may be compromised. It is important for ophthalmologists to evaluate and follow-up patients taking long-term linezolid treatment (outside the 28-day US Food and Drug Administration-recommended period), especially those with visual complaints. Once promptly recognised, immediate cessation of treatment may enable full visual recovery. A prospective, longitudinal study including patients already taking long-term linezolid is warranted to fully evaluate the clinical characteristics of LION, and to apply psychophysical and imaging measures for the early detection, characterisation and monitoring of subclinical evidence of optic nerve dysfunction.

Authors' affiliations

M Javaheri, R N Khurana, T M O'Hearn, M M Lai, A A Sadun, Department of Ophthalmology, Doheny Eye Institute, Keck School of Medicine, University of Southern California, Los Angeles, California, USA

Competing interests: None.

REFERENCES

- 1 Menichetti F. Current and emerging serious Gram-positive infections. *Clin Microbiol Infect* 2005;**11**:22-8.
- 2 Mascini EM, Bonten MJ. Vancomycin-resistant enterococci: consequences for therapy and infection control. *Clin Microbiol Infect* 2005;**11**:43-56.
- 3 Fridkin SK, Hageman JC, Morrison M, *et al*. Active Bacterial Core Surveillance Program of the Emerging Infections Program Network. Methicillin-resistant *Staphylococcus aureus* disease in three communities. *N Engl J Med* 2005;**352**:1436-44.
- 4 Perry CM, Jarvis B. Linezolid: a review of its use in the management of serious Gram-positive infections. *Drug* 2001;**61**:525-51.
- 5 Fiscella RG, Lai WW, Buerk B, *et al*. Aqueous and vitreous penetration of linezolid (Zyvox) after oral administration. *Ophthalmology* 2004;**111**:1191-5.
- 6 Birmingham MC, Rayner CR, Meagher AK, *et al*. Linezolid for the treatment of multidrug-resistant, Gram-positive infections: experience from a compassionate-use program. *Clin Infect Dis* 2003;**36**:159-68.
- 7 Zyvox (linezolid) product information. Rydalmere, NSW: Pharmacia Australia 2002.
- 8 Corallo CE, Paull AE. Linezolid-induced neuropathy. *Med J Aust* 2002;**16**:332.
- 9 Lee E, Burger S, Shah J, *et al*. Linezolid-associated toxic optic neuropathy: a report of 2 cases. *Clin Infect Dis* 2003;**37**:1389-91.
- 10 Frippiat F, Bergiers C, Michel C, *et al*. Severe bilateral optic neuritis associated with prolonged linezolid therapy. *J Antimicrob Chemother* 2004;**53**:1114-15.
- 11 McKinley SH, Foroosan R. Optic neuropathy associated with linezolid treatment. *J Neuroophthalmol* 2005;**25**:18-21.
- 12 Saijo T, Hayashi K, Yamada H, *et al*. Linezolid-induced optic neuropathy. *Am J Ophthalmol* 2005;**139**:1114-16.
- 13 Kulkarni K, Del Priore LV. Linezolid induced toxic optic neuropathy. *Br J Ophthalmol* 2005;**89**:1664-5.
- 14 Rucker JC, Hamilton SR, Bardenstein D, *et al*. Linezolid-associated toxic optic neuropathy. *Neurology* 2006;**66**:595-8.
- 15 De Vriese AS, Coster RV, Smet J, *et al*. Linezolid-induced inhibition of mitochondrial protein synthesis. *Clin Infect Dis* 2006;**42**:1111-17.
- 16 Bressler AM, Zimmer SM, Gilmore JL, *et al*. Peripheral neuropathy associated with prolonged use of linezolid. *Lancet Infect Dis* 2004;**4**:528-31.
- 17 Sadun AA. Metabolic optic neuropathies. *Semin Ophthalmol* 2002;**17**:29-32.
- 18 Carelli V, Ross-Cisneros FN, Sadun AA. Mitochondrial dysfunction as a cause of optic neuropathies. *Prog Retin Eye Res* 2004;**23**:53-89.
- 19 Sadun AA, Carelli V. Mitochondrial function and dysfunction within the optic nerve. *Arch Ophthalmol* 2003;**121**:1342-3.
- 20 Wang L, Dong J, Cull G, *et al*. Varicosities of intraretinal ganglion cell axons in human and nonhuman primates. *Invest Ophthalmol Vis Sci* 2003;**44**:2-9.
- 21 Glaser JS, Sadun AA. Anatomy of the visual sensory system. In: Gasser JS, ed. *Neuro-Ophthalmology*. Philadelphia: JB Lippincott, 1990:61-82.
- 22 Waxman SG. Prerequisites for conduction in demyelinated fibers. *Neurology* 1977;**28**:27-33.
- 23 Andrews RM, Griffiths PG, Johnson MA, *et al*. Histochemical localisation of mitochondrial enzyme activity in human optic nerve and retina. *Br J Ophthalmol* 1999;**83**:231-5.
- 24 Bristow EA, Griffiths PG, Andrews RM, *et al*. The distribution of mitochondrial activity in relation to optic nerve structure. *Arch Ophthalmol* 2002;**120**:791-6.
- 25 Minkler DS, McLean IW, Tso MO. Distribution of axonal and glial elements in the rhesus optic nerve head studied by electron microscopy. *Am J Ophthalmol* 1976;**82**:179-87.
- 26 Sadun AA, Win PH, Ross-Cisneros F, *et al*. Leber's hereditary optic neuropathy differentially affects smaller axons in the optic nerve. *Trans Am Ophthalmol* 2000;**98**:223-32.
- 27 Grafstein B. Axonal transport: function and mechanisms. In: Waxman SG, Kocsis JD, Stys PK, eds. *The axon: structure, function and pathophysiology*. Oxford: Oxford University Press, 1995:185-99.
- 28 Sadun AA, Carelli V, Salomao SR, *et al*. Extensive investigation of a large Brazilian pedigree of 11778/haplogroup J Leber hereditary optic neuropathy. *Am J Ophthalmol* 2003;**136**:231-8.
- 29 Yu Wai Man CY, Chinnery PF, Griffiths PG. Optic neuropathies—importance of spatial distribution of mitochondria as well as function. *Med Hypotheses* 2005;**65**:1038-42.
- 30 Wallace DC. Animal models for mitochondrial disease. *Methods Mol Biol* 2002;**197**:3-54.
- 31 Savini G, Zanini M, Carelli V, *et al*. Correlation between retinal nerve fibre layer thickness and optic nerve head size: an optical coherence tomography study. *Br J Ophthalmol* 2005;**89**:489-92.
- 32 Lee H, Shah GK. Intravitreal triamcinolone as primary treatment of cystoid macular edema secondary to branch retinal vein occlusion. *Retina* 2005;**25**:551-5.
- 33 Katyare SS, Balasubramanian S, Parmar DV. Effect of corticosterone treatment on mitochondrial oxidative energy metabolism in developing rat brain. *Exp Neurol* 2003;**183**:241-8.