



Photodynamic therapy combined with ranibizumab for polypoidal choroidal vasculopathy: results of a 1-year preliminary study

P Ruamviboonsuk,¹ M Tadarati,¹ S Vanichvaranont,¹ P Hanutsaha,² N Pokawattana¹

► Supplementary tables are published online only. To view these files please visit the journal online (<http://bj.o.bmj.com>).

¹Department of Ophthalmology, Faculty of Medicine, Rajavithi Hospital, Rangsit University, Bangkok, Thailand

²Department of Ophthalmology, Faculty of Medicine, Ramathibodi Hospital, Mahidol University, Bangkok, Thailand

Correspondence to

Dr Paisan Ruamviboonsuk, Department of Ophthalmology, Rajavithi Hospital, Bangkok 10400, Thailand; paisan@rajavithi.go.th

Accepted 31 January 2010

Published Online First
8 June 2010

ABSTRACT

Background/aims To determine the potential efficacy and safety of combined verteporfin photodynamic therapy (PDT) with ranibizumab for the treatment of polypoidal choroidal vasculopathy (PCV).

Methods In this prospective, non-comparative, interventional study, 12 eyes from 12 patients that had active PCV were treated with PDT combined with three monthly intravitreal injections of ranibizumab. The patients were then monitored monthly with measurements of best-corrected visual acuity (BCVA) and central retinal thickness quantified by optical coherence tomography for 1 year. Indocyanine green angiography (ICGA) and fluorescein angiography were performed every 3 months. The eyes were re-treated with PDT and a ranibizumab injection, or with solely ranibizumab injection when indicated.

Results At month 12, the mean BCVA change from baseline was +12.3 letters ($p=0.04$). Eight patients (58.3%, $p=0.02$) had a BCVA gain of 15 letters or more. One patient (8.3%, $p=1.0$) had a BCVA loss of 15 letters or more. All patients underwent regression of polyps without recurrence. One patient experienced an insignificant subretinal haemorrhage. No other adverse event that could be attributed to the treatment was observed.

Conclusions This combination therapy showed encouraging results concerning improving vision, reducing the incidence of subretinal haemorrhage and reducing the recurrence of polyps when compared to previously published data that reported PDT monotherapy for PCV.

Polypoidal choroidal vasculopathy (PCV) is a variation of choroidal neovascularisation (CNV), which is characterised by an abnormal-branching vascular network with polypoidal terminal bulbs in the inner choroids.¹ Data from interventional case series indicate that photodynamic therapy (PDT) with verteporfin may be an effective treatment for PCV.^{2–9} When the best-corrected visual acuity (BCVA) was assessed 1 year after treatment, approximately 25–50% of eyes with active PCV that were treated with PDT had improved visual acuity of more than three lines.^{2 5 6 9 10} PDT also induced the regression of polypoidal bulbs in up to 90% of eyes.^{5 7 8} Subretinal haemorrhage and recurrence of the polyp are potential complications of PDT, with their respective incidences ranging from 4.7% to 30.8%^{2 4–6 11} and from 4.5% to 50%^{2 5 6 8 9 11} over 1 year.

Vascular endothelial growth factor (VEGF) is an angiogenic signalling molecule triggered by tissue

ischaemia and/or inflammation. It is overexpressed in the retinal pigment epithelial (RPE) cells of areas affected by CNV.¹² The strong expression of VEGF has also been found in RPE and vascular endothelial cells in PCV lesions,¹³ and upregulation of VEGF has been demonstrated in the aqueous humour of eyes with active PCV.¹⁴ Another study, however, could not identify VEGF in vascular endothelial cells in PCV specimens, although VEGF was still found in RPE cells in these specimens.¹⁵

In two interventional case series,^{16 17} off-label intravitreal injections of bevacizumab, which is a full-length humanised antibody that inhibits all VEGF-A isoforms, were found to reduce the fluid leakage and exudative retinal detachment seen with PCV. This treatment, however, had only limited efficacy in inducing regression of the associated polyps, which were considered as mature vasculatures. In another small case series with a 4-month follow-up,¹⁸ three monthly injections of ranibizumab, a recombinant humanised IgG monoclonal antibody fragment that selectively binds to human VEGF-A, induced polyp regression in 9 out of 13 PCV lesions.

These data provide a rationale for combining an anti-VEGF agent with PDT for the treatment of PCV. In PDT monotherapy, the mechanism of selective photothrombosis¹⁹ causes regression of the polyp and allows pathological manifestations of PCV to improve gradually. Combining PDT with an anti-VEGF agent could create a synergistic effect, which induces polyp regression and reduces fluid leakage and inflammation. These effects would occur simultaneously, thereby enhancing the treatment benefits. Moreover, PDT was found to upregulate VEGF in eyes with CNV after treatment.²⁰ This upregulation may also result to increased complications or the recurrence of disease in eyes after treatment with PDT.

We conducted the preliminary study reported herein to evaluate the potential efficacy and safety of combining ranibizumab with PDT for the treatment of PCV.

METHODS

This prospective, consecutive, open-label, non-comparative, interventional study was conducted at the Eye Clinic of Rajavithi Hospital, Bangkok. The Ethical Committee on Research Involving Human Subjects of the same institution approved the study. The patients enrolled between June 2007 and March 2008. All patients gave written informed consent before they enrolled.

Patients and study design

Box 1 shows the inclusion and exclusion criteria for the study patients and eyes.

We conducted a comprehensive examination of the study eyes of each patient at the baseline assessment and during each subsequent monthly visit for 1 year. The examination included a BCVA measurement, three-dimensional dilated fundus examination, colour fundus photography and central retinal thickness (CRT) quantified by optical coherence tomography (OCT; Zeiss OCT Model 3000, Dublin, California, USA). We measured BCVA using the standard Early Treatment Diabetic Retinopathy Study visual acuity testing protocol, using as the score the total number of correct letters identified at 4 m plus 30 letters. If the patients read fewer than five letters correctly at 4 m, we tested them again at 1 m. We then calculated the scores from the total number of correct letters identified at 1 m. We performed fundus fluorescein angiography and indocyanine green angiography (ICGA) using a digital fundus camera (Topcon 501A, Topcon, Tokyo, Japan) or a scanning laser ophthalmoscope (Heidelberg Retinal Angiography II, Heidelberg, Germany) at the baseline examination and every 3 months thereafter.

Initial treatment

The initial treatment regimen consisted of a session of PDT (Visudyne; Novartis AG, Basel, Switzerland) guided by ICGA and an intravitreal injection of 0.5 mg ranibizumab (Lucentis; Genentech Inc, South San Francisco, CA) approximately 30 min after PDT, followed by additional intravitreal injections of ranibizumab each month over the next 2 months. The sequence of treatment on the first day, an injection of ranibizumab after a session of PDT, was based on the evidence that VEGF expression was enhanced in elderly human eyes after PDT.²⁰

We administered PDT according to the Treatment of Age-Related Macular Degeneration with Photodynamic Therapy study protocol.²¹ We determined the diameter of the laser spot size by adding 1000 µm to the greatest linear dimension of PCV lesions determined by ICGA. We then asked the patients to wear protective sunglasses and avoid exposure to sunlight for 48 h after receiving PDT.

We gave the intravitreal injection using standard protocols.²² We also prescribed the application of topical antibiotics for 3 days after each intravitreal injection.

Re-treatment

We re-treated the study eyes during follow-up visits when the previously treated area had one of the following: (1) an area of hyperfluorescence suggesting an active polyp on ICGA (the criteria for defining active polyps on ICGA were described elsewhere²³; an area of vascular network identified on ICGA was not re-treated if ICGA could not identify the associated active polyps and fluorescein angiography could not identify leakage); (2) an area of leakage demonstrated by fluorescein angiography although the polypoidal or the vascular network component of PCV could not be identified on ICGA; (3) a presence of intraretinal or subretinal fluid by OCT; or (4) an increase of CRT by OCT for 100 µm or more compared to the lowest previous CRT value. Only when these findings were not found did the ophthalmologists consider re-treatment of the eyes if they determined that re-treatment would be beneficial.

If the decision to re-treat was based on the ICGA or fluorescein angiography criteria, the re-treatment consisted of a session of PDT and an intravitreal injection of ranibizumab approximately 30 min after PDT. The PDT was guided by ICGA if polyps were identified, and by fluorescein angiography if fluo-

Box 1 Inclusion and exclusion criteria**The inclusion criteria***Patient criteria*

- (1) At least 50 years old.
- (2) Willing to participate in monthly follow-up visits for at least 1 year.

Eye criteria

- (1) Clinical presentation is compatible with neovascular AMD.
- (2) Baseline BCVA ranges from a letter score of 34–73 after testing using the Early Treatment Diabetic Retinopathy Study chart protocol.
- (3) Presence of polyps with or without an interconnecting vascular network identified using ICGA in the macular area, which is a characteristic of PCV. The presence of polyps identified on ICGA was described elsewhere.²³
- (4) Total lesion size identified by ICGA, including the vascular network and the terminal polyps, is less than 5400 µm in the greatest linear dimension.

The exclusion criteria*Patient criteria*

- (1) Previous systemic treatment with anti-angiogenic medications.
- (2) Hypersensitivity to verteporfin, ranibizumab, fluorescein or indocyanine green.
- (3) A diagnosis of porphyria.
- (4) Severe systemic diseases, including hepatic diseases.
- (5) Long-term (>6 months) use of systemic steroids (dose equivalent to 10 mg/day prednisolone or higher).
- (6) Use of other medications with ocular toxicity, such as deferoxamine, chloroquine, hydroxychloroquine, tamoxifen, phenothiazine or ethambutol.

Eye criteria

- (1) Previous treatment with anti-angiogenic medications, such as pegaptanib, ranibizumab, bevacizumab, anecortave or triamcinolone.
- (2) Previous treatment with photodynamic therapy, radiation, laser photocoagulation in the macular area, vitrectomy, transpupillary thermotherapy, penetrating keratoplasty or glaucoma surgery.
- (3) Previous complicated intraocular surgery less than 12 months ago or uncomplicated intraocular surgery less than 3 months ago.
- (4) Other serious ophthalmic diseases such as diabetic retinopathy, uncontrolled glaucoma, vitreous haemorrhage, retinal detachment, macular hole, significant cataract, nasolacrimal duct obstruction or active intraocular inflammation.
- (5) Specific diseases that cause choroidal neovascularisation such as angiod streaks, histoplasmosis, trauma and pathological myopia (>8.0 dioptres).
- (6) An area of scar tissue that accounts for ≥50% of the lesion of PCV.

AMD, age-related macular degeneration; BCVA, best-corrected visual acuity; ICGA, indocyanine green angiography; PCV, polypoid choroidal vasculopathy.

rescein angiography leakage was found without polyp identified on ICGA. If the decision to re-treat was based on the OCT criteria only, the re-treatment consisted solely of an injection of ranibizumab.

These indications for re-treatment are summarised in an additional table A1 (available online).

Table 1 Patient demographics and baseline characteristics

Demographics		n=12
Gender, n (%)		
Male		7 (58.3%)
Female		5 (41.7%)
Age, years		
Mean (SD)		66.8 (10.3)
Range		50–84
Age group, years, n (%)		
50–59		4 (33.3%)
60–69		1 (8.3%)
70–79		6 (50%)
≥80		1 (8.3%)
Ethnicity		
Asian		12 (100%)
Unilaterality		12 (100%)
Visual acuity		
Letters		
Mean (SE)		50.7 (2.9)
Median, range		52.5, 35–64
LogMAR		0.725
Snellen equivalence		20/100
Clinical/FA manifestations		
Occult CNV pattern		7 (58.3%)
Haemorrhagic pattern		5 (41.7%)
Central retina thickness by OCT		
Microns, mean (SE)		284.8 (23.7)

CNV, choroidal neovascularisation; FA, fundus fluorescein angiography; LogMAR, logarithm of minimal angle of resolution; OCT, optical coherence topography.

Outcome measures and statistical analysis

Visual outcome measures included the mean BCVA change in letters from baseline and the categorical BCVA change. Concerning the categorical change, we defined moderate gain in, or loss of, vision as gaining or losing 15 letters of BCVA or more from the baseline.

Table 2 Visual acuity outcomes and re-treatment at each month

BCVA change from baseline in letters													
Patient	Baseline BCVA	Mo 1	Mo 2	Mo 3	Mo 4	Mo 5	Mo 6	Mo 7	Mo 8	Mo 9	Mo 10	Mo 11	Mo 12
1	40	9	30	23	35	35	30	30	19	24	30	27	24
2	48	9	15	21 (R-P)	21	19	21	23	22	24	25	25	30
3	64	–4	–1	1	4	6	4	14	6	6	8	9	14
4	35	–4	–3	–3	–3	–3	–4	–3	2	5	7	9	16
5	57	12	21	12	25	25	26	25	28	28	24	20	18
6	40	–5	2	30	32	38	36	35	40	35	40	38	40
7	58	0	7	12 (R-P)	16	22	18 (R-P)	18	14	12 (R-P)	12	10	15
8	42	4	–7	–7	–9	–10	–9	–7	–2	–9	–9	–7	–7
9	58	–1	14	7	15	17	5 (R-F)	14	17	19	17	17	0 (R-F)
10	63	5	3	1	1	3	–5 (R-F)	–3	4	–2	–2	–2	–3 (R-F)
11	58	–4	10	5	2	0	–8 (R-F)	–5	1	–4 (R-F)	5	–11 (R-L)	–22 (R-F)
12	45	16	27	27	27	33	25	35	30	29	24	19	23
Mean (SE)	50.7 (2.9)	3.1 (2.1)	9.8 (3.4)	10.8 (3.5)	13.8 (4.2)	15.4 (4.6)	11.6 (4.7)	14.7 (4.5)	15.1 (3.8)	13.9 (4.2)	15.1 (4.1)	12.8 (4.2)	12.3 (5.0)
p Value*	–	0.180	0.023	0.017	0.015	0.014	0.071	0.023	0.004	0.015	0.010	0.019	0.041

BCVA, best-corrected visual acuity; Mo, month; R-F, re-treatment due to leakage on fluorescein angiography without polyp identified; R-L, re-treatment by the discretion of a treating ophthalmologist using ranibizumab only; SER-P, re-treatment due to identified polyp.

*Mean BCVA at each month was compared for significant change from baseline using the Wilcoxon signed rank test.

We used Wilcoxon signed rank test to determine the significance of changes of the mean BCVA and CRT from the baseline. We used McNemar's test to analyse the proportion of patients who had moderate visual gain and loss, leakage demonstrated by fluorescein angiography, and polyp regression for significant changes from the baseline. We used a p value of <0.05 for statistical significance for both tests.

RESULTS

We treated 12 eyes in 12 patients who were consecutively enrolled during the study period (table 1).

Visual outcomes

The mean BCVA improved significantly from the baseline from month 2 (table 2) and continued to improve significantly until month 5, when the best BCVA was achieved (an average gain of 15.4 letters from the baseline, $p=0.01$). By month 6, there was a four-letter loss of the mean BCVA from that recorded during month 5. This was because four patients lost more than five letters in the BCVA. However, during month 7, the mean BCVA improved by three letters from month 6 and improved significantly from the baseline (14.7 letters, $p=0.02$). This significant gain from the baseline of the mean BCVA was maintained until month 12.

A significant proportion of patients had moderate gain in vision from month 4. Seven patients (58.3%, $p=0.02$) at months 4, 5 and 12, and 6 patients (50%, $p=0.03$) from months 6 to 11 had a moderate gain in vision. We did not define any patient as having moderate loss of vision until one patient (8.3%, $p=1.0$ (patient 11; see table 2)) showed such loss in month 12.

Angiographic and OCT outcomes

There were seven eyes that had associated retinal pigment epithelial detachment (RPED), four of which had haemorrhagic and three had fibrovascular RPED. All RPEDs were located in the macular area. The size of RPEDs ranged approximately from 0.5 to 4 disc area. We found no association between RPEDs and treatment outcomes.

We found that patients who had a polyp identified on ICGA all had leakage identified on fluorescein angiography, but patients who had polyp regression on ICGA might still have a leakage that can only be visualised on fluorescein angiography. During the third month of follow-up, we observed polyp

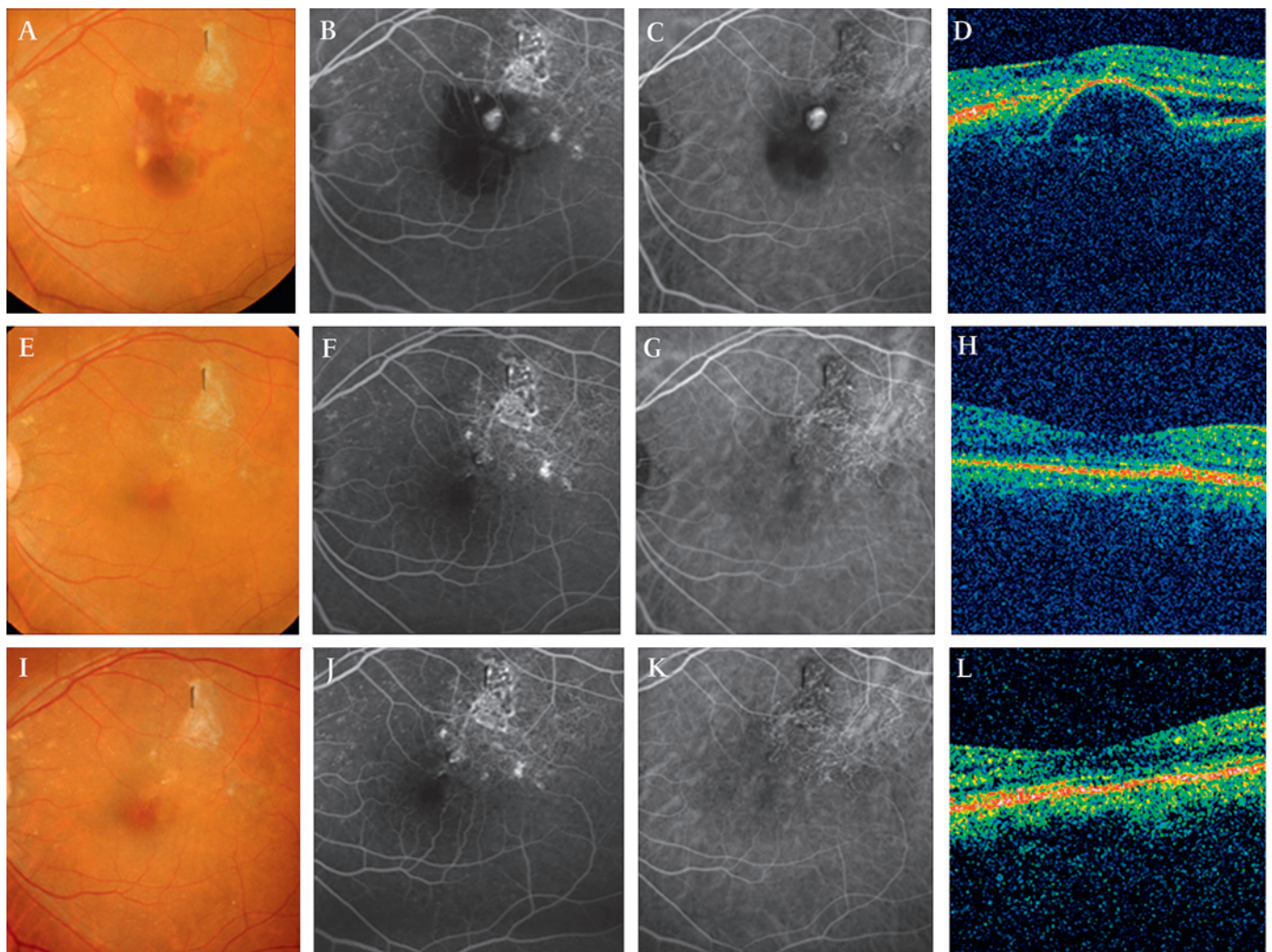


Figure 1 Fundus photos, fluorescein angiography, indocyanine green angiography (ICGA) and optical coherence tomography (OCT) of patient 6 before the combination therapy, at months 6 and 12 after the treatment. (A) Fundus photo, at baseline, showing haemorrhagic retinal pigment epithelial detachment (RPED) involving the fovea with subretinal scar tissue at the superotemporal macular. The patient's best-corrected visual acuity (BCVA) was 40 letters. (B) Fluorescein angiography showing leakage with staining of the scar. (C) ICGA showing focal hyperfluorescence indicating an active polyp. (D) OCT showing RPED with subretinal fluid. (E) Fundus photo, at month 6, after only one session of the combination therapy, showing resolution of the haemorrhagic RPED. The patient's BCVA was 76 letters. (F) Fluorescein angiography showing no leakage with the staining of the scar. (G) ICGA showing disappearance of the polyp with vascular branching network identified at the temporal macular. (H) OCT showing resolution of the RPED and no subretinal fluid. (I) Fundus photo, at month 12, showing no recurrence of PCV. The patient's BCVA was 80 letters. (J) Fluorescein angiography still showing no leakage with the staining of the scar. (K) ICGA showing no recurrence of the polyp with the vascular network identified. (L) OCT still showing resolution of the RPED and no subretinal fluid.

regression without fluorescein angiography leakage in 10 patients (83.3%, $p=0.002$) and persistent polyps in two patients. By month 6, 11 patients had polyp regression (91.7%, $p=0.001$), and 8 had no leakage on fluorescein angiography (66.7%, $p=0.008$). Three patients had fluorescein angiography leakage without polyps, and one patient had persistent polyps. By month 9, 11 patients had polyp regression and 10 had no fluorescein angiography leakage (83.3%, $p=0.002$); one patient had fluorescein angiography leakage without polyps while another had persistent polyps. At month 12, all patients had evidence of polyp regression ($p<0.0001$), and 9 patients had no leakage on fluorescein angiography (75%, $p=0.004$). Patients 9, 10 and 11 had leakage on fluorescein angiography without polyps. We did not observe any recurrence of polyps in any of the patients over 12 months.

All eyes that had subretinal or intraretinal fluid before treatment showed complete resolution of the fluid by OCT within 2 months after the first day of treatment. No eye had recurrence of

the fluid within 1 year. The mean CRT decreased significantly from the baseline from the first month of follow-up (a mean CRT of 215.8 or a 69 μm decrease from the baseline, $p=0.002$) and was maintained throughout follow-up with a mean CRT of 200.8 μm at month 12 (an 84 μm decrease from the baseline, $p=0.01$). The mean thicknesses found during month 8 (a mean CRT of 180.6 or a 104.2 μm decrease from the baseline, $p=0.003$) and month 1 were the thinnest and thickest, respectively. No eye had an increase of CRT for 100 μm or more compared to the lowest previous CRT value at any point within the follow-up period.

The mean CRT of each patient at each month is displayed in an additional table A2 (available online). Fundus photographs, fluorescein angiography, ICGA and OCT of patient 6 before and after treatment are shown in figure 1.

Re-treatments

Table 2 outlines the re-treatments that we gave to the study patients over the follow-up period. Of the 12 episodes of

Table 3 Number of patients treated with verteporfin photodynamic therapy (PDT) and ranibizumab

No of additional treatments	PDT	Ranibizumab
None (%)	7 (58.3%)	7 (58.3%)
1 (patient #)	1 (2)	1 (2)
2 (patient #)	2 (9,10)	2 (9,10)
3 (patient #)	2 (7,11)	1 (7)
4 (patient #)	0	1 (11)

No additional treatment—one session of verteporfin PDT and three injections of ranibizumab only.

re-treatments, 7 were due to leakage identified by fluorescein angiography without an identified coexisting polyp. At month 12, there were three patients who were re-treated due to this fluorescein angiography leakage. Table 3 summarises the number of patients that we treated with PDT and ranibizumab over 12 months. The mean episodes of PDT and mean injections of ranibizumab over 12 months, including the treatments in the initial regimen, were 1.9 and 4.2, respectively.

Adverse events

A small subretinal haemorrhage of 1 disc area, without a coexisting polyp detected on ICGA, occurred at month 12 in patient 7, who had a persistent polyp from the baseline until month 9. This patient had a total of four episodes of PDT and seven injections of ranibizumab. We did not observe any other adverse event, either systemic or ocular, in any other patient over 12 months.

DISCUSSION

The results suggest that combining ranibizumab with PDT might increase the degree of visual improvement obtained from PDT alone for the treatment of PCV. Table 4 summarises the 1-year results of the previously published studies of PDT monotherapy for PCV. The combination therapy used in this study resulted in a significantly higher gain in BCVA than that reported in those studies. This gain was approximately three times the average value of the mean BCVA gain at each interval of 3 months that was reported in those studies (figure 2 and table 4). Moreover, the proportion of patients with moderate gain in vision (58.3%) and moderate loss of vision (8.3%) at 1 year in this study was comparable with the highest propor-

tion of patients with moderate gain in vision (50%) and the lowest proportion of patients with moderate loss of vision (5%) at 1 year, as reported by Eandi *et al* and Chan *et al*, respectively.⁵⁻⁹

We hypothesise that the larger improvement in vision after the use of combination therapy results from the synergistic effect of PDT and ranibizumab. After PDT, a balance in angiogenesis, which is regulated in part by VEGF, is crucial for the beneficial effect to occur. Physiological regenerative angiogenesis is required for the recanalisation of the choriocapillaris, which is temporarily occluded by PDT. However, pathological angiogenesis may account for adverse events, such as subretinal haemorrhage and the recurrence of polyps. A study by Kim *et al* demonstrated that combined intravitreal ranibizumab injections with PDT in an animal model did not adversely affect the recanalisation of the choriocapillaris compared to PDT alone.²⁵ We also found no evidence of permanent non-perfusion affecting the choriocapillaris in any of the eyes reported herein. Moreover, we did not find any recurrent polyps and only one patient developed a subretinal haemorrhage after treatment, which was insignificant clinically. This suggested that the combination therapy might have balanced the angiogenesis after PDT and minimised VEGF-related adverse events and recurrence of disease.

Combination therapy, however, did not lessen the number of patients who required re-treatment or reduce the total number of re-treatments over 1 year when compared to data in the studies of PDT alone (table 4). This indicated that there were patients, such as patient 7, whose polyps were recalcitrant to the combination therapy. Other patients, such as patients 9, 10 and 11, had polyps that responded well to combination therapy, as indicated by regression on ICGA; however, the activity of the lesions as detected by leakage identified by fluorescein angiography recurred by month 6 when the effect of the initial treatment faded. Moreover, the re-treatment regimen in this study had limited efficacy in treating this fluorescein angiography leakage. More importantly, we found that this area of leakage seen with fluorescein angiography without polyps may translate into the clinical symptom of loss of vision.

It is therefore important to make an emphasis here that, after treatments or during natural courses, the disappearance of polyps on ICGA does not guarantee quiescence of activity of PCV lesions. This activity can be identified as leakage on

Table 4 One-year results of verteporfin PDT alone for the treatment of polypoidal choroidal vasculopathy in published studies compared with the combination therapy in this study

Author	N	Baseline mean BCVA (letters)	Mean BCVA change (letters)				Results at Mo 12				Results over 12 months			
			Mo 3	Mo 6	Mo 9	Mo 12	BCVA gain ≥ 3 lines (% of eyes)	BCVA loss ≥ 3 lines (% of eyes)	Absence of FA leakage (% of eyes)	Complete polyp regression (% of eyes)	Polyp recurrence (% of eyes)	Re-treatment (% of eyes)	Mean No of PDT	Subretinal haemorrhage (% of eyes)
Chan ⁵	22	48.5*	+7.5	+6	+5.5	+6	45.5	4.5	90.5	95.5	4.5	40.9	1.6	18.2
Silva ⁶	21	37†	NA	NA	NA	+1	28.6	14.3	66.7	NA	4.7	95.2	2.9	4.7
Akaza ⁸	35	51.5	+1.5	0	-1	-1.5	NA	NA	74.3	82.9	8.6	NA	2.2	8.6
Eandi ⁹	30	55†	NA	+3	NA	+3	50.0	20.0	98.3	NA	50.0	50.0	2.2	NA
Mitamura ²⁴	27	53.5	+3	+2.5	NA	+3	NA	NA	NA	NA	NA	22.2	1.3	NA
Gomi ²	36	49.5†	NA	NA	NA	+6.8	25.0	8.3	86.1	86.1	5.6	38.9	1.5	19.4
Kurashige ¹⁰	41	57.5†	NA	NA	NA	+4.5	29.3	17.1	NA	NA	NA	NA	NA	NA
Average	—	50.4	+4.0	+3.8	+2.3	+3.3	35.7	12.8	73.5	87.8	14.7	49.4	2.0	12.7
This study	12	50.7†	+10.8	+11.6	+13.9	+12.3	58.3	8.3	83.3	100	0	41.7	1.9	8.3

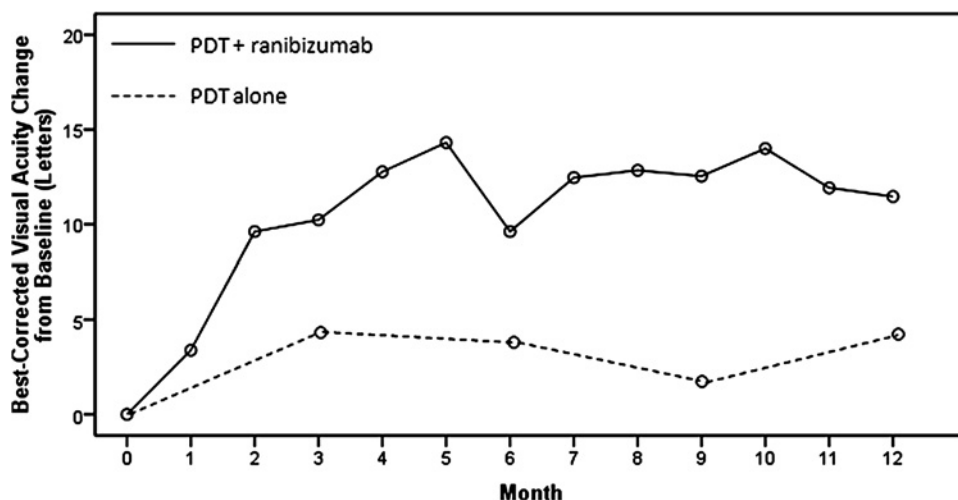
BCVA, best-corrected visual acuity (Snellen and logarithm of minimal angle of resolution visual acuity in each study was converted into letter scores for comparison); FA, fundus fluorescein angiography; Mo, month; NA, not available; PDT, photodynamic therapy.

The studies by Chan, Silva and Gomi were prospective, whereas the rest were retrospective; the superscripted number after each author's name indicates the reference number.

*Measured with Snellen chart.

†Measured with Early Treatment Diabetic Retinopathy Study chart (no data for the rest).

Figure 2 The mean best-corrected visual acuity change over time after combination therapy (top line) and of photodynamic therapy (PDT) alone in previously published studies (bottom line).



fluorescein angiography better than as leakage on ICGA. Surprisingly, OCT, as demonstrated in this study, may not identify subretinal or intraretinal fluid although the leakage is found on fluorescein angiography.

The finding of fluorescein angiography leakage without polyps after treatment with combination therapy in this study was consistent with that reported in other studies of PDT monotherapy for PCV, in which the proportion of patients with polyp regression on ICGA outnumbered the proportion of patients without leakage on fluorescein angiography after treatment.^{5–8} This leakage may reflect the activity of the vascular network component of PCV, which continues despite the obliteration of the polypoidal component of PCV by PDT.²⁶ The clinical course of this network tends to behave like typical CNV rather than PCV. Thus, anti-VEGF alone may be more effective than either combining PDT with an anti-VEGF agent or PDT alone for the treatment of the vascular network.

While the prospective, monthly follow-up of the study patients for the duration of a year is a strength of this study, there are inherent weaknesses due to the small sample size and the lack of a control group. The comparison of treatment results among the published case series of PDT monotherapy for PCV also demonstrated limitations. The designs of these series were different: four were retrospective and three were prospective; moreover, the methods of measuring outcomes (such as BCVA determination) and the criteria for defining outcomes (such as subretinal haemorrhage after treatment) were not uniform. However, the mean BCVA at baseline in this study (50.7 letters) was comparable with the average value of the mean BCVA at baseline reported among those series (50.4 letters). The criteria for re-treatment, which were based on angiographic outcomes, were uniform between those series and our study.

In summary, the treatment of PCV using PDT combined with ranibizumab showed encouraging results with respect to the improvement of vision when compared to data from the published studies of PDT monotherapy. At present, there is no randomised controlled trial that compares PDT monotherapy and PDT combined with ranibizumab for the treatment of PCV. Other important issues concerning combination therapy for the treatment of PCV, such as the use of different anti-VEGF agents, the number of the initial anti-VEGF injections and the re-treatment regimen, should also be investigated.

Acknowledgements This study was supported by research funds from Rajavithi Hospital, Bangkok, Thailand. The use of ranibizumab in this study was supported by

Novartis (Thailand). The authors acknowledge Drs Chairat Saovaprut, Atchara Ampornprut, Jiravut Limwattanayingyong and Atchareeya Sanmee at the Center of Excellence in Retina Diseases, Department of Medical Services, Ministry of Public Health, Thailand, for their support. The authors also acknowledge Dr Sid Borirak from the University of California, San Francisco, for his kind assistance in the review of this paper.

Funding Research funds of Rajavithi Hospital.

Competing interests None.

Patient consent Obtained.

Ethics approval This study was conducted with the approval of the Ethical Committee on Research Involving Human Subjects of Rajavithi Hospital.

Provenance and peer review Not commissioned; externally peer reviewed.

REFERENCES

1. **Yannuzzi LA**, Wong DW, Sforzolini BS, *et al.* Polypoidal choroidal vasculopathy and neovascularized age-related macular degeneration. *Arch Ophthalmol* 1999;**117**:1503–10.
2. **Gomi F**, Ohji M, Sayanagi K, *et al.* 1-year outcomes of photodynamic therapy in age-related macular degeneration and polypoidal choroidal vasculopathy in Japanese patients. *Ophthalmology* 2008;**115**:141–6.
3. **Quaranta M**, Mauget-Fayssie M, Coscas G. Exudative idiopathic polypoidal choroidal vasculopathy and photodynamic therapy with verteporfin. *Am J Ophthalmol* 2002;**134**:277–80.
4. **Spaide RF**, Donsoff I, Lam DL, *et al.* Treatment of polypoidal choroidal vasculopathy with photodynamic therapy. *Retina* 2002;**22**:529–35.
5. **Chan WM**, Lam DS, Lai TY, *et al.* Photodynamic therapy with verteporfin for symptomatic polypoidal choroidal vasculopathy: 1-year results of a prospective case series. *Ophthalmology* 2004;**111**:1576–84.
6. **Silva RM**, Figueira J, Cachulo ML, *et al.* Polypoidal choroidal vasculopathy and photodynamic therapy with verteporfin. *Graefes Arch Clin Exp Ophthalmol* 2005;**243**:973–9.
7. **Otani A**, Sasahara M, Yodoi Y, *et al.* Indocyanine green angiography: guided photodynamic therapy for polypoidal choroidal vasculopathy. *Am J Ophthalmol* 2007;**144**:7–14.
8. **Akaza E**, Yuzawa M, Matsumoto Y, *et al.* Role of photodynamic therapy in polypoidal choroidal vasculopathy. *Jpn J Ophthalmol* 2007;**51**:270–7.
9. **Eandi CM**, Ober MD, Freund KB, *et al.* Selective photodynamic therapy for neovascular age-related macular degeneration with polypoidal choroidal neovascularization. *Retina* 2007;**27**:825–31.
10. **Kurashige Y**, Otani A, Sasahara M, *et al.* 2-year results of photodynamic therapy for polypoidal choroidal vasculopathy. *Am J Ophthalmol* 2008;**146**:513–19.
11. **Hirami Y**, Tsujikawa A, Otani A, *et al.* Hemorrhagic complications after photodynamic therapy for polypoidal choroidal vasculopathy. *Retina* 2007;**27**:335–41.
12. **Kwak N**, Okamoto N, Wood JM, *et al.* VEGF is major stimulator in model of choroidal neovascularization. *Invest Ophthalmol Vis Sci* 2000;**41**:3158–64.
13. **Matsuoka M**, Ogata N, Otsuji T, *et al.* Expression of pigment epithelium derived factor and vascular endothelial growth factor in choroidal neovascular membranes and polypoidal choroidal vasculopathy. *Br J Ophthalmol* 2004;**88**:809–15.
14. **Tong JP**, Chan WM, Liu DT, *et al.* Aqueous humor levels of vascular endothelial growth factor and pigment epithelium-derived factor in polypoidal choroidal vasculopathy and choroidal neovascularization. *Am J Ophthalmol* 2006;**141**:456–62.
15. **Nakashizuka H**, Mitsumata M, Okisaka S, *et al.* Clinicopathological findings of polypoidal choroidal vasculopathy. *Invest Ophthalmol Vis Sci* 2008;**49**:4729–37.

16. **Lai TY**, Chan WM, Liu DT, *et al*. Intravitreal bevacizumab (Avastin) with or without photodynamic therapy for the treatment of polypoidal choroidal vasculopathy. *Br J Ophthalmol* 2008;**92**:661–6.
17. **Gomi F**, Sawa M, Sakaguchi H, *et al*. Efficacy of intravitreal bevacizumab for polypoidal choroidal vasculopathy. *Br J Ophthalmol* 2008;**92**:70–3.
18. **Reche-Frutos J**, Calvo-Gonzalez C, Donate-Lopez J, *et al*. Short-term anatomic effect of ranibizumab for polypoidal choroidal vasculopathy. *Eur J Ophthalmol* 2008;**18**:645–8.
19. **Schmidt-Erfurth U**, Hasan T. Mechanisms of action of photodynamic therapy with verteporfin for the treatment of age-related macular degeneration. *Surv Ophthalmol* 2000;**45**:195–214.
20. **Schmidt-Erfurth U**, Schlotzer-Schrehard U, Cursiefen C, *et al*. Influence of photodynamic therapy on expression of vascular endothelial growth factor (VEGF), VEGF receptor 3, and pigment epithelium-derived factor. *Invest Ophthalmol Vis Sci* 2003;**44**:4473–80.
21. **Treatment of age-related macular degeneration with photodynamic therapy (TAP) Study Group**. Photodynamic therapy of subfoveal choroidal neovascularization in age-related macular degeneration with verteporfin: 1-year results of 2 randomized clinical trials—TAP report. *Arch Ophthalmol* 1999;**117**:1329–45.
22. **Aiello LP**, Brucker AJ, Chang S, *et al*. Evolving guidelines for intravitreal injections. *Retina* 2004;**24**:S3–19.
23. **Ciardella AP**, Donsoff IM, Huang SJ, *et al*. Polypoidal choroidal vasculopathy. *Surv Ophthalmol* 2004;**49**:25–37.
24. **Mitamura Y**, Kubota-Taniai M, Okada K, *et al*. Comparison of photodynamic therapy to transpupillary thermotherapy for polypoidal choroidal vasculopathy. *Eye* 2009;**23**:67–72.
25. **Kim IK**, Husain D, Michaud N, *et al*. Effect of intravitreal injection of ranibizumab in combination with verteporfin PDT on normal primate retina and choroid. *Invest Ophthalmol Vis Sci* 2006;**47**:357–63.
26. **Lee WK**, Lee PY, Lee SK. Photodynamic therapy for polypoidal choroidal vasculopathy: vaso-occlusive effect on the branching vascular network and origin of recurrence. *Jpn J Ophthalmol* 2008;**52**:108–15.

Additional Table 1. Summary of the indications for retreatment.

	ICGA	FA	OCT	Treatment
Polypoidal component of PCV lesions	+	+	+/-	ICG-guided combination therapy
	-	+	+/-	FA-guided combination therapy
	+	-	+/-	ICG-guided combination therapy
	-	-	+	Ranibizumab only, no treatment if OCT criteria were -
Vascular network component of PCV lesions (when polyps were -)	+	+	+/-	FA-guided combination therapy
	-	+	+/-	FA-guided combination therapy
	+	-	+	Ranibizumab only, no treatment if OCT criteria were -
	-	-	+	Ranibizumab only, no treatment if OCT criteria were -

ICGA = an area of polypoidal component or vascular network component demonstrated by indocyanine green angiography; FA = an area of leakage demonstrated by fluorescein angiography; OCT = a presence of intraretinal or subretinal fluid by optical coherent tomography or an increase of central retinal thickness (CRT) by optical coherent tomography for 100 µm or more compared to the lowest previous CRT value.

Additional Table 2. Mean CRT determined by OCT at each month.

Patient	Baseline OCT	Mean CRT in μm											
		1 mo	2 mo	3 mo	4 mo	5 mo	6 mo	7 mo	8 mo	9 mo	10 mo	11 mo	12 mo
1	474	199	200	191	212	206	195	203	204	212	214	216	217
2	212	203	203	187	178	204	171	181	194	237	214	248	223
3	335	300	211	198	224	200	198	175	154	208	219	229	206
4	194	159	179	204	229	193	198	199	202	194	193	200	216
5	228	163	164	149	163	168	163	160	161	164	166	170	173
6	276	230	145	144	143	142	168	146	150	151	148	146	159
7	241	231	267	193	234	167	173	169	164	164	237	201	164
8	251	194	203	206	210	217	223	174	178	172	177	165	167
9	296	238	245	210	248	222	240	256	189	190	234	286	202
10	256	197	177	203	172	215	193	180	182	231	256	261	281
11	251	227	207	211	235	232	180	189	206	199	196	201	201
12	403	248	186	191	191	190	200	199	183	189	189	189	201
Mean	284.8	215.8	198.9	190.6	203.3	196.3	191.9	185.9	180.6	192.6	203.6	209.3	200.9
<i>P</i> value*		0.01	0.001	<0.0001	0.002	0.001	<0.0001	<0.0001	<0.0001	<0.0001	0.002	0.009	0.002

CRT = central retinal thickness; OCT = optical coherence topography; Mo = month; *Mean CRT at each month was compared for significant change from baseline using the Wilcoxon signed rank test.

Additional Table 1. Summary of the indications for retreatment.

	ICGA	FA	OCT	Treatment
Polypoidal component of PCV lesions	+	+	+/-	ICG-guided combination therapy
	-	+	+/-	FA-guided combination therapy
	+	-	+/-	ICG-guided combination therapy
	-	-	+	Ranibizumab only, no treatment if OCT criteria were -
Vascular network component of PCV lesions (when polyps were -)	+	+	+/-	FA-guided combination therapy
	-	+	+/-	FA-guided combination therapy
	+	-	+	Ranibizumab only, no treatment if OCT criteria were -
	-	-	+	Ranibizumab only, no treatment if OCT criteria were -

ICGA = an area of polypoidal component or vascular network component demonstrated by indocyanine green angiography; FA = an area of leakage demonstrated by fluorescein angiography; OCT = a presence of intraretinal or subretinal fluid by optical coherent tomography or an increase of central retinal thickness (CRT) by optical coherent tomography for 100 µm or more compared to the lowest previous CRT value.

Additional Table 2. Mean CRT determined by OCT at each month.

Patient	Baseline OCT	Mean CRT in μm											
		1 mo	2 mo	3 mo	4 mo	5 mo	6 mo	7 mo	8 mo	9 mo	10 mo	11 mo	12 mo
1	474	199	200	191	212	206	195	203	204	212	214	216	217
2	212	203	203	187	178	204	171	181	194	237	214	248	223
3	335	300	211	198	224	200	198	175	154	208	219	229	206
4	194	159	179	204	229	193	198	199	202	194	193	200	216
5	228	163	164	149	163	168	163	160	161	164	166	170	173
6	276	230	145	144	143	142	168	146	150	151	148	146	159
7	241	231	267	193	234	167	173	169	164	164	237	201	164
8	251	194	203	206	210	217	223	174	178	172	177	165	167
9	296	238	245	210	248	222	240	256	189	190	234	286	202
10	256	197	177	203	172	215	193	180	182	231	256	261	281
11	251	227	207	211	235	232	180	189	206	199	196	201	201
12	403	248	186	191	191	190	200	199	183	189	189	189	201
Mean	284.8	215.8	198.9	190.6	203.3	196.3	191.9	185.9	180.6	192.6	203.6	209.3	200.9
<i>P</i> value*		0.01	0.001	<0.0001	0.002	0.001	<0.0001	<0.0001	<0.0001	<0.0001	0.002	0.009	0.002

CRT = central retinal thickness; OCT = optical coherence topography; Mo = month; *Mean CRT at each month was compared for significant change from baseline using the Wilcoxon signed rank test.