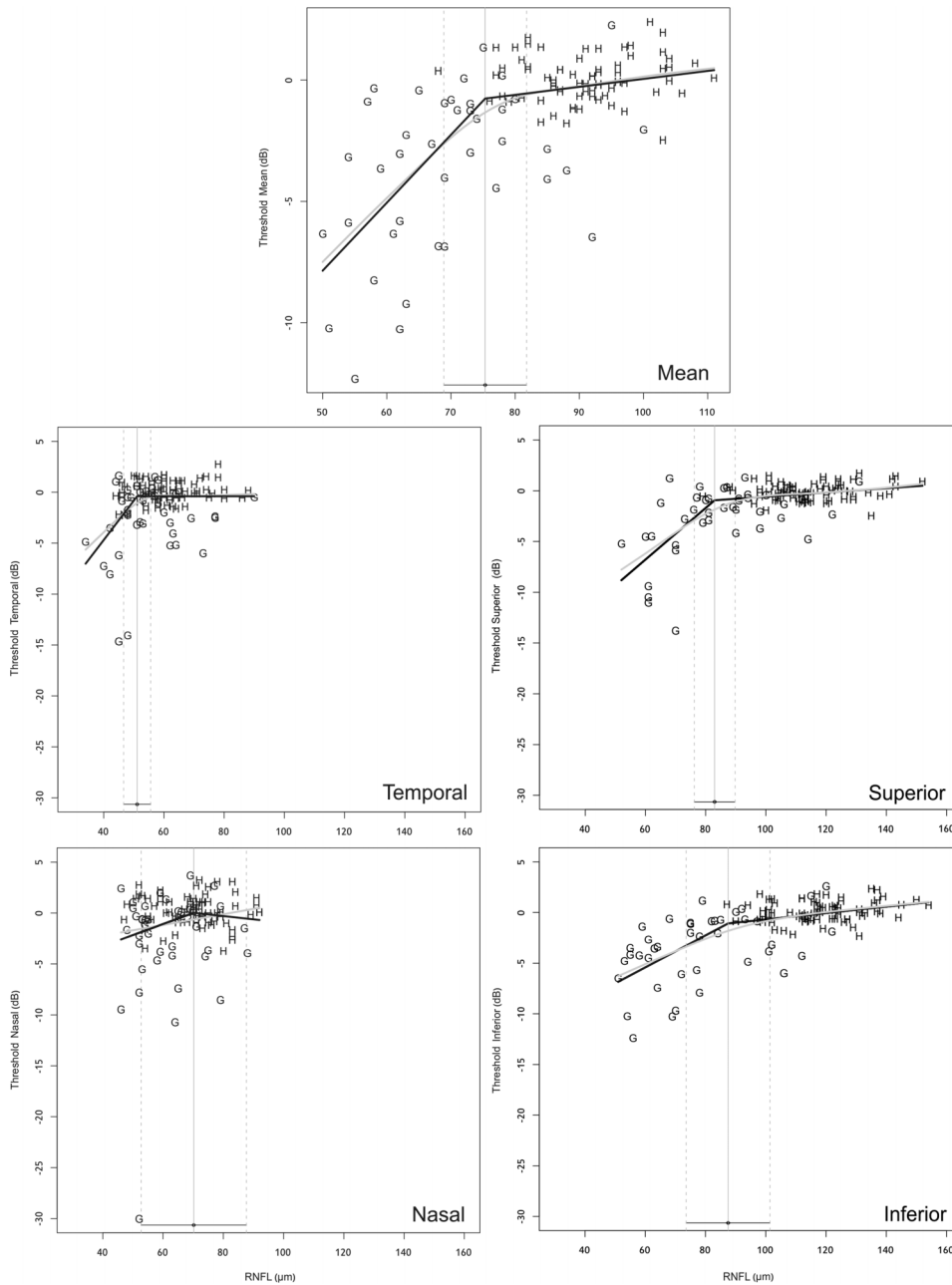


Corrections

Wollstein G, Kagemann L, Bilonick RA, *et al.* Retinal nerve fibre layer and visual function loss in glaucoma: the tipping point. *Br J Ophthalmol.* 2012;96:47–52. In Figure 1, the authors erroneously included the same plot for the temporal and inferior sectors. The correct figure is shown below.



Br J Ophthalmol 2013;97:1088. doi:10.1136/bjo.2010.196907corr1