




Avoiding mask-related artefacts in visual field tests during the COVID-19 pandemic

Marta Gómez Mariscal ¹, Francisco José Muñoz-Negrete,^{1,2}
Pablo Vicente Muñoz-Ramón ¹, Víctor Aguado Casanova ¹, Laia Jaumandreu,¹
Gema Rebolledo^{1,2}

► Additional material is published online only. To view, please visit the journal online (<http://dx.doi.org/10.1136/bjophthalmol-2020-318408>).

¹Ophthalmology, Ramon y Cajal University Hospital, IRYCIS, Madrid, Spain

²Facultad Medicina, Universidad Alcalá, Alcalá de Henares, Spain

Correspondence to

Dr Francisco José Muñoz-Negrete, Ophthalmology, Ramon y Cajal University Hospital, 28034 Madrid, Spain; francisco.munoz@uah.es

Received 12 November 2020

Revised 14 January 2021

Accepted 5 February 2021

ABSTRACT

Aims To assess visual field (VF) pseudoprogression related to face mask use.

Methods We reviewed a total of 307 VFs performed with a face mask (FPP2/KN95 or surgical masks) and compared them with prior VFs, performed before the pandemic. VFs with suspected pseudoprogression due to mask artefacts (VF test 1) were repeated with a surgical mask and an adhesive tape on its superior border (VF test 2) to distinguish from true VF loss. Several parameters including reliability indices, test duration, VF index (VFI), mean defect (MD) and pattern deviation probability plots were compared among last pre-COVID VFs, VF tests 1 and VF tests 2, using the Wilcoxon signed-rank test.

Results We identified 18 VFs with suspected progression artefact due to masks (5.8%). In all of them, the median VFI and MD significantly improved after fitting the superior border of the mask, showing no significant differences with pre-COVID tests. The median fixation losses were significantly higher when wearing the unfitted mask (13% vs 6%, $p=0.047$). The inferior hemifield was the most affected, either as a new scotoma or as an enlargement of a prior defect.

Conclusion Unfitted masks can simulate VF progression in around 6% of cases, mainly in the inferior hemifield, and increase significantly the rate of fixation losses. A similar rate of artefacts was observed using FPP2/KN95 or surgical masks. The use of a surgical mask with an adhesive tape covering the superior border may reduce mask-related artefacts, although concomitant progression cannot be ruled out in all cases.

INTRODUCTION

The worldwide coronavirus pandemic has deeply influenced clinical practice.¹ New protocols for a safer and effective hospital-setting ophthalmic clinical practice are emerging.^{2,3} Among them, the use of face masks is highly recommended to reduce viral transmission but has brought some challenges. In glaucoma consultations, our team had the impression that many patients presented a presumed progression of the visual field (VF) scotoma despite the apparent stability of their disease.

A recent report has shown that wearing a face mask while performing a VF test may cause inferior artefacts due to the fog on the trial lens.⁴ Furthermore, face masks seem to be a distracting factor to make a reliable test, as patients refer to feeling uncomfortable and short of breath.

The current study has analysed a cluster of VF tests performed with a face mask showing progression despite glaucoma stability, suggesting a mask-related false progression. We propose a more effective way to place the surgical face mask to avoid these artefacts.

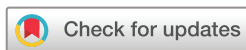MATERIALS AND METHODS

This case series study was conducted between July and August 2020 at Ramón y Cajal University Hospital. Informed consent was obtained from all participants included in the study. VF tests that presumably showed artefacts due to the use of a face mask were repeated with a well-fitted surgical face mask to see if suspected artefacts disappeared.

All VF tests performed with a face mask from June 29 to 31 July 2020 (VF test 1) were compared with previous VF tests, performed before the pandemic. VF tests 1 were suspected of progression when at least three new adjacent locations exhibited significant deterioration in the glaucoma progression analysis (GPA) event-based analysis or, if not present, when at least three new adjacent locations exhibited a sensitivity lower than 95% considered normal for an age-adjusted population in the pattern deviation probability plot compared with the last pre-COVID scotoma (pre-COVID VF). This evaluation was carried out by two trained ophthalmologists (VAC and PVM-R).

Medical records from patients with suspected VF progression were revised. Retinal nerve fibre layer (RNFL) thickness (Spectralis OCT, Heidelberg Engineering, Heidelberg, Germany) was considered stable when the average progression rate was under $1 \mu\text{m}/\text{year}$.⁵ Intraocular pressure (IOP) was considered well-controlled if it had not changed in the last 6 months and no RNFL progression was evidenced in the same period. If RNFL thickness and IOP remained stable, VF artefact was suspected and the patient was selected and scheduled for a new appointment to repeat the VF test and check if the suspected artefact disappeared. The repeated VF test (VF test 2) was performed under the same conditions, but changing patients' own masks by a surgical well-fitted face mask. This mask was placed as low as possible on the nose and with an adhesive tape (paper surgical tape, Ecopore, Barcelona, Spain) covering the entire length of the superior border to avoid fogging the trial lens and the upward displacement of the mask (figure 1).

Exclusion criteria included 10–2 strategy, deeply depressed VF tests, unreliable tests in the



© Author(s) (or their employer(s)) 2021. No commercial re-use. See rights and permissions. Published by BMJ.

To cite: Gómez Mariscal M, Muñoz-Negrete FJ, Muñoz-Ramón PV, et al. *Br J Ophthalmol* Epub ahead of print: [please include Day Month Year]. doi:10.1136/bjophthalmol-2020-318408

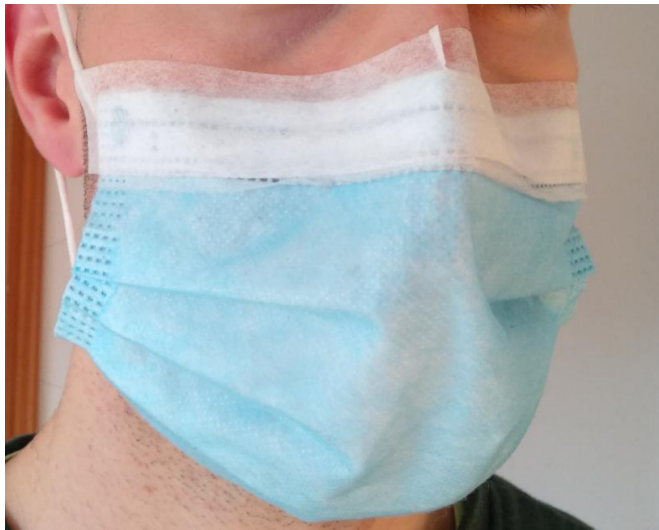

Figure 1 The proposed position of the surgical face mask, placed as low as possible on the nose and with an adhesive tape covering the entire length of the superior border.

pre-COVID period according to reliability indices, a limited experience with VF test defined as less than three VF tests performed in any perimeter device before the COVID-19 pandemic, absence of a pre-COVID VF test in the last year, VF test performed without a trial lens, or a disease other than ocular hypertension or glaucoma.

All patients had undergone a detailed ophthalmic examination in their scheduled glaucoma consultation, including visual acuity, non-dilated IOP measurement, optic disc assessment, RNFL thickness evaluated with Spectralis OCT, and VF test performed with the Humphrey Field Analyser (HFA, Carl Zeiss Meditec, Dublin, California). VF tests were all performed with a trial lens with the optimal near correction and the 24–2 SITA Fast strategy with a size III white stimulus projected against a background with a brightness of 31.5 apostilbs. A trained optician was always present to watch over the correct performance of the test.

The next parameters were recorded: reliability indices (percentage of fixation losses, false-positive errors and false-negative errors), test duration expressed in seconds, visual field index (VFI) and mean deviation (MD). Reliability indices were considered within the normal limits if the percentage of fixation losses was under 20%, and the percentage of false-positive errors and false-negative errors were both under 15%. These parameters were compared among the last pre-COVID VF, the VF test 1 and the VF test 2.

Pattern deviation probability plots of VF tests 1 and 2 were compared with check if the suspected artefact improved or remained despite fitting the mask. Improvement was defined when VF test 2 exhibited a scotoma smaller in at least three fewer locations compared with VF test 1, and so the suspicion of artefact persisted. In the cases whose scotoma did not improve a true progression was considered more probable.

Finally, we quantified the number of new locations with a sensitivity lower than 95% considered normal for an age-adjusted population and those locations previously affected whose sensitivity impaired in the pattern deviation probability plot.

Statistical analysis was performed using Stata software (V.12.0 for Windows, Stata Corporation, College Station, Texas). The Shapiro-Wilk test proved the non-parametric distribution of the data. Quantitative variables were compared using the Wilcoxon signed-rank test. Results were expressed as median (minimum-maximum). $P < 0.05$ was considered statistically significant.

RESULTS

A total of 307 patients performed a VF test during the 5-week study period. Among them, 222 performed a successive 24–2 strategy-VF test, which was compared with prior pre-COVID VFs. In total, 20 eyes from 13 (5.85%) patients showed presumed VF defect progression despite stable RNFL thickness and well-controlled IOP in at least one eye. As one patient refused to repeat the VF test, a total of 18 eyes from 12 patients (6 males and 6 females) were included in the current study.

The median age of participants when performing the VF test 1 was 76 years (range: 58–89 years). The most common type of glaucoma was primary open-angle glaucoma (13/18, 72%),

Table 1 Quantitative variables of the three visual field (VF) tests (pre-COVID test, VF test 1 (with unfitted mask), and VF test 2 (with fitted mask)) performed by the 12 patients (18 eyes) included in the study, and comparisons between the three VF test

	Pre-COVID VF test	VF test 1 (p^1)	VF test 2 (p^2)	VF test 1 versus 2 (p^3)
VFI (%)	92 (68/99)	84 (53/97) 0.001*	92 (69/99) 0.597	0.004*
MD (dB)	–6.0 (–13.42/2.33)	–7.57 (–14.88/–1.97) 0.004*	–5.45 (–12.77/–1.07) 0.648	0.007*
FL (%)	6 (0/20)	13 (0/60) 0.047*	0 (0/38) 0.668	0.016*
FPR (%)	1 (0/15)	1 (0/7) 0.408	2 (0/11) 0.658	0.066
FNR (%)	6 (0/11)	7 (0/53) 0.222	5.5 (0/11) 0.810	0.084
Length (s)	381 (299/451)	374 (304/456) 0.306	373.5 (302/441) 0.845	0.500

Results are expressed as median (minimum/maximum).

Pre-COVID test: last VF test before the pandemic; VF test 1: VF test performed with patient's mask; VF test 2: VF test performed with well-fitted surgical mask; p^1 : Comparison between pre-COVID VF test and VF test 1; p^2 : Comparison between pre-COVID VF test and VF test 2; p^3 : Comparison between VF test 1 and VF test 2.

* $p < 0.05$.

FL, fixation losses; FNR, false negative responses; FPR, false positive responses; MD, mean deviation; VFI, visual fixation index.

followed by pigmentary glaucoma (4/18, 22%), and pseudoexfoliative glaucoma (1/18, 5.5%). The median number of VF tests performed before the COVID-19 pandemic was nine (3–28), and the median follow-up since the first VF test was 9 years (2–20 years). According to the Hodapp classification, nine eyes (50%) showed early glaucoma, eight (44%) moderate glaucoma and one (6%) advanced disease.

The types of mask that patients wore to perform the VF test 1 were 50%, 39% and 11% by surgical, KN95 and FFP2 masks, respectively. In the remaining 209 patients, without suspicion of mask-related artefacts, the type of mask were 56%, 40% and 4% by surgical, KN95 or FFP2, and a combination of both types (surgical and FFP2/KN95 masks). There were no differences in the type of mask used between both groups ($p=0.612$, Fisher's exact test).

Table 1 displays quantitative data comparing VF parameters among pre-COVID VF, VF test 1 and VF test 2. VFI and MD were significantly worse in VF tests 1 compared with pre-COVID VF tests (84% vs 92%, $p=0.001$; and -7.57 vs -6.0 , $p=0.004$, respectively, Wilcoxon signed-rank test), while there were no significant differences between pre-COVID VF tests and VF tests 2 ($p=0.597$ and $p=0.648$, respectively).

The percentage of fixation losses was the only reliability index significantly worse in VF tests 1 compared with pre-COVID VF tests (13% vs 6%, $p=0.047$). The three indices showed no significant differences between pre-COVID tests and VF tests 2. There were no differences in the time lapsed for testing in any comparison.

Regarding the pattern of progression or pseudoprogession, two patterns were observed: new locations with a sensitivity lower than 95% considered normal for an age-adjusted population (pattern A) and sensitivity impaired pattern deviation probability plot (pattern B). In total, 14 eyes (78%) showed a pattern A, while 4 (22%) showed a pattern B (cases 6, 9, 11, 15). Among the cases showing a pattern A, 6 eyes presented a VF test 2 similar to the pre-COVID test (cases 1, 2, 12, 13, 17, and 18) and 8 only showed partial improvement of the scotoma observed in the VF test 1 (cases 3, 4, 5, 7, 8, 10, 14 and 16), while none of the cases showing a pattern B improved with the well-fitted mask. Pattern A was observed in 78% of cases using either the FFP2/KN95 or the surgical mask.

Considering VF tests 1 with pattern A, the inferior field was the most affected, either as a new scotoma or as an extension of a previous defect. The central area was the second most affected zone. In total, 8 (57%) defects predominately affected the inferior hemifield, 5 (35%) affected the central and paracentral zones; 2 (14%) showed a double arcuate scotoma, predominately inferior, 2 (14%) were a large scotoma affecting most of the VF, 1 (7%) affected the superior hemifield and 1 (7%) showed some scattered points. Figure 2 displays VF plots of three patients. Plots from the whole sample are included as online supplemental material.

In pattern A, the median number of new locations with a sensitivity lower than 95% considered normal was 14 (6–26), with a median sensitivity of -4.94 dB (-12.86 to -2.33). In pattern B, the median number was 6.5 (3–11), with a median sensitivity of -5.38 (-9.14 to -3.83). The median number of locations already affected in the pre-COVID test whose sensitivity impaired in VF test 1 was 4 (0–17) in pattern A and 9 (2–20 in pattern B).

DISCUSSION

Many situations can make VF test results misleading. Some artefacts have been described and could complicate the detection

of glaucoma progression. Low patient reliability, fatigue effect in prolonged tests could simulate a worsening in the VF. The presence of ptosis or trial lens artefacts result in localised defect not related to RNFL damage.⁶ The correct detection of these artefacts is essential to evaluate real glaucoma damage and progression.

The current study analyses new artefacts that appear in VF tests in relation to face mask use during the COVID-19 pandemic. We observed that the inferior field was the most affected, followed by central and paracentral areas.

In the current study, the prevalence of suspected mask-related artefacts was about 6%. Although this figure suggests that this is not a common finding, we cannot discard a higher prevalence in the VFs excluded from this analysis due to RNFL progression, IOP rise, unreliability or severe VF damage.

The most likely reason for artefacts is the breath exhaled through the superior border of the mask. The breath fogs the perimeter's trial lens, as it does with glasses.⁷ Surgical and KN95/FFP2 masks were used in a similar proportion by our patients. Most KN95 and FFP2 designs allowed a tight apposition on the face but presented a rigid edge on the nose bridge that did not seal well. On the contrary, surgical face masks are more flexible and adapt better the edges, including the strip for the nose, to any facial morphology, although their ear loop design is too loose to seal well the borders by itself. For this reason, we used surgical masks to adapt the mask well to the nose bridge and improved the sealing with the adhesive tape. However, despite these differences in their design, we did not observe that any kind of mask was more prone to favour mask-related artefacts.

Another reason for artefacts could be the upward displacement of the mask, which would cause a deep inferior peripheral scotoma similar to the eyelid-induced defect in the superior field. Nevertheless, we did not observe this type of scotoma and patients, when they were asked in the consultation, did not notice that their mask was displaced.

The use of adhesive bands or special techniques for tying masks has been described to prevent fogging the surgical loupes or microscopes.^{8,9} In the same way, the use of a surgical face mask with the superior strip pinched down on the nose and the adhesive tape covering the entire length of the superior border could theoretically prevent both fogging of the lens and the potential displacement of the mask. In the current study, VF tests 1 showed worse MD and VFI, as expected. When the mask was well fitted, these parameters significantly improved and showed no significant difference with pre-COVID tests, meaning that this position of the mask could be useful to reduce VF pseudoprogession.

The third factor that may diminish the reliability of VF tests is the discomfort and lack of breath that many patients refer to with the face mask.^{10,11} This was reflected in the significantly higher percentage of fixation losses in VF tests 1. In addition, we found that 8 (44%) of the tests performed with the patient's own masks were unreliable in at least one of the three reliability indices, compared with one (6%) among the VF tests 2.

We observed two patterns of pseudoprogession: new locations with a sensitivity lower than 95% considered normal for an age-adjusted population (pattern A) and sensitivity impaired pattern deviation probability plot (pattern B). We suspected mask-related artefacts in all cases showing the pattern A, as the scotoma improved with the well-fitted face mask. However, as 8 out of the 14 cases only showed partial improvement, concomitant progression could not be ruled out. All the cases showing the pattern B did not improve despite the well-fitted face mask and true progression was suspected. Therefore, a reduction of sensitivity in the probability plot is highly suggestive of true

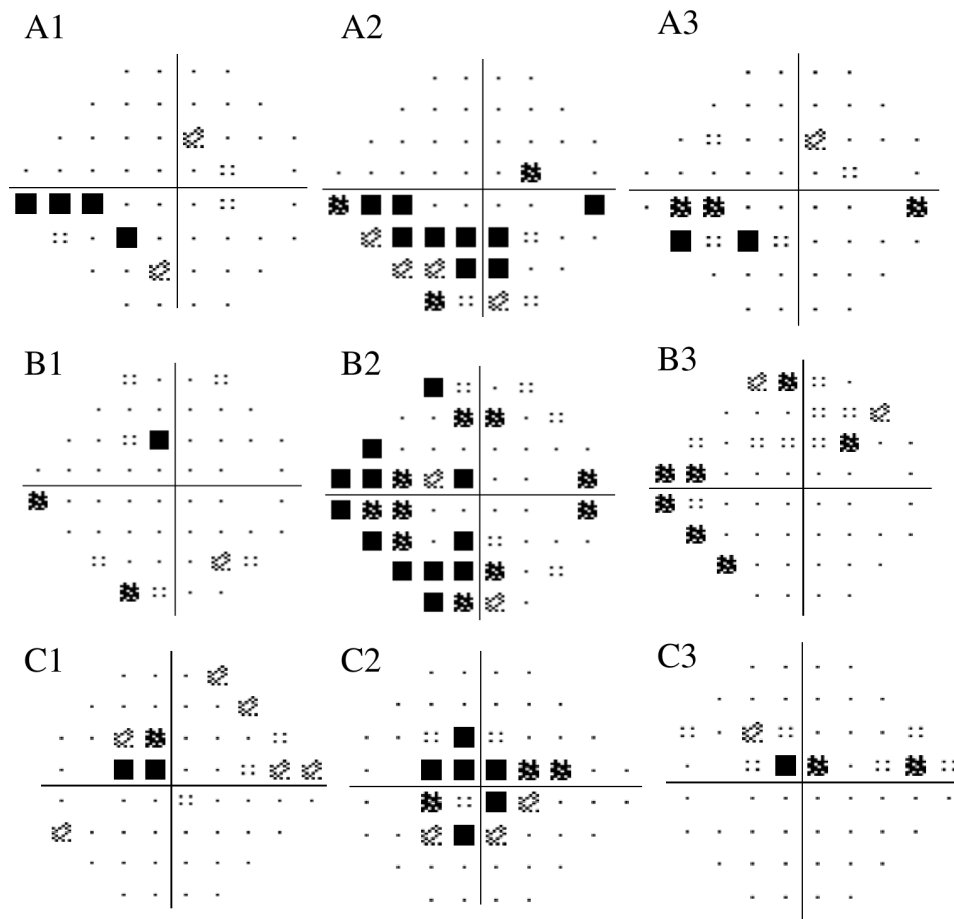


Figure 2 Pattern deviation probability plots of pre-COVID visual field (VF) test (1) VF test performed with patient's own face mask (2) and VF test performed with a well-fitted surgical mask and tape (3) of cases 1 (A), 5 (B) and 18 (C). In case 1, the VF performed before the pandemic showed an inferior nasal step extending back to the paracentral field (A1). With the unfitted mask, it enlarged to a moderate inferior arcuate defect (A2) that improved with the well-fitted mask (A3). In case 5, the pre-COVID VF showed a peripheral and unspecific inferior defect (B1). It became a new double arcuate scotoma, predominately in the inferior field (B2), and partially improved using a well-fitted mask (B3). In case 18, the pre-COVID VF showed a central scotoma (C1) that enlarged, predominately in the inferior field (C2). With the well-fitted mask, the VF showed a defect similar to the pre-COVID VF test (C3).

progression. Nevertheless, to confirm real progression, we need several successive VF tests carried out under ideal conditions and with the reliability parameters within normal limits. The use of masks to reduce viral transmission during the pandemic does not allow to ensure VF progression in patients in whom progression is highly suspected.

Statistical comparisons between patterns A and B was not possible due to the small number of cases. However, we observed that VFs with high suspicion of mask-related artefacts showed a clinically relevant higher number of new locations with a sensitivity lower than 95% considered normal in the pattern deviation probability plot compared with VFs suspected of true progression. We think this parameter is quite easy to evaluate during the daily clinical practice and could help to suspect mask-related artefacts.

Paper surgical adhesive tape is easily found in consultation rooms. It is hypoallergenic, latex-free, and adheres firmly to the skin, leaving a minimal sticky residue, properties that make it a good option. None of our patients suffered a medical adhesive-related skin injury after removing the adhesive tape. However, the adhesive material is an acrylic copolymer, and several studies have suggested that silicone-based medical adhesive tapes are better than acrylic-based medical tapes.^{12 13} Silicone-based

adhesive tapes should be considered in patients at risk of facial injuries, such as those with dry fragile skin, a history of previous skin tears, or chronic steroid treatment.

The current study presents several limitations. First, a healthy control group is missing; however, as we have mentioned above, a learning effect could not be ruled out and would distort comparisons. Second, the small sample size, conditioned by the recent changes in the clinical practice due to the COVID-19 pandemic. However, we consider that this number widely exemplifies the new artefacts that we can observe. Third, although repeating the VF test without any mask would be useful to distinguish true from pseudoprogession, it would not be ethical, considering the risks of infection. Fourth, although statistical methods, such as the GPA in the HFA, are preferable to establish progression in VF tests, it was not possible to apply it in all our patients, as two of them had previously performed VF tests in another perimeter device (Octopus perimeter or Humphrey perimeter in another medical centre), and had less than three tests in the HFA.¹⁴ To compensate for this weakness, an objective criterion was employed to determine which VF tests 1 showed suspected scotoma progression and which VF tests 2 exhibit improvement of the scotoma. Fifth, to calculate the changes in sensitivity, we took the values of the last pre-COVID test as the reference and

not the mean value of two or three previous VF tests to simplify the calculations. Nevertheless, as the reliability parameters of the last pre-COVID VF tests included were within normal limits, we think this is a valid approximation. Finally, other artefacts such as those due to the border of the trial lens or the superior eyelid may coexist. We suspected concomitant lens border-related artefact in one case (case 4).

In conclusion, in COVID-19 period a new artefact could be present in VF evaluation. Mask-related artefacts seem to be more common in the inferior field, followed by the central area. These artefacts could be mistaken as glaucoma progression damage. We propose the use of a surgical face mask with an adhesive tape on the superior border to reduce the presence of these artefacts.

Contributors Conception and design of the work were performed by FJM-N and GR. Material preparation and data collection were performed by PVM-R, VAC and MGM. Statistical analysis was performed by MGM and GR. Research of previous literature was performed by FJM-N and LJ. The first draft of the manuscript was written by MGM and all authors commented on previous versions of the manuscript. All authors read and approved the final manuscript.

Funding The authors have not declared a specific grant for this research from any funding agency in the public, commercial or not-for-profit sectors.

Competing interests None declared.

Patient consent for publication Not required.

Ethics approval The study protocol was approved by the local Institutional Research Ethics Committee and was carried out under the tenets of the Helsinki declaration.

Provenance and peer review Not commissioned; externally peer reviewed.

Data availability statement All data relevant to the study are included in the article or uploaded as supplementary information. The authors confirm that the data supporting the findings of this study are available within the article (and/or) its supplementary materials.

Supplemental material This content has been supplied by the author(s). It has not been vetted by BMJ Publishing Group Limited (BMJ) and may not have been peer-reviewed. Any opinions or recommendations discussed are solely those of the author(s) and are not endorsed by BMJ. BMJ disclaims all liability and responsibility arising from any reliance placed on the content. Where the content includes any translated material, BMJ does not warrant the accuracy and reliability of the translations (including but not limited to local regulations, clinical guidelines, terminology, drug names and drug dosages), and is not responsible for any error and/or omissions arising from translation and adaptation or otherwise.

This article is made freely available for use in accordance with BMJ's website terms and conditions for the duration of the covid-19 pandemic or until otherwise determined by BMJ. You may use, download and print the article for any lawful, non-commercial purpose (including text and data mining) provided that all copyright notices and trade marks are retained.

ORCID iDs

Marta Gómez Mariscal <http://orcid.org/0000-0003-4900-9359>

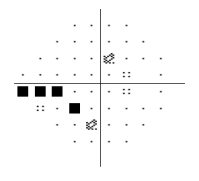
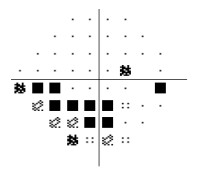


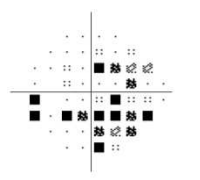
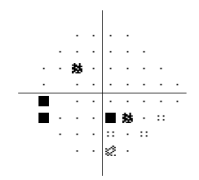
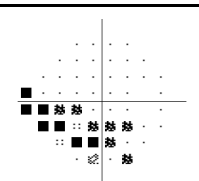
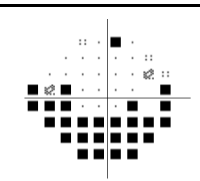
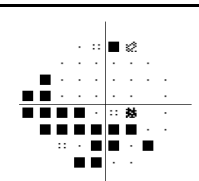
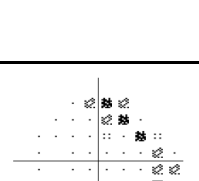
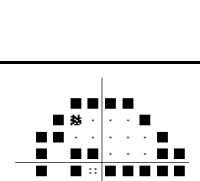
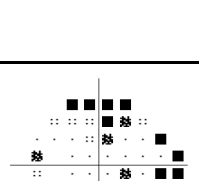
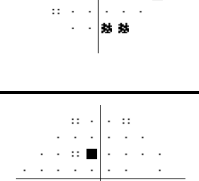
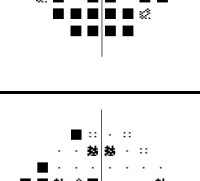

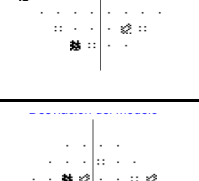





Pablo Vicente Muñoz-Ramón <http://orcid.org/0000-0002-3121-8083>

Victor Aguado Casanova <http://orcid.org/0000-0002-5051-5884>

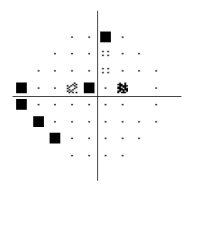
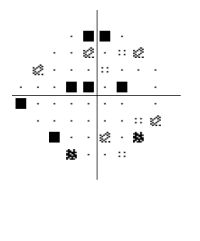
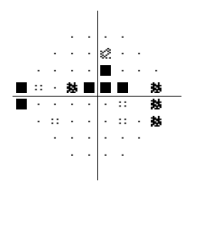
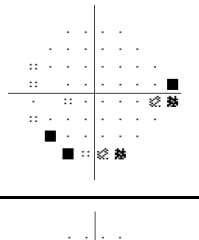
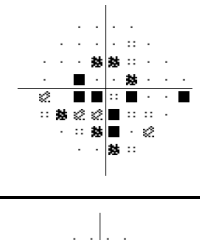
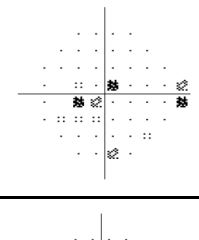


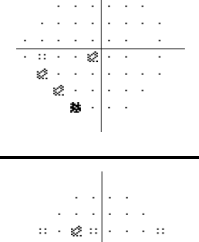
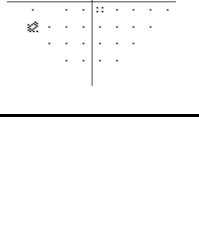
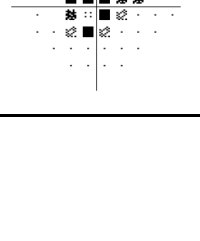
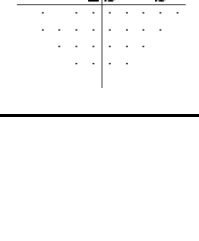
REFERENCES

- Liebmann JM. Ophthalmology and glaucoma practice in the COVID-19 era. *J Glaucoma* 2020;29:407–8.
- Romano MR, Montericcio A, Montalbano C, et al. Facing COVID-19 in ophthalmology department. *Curr Eye Res* 2020;45:653–8.
- Safadi K, Kruger JM, Chowers I, et al. Ophthalmology practice during the COVID-19 pandemic. *BMJ Open Ophthalmol* 2020;5:e000487.
- Young SL, Smith ML, Tatham AJ. Visual field artifacts from face mask use. *J Glaucoma* 2020;29:989–91.
- Wessel JM, Horn FK, Tornow RP, et al. Longitudinal analysis of progression in glaucoma using spectral-domain optical coherence tomography. *Invest Ophthalmol Vis Sci* 2013;54:3613–20.
- Heijl A, Patella VM. *Essential perimetry: the field analyzer primer*. 3 edn. Carl Zeiss Meditec, 2002.
- Hazanchuk V. How to wear a face mask without fogging your glasses. American Academy of ophthalmology, 2020. Available: <https://www.aaopt.org/eye-health/tips-prevention/face-mask-foggy-glasses-coronavirus-covid>
- Karabagli Y, Kocman EA, Kose AA, et al. Adhesive bands to prevent fogging of lenses and glasses of surgical loupes or microscopes. *Plast Reconstr Surg* 2006;117:718–9.
- Jordan DJ, Pritchard-Jones R. Tying a surgical mask to prevent fogging. *Ann R Coll Surg Engl* 2014;96:165.
- Fikenzer S, Uhe T, Lavall D, et al. Effects of surgical and FFP2/N95 face masks on cardiopulmonary exercise capacity. *Clin Res Cardiol* 2020;109:1522–30.
- Scarano A, Inchingolo F, Lorusso F. Facial skin temperature and discomfort when wearing protective face masks: thermal infrared imaging evaluation and hands moving the mask. *Int J Environ Res Public Health* 2020;17. doi:10.3390/ijerph17134624. [Epub ahead of print: 27 Jun 2020].
- Manriquez S, Loperfido B, Smith G. Evaluation of a new silicone adhesive tape among clinicians caring for patients with fragile or at-risk skin. *Adv Skin Wound Care* 2014;27:163–70.
- Zeng LA, Lie SA, Chong SY. Comparison of medical adhesive tapes in patients at risk of facial skin trauma under anesthesia. *Anesthesiol Res Pract* 2016;2016:1–6.
- Aref AA, Budenz DL. Detecting visual field progression. *Ophthalmology* 2017;124:551–6.

Supplementary material. Pattern deviation probability plots of pre-COVID visual field (VF) test, VF test performed with patient's own face mask and VF test performed with a well-fitted surgical mask and tape (OD: oculus dexter; OS: oculus sinister).

Case	Pre-COVID VF test	VF test performed with patient's own face mask	VF test performed with surgical mask and tape	Visual field scotomas
Case 1 (OD)				The inferior nasal step extending back to the paracentral field enlarged to a moderate inferior arcuate defect. With the well-fitted mask, the original inferior nasal step reappeared.
Case 2 (OS)				The inferior Bjerrum scotoma has extended to a diffuse, predominately inferior field defect. Original nasal step and inferior paracentral defect reappeared with a well-fitted mask
Case 3 (OD)				The inferior arcuate defect has extended to most of the inferior field. With a well-fitted mask, the inferior defect improved, although is still larger than in the pre-covid VF test. True progression could not be discarded, although an overlapped mask-related artefact was highly suspected.
Case 4 (OS)				Superior arcuate defect and inferior nasal step have extended to a diffuse and deep inferior defect. There was a superior artefact due to the lens border. With the well-fitted mask, the visual field improved, although some artefacts due to the lens border persisted.
Case 5 (OD)				The peripheral and unspecific inferior defect became a new double arcuate scotoma, predominately in the inferior field, and improved using a well-fitted mask.
Case 6 (OS)				The inferior and superior central and paracentral scotoma enlarged mainly inferiorly. With the well-fitted mask, the scotoma is still larger than in the pre-COVID VF test. True progression was suspected.
Case 7 (OD)				A new double arcuate scotoma, predominately inferior field defects. An inferior arcuate scotoma persisted despite the well-fitted mask, although quite smaller.

Case	Pre-COVID VF test	VF test performed with patient's own face mask	VF test performed with surgical mask and tape	Visual field scotomas
Case 8 (OD)				The inferior and superior arcuate defects became a diffuse and large scotoma affecting both hemifields. With the well-fitted mask, the defect reduced and was similar to the pre-COVID scotoma.
Case 9 (OD)				The inferior arcuate defect enlarged and deepened. With the well-fitted mask, there was no improvement. True progression was suspected.
Case 10 (OS)				A new small peripheral and inferior scotoma appeared and persisted despite the well-fitted mask.
Case 11 (OS)				The inferior scotoma enlarged and deepened. With the well-fitted mask, there was no improvement. True progression was suspected.
Case 12 (OD)				The new central scotoma improved using a well-fitted mask.
Case 13 (OS)				The inferior paracentral scotoma enlarged towards the central VF. With the well-fitted mask, it improved.
Case 14 (OD)				The superior arcuate scotoma extending to the paracentral field enlarged and a new inferior nasal step appeared. With the well-fitted mask, it improved.

Case	Pre-COVID VF test	VF test performed with patient's own face mask	VF test performed with surgical mask and tape	Visual field scotomas
Case 15 (OD)				New lower-sensitivity scattered points appeared all over the VF, some of them clustered inferiorly. With the well-fitted mask, the inferior scotoma improved. The central scotoma persisted even deepened. True progression was suspected.
Case 16 (OS)				A large central and inferior scotoma appeared and clearly disappeared with the well-fitted mask
Case 17 (OD)				The new inferior scotoma disappeared with the well-fitted mask
Case 18 (OS)				The central scotoma enlarged, predominately in the inferior field. With the well-fitted mask, there is no change compared to the pre-COVID VF test.