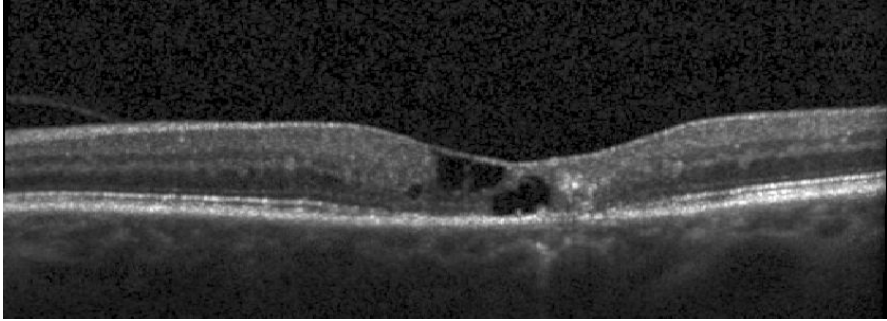
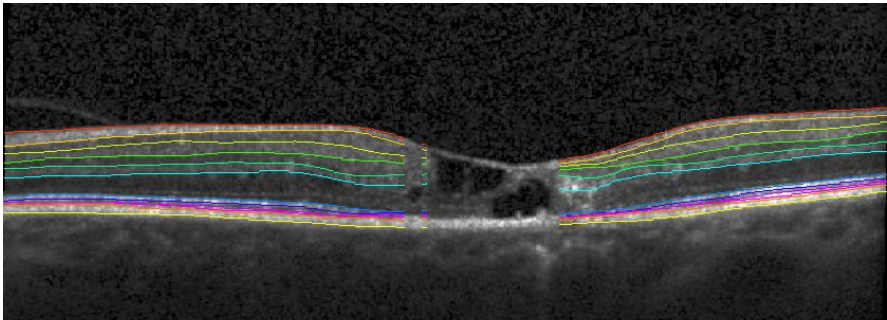
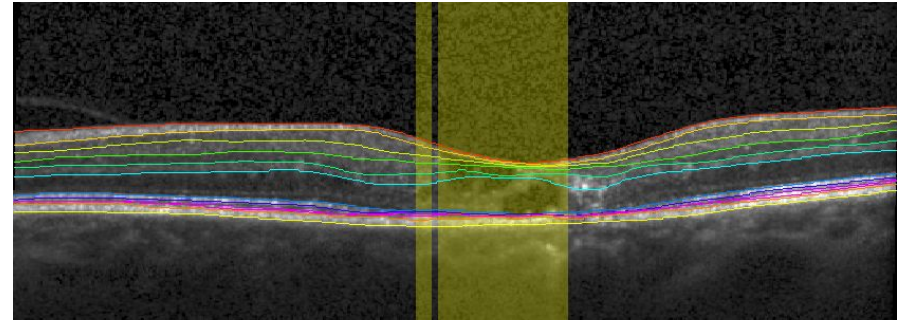
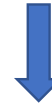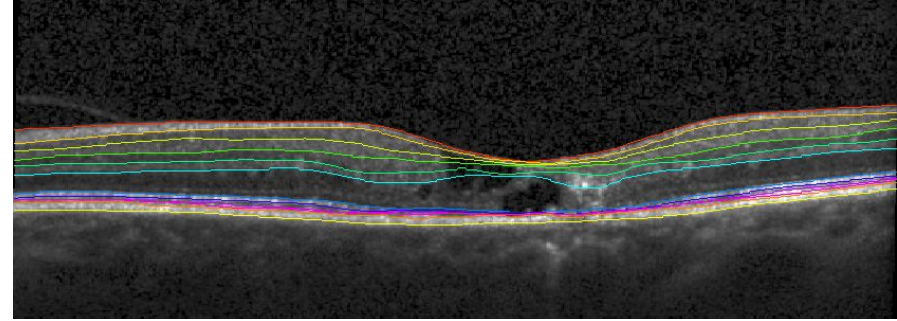


Supplementary figure. Automated retinal segmentation with IOWA Reference Algorithms of an eye with manual removal of regions containing empty cystic cavities

OCT with non-proliferative MacTel and empty cystic cavities



Automated retinal segmentation with IOWA Reference Algorithms



After removal of regions with empty cystic areas, the remaining areas to be analyzed are shown

Manual identification of areas with empty cystic cavities