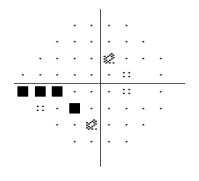
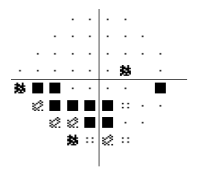


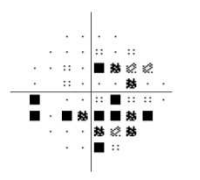
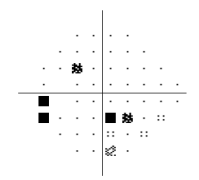
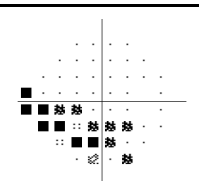
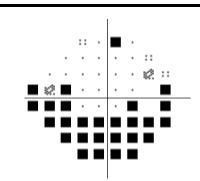
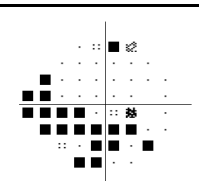
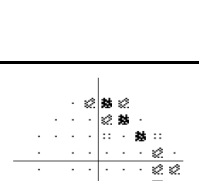
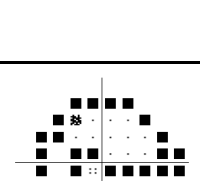
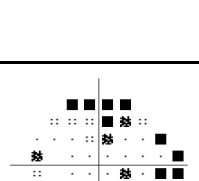
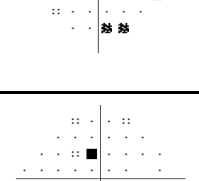
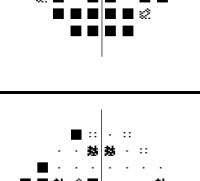

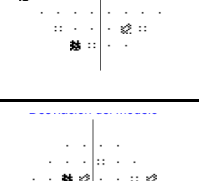





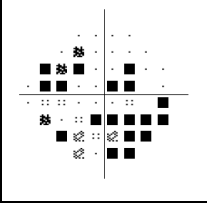
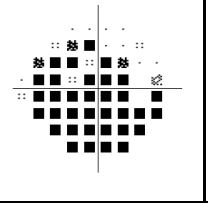
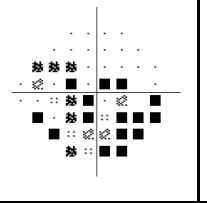
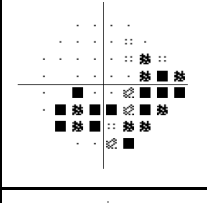
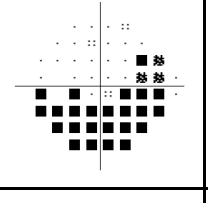
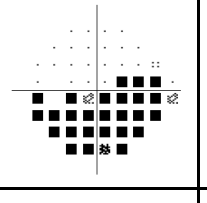
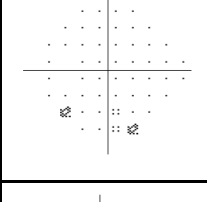
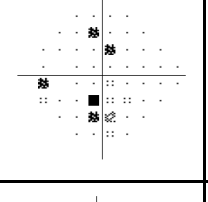
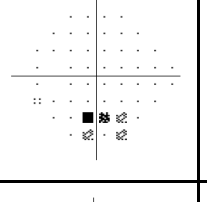
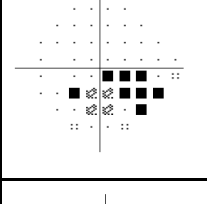
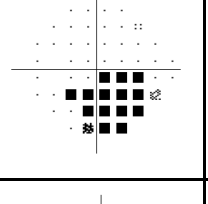
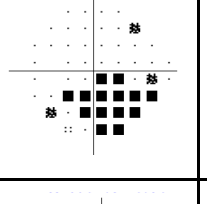
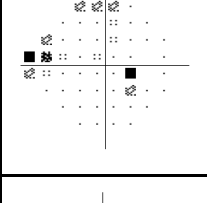
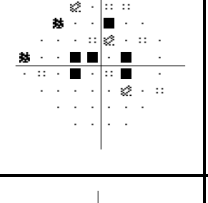
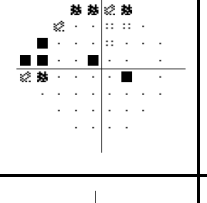
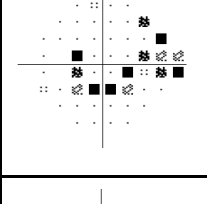
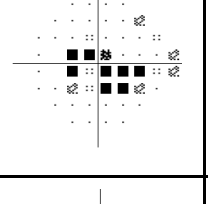
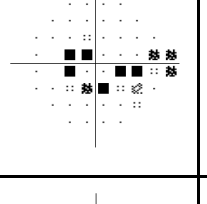
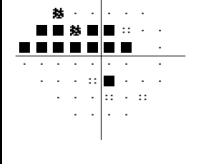
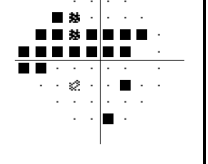
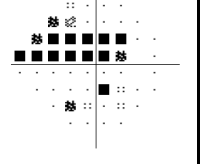
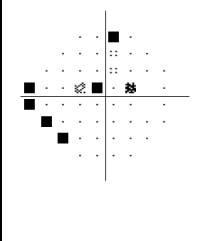
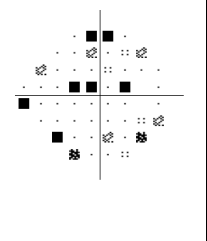
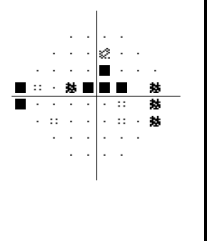
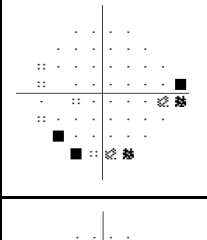
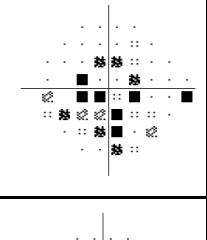
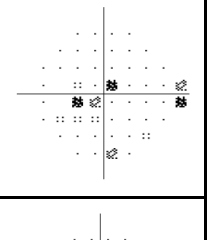
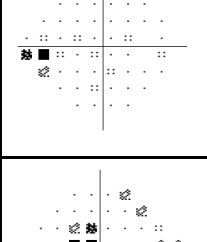
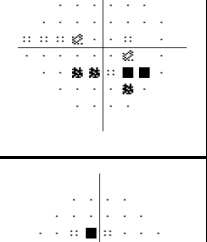
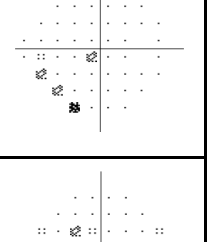
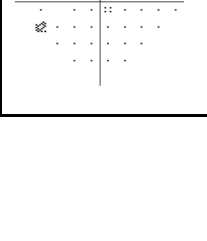
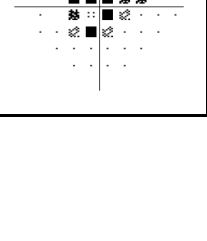
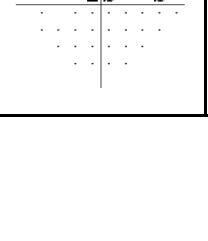


Supplementary material. Pattern deviation probability plots of pre-COVID visual field (VF) test, VF test performed with patient's own face mask and VF test performed with a well-fitted surgical mask and tape (OD: oculus dexter; OS: oculus sinister).

Case	Pre-COVID VF test	VF test performed with patient's own face mask	VF test performed with surgical mask and tape	Visual field scotomas
Case 1 (OD)				The inferior nasal step extending back to the paracentral field enlarged to a moderate inferior arcuate defect. With the well-fitted mask, the original inferior nasal step reappeared.
Case 2 (OS)				The inferior Bjerrum scotoma has extended to a diffuse, predominately inferior field defect. Original nasal step and inferior paracentral defect reappeared with a well-fitted mask
Case 3 (OD)				The inferior arcuate defect has extended to most of the inferior field. With a well-fitted mask, the inferior defect improved, although is still larger than in the pre-covid VF test. True progression could not be discarded, although an overlapped mask-related artefact was highly suspected.
Case 4 (OS)				Superior arcuate defect and inferior nasal step have extended to a diffuse and deep inferior defect. There was a superior artefact due to the lens border. With the well-fitted mask, the visual field improved, although some artefacts due to the lens border persisted.
Case 5 (OD)				The peripheral and unspecific inferior defect became a new double arcuate scotoma, predominately in the inferior field, and improved using a well-fitted mask.
Case 6 (OS)				The inferior and superior central and paracentral scotoma enlarged mainly inferiorly. With the well-fitted mask, the scotoma is still larger than in the pre-COVID VF test. True progression was suspected.
Case 7 (OD)				A new double arcuate scotoma, predominately inferior field defects. An inferior arcuate scotoma persisted despite the well-fitted mask, although quite smaller.

Case	Pre-COVID VF test	VF test performed with patient's own face mask	VF test performed with surgical mask and tape	Visual field scotomas
Case 8 (OD)				The inferior and superior arcuate defects became a diffuse and large scotoma affecting both hemifields. With the well-fitted mask, the defect reduced and was similar to the pre-COVID scotoma.
Case 9 (OD)				The inferior arcuate defect enlarged and deepened. With the well-fitted mask, there was no improvement. True progression was suspected.
Case 10 (OS)				A new small peripheral and inferior scotoma appeared and persisted despite the well-fitted mask.
Case 11 (OS)				The inferior scotoma enlarged and deepened. With the well-fitted mask, there was no improvement. True progression was suspected.
Case 12 (OD)				The new central scotoma improved using a well-fitted mask.
Case 13 (OS)				The inferior paracentral scotoma enlarged towards the central VF. With the well-fitted mask, it improved.
Case 14 (OD)				The superior arcuate scotoma extending to the paracentral field enlarged and a new inferior nasal step appeared. With the well-fitted mask, it improved.

Case	Pre-COVID VF test	VF test performed with patient's own face mask	VF test performed with surgical mask and tape	Visual field scotomas
Case 15 (OD)				New lower-sensitivity scattered points appeared all over the VF, some of them clustered inferiorly. With the well-fitted mask, the inferior scotoma improved. The central scotoma persisted even deepened. True progression was suspected.
Case 16 (OS)				A large central and inferior scotoma appeared and clearly disappeared with the well-fitted mask
Case 17 (OD)				The new inferior scotoma disappeared with the well-fitted mask
Case 18 (OS)				The central scotoma enlarged, predominately in the inferior field. With the well-fitted mask, there is no change compared to the pre-COVID VF test.