

Supplementary Materials

Supplementary Table 1. Uveitis Entities in the Non-Fuchs' Uveitis Syndrome (Non-FUS) Disease Control Group

| Entity | Number (%) | |
|--|------------------|-----------------|
| | Development Step | Evaluation Step |
| Idiopathic chronic anterior uveitis | 264 (42.2) | 212 (42.1) |
| Presumed viral anterior uveitis ^a | 125 (20.0) | 97 (19.3) |
| Posner-Schlossman syndrome | 108 (17.2) | 113 (22.4) |
| Vogt-Koyanagi-Harada ^b | 45 (7.2) | 29 (5.8) |
| Behcet's disease | 40 (6.4) | 20 (4.0) |
| Sarcoidosis-associated anterior uveitis | 31 (5.0) | 25 (5.0) |
| Intermediate uveitis | 12 (2.0) | 7 (1.4) |
| Total | 625 | 503 |

^a The diagnosis of presumed viral anterior uveitis was performed strictly based on the editorial in 2000¹⁶ and the Chinese study in 2019¹⁷.

^b The diagnosis of Vogt-Koyanagi-Harada syndrome was made according to both the revised diagnostic criteria in 2001¹⁸ and the Chinese diagnostic criteria in 2018¹⁹.

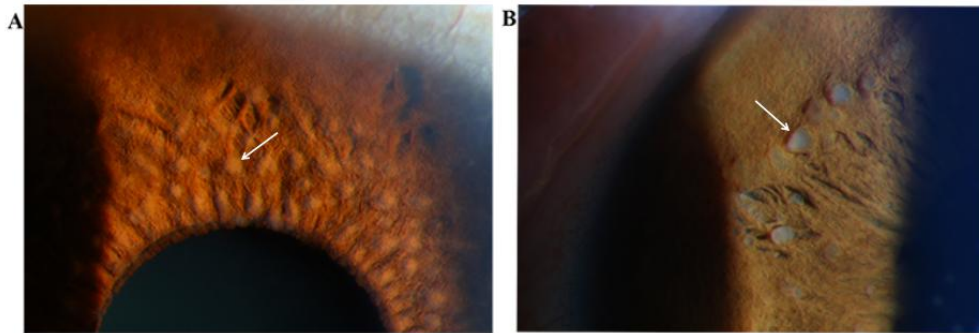
Supplementary Table 2. Performance of the three criteria for Fuchs' uveitis syndrome in the validation set.

| | Sensitivity, % | Specificity, % | AUCs (95%CI) | P value ^a |
|---------------------------------|-------------------|-------------------|------------------------|----------------------|
| The RDC | 96.55 | 97.42 | 0.970 (0.957-0.983) | - |
| the SUN classification criteria | 84.08 | 99.40 | 0.917 (0.895-0.940) | <0.01 |
| The La Heij criteria | 77.72 | 97.42 | 0.876 (0.849-0.902) | <0.01 |

^aComparison with the RDC by using McNemar test.

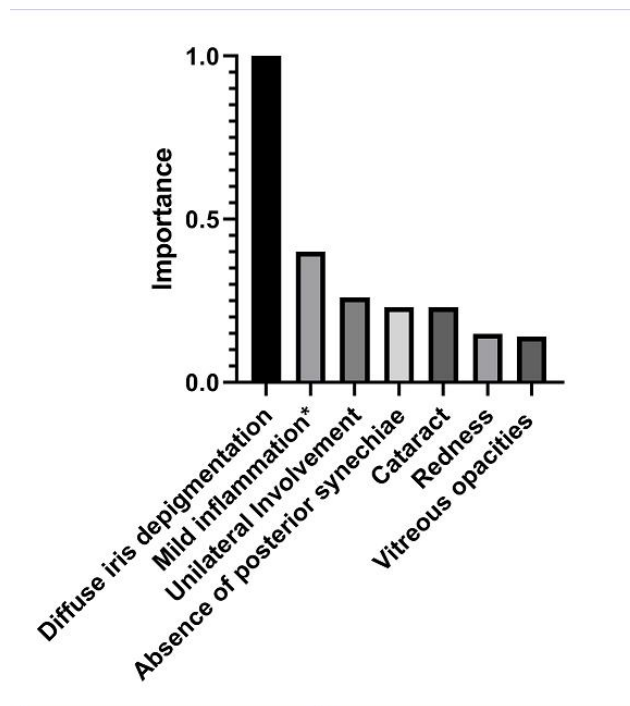
AUCs: area under the receiver operating characteristic curves; RDC: the revised diagnostic criteria; SUN: the Standardization of Uveitis Nomenclature.

Supplementary Figure



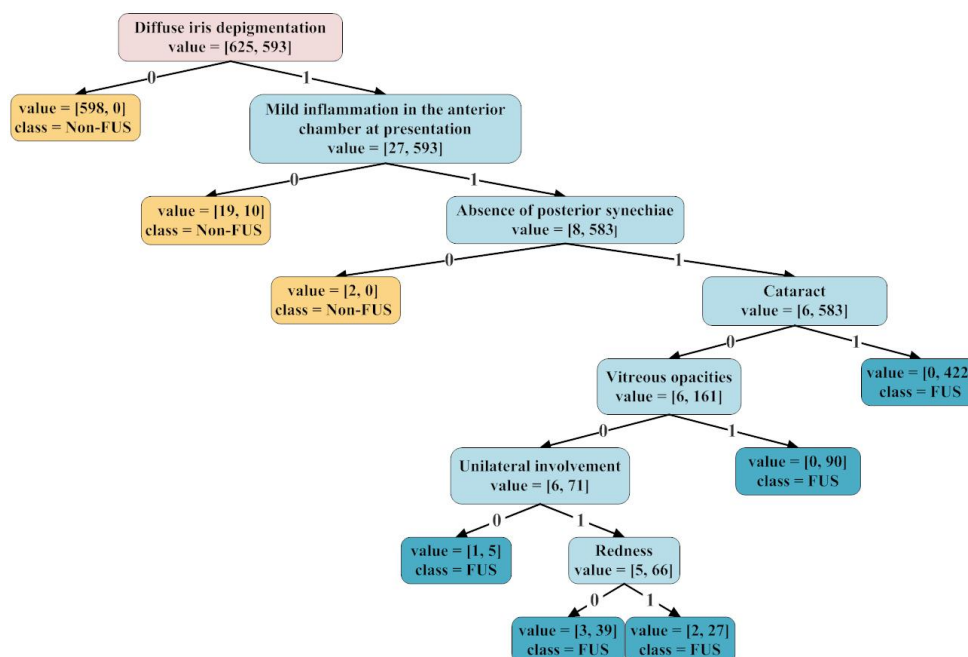
Supplementary Figure 1 Busacca nodules observed in Fuchs' uveitis syndrome

Busacca nodules observed in Fuchs' uveitis syndrome (A) are different from those noted in granulomatous inflammation (B).



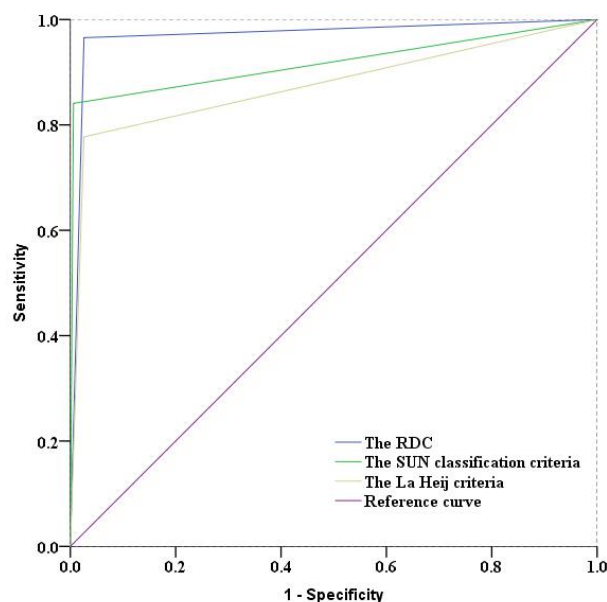
Supplementary Figure 2: The "Importance" >0.05 of nine variables in cluster analysis.

Mild inflammation: Mild inflammation in the anterior chamber at presentation.



Supplementary Figure 3: The decision tree of 8 variables

The decision tree of 8 variables with “Importance” >0.05 in cluster analysis or $P < 0.05$ in logistic regression. “Value” represents the remaining number of the control group and Fuchs’ uveitis syndrome group in the development set after segmentation. FUS: Fuchs’ uveitis syndrome



Supplementary Figure 4: The receiver operating characteristic curves of the three criteria for Fuchs’ uveitis syndrome. The RDC: the revised diagnostic criteria; SUN: Standardization of Uveitis Nomenclature.

Supplementary methods

Three data mining methods

In this study, three data mining methods (multivariate 2-step cluster analysis, binary logistic regression and decision tree) were used to establish the revised diagnostic criteria. In the first step, the Student's t-test and chi-square test were respectively used to compare quantitative and categorical variables between the FUS group and control uveitis group. According to the combined opinions of uveitis experts, some of those variables that had a $p < 0.01$ were chosen not only for multivariate 2-step cluster analysis but also for binary logistic regression analysis with a forward selection. Cluster analysis is an exploratory data mining technique, which divides the data into different clusters according to the similarity, so that the patterns in the effective clusters are more similar to each other.¹ Gilbert et al² have identified peripheral lesions and intraocular inflammation as distinct clinical phenotypes of multifocal choroiditis and punctate inner choroidopathy by using a cluster analysis approach. In a multivariate 2-step cluster analysis, the optimized Bayesian information criterion was used to determine the number of clusters and a log-likelihood decision rule was used to resolve cluster differentiation. Logistic regression is a powerful method to analyze the relationship between a binary outcome or categorical outcome and multiple influencing factors.³ A previous study for instance used logistic regression to establish new diagnostic criteria for Takayasu arteritis.⁴ The combined use of multivariate 2-step cluster analysis and binary logistic regression analysis was used to screen candidate variables that could be used to develop diagnostic criteria. "Predictor Importance" was calculated and variables with an "Importance" > 0.05 in cluster analysis or with a $p < 0.05$ in binary logistic regression were used for decision tree classification. The decision tree model was subsequently used to determine the association between the meaningful main effect variables and the disease of interest. Previous studies have shown that "meaningful main effect variables" can be screened by logistic regression and then further used in decision tree models to obtain better results.⁵ In the decision trees algorithm, quantitative variables were dichotomized and categorical variables were normalized to "0" or "1" values. By using recursive segmentation analysis between different variables, the decision tree model was built for all potential determinants.^{6,7} Each internal node of the decision tree represents a test on a variable, which is related to the final classification results. Each branch represents a test output, and each terminal node represents a class or class distribution. The variable of the root node at the top of the tree model is most important to the classification results.⁸ The minimum sample size on the node was set as "50". If the sample size on the node failed to meet this requirement, the segmentation was finished. Based on the decision tree result, each recruited variable was reassessed by uveitis experts and statisticians, leading to the development of a final set of diagnostic criteria. The use of three data mining methods further added to the degree of reliability of the RDC for FUS.

Supplementary Discussion

Clinical differentiation of FUS

As one of the frequently misdiagnosed uveitis entities in the world, FUS is in urgent

need for differentiation from other types of uveitis presenting as chronic anterior inflammation, complicated cataract and elevated IOP. In the control group we included several diseases that need to be differentiated from FUS. For example, patients with idiopathic chronic anterior uveitis, who may present with dust-like KPs and uneven iris depigmentation, may be misdiagnosed as FUS. Patients with idiopathic chronic anterior uveitis however often show bilateral involvement and posterior synechiae. In addition, presumed viral anterior uveitis and Posner-Schlossman syndrome with iris depigmentation are also easily confused with FUS. A few patients with Vogt-Koyanagi-Harada (VKH) disease and Behcet's disease were included in our study. The granulomatous Koeppe nodules and Busacca nodules seen in VKH or sarcoidosis also need to be distinguished from the characteristic iris nodules observed in FUS (Figure 1). In the context of these uveitis types as a control group, we hope that our new set of diagnostic criteria may facilitate the correct clinical identification of FUS.

The complications of FUS

The ocular examinations that focus on slit-lamp biomicroscopy for the bilateral anterior segment of the eye to detect iris abnormalities and the degree of inflammation in the anterior chamber were of great importance for FUS patients. A late diagnosis of FUS may lead to an inappropriate medication resulting in serious complications such as cataract and ocular hypertension. Cataract is often the major cause of visual acuity loss and it is thought that this may be hastened by prolonged use of corticosteroids, although this has not yet been formally proven by randomized clinical trials.⁹ The importance of diagnosing FUS is especially important in the light of the fact that these patients may develop glaucoma and regular follow-up is necessary for the timely evaluation of IOP changes. Approximately 40% of FUS patients showed an elevated intraocular pressure in our study. Previous studies showed that the development of secondary glaucoma in FUS patients is variable, ranging between 6.3% and 59% of cases.^{10,11} Secondary glaucoma can be controlled by topical and systemic anti-glaucoma medication combined with regular monitoring. Taken together, we recommend that patients have a follow-up visit every 3-4 months in order to detect complications such as cataract and glaucoma, unless they suffer from an exacerbation that may require immediate treatment.

The treatment for FUS patients in our uveitis center

For FUS patients, a detailed history taking, including general information, complaints and associated systemic diseases, were collected at the patients' initial visit in our uveitis center. The best-corrected visual acuity (BCVA) and IOP were obtained on the same day. The ocular examinations focus on slit-lamp biomicroscopy for the bilateral anterior segment of the eye to detect iris abnormalities and the degree of inflammation in the anterior chamber. The correct diagnosis was strengthened by the presence of diffuse iris depigmentation. The cornea, the chamber angle and the anterior vitreous could be evaluated by ultrasound biomicroscopy (UBM) in some FUS patients with elevated IOP. In FUS patients, corticosteroid therapy is often not successful and visual acuity may only improve slightly by this treatment. Generally, a short treatment with topical corticosteroids might be indicated if obvious anterior chamber inflammation is present.

Reference

1. Jain AK, Murty MN, Flynn PJ. Data clustering: a review. *ACM Comput Surv* 1999;31(3):264-323.
2. Gilbert RM, Niederer RL, Kramer M, et al. Differentiating Multifocal Choroiditis and Punctate Inner Choroidopathy: A Cluster Analysis Approach. *Am J Ophthalmol*. 2020;213:244-251.
3. Hughes G, Choudhury RA, McRoberts N. Summary Measures of Predictive Power Associated with Logistic Regression Models of Disease Risk. *Phytopathology*. 2019;109(5):712-715.
4. Kong X, Ma L, Wu L, et al. Evaluation of clinical measurements and development of new diagnostic criteria for Takayasu arteritis in a Chinese population. *Clin Exp Rheumatol*. 2015;33(2 Suppl 89):S-48-55.
5. Zhu Y, Fang J. Logistic Regression-Based Trichotomous Classification Tree and Its Application in Medical Diagnosis. *Med Decis Making*. 2016;36(8):973-989.
6. Loh WY, Seneta E, Zeelenberg K. *Fifty Years of Classification and Regression Trees*. Chapman & Hall/CRC; 2018.
7. Gheondea-Eladi A. Patient decision aids: a content analysis based on a decision tree structure. *BMC Med Inform Decis Mak*. 2019;19(1):137.
8. Luna JM, Gennatas ED, Ungar LH, et al. Building more accurate decision trees with the additive tree. *Proc Natl Acad Sci U S A*. 2019;116(40):19887-19893.
9. La Hey E, de Jong PT, Kijlstra A. Fuchs' heterochromic cyclitis: review of the literature on the pathogenetic mechanisms. *Br J Ophthalmol*. 1994;78(4):307-312.
10. Sun Y, Ji Y. A literature review on Fuchs uveitis syndrome: An update. *Surv Ophthalmol*. 2020;65(2):133-143.
11. Norrsell K, Sjodell L. Fuchs' heterochromic uveitis: a longitudinal clinical study. *Acta Ophthalmol*. 2008;86(1):58-64.