

eFigure 1

Study flowchart.

eFigure 2

OCTA images of SCP, DCP and CC.

eTable 1

OCTA parameters in the PA-ST group and the PA-FT group with HC.

eFigure 1

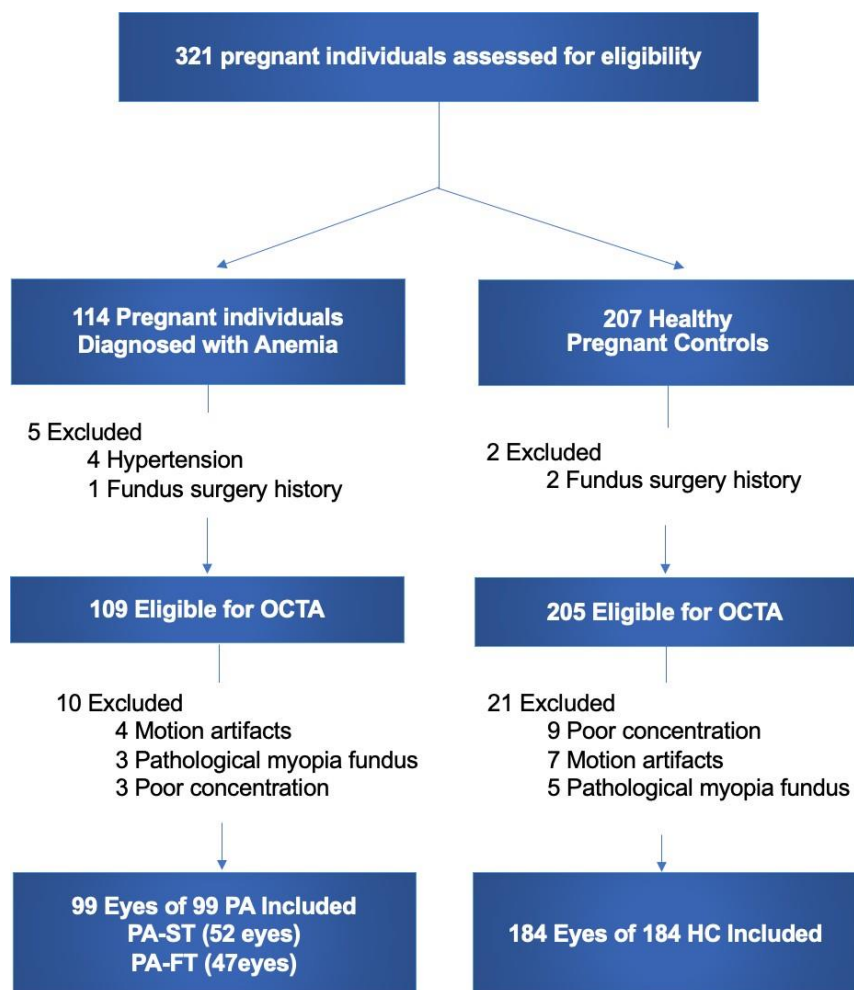


Figure Legends: Study flowchart.

OCTA: optical coherence tomography angiography. PA: pregnant individuals with anemia. HC: healthy pregnancy controls. PA-ST: PA diagnosed in the second or third trimesters. PA-FT: PA diagnosed in the first trimesters.

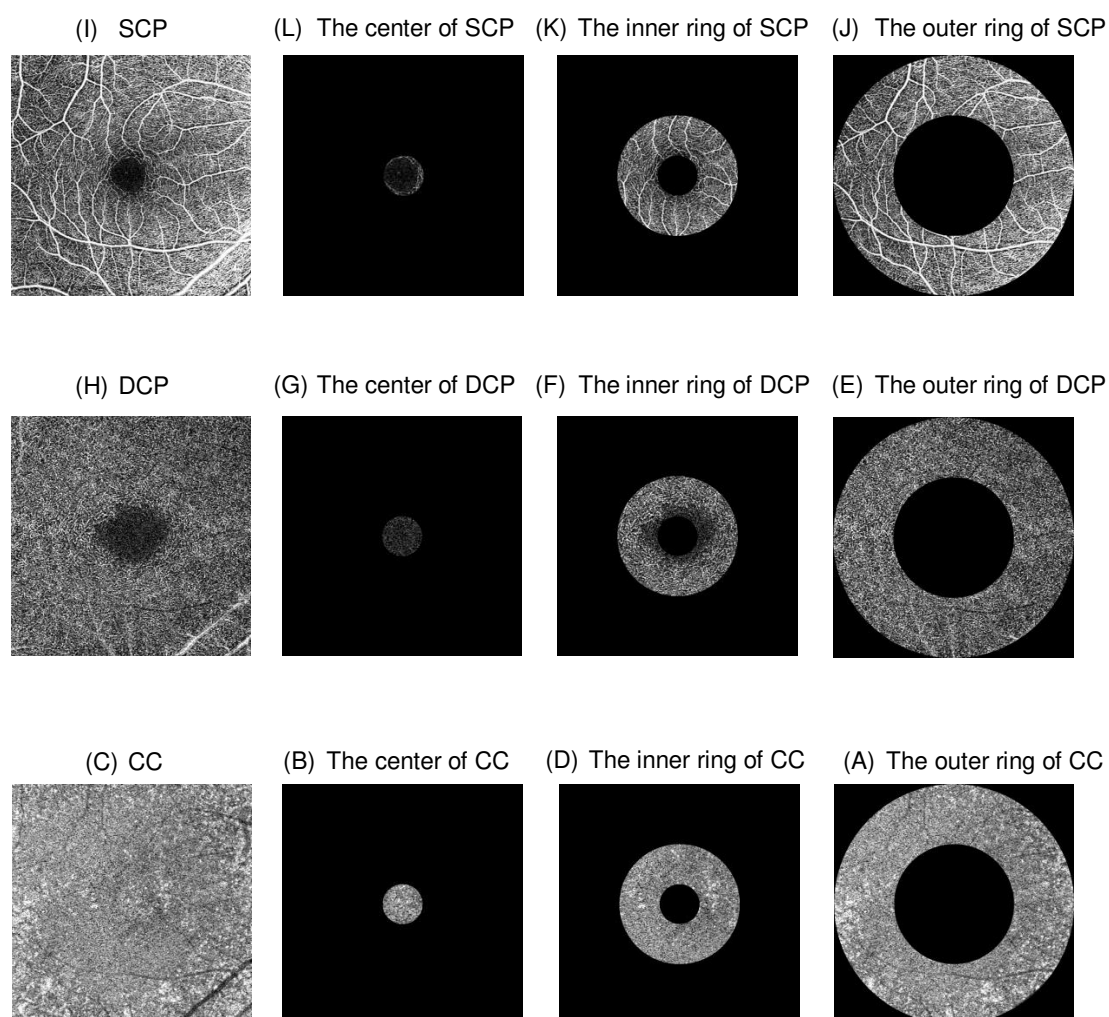
eFigure 2

Figure Legends: OCTA images of SCP, DCP and CC.

Representative OCTA images of SCP (A-D), DCP(E-H) and CC(I-L). ETDRS subfields are overlaid on the 6 × 6mm fovea-centered images. PD and FD were measured over the center region (d=1mm) (B,F,J), the inner ring (d=1~3mm) (C,G,K), and the outer ring (d=3~6mm) (D,H,L).

Abbreviations: OCTA: optical coherence tomography angiography. SCP: superficial capillary plexus. DCP: deep capillary plexus. CC: choriocapillaris. PD: perfusion density. FD: flow deficits.

eTable 1

OCTA parameters in the PA-ST group and the PA-FT group with HC.

Variable	HC(N=184)	PA-ST (N=52)	β coefficient (95% CI)	P Value	PA-FT (N=47)	β coefficient (95% CI)	P Value
FAZ in the DCP							
Area /mm ²	1.27(0.29)	1.14(0.28)	-0.177(-0.264 to -0.090)	<0.001***	1.13(0.29)	-0.057(-0.149 to 0.036)	0.229
Perimeter/mm	4.35(0.56)	4.04(0.55)	-0.407(-0.574 to -0.240)	<0.001***	4.00(0.54)	-0.199(-0.376 to -0.022)	0.028*
Circularity	0.84(0.08)	0.87(0.05)	0.038(0.016 to 0.059)	0.001**	0.88(0.05)	0.036(0.013 to 0.060)	0.002**
FAZ in the SCP							
Area/mm ²	0.37(0.12)	0.34(0.12)	-0.048(-0.084 to -0.012)	0.010**	0.35(0.12)	0.000(-0.039 to 0.038)	0.982
Perimeter/mm	2.26(0.37)	2.14(0.36)	-0.165(-0.279 to -0.052)	0.005**	2.15(0.40)	-0.025(-0.146 to 0.097)	0.691
Circularity	0.90(0.03)	0.90(0.04)	0.011(0.000 to 0.022)	0.041*	0.92(0.03)	0.019(0.008 to 0.030)	0.001**
PD(%) in the DCP							
Center	25.41(4.73)	26.79(4.29)	1.738(-0.695 to 4.172)	0.161	30.51(15.82)	4.968(2.379 to 7.556)	<0.001***
Inner Ring	48.86(1.59)	40.09(1.49)	0.282(-0.252 to 0.816)	0.299	48.89(2.18)	0.099(-0.468 to 0.667)	0.731
Outer Ring	49.85(1.01)	50.08(1.03)	0.182(-0.141 to 0.506)	0.267	50.29(1.07)	0.542(0.198 to 0.886)	0.002**
PD(%) in the SCP							
Center	23.63(5.04)	25.44(4.49)	2.490(-0.050 to 5.031)	0.055	27.83(16.50)	3.283(0.581 to 5.985)	0.017*
Inner Ring	39.65(2.35)	39.75(1.66)	0.257(-0.777 to 1.291)	0.625	40.80(6.30)	0.938(-0.162 to 2.038)	0.094
Outer Ring	44.97(1.44)	45.28(1.06)	0.293(-0.246 to 0.832)	0.286	45.40(2.82)	0.449(-0.125 to 1.022)	0.125
FD(%) in the CC							
Center	34.39(8.25)	34.29(7.18)	-0.745(-3.301 to 1.810)	0.566	38.11(8.25)	4.095(1.377 to 6.813)	0.003**
Inner Ring	33.41(8.52)	33.71(7.85)	-0.425(-3.084 to 2.234)	0.753	35.46(9.04)	2.432(-0.396 to 5.260)	0.092
Outer Ring	32.03(7.52)	32.03(6.66)	-0.582(-2.924 to 1.759)	0.625	33.13(8.01)	1.418(-1.073 to 3.908)	0.263

Legends: The comparisons of OCTA parameters between the PA-ST group with HC and the PA-FT group with HC. OCTA values are presented as the mean [standard deviation (SD)]. Linear regressions were performed and adjusted for age and gestational age. * $P < 0.05$; ** $P < 0.01$; and *** $P < 0.001$. PA-ST: pregnancy with anemia diagnosed in the second or third trimester; PA-FT: pregnancy with anemia diagnosed in the first trimester; HC: healthy pregnant controls; OCTA, optical coherence tomography angiography; PD, perfusion density; FD: flow deficits; FAZ, foveal avascular zone; SCP, superficial capillary plexus; DCP, deep capillary plexus; CC, choriocapillaris; Center: d=1mm ring of ETDRS grid; Inner Ring: d=1-3mm ring of ETDRS grid; Outer Ring: d=3-6mm ring of ETDRS grid. ETDRS: Early Treatment Diabetic Retinopathy Study.